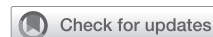

## Avoiding the atrioventricular node in tricuspid replacement: The interatrial septal patch technique



Stephen M. Spindel, MD,<sup>a</sup> Reginald E. Du, MD,<sup>a</sup> Jasmine Su, BS,<sup>b</sup> Antonio Polanco, MD,<sup>c</sup> Katrina J. Jiang, BA,<sup>d</sup> and Autumn P. Stevenson, MD,<sup>a</sup> New Orleans, La; Amherst, Mass; and Baltimore, Md

From the <sup>a</sup>Section of Cardiothoracic Surgery, Department of Surgery, Ochsner Medical Center, New Orleans, La;

<sup>b</sup>The University of Massachusetts, Amherst, Mass; <sup>c</sup>Division of Cardiac Surgery, The Johns Hopkins University, Baltimore, Md; and <sup>d</sup>The University of Queensland Medical School, Ochsner Clinical School, New Orleans, La.

Received for publication Aug 30, 2023; revisions received Oct 2, 2023; accepted for publication Oct 3, 2023; available ahead of print Oct 11, 2023.

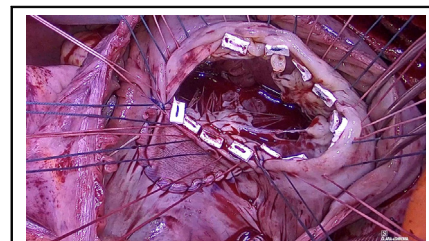
Address for reprints: Stephen M. Spindel, MD, Section of Cardiothoracic Surgery, Ochsner Medical Center, 1514 Jefferson Highway, New Orleans, LA 70121 (E-mail: [stephenspindel123@gmail.com](mailto:stephenspindel123@gmail.com)).

JTCVS Techniques 2023;22:204-7

2666-2507

Copyright © 2023 The Author(s). Published by Elsevier Inc. on behalf of The American Association for Thoracic Surgery. This is an open access article under the CC BY-NC-ND license (<http://creativecommons.org/licenses/by-nc-nd/4.0/>).

<https://doi.org/10.1016/j.jtcv.2023.10.003>



Interatrial septal patch technique avoids atrioventricular tissue in tricuspid replacement.

### CENTRAL MESSAGE

The interatrial septal patch technique can avoid damage to the conduction tissue during tricuspid valve replacement.

▶ Video clip is available online.

Despite improvements in valvular surgery outcomes, tricuspid replacement continues to have a high in-hospital mortality of 20% and considerable morbidity, specifically the 21% pacemaker implantation rate.<sup>1,2</sup> Given the close association between the tricuspid annulus and atrioventricular node, suture placement here results in significantly greater chances of conduction dysfunction versus other valvular interventions.<sup>2,3</sup> This article describes a method that circumvents the conduction pathways during tricuspid replacement. The novel technique can be deployed for any tricuspid pathology requiring replacement and may be particularly advantageous for patients with endocarditis, since repair is unlikely. The subject(s) provided informed written consent for the publication of the study data. The institutional review board was not required.

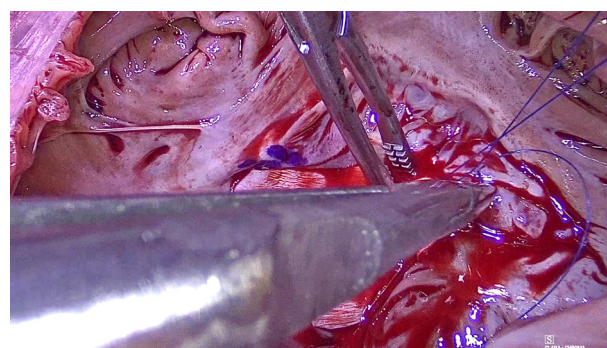
### PROCEDURE

The procedure is performed through a median sternotomy or right thoracotomy. Cardiopulmonary bypass is initiated, and the surgery is undertaken on a beating or arrested heart. The right atrium is opened, and if the valve is not repairable, the interatrial septal patch technique is initiated.

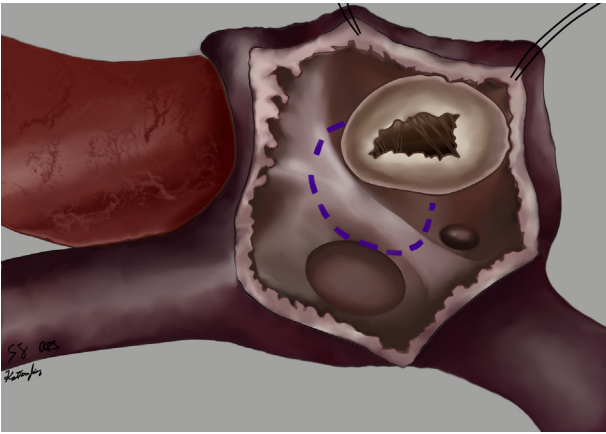
The purpose is to anchor the tricuspid prosthesis, simultaneously bypassing the conduction tissue (Video 1). It is accomplished by prohibiting suture placement in the tricuspid annulus between the 6-o'clock to 10-o'clock positions, yet still anchoring the prosthesis here. This is

achieved through a patch established to hold the sewing cuff sutures while avoiding the atrioventricular node.

The danger zone is marked (Figure 1), providing a 1-cm radius around the apex of the triangle of Koch, which circumvents atrioventricular nodal tissue. A bovine pericardial patch is fashioned into a 5-cm × 4-cm semicircle. The inferior corner of the patch is tacked to the 6-o'clock position of the tricuspid annulus with a 4-0 polypropylene suture. This suture remains double-armed with needles to anastomose

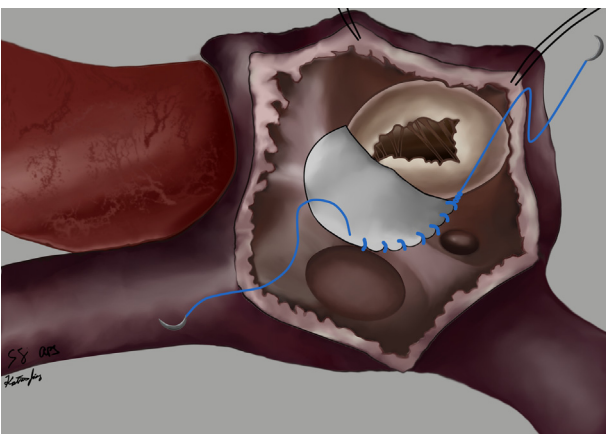


**VIDEO 1.** Intraoperative video illustrating the interatrial septal patch technique to assist in decreasing the risk of atrioventricular nodal injury during tricuspid valve replacement. Video available at: [https://www.jtcvs.org/article/S2666-2507\(23\)00380-2/fulltext](https://www.jtcvs.org/article/S2666-2507(23)00380-2/fulltext).



**FIGURE 1.** The bovine pericardial patch is anastomosed to these landmarks.

the patch in two directions: along the tricuspid leaflets and into the interatrial septum, meeting at the 10-o'clock position on the tricuspid annulus. The first suture arm anastomoses the patch to the interatrial septum in a continuous fashion, starting from 6 o'clock and heading posterolaterally (Figure 2). This suture line travels into the mouth of the coronary sinus, onto the lateral edge of the Tendon of Todaro, then near the medial edge of the fossa ovalis. The suture line continues anteromedially towards the 10-o'clock position of the tricuspid annulus and staying 1 to 2 cm distal to the atrioventricular node. The second suture arm completes the patch anastomosis by traveling from 6 o'clock to 10 o'clock (Figure E1). This suture anastomoses the patch into the tricuspid leaflets, not the tricuspid annulus. It includes the bases of half the septal leaflet and third of the anterior leaflet but avoids all the tricuspid annulus and the nearby atrioventricular nodal tissue. Both suture arms rejoin at the 10-o'clock position of



**FIGURE 2.** The first arm of the suture anastomoses the patch to the interatrial septum.

the annulus and are tied, completing the bovine pericardial patch anastomosis to the interatrial septum.

The prosthetic valve anchoring sutures are now placed. Pledged polyethylene sutures are placed clockwise from the 6-o'clock position to the 10-o'clock position solely through the bovine pericardial patch, avoiding the tricuspid annulus deep to the patch (Figure E2). These sutures will anchor the prosthetic valve into a patch, which gains its strength from a very long suture line, distributing the force throughout its circumference. The remaining anchor sutures are inserted circumferentially into the annulus as in a standard tricuspid replacement. All sutures are passed through the sewing cuff of the prosthetic valve, the valve is lowered in place, and the sutures are tied (Figure E3). The valve is tested with saline, and the right atrium is closed.

## DISCUSSION

Although once a not-so-common operation, tricuspid replacement has become more ubiquitous secondary to endocarditis and the opioid epidemic.<sup>4</sup> With high recidivism and poor social support, these individuals can be challenging to treat, and that challenge is heightened when pacemaker implantation is required.<sup>2,5</sup> As endocarditis prevalence increases, methods to combat the morbidity associated with tricuspid interventions should be developed.

The interatrial septal patch technique is a simple and reproducible method to minimize atrioventricular nodal injury by adhering the tricuspid prosthesis onto a patch rather than into the conduction tissue itself. This novel technique aims to decrease postoperative pacemaker rates and has been applied to 5 patients with endocarditis at this institution; none experienced postoperative conduction disturbances.

## CONCLUSIONS

Avoiding the conduction tissue during tricuspid valve replacement may potentially decrease postoperative conduction disturbances. The interatrial patch technique uses anatomical landmarks to circumvent the atrioventricular nodal area while providing a strong anchoring point to substitute for annular suture placement. The goal of this novel approach is to potentially minimize a major morbidity associated with tricuspid replacement.

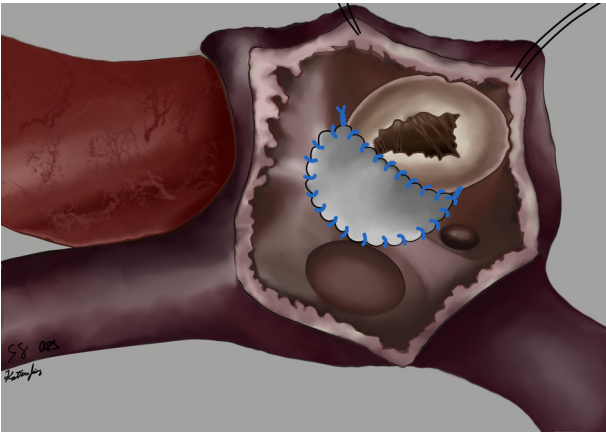
## Conflict of Interest Statement

The authors reported no conflicts of interest.

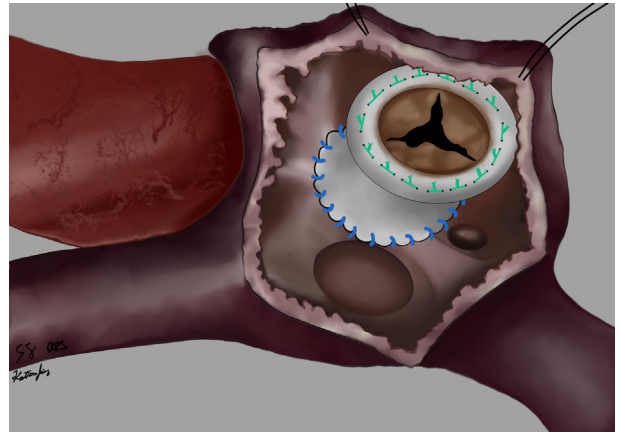
The *Journal* policy requires editors and reviewers to disclose conflicts of interest and to decline handling or reviewing manuscripts for which they may have a conflict of interest. The editors and reviewers of this article have no conflicts of interest.

### References

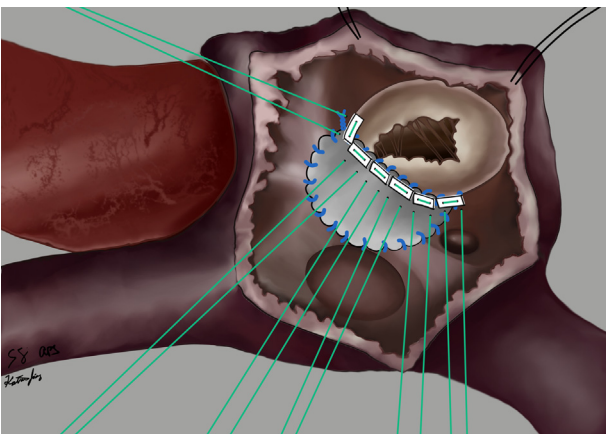
1. Filsoufi F, Anyanwu AC, Salzberg SP, Frankel T, Cohn LH, Adams DH. Long-term outcomes of tricuspid valve replacement in the current era. *Ann Thorac Surg.* 2005;80:845-50.
2. Jokinen JJ, Turpeinen AK, Pitkänen O, Hippeläinen MJ, Hartikainen JE. Pacemaker therapy after tricuspid valve operations: implications on mortality, morbidity, and quality of life. *Ann Thorac Surg.* 2009;87:1806-14.
3. Jouan J, Mele A, Florens E, Chatellier G, Carpentier A, Achouh P, et al. Conduction disorders after tricuspid annuloplasty with mitral valve surgery: implications for earlier tricuspid intervention. *J Thorac Cardiovasc Surg.* 2016;151:99-103.
4. Slaughter MS, Badhwar V, Ising M, Ganzel BL, Sell-Dottin K, Jaqitz OK, et al. Optimum surgical treatment for tricuspid valve infective endocarditis: an analysis of the Society of Thoracic Surgeons national database. *J Thorac Cardiovasc Surg.* 2021;161:1227-35.e1.
5. Protos AN, Trivedi JR, Whited WM, Rogers MP, Owolabi U, Grubb KJ, et al. Valvectomy versus replacement for the surgical treatment of tricuspid endocarditis. *Ann Thorac Surg.* 2018;106:664-9.



**FIGURE E1.** The second arm of the suture completes the patch anastomosis.



**FIGURE E3.** The prosthetic valve is anchored to the patch, subsequently avoiding the conduction tissue.



**FIGURE E2.** Prosthetic valve anchoring sutures are placed solely through the patch from 6-o'clock to 10-o'clock positions, avoiding the tricuspid annulus here.