

Utility of preoperative ferumoxtran-10 MRI to evaluate retroperitoneal lymph node metastasis in advanced cervical cancer: Results of ACRIN 6671/GOG 0233[☆]

Mostafa Atri^{a,*}, Zheng Zhang^b, Helga Marques^b, Jeremy Gorelick^b, Mukesh Harisinghani^c, Aslam Sohaib^d, Dow-Mu Koh^d, Steven Raman^e, Michael Gee^c, Haesun Choi^f, Lisa Landrum^g, Robert Mannel^g, Linus Chuang^h, Jian Qin (Michael) Yuⁱ, Carolyn Kay McCourt^j, Michael Gold^k

^a Toronto General Hospital, Canada

^b Brown University, United States

^c Massachusetts General Hospital, United States

^d Royal Marsden Hospital, United Kingdom

^e University of California at Los Angeles, United States

^f MD Anderson Cancer Center, United States

^g University of Oklahoma, United States

^h Mount Sinai School of Medicine, United States

ⁱ Fox Chase Cancer Center, United States

^j Woman and Infants Hospital of Rhode Island, United States

^k Vanderbilt University, United States

Received 22 September 2014; accepted 25 November 2014

Available online 19 December 2014

Abstract

Rationale and objectives: To assess if ferumoxtran-10 (f-10) improves accuracy of MRI to detect lymph node (LN) metastasis in advanced cervical cancer.

Materials and methods: F-10 MRI component of an IRB approved HIPAA compliant ACRIN/GOG trial was analyzed.

Patients underwent f-10 MRI followed by extra-peritoneal or laparoscopic pelvic and abdominal lymphadenectomy. F-10-sensitive sequences were T2* GRE sequences with TE of 12 and 21. Seven independent blinded readers reviewed f-10-insensitive sequences and all sequences in different sessions. Region correlations were performed between pathology and MRI for eight abdomen and pelvis regions. Sensitivity and specificity were calculated at participant level. Reference standard is based on pathology result of surgically removed LNs.

Results: Among 43 women enrolled in the trial between September 2007 and November 2009, 33 women (mean age 49 ± 11 years old) with advanced cervical cancer (12 IB2, 3 IIA, 15 IIB and 3 IIIB, 29 squamous cell carcinomas, 32 grade 2 or 3) were evaluable. Based on histopathology, LN metastasis was 39% in abdomen and 70% in pelvis. Sensitivity of all sequence review in pelvis, abdomen, and combined were 83%, 60%, and 86%, compared with 78%, 54%, and 80% for f-10 insensitive sequences (P : 0.24, 0.44 and 0.14, respectively). Mean diameter of the largest positive focus on histopathology was 13.7 mm in abdomen and 18.8 mm in pelvis (P = 0.018). Specificities of all sequence review in pelvis, abdomen, and combined were 48%, 75%, and 43%, compared with 75%, 83%, and 73% (P : 0.003, 0.14, 0.002 respectively) for f-10 insensitive sequences.

[☆] American College of Radiology Imaging Network [ACRIN] (U10 CA80098 and U10 CA079778) and Gynecologic Oncology Group [GOG] (U10CA27469 and U10 CA37517) receive funding through the National Cancer Institute (NCI). Presented in part at the American Society of Clinical Oncology 2011 Annual Meeting, Chicago, Illinois, June 3–7, 2011.

* Corresponding author at: NCSB 1C569, Toronto General Hospital, Department of Medical Imaging, University Health Network, 585 University Avenue Toronto, ON, Canada M5G 2N2. Tel.: +1 416 340 4800x3253.

E-mail address: mostafa.atri@uhn.on.ca (M. Atri).

Conclusion: Addition of f-10 increased MRI sensitivity to detect LN metastasis in advanced cervical cancer. Increased sensitivity did not reach statistical significance and was at the expense of lower specificity.

© 2014 Published by Elsevier Ltd. This is an open access article under the CC BY-NC-ND license (<http://creativecommons.org/licenses/by-nc-nd/4.0/>).

Keywords: Cervical cancer; Lymph node metastasis; MRI; USPIO; Ferumoxtran-10

1. Introduction

Nonsurgical therapy fails to control locoregional disease in 20–85% of patients with locally advanced cervical carcinoma [1–6]. This may be due to understaging clinically [7]. In many instances, errors in staging are related to undiagnosed lymph node (LN) metastases [8,9]. In a recent meta-analysis, positive predictive value (PPV) of CT was 60% and the negative predictive value (NPV) was 91% for detection of retroperitoneal lymph node metastasis with no significant difference between MRI and CT accuracy [10].

It is suggested that accuracy of MRI is improved by using ferumoxtran-10 (f-10) nanoparticles. f-10, an ultra-small particle iron oxide (USPIO) agent, is the most widely investigated contrast medium in clinical trials. It has been used in a number of malignancies, including breast [11], lung [12], head and neck [13,14], and abdominal and pelvic malignancies [15,16]. In a recent study Rockall et al. [17] evaluated 44 women with endometrial ($n = 15$) and cervical ($n = 29$) cancer with f-10, sensitivity of f-10 MRI was significantly higher than size criteria for one reviewer ($P = 0.031$) and showed a trend in the other reviewer ($P = 0.06$) without compromise of specificity.

This prospective multicenter clinical trial conducted by ACRIN (American College of Radiology Imaging Network) and GOG (Gynecology Oncology Group) was designed to evaluate the efficacy of PET/CT and f-10 MRI in the evaluation of LN metastasis in women with advanced cervical cancer. Since the provider of Combidex decided to discontinue further production, MRI component of the trial was closed. We report the results of the MRI component here. Our hypothesis was that f-10 improves accuracy of standard MRI (without USPIO agent) to detect LN metastasis in women with loco-regionally advanced cervical cancer.

2. Materials and methods

2.1. Study population

This is an IRB approved HIPAA compliant non-randomized prospective multicenter trial conducted by ACRIN/GOG. All patients provided written consent to participate in the study. Trial was IRB approved at all centers.

Patients were included who had primary, previously untreated, histologically confirmed, loco-regionally advanced (stages IB2, IIA2, IIB-IVA based on clinical examination \pm imaging), invasive carcinoma of the cervix and were appropriate surgical candidate to undergo extra-peritoneal or laparoscopic pelvic and abdominal LN sampling within 2 weeks after MRI. Patients who had metastasis outside of the pelvis or

abdominal LNs, prior pelvic radiation therapy or prior pelvic or abdominal lymphadenectomy, other invasive malignancies within the last 5 years, with the exception of non-melanoma skin cancer, and patients who had received ferumoxides within 2 weeks of enrollment were excluded.

2.2. Imaging protocol

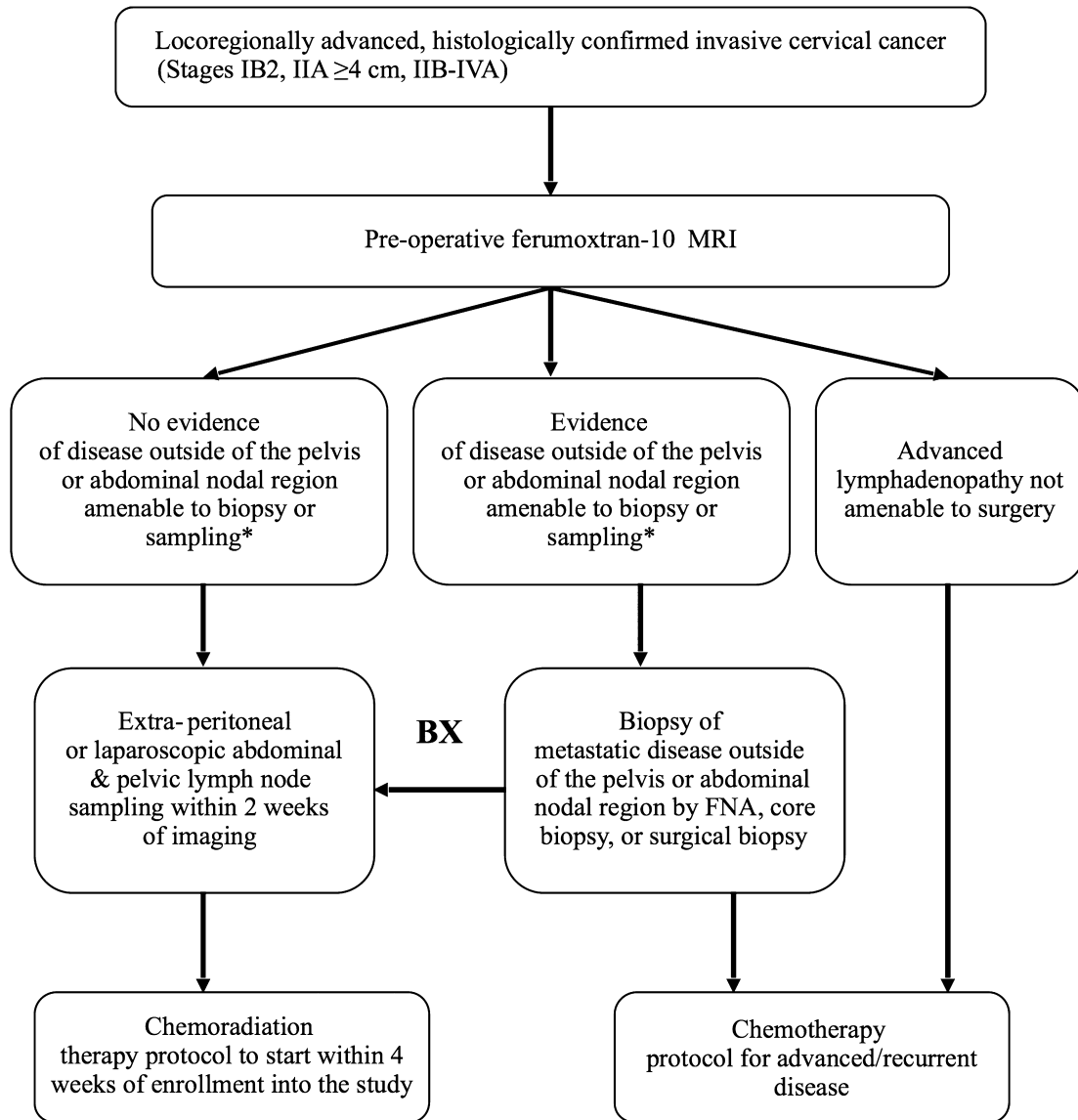
Trial schema is shown in Fig. 1. All analyzed patients underwent MRI followed by surgery within 2 weeks of MRI.

Patients underwent a single MRI, performed on a 1.5 T magnet with pelvic phased-array coil extending from pubic symphysis to the level of the origin of the inferior mesenteric artery. The MR sequences consisted of axial T1 GRE, axial and sagittal FSE, and axial T2* GRE. Slice thickness was 3 mm and no gap for all sequences. T2* sequences were obtained at TE of 12 and 21. MRIs were acquired 24–36 h after intravenous administration of f-10. Patients received 2.6 mg/kg of f-10 (Combindex; AMAG pharmaceuticals, Lexington, MA) diluted in 100 ml of normal saline and infused over 30 min. F-10 was provided as an IND (investigational new drug) agent by AMAG Inc (Cambridge, MA). IND was held by the National Cancer Institute. The use of anti-peristaltic glucagon, 1 mg IM was encouraged and 20/33 (61%) received glucagon. We obtained only a post f-10MRI since it has been validated that trained reviewers would perform equally well reviewing post-f-10 MRI without access to pre-f-10 MRI [18].

2.3. Surgery

Surgery consisted of lymphadenectomy in eight nodal regions: right and left obturator, right and left external iliac, right and left common iliac, and right para-caval and aorto-caval and left para-aortic. Each was compared separately between MRI and lymphadenectomy results. Surgeons were expected to provide a full lymphadenectomy for each of the eight regions independently or confirm malignancy by intra-operative biopsy, if a region was not resectable. Combined external iliac and obturator LN sub-regions were considered pelvic region and combined common iliac and para-aortic LN sub-regions were considered abdominal region for statistical analysis. A patient was considered to have pelvic or abdominal malignant lymphadenopathy if there was at least one of the included 4 sub-regions involved.

Surgeons were not blinded to the pre-enrollment imaging results. Protocol required discussion of the result of f-10 MRI with the surgeons. However, we could not confirm if this discussion occurred.



*(i.e., intrahepatic or pulmonary metastasis; bony involvement; suprarenal, thoracic, or supraclavicular lymphadenopathy; or lymphadenopathy above the renal hilum on PET/CT)

Fig. 1. Study schema.

2.4. Pathology analysis

Pathology review was performed at each institution. For LNs smaller than 10mm in long axis, they were bisected into two halves, each approximately 5 mm thick. For LNs longer than 10mm, the nodes were sectioned at 5 mm intervals parallel to the short axis, and one slide was prepared from each section. The following data were collected: total number of LNs per sub-region, presence/absence of LN metastasis, size of the largest focus of metastasis per sub-region, size of the largest positive and negative LN per sub-region.

2.5. Imaging review

The initial design of the study required review by seven reviewers based on sample size calculation. Four of the seven readers had previous experience in review of f-10 trials and the other three went through an initial didactic training as well as three test cases before reviewing study MRIs. Test cases were not selected from study cases. The readers independently reviewed MRIs, blinded to the clinical information and final pathology results. They were chosen from centers not involved in the accrual of patients. Readers were provided MRI images either at the ACRIN headquarters or in

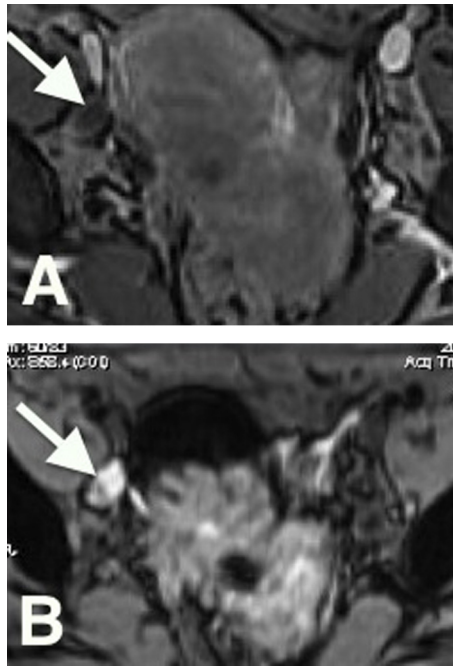


Fig. 2. (A) Axial T1W (TR 175, TE 1.9), and B) axial T2* (TR 2200, TE 21) in a 34 year-old woman with squamous carcinoma of the cervix. A right obturator lymph node is present (arrows) measuring 10 mm × 10 mm that is hypo T1 signal (A), and high T2* signal (B) indicating lack of accumulation of USPIO agent. This was a true positive LN at pathology.

their own institutions using different commercially available familiar workstation. Review process was arranged in two settings; (a) first, all sequences excluding T2* GRE sequence were reviewed (USPIO-insensitive sequences), (b) second, review of all sequences including USPIO-sensitive sequences. During the first review of each region, the number of positive and negative LNs, presence/absence of metastatic LN, and short axis of the largest positive/negative LNs was recorded. A LN was considered positive if the short axis was >8 mm for a node with short axis > half the length of long axis, and >10 mm for a node with short axis < half the length of long axis in all regions. Previously published criteria were used for evaluation of USPIO-sensitive sequences [18]. High intensity LN or high intensity focus in an otherwise normal intensity LN on T2* was considered positive (Fig. 2).

The LNs were rated from 1 to 6 to capture the possibility of malignancy, with 1 = definitely benign, 2 = most likely benign, 3 = probably benign, 4 = probably malignant, 5 = most likely malignant and 6 = definitely malignant. For the purpose of sensitivity and specificity calculation, 1–3 was considered negative and 4–6 was considered positive.

2.6. Data analysis

The primary unit of analysis was patient and not nodal region. Pathology data was the reference standard. The abdomen or pelvis region was considered positive if at least one of the corresponding four sub-regions had a positive reference standard. However, if any sub-regional reference standard was missing,

and the rest of the sub-regions were negative, the reference standard for abdomen or pelvis was considered missing.

In order for the reader to get credit for making a correct diagnosis, the true positive node should be on the same side as identified by the imaging, i.e. para-aortic or common iliac for abdomen region, and external iliac or obturator for pelvic region. For the calculation of sensitivity, specificity, NPV, PPV, and AUC, the individual reader scores were used.

For each reader, 95% CIs for the estimates of sensitivity, specificity, PPV and NPV were presented as the exact confidence intervals (Clopper-Pearson). 95% CIs for the differences in sensitivity and specificity were calculated using the method by Fleiss [19]. *P*-values for the sensitivity and specificity comparisons were based on McNemar's test statistic. Comparison of PPVs and NPVs were based on a GEE model proposed by Leisenring et al. [20], where the link function was chosen to be the logit function, hence the inference was made on the odds ratio of PPV or NPV and *P*-values were derived from Wald's statistic. Estimates, 95% CIs and *P*-values related to AUC were derived by using the Delong & Delong method [21] for empirical ROC curve.

Comparison of the average sensitivity/specificity, PPV, and NPV between USPIO-insensitive sequences and all sequences, for an average reader, were computed with a generalized linear mixed model with a random reader effect. The comparison of average empirical AUCs between USPIO-insensitive sequences and all sequences, from all seven readers, were computed using Obuchowski's method [22]. MRI diagnoses of LN metastasis (yes/no) from the seven readers were compared with kappa statistics, assuming all observations are independent, for USPIO-insensitive sequences and all sequences, and for abdominal, pelvic, and combined. The sensitivities or specificities between the seven readers were compared with generalized estimating equation methodology.

3. Results

Forty-three women were accrued to the trial between September 2007 and November 2009 at seven centers. Of those, 33 had undergone both MRI and surgery and were evaluable. The other 10 patients were excluded because of the following reasons: patient refusing MRI ($n=5$), and no surgery due to the extent of disease ($n=5$). The 33 evaluable patients have mean age 49 ± 11 years. The stage distribution is 12 IB2, 3 IIA, 15 IIB, and 3 IIIB. The tumor types are 29 squamous cell carcinoma, 3 adenocarcinoma, and 1 embryonal rhabdomyosarcoma. There are 1 grade 1, 20 grade 2, and 12 grade 3 tumors. The mean primary tumor size is 5.4 ± 1.5 cm (median 5.6 cm, range 1.9–8.0 cm) as measured on MRI.

Of the 33 patients, 31 had complete information for abdominal lymph nodes based on pathology, and 12 were positive (prevalence 39%). Thirty patients had complete information for pelvic lymph nodes, and 21 were positive (prevalence 70%). Ten of 12 patients with abdominal lymph node metastasis also had pelvic metastasis. Range and mean size of the largest metastatic focus in the LN on pathology in the abdomen were 1–30 mm (mean 13.7 ± 10 mm) and in the pelvis were 2–50 mm (mean

18.8 ± 11.7 mm). The largest focus of metastasis in a LN was larger in the pelvis than those in the abdomen ($P=0.018$).

The sensitivities of f-10 MRI all sequences to detect LN metastasis were 83% in pelvis, 60% in abdomen, and 86% abdomen and pelvis combined, compared with 78%, 54%, and 80% respectively for USPIO-insensitive sequences. Although the sensitivities of f-10 MRI all sequences were higher than the ones from USPIO-insensitive sequences for all three comparisons, the differences were not statistically significant ($P=0.24$, 0.44 and 0.14, respectively) (Table 1).

The specificities of f-10 MRI all sequences were 48% in pelvis, 75% in abdomen, and 43% abdomen and pelvis combined, compared with 75%, 83%, and 73% for USPIO-insensitive sequences. Although the specificities of f-10 MRI all sequences were lower than the ones from USPIO-insensitive sequences for all three comparisons, the differences were significant in the pelvis ($P=0.003$) and combined abdomen/pelvis ($P=0.002$) but not in the abdomen alone ($P=0.14$).

To determine the effect of LN size on the accuracy values of f-10, we compared the accuracy values for LN metastasis detection for LNs > 8 mm in short axis and those ≤ 8 mm (Table 2). Eight millimeter was used as a threshold since this is the value we used to consider a LN abnormal on USPIO-insensitive sequences. LN size on USPIO-insensitive sequences were used to do this analysis. Among patients with LNs ≤ 8 mm (which, by definition, were negative on USPIO-insensitive sequences), f-10 MRI increased sensitivity of MRI from 0% to 18% ($P=0.018$) in the abdomen and from 9% to 36% ($P=0.011$) in the pelvis but this was at the expense of reduced specificity. Among patients with LNs > 8 mm, the addition of f-10 MRI did not improve sensitivity over USPIO-insensitive sequences alone.

The areas under the ROC curve (AUC) for both sets of sequences review were almost identical, with AUC of 0.69 in the abdomen for both sets of sequences. AUC was 0.78 for USPIO-insensitive sequences and 0.75 for all sequences review in the pelvis ($P=0.47$) (Table 1).

Table 3 shows inter-reader agreement on lymph node metastasis diagnosis for all regions. The inter-reader agreement to identify a LN as positive or negative was good to excellent (Kappa: 0.74–0.89) for USPIO-insensitive sequences that relied on size criteria alone. The agreement was moderate (Kappa: 0.46–0.54) for all sequences. The sensitivity and specificity values for each individual reader in any of the regions did not differ significantly ($P>0.32$).

4. Discussion

The purpose of this trial was to determine the accuracy of f-10 MRI in the detection of LN metastasis in loco-regionally advanced cervical cancer. The knowledge of the extent of LN metastasis is important to determine the radiation field in those patients who undergo primary chemo-radiotherapy or postoperative adjuvant radiotherapy.

The prevalence of LN metastasis in this cohort was 70% in the pelvis and 39% in the abdomen with two patients with abdominal LN metastasis only. This corresponds to the known sequential LN metastasis in cervix cancer with pelvic LN metastases generally occurring first, followed by common iliac and abdominal LN metastasis [23]. The prevalence of LN metastasis in our cohort is higher than that previously reported in the literature [23,24]. This may potentially be related to a number of factors, including more complete surgical lymphadenectomy being performed on this prospective evaluation with a defined surgical

Table 1
Accuracy values comparing average results of the 7 readers for all sequences and USPIO-insensitive sequences. Est.: Estimate.

	All sequence			USPIO-insensitive sequence			P-value
	Est	95% CI	Range	Est	95% CI	Range	
<i>Abdomen</i>							
Sensitivity	0.60	(0.49, 0.70)	0.50–0.75	0.54	(0.43, 0.64)	0.50–0.58	0.438
Specificity	0.75	(0.67, 0.82)	0.58–0.89	0.83	(0.75, 0.88)	0.68–0.89	0.136
AUC	0.69	(0.52, 0.85)	0.62–0.75	0.69	(0.52, 0.85)	0.62–0.73	0.926
PPV	0.60	(0.49, 0.70)	0.47–0.75	0.66	(0.54, 0.76)	0.54–0.75	0.454
NPV	0.75	(0.67, 0.81)	0.69–0.83	0.74	(0.66, 0.80)	0.70–0.76	0.878
Accuracy	0.69	(0.63, 0.75)	0.58–0.77	0.71	(0.65, 0.77)	0.65–0.74	0.600
<i>Pelvis</i>							
Sensitivity	0.83	(0.76, 0.88)	0.71–0.90	0.78	(0.70, 0.84)	0.76–0.81	0.243
Specificity	0.48	(0.35, 0.61)	0.22–0.67	0.75	(0.62, 0.84)	0.56–0.89	0.003
AUC	0.73	(0.58, 0.88)	0.58–0.85	0.75	(0.60, 0.89)	0.73–0.85	0.726
PPV	0.79	(0.72, 0.84)	0.68–0.85	0.88	(0.81, 0.92)	0.80–0.94	0.049
NPV	0.55	(0.41, 0.67)	0.25–0.67	0.59	(0.48, 0.69)	0.50–0.64	0.629
Accuracy	0.72	(0.66, 0.78)	0.57–0.77	0.77	(0.70, 0.82)	0.70–0.80	0.315
<i>Combined</i>							
Sensitivity	0.86	(0.79, 0.90)	0.78–0.96	0.80	(0.73, 0.85)	0.78–0.83	0.144
Specificity	0.43	(0.30, 0.56)	0.25–0.63	0.73	(0.60, 0.83)	0.63–0.88	0.002
AUC	0.71	(0.54, 0.88)	0.62–0.84	0.74	(0.57, 0.91)	0.73–0.82	0.435
PPV	0.81	(0.75, 0.86)	0.75–0.87	0.90	(0.83, 0.94)	0.86–0.95	0.043
NPV	0.51	(0.37, 0.65)	0.29–0.67	0.55	(0.44, 0.66)	0.50–0.60	0.642
Accuracy	0.75	(0.68, 0.80)	0.65–0.81	0.78	(0.72, 0.83)	0.74–0.81	0.430

Table 2
Accuracy values comparing average results of the seven readers for all sequences and USPIO-insensitive sequences for nodes with longest short axis above and below 8 mm as determined by MRI.

		All sequences		USPIO-insensitive sequences		P-value
		Est	95% CI	Est	95% CI	
<i>Abdomen</i>						
≤8 mm	Sensitivity	0.18	(0.06, 0.44)	0.00		0.018
	Specificity	0.85	(0.74, 0.92)	0.97	(0.91, 0.99)	0.004
>8 mm	Sensitivity	0.93	(0.81, 0.98)	0.98	(0.86, 1)	0.333
	Specificity	0.23	(0.06, 0.61)	0.07	(0.01, 0.41)	0.133
<i>Pelvis</i>						
≤8 mm	Sensitivity	0.36	(0.19, 0.58)	0.09	(0.03, 0.27)	0.011
	Specificity	0.56	(0.4, 0.71)	0.92	(0.8, 0.97)	<0.001
>8 mm	Sensitivity	0.98	(0.93, 1)	1.00		0.998
	Specificity	0.15	(0.03, 0.48)	0.08	(0.01, 0.43)	0.554

Table 3
Agreement of readers on positive/negative diagnosis at the region level. Kappa statistics was used for inter-observer agreement. Kappa values ≤0 is poor, 0–0.2 is slight, 0.2–0.4 is fair, 0.4–0.6 is moderate, 0.6–0.8 is substantial, 0.8–1 is almost perfect.

Comparison of all readers	All sequence			USPIO-insensitive sequences		
	Kappa	Standard error	P-value	Kappa	Standard error	P-value
<i>Region</i>						
Abdomen	0.54	0.04	<0.001	0.74	0.04	<0.001
Pelvis	0.52	0.04	<0.001	0.84	0.04	<0.001
Combined	0.46	0.04	<0.001	0.89	0.04	<0.001

endpoint, or selection bias on the part of the surgeons if they had access to pre-enrollment imaging.

The sensitivity of all sequences was higher than USPIO-insensitive sequences in both abdomen and pelvis, but without statistical significance. Due to the moderate size of the study population, this study may lack sufficient power to detect a true improvement of diagnostic sensitivity with f-10 MRI compared with an MRI without f-10. F-10 increases sensitivity of MRI significantly to detect LN metastasis in LNs with short axis ≤ 8 mm in both the abdomen and the pelvis but this was at the expense of reduced specificity. Improving sensitivity is in agreement with other studies and a recent meta-analysis of the utility of f-10 MRI in different cancers [25].

The mean diameter of the largest positive focus in the LNs of abdomen was significantly smaller than in the pelvis. The sensitivity of both sets of sequences was lower in the abdomen, likely due to the smaller size of metastatic foci in the abdominal LNs. The specificities of USPIO-insensitive sequences were significantly higher than those of all sequences in the pelvis and combined abdomen/pelvis but not in the abdomen.

It is difficult to explain the lower specificity of MRI considering we were not able to do node for node analysis in this multicenter trial. We speculate, however, that it could be partly related to lack of removal of some of the involved LNs on imaging during lymphadenectomy. Fig. 3 is an example of an enlarged common iliac LN that was positive on all sequence. This LN region was called negative on lymphadenectomy. Some regions are likely more difficult to dissect, such as LNs posterior to the common iliac vessels. In a multicenter study of f-10 MRI in prostate cancer, a high percentage of positive lymph nodes could

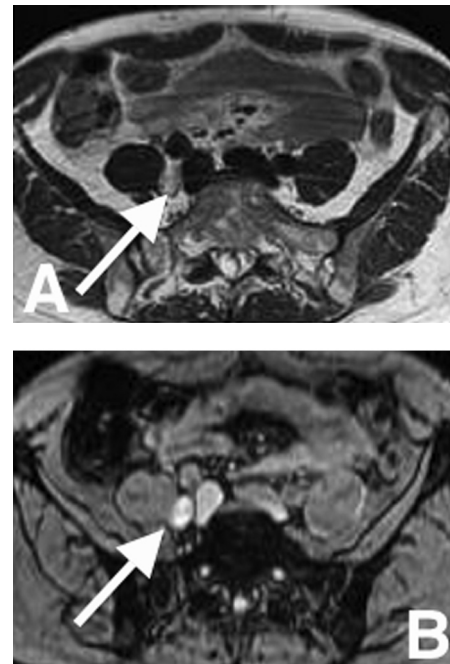


Fig. 3. (A) Axial T2W (TR 5500, TE), and B) axial T2* (84 TR 2200, TE 21) in a 17 year-old-woman with squamous carcinoma of the cervix. A lymph node is present posterior to the right common iliac artery (arrows) measuring 10 mm × 15 mm that is intermediate T2 signal (A), and high T2* signal (B) indicating lack of accumulation of USPIO agent. This was region was called negative at pathology likely because of the location of this lymph node behind the artery and not accessible to lymphadenectomy.

be confirmed histologically only by extended lymphadenectomy beyond the standard lymphadenectomy or MR or CT-guided biopsy [26]. Similar results were obtained in another study evaluating diffusion-weighted MR imaging in normal sized lymph nodes in patients with bladder or prostate cancer using extended pelvic lymphadenectomy [27]. Another explanation would be a true false positive by f-10 MRI. Many patients with cervical cancer develop chronic infection within their primary tumor. This could potentially result in reactively enlarged lymph nodes. It is possible that reactive LNs caused apparent defects within the nodes resulting in false positive diagnosis. In the multicenter trial on prostate cancer [26], 24% of positive LNs on f-10 MRI did not show histological confirmation [26]. There is no other study that has evaluated the utility of f-10 MRI in this cohort of patients. However, multicenter trials generally have less favorable results than the single center studies.

The inter-reader agreement to identify positive or negative LN was good to excellent for USPIO-insensitive sequences that relied on size criteria. The agreement was moderate for sequences relying on USPIO sensitive sequence. This is not unexpected since this sequence is less robust to acquire and more difficult to interpret. The range of experience of the seven readers in this study did not significantly influence their accuracy values ($P > 0.05$).

This study has a number of limitations. The main limitation is the small sample size due to stoppage of the trial because of unavailability of Combixidex. The second limitation is that we were not able to do node for node comparison. This is not feasible for most studies that compare imaging with lymphadenectomy, especially in a multicenter trial. New 3D acquisitions with isotropic 1 mm slices could potentially improve results. Additionally, thinner than 5 mm pathology sections could have potentially detected smaller foci of metastasis.

Ferumoxtran-10 has been discontinued but Combixidex® has been purchased by a Dutch university that intends to launch global trials (www.prweb.com/releases/2013/4/prweb10600077.htm).

In conclusion, in this study, the addition of USPIO agent adds to the sensitivity of MRI to detect LN metastasis in advanced cervical cancer. However, specificity was lower in the pelvis when USPIO MRI was considered. Both USPIO-insensitive and sensitive sequences performed better in the pelvis as compared to the abdomen. This appears to be due to larger foci of metastatic disease in the lymph nodes in the pelvis. Further trial with a larger sample size is warranted once a LN specific agent for MRI becomes available.

Funding

Funding from the NCI sponsor paid for all the expenses of the trial.

Conflict of interest

Authors have no conflicts of interest to declare.

Acknowledgement

We acknowledge AMAG pharmaceuticals for providing the agent Combixidex for this trial.

References

- [1] Green J, Kirwan J, Tierney J, Vale C, Symonds P, Fresco L, et al. Concomitant chemotherapy and radiation therapy for cancer of the uterine cervix. *Cochrane Database Syst Rev* 2005;3:CD002225.
- [2] Lukka H, Hirte H, Fyles A, Thomas G, Elit L, Johnston M, et al. Concurrent cisplatin-based chemotherapy plus radiotherapy for cervical cancer: a meta-analysis. *Clin Oncol R Coll Radiol* 2002;14:203–12.
- [3] Perez CA, Fox S, Lockett MA, Grigsby PW, Camel HM, Galakatos A, et al. Impact of dose in outcome of irradiation alone in carcinoma of the uterine cervix: analysis of two different methods. *Int J Radiat Oncol Biol Phys* 1991;21:885–98.
- [4] Lanciano RM, Won M, Coia LR, Hanks GE. Pretreatment and treatment factors associated with improved outcome in squamous cell carcinoma of the uterine cervix: a final report of the 1973 and 1978 patterns of care studies. *Int J Radiat Oncol Biol Phys* 1991;20:667–76.
- [5] Horiot JC, Pigneux J, Pourquier H, Schraub S, Achille E, Keiling R, et al. Radiotherapy alone in carcinoma of the intact uterine cervix according to G. H. Fletcher guidelines: a French cooperative study of 1383 cases. *Int J Radiat Oncol Biol Phys* 1988;14:605–11.
- [6] Stehman FB, Bundy BN, DiSaia PJ, Keys HM, Larson JE, Fowler WC. Carcinoma of the cervix treated with radiation therapy. I. A multi-variate analysis of prognostic variables in the Gynecologic Oncology Group. *Cancer* 1991;67:2776–85.
- [7] Morrow CPCJ, Townsend DE. Synopsis of gynecologic oncology. New York: Churchill Livingstone; 1993.
- [8] Ballon SC, Berman ML, Lagasse LD, Petrilli ES, Castaldo TW. Survival after extraperitoneal pelvic and paraaortic lymphadenectomy and radiation therapy in cervical carcinoma. *Obstet Gynecol* 1981;57:90–5.
- [9] Averette HE, Dudan RC, Ford Jr JH. Exploratory celiotomy for surgical staging of cervical cancer. *Am J Obstet Gynecol* 1972;113:1090–6.
- [10] Scheidler J, Hricak H, Yu KK, Subak L, Segal MR. Radiological evaluation of lymph node metastases in patients with cervical cancer. A meta-analysis. *J Am Med Assoc* 1997;278:1096–101.
- [11] Michel SC, Keller TM, Frohlich JM, Fink D, Caduff R, Seifert B, et al. Preoperative breast cancer staging: MR imaging of the axilla with ultrasmall superparamagnetic iron oxide enhancement. *Radiology* 2002;225:527–36.
- [12] Pannu HK, Wang KP, Borman TL, Bluemke DA. MR imaging of mediastinal lymph nodes: evaluation using a superparamagnetic contrast agent. *J Magn Reson Imag* 2000;12:899–904.
- [13] Sigal R, Vogl T, Casselman J, Moulin G, Veillon F, Hermans R, et al. Lymph node metastases from head and neck squamous cell carcinoma: MR imaging with ultrasmall superparamagnetic iron oxide particles (Sinerem MR) – results of a phase-III multicenter clinical trial. *Eur Radiol* 2002;12:1104–13.
- [14] Mack MG, Balzer JO, Straub R, Eichler K, Vogl TJ. Superparamagnetic iron oxide-enhanced MR imaging of head and neck lymph nodes. *Radiology* 2002;222:239–44.
- [15] Harisinghani MG, Saini S, Weissleder R, Hahn PF, Yantiss RK, Tempany C, et al. MR lymphangiography using ultrasmall superparamagnetic iron oxide in patients with primary abdominal and pelvic malignancies: radiographic-pathologic correlation. *AJR Am J Roentgenol* 1999;172:1347–51.
- [16] Triantafyllou M, Studer UE, Birkhäuser FD, Fleischmann A, Bains LJ, Petralia G, et al. Ultrasmall superparamagnetic particles of iron oxide allow for the detection of metastases in normal sized pelvic lymph nodes of patients with bladder and/or prostate cancer. *Eur J Cancer* 2013;49:616–24.
- [17] Rockall AG, Sohaib SA, Harisinghani MG, Babar SA, Singh N, Jeyarajah AR, et al. Diagnostic performance of nanoparticle-enhanced magnetic resonance imaging in the diagnosis of lymph node metastases in patients with endometrial and cervical cancer. *J Clin Oncol* 2005;23:2813–21.

- [18] Harisinghani MG, Saksena MA, Hahn PF, King B, Kim J, Torabi MT, et al. Ferumoxtran-10-enhanced MR lymphangiography: does contrast-enhanced imaging alone suffice for accurate lymph node characterization. *AJR Am J Roentgenol* 2006;186:144–8.
- [19] Fleiss DJ. Diagnostic tests for gastrocnemius tightness. *J Bone Joint Surg Am* 2003;85-A:760, author reply 760.
- [20] Leisenring W, Alonzo T, Pepe MS. Comparisons of predictive values of binary medical diagnostic tests for paired designs. *Biometrics* 2000;56:345–51.
- [21] DeLong ER, DeLong DM, Clarke-Pearson DL. Comparing the areas under two or more correlated receiver operating characteristic curves: a nonparametric approach. *Biometrics* 1988;44:837–45.
- [22] Obuchowski NA. Hypothesis testing of diagnostic accuracy for multiple readers and multiple tests: An ANOVA approach with dependent observations. *Commun Stat Simul* 1995;24:285–308.
- [23] Hackett TE, Olt G, Sorosky JI, Podczaski E, Harrison TA, Mortel R. Surgical predictors of para-aortic metastases in early-stage cervical carcinoma. *Gynecol Oncol* 1995;59:15–9.
- [24] Inoue T, Morita K. The prognostic significance of number of positive nodes in cervical carcinoma stages IB, IIA, and IIB. *Cancer* 1990;65:1923–7.
- [25] Wu L, Cao Y, Liao C, Huang J, Gao F. Diagnostic performance of USPIO-enhanced MRI for lymph-node metastases in different body regions: a meta-analysis. *Eur J Radiol* 2011;80:582–9.
- [26] Heesakkers RA, Jager GJ, Hövels AM, de Hoop B, van den Bosch HC, Raat F, et al. Prostate cancer: detection of lymph node metastases outside the routine surgical area with ferumoxtran-10-enhanced MR imaging. *Radiology* 2009;251:408–14.
- [27] Thoeny HC, Froehlich JM, Triantafyllou M, Huesler J, Bains LJ, Verma-then P, et al. Metastases in normal-sized pelvic lymph nodes: detection with diffusion-weighted MR imaging. *Radiology* 2014;(June):132921 [Epub ahead of print].