



Navigation of video-assisted thoracoscopic surgery using electromagnetic versus CT-guided localization (NOVEL): a study protocol for comparing procedural success and complication rates in a prospective, multicenter, randomized controlled, non-inferiority phase III trial

Juntao Xie^{1,2#^}, Dingpei Han^{3#}, Yang Zhou^{4#}, Boxuan Huang², Can Ge¹, Agathe Seguin-Givelet⁵, Ajay Wagh⁶, Yeon Wook Kim^{7,8}, Weicheng Kong⁹, Censong Xu⁹, Hecheng Li³, Jie Zhang²; the NOVEL study group

¹Department of Thoracic Surgery, Putuo People's Hospital, Tongji University, Shanghai, China; ²Department of Thoracic Surgery, Shanghai Chest Hospital, Shanghai Jiaotong University of Medicine, Shanghai, China; ³Department of Thoracic Surgery, Ruijin Hospital, Shanghai Jiaotong University School of Medicine, Shanghai, China; ⁴Purchasing Center, Shanghai Chest Hospital, Shanghai Jiaotong University of Medicine, Shanghai, China; ⁵Thoracic Surgery Department, Institut du Thorax Curie-Montsouris-Institut Mutualiste Montsouris (IMM), Paris, France; ⁶Section of Pulmonary and Critical Care Medicine/Interventional Pulmonology, The University of Chicago, Chicago, IL, USA; ⁷Department of Internal Medicine, Seoul National University College of Medicine, Seoul, Republic of Korea; ⁸Division of Pulmonary and Critical Care Medicine, Department of Internal Medicine, Seoul National University Bundang Hospital, Seongnam, Republic of Korea; ⁹Department of Thoracic Surgery, Putuo District People's Hospital, Zhoushan, China

Contributions: (I) Conception and design: J Zhang, J Xie; (II) Administrative support: J Zhang, C Ge, Y Zhou, W Kong, H Li; (III) Provision of study materials or patients: J Xie, B Huang, C Ge, C Xu, D Han; (IV) Collection and assembly of data: J Xie, B Huang, C Ge, C Xu; (V) Data analysis and interpretation: J Zhang, J Xie; (VI) Manuscript writing: All authors; (VII) Final approval of manuscript: All authors.

[#]These authors contributed equally to this work.

Correspondence to: Jie Zhang, MD, PhD. Department of Thoracic Surgery, Shanghai Chest Hospital, Shanghai Jiaotong University of Medicine, No. 241, Huaihai West Road, Xuhui District, Shanghai 200030, China. Email: zhangjie2289@hotmail.com; Hecheng Li, MD, PhD. Department of Thoracic Surgery, Ruijin Hospital, Shanghai Jiaotong University School of Medicine, 197 Ruijin 2nd Road, Shanghai 200025, China. Email: lihecheng2000@hotmail.com.

Background: The rise of low-dose computed tomography (LDCT) has increased the detection of small pulmonary nodules, demanding more effective localization techniques for their resection. Minimally invasive resection utilizing video-assisted thoracoscopic surgery (VATS) is a critical method for treating these nodules. However, traditional computed tomography (CT)-guided localization has limitations such as invasiveness and patient discomfort. The current gap in knowledge relates to the potential advantages of electromagnetic navigation bronchoscopy (ENB) in reducing complications and improving procedural efficiency. The NOVEL trial evaluates the non-inferiority of ENB-guided labeling against CT-guided puncture for lung nodule localization.

Methods: This multicenter, randomized, controlled, non-inferiority phase III trial includes 156 participants across four Chinese hospitals, randomized to undergo either ENB-guided or CT-guided localization prior to VATS sub-lobar resection. Randomization is performed using sealed opaque envelopes to ensure allocation concealment. Primary outcomes are the procedural success rates and complication rates of both techniques, with secondary outcomes including procedure times and lesion margins.

Discussion: The NOVEL trial aims to provide a detailed comparison of ENB-guided versus CT-guided

[^] ORCID: 0000-0003-1118-8240.

localization for small pulmonary nodules. Establishing the safety and efficacy of the ENB method could significantly influence clinical practices and improve patient outcomes.

Trial Registration: This trial was registered with the Medical Research Registration Platform (<https://www.medicalresearch.org.cn>), registration number MR-31-24-018575.

Keywords: Electromagnetic navigation bronchoscopy (ENB); computed tomography (CT); pulmonary nodules; video-assisted thoracoscopic surgery (VATS); localization

Submitted Jul 23, 2024. Accepted for publication Sep 20, 2024. Published online Oct 17, 2024.

doi: 10.21037/tlcr-24-641

View this article at: <https://dx.doi.org/10.21037/tlcr-24-641>

Introduction

With the increasing utilization of low-dose computed tomography (LDCT) scanning in clinical practice, more isolated small pulmonary nodules are being detected (1). On account of the probability of malignancy, diagnosing and treating pulmonary nodules have become a primary concern for clinicians (2). Video-assisted thoracoscopic surgery (VATS) is essential for diagnosing and treating pulmonary nodules (3). However, it can be difficult to use the VATS procedure to localize deep nonpalpable nodule that lie in the lung parenchyma (4,5).

There are many reported techniques for localizing small pulmonary nodules before lung cancer resection, which can be performed using non-targeted approaches, including intraoperative review of a computed tomography (CT) scan by a surgeon (anatomical localization), or targeted techniques, such as using dye (6), hook-wire (7), and microcoil (8). CT-guided localization techniques are limited by their invasive nature, requiring patients to undergo procedures under local anesthesia within the CT room. After the localization, patients must be transported to the operating room, adding complexity and potential risk to the process. In contrast, electromagnetic navigation bronchoscopy (ENB) localization can be carried out in the operating room under general anesthesia (9). Zhang *et al.* (10) reported that the electromagnetic navigation system has a 100% technical success rate and a 92.9% technical efficacy rate in CT-guided lung biopsies, highlighting its high efficiency and safety in nodule localization. This method reduces patient discomfort by allowing the entire procedure, from localization to surgery, to be performed while the patient is under general anesthesia, eliminating the need for movement between different areas and offering a more streamlined and potentially less stressful experience.

Although some retrospective studies (11-14) have evaluated this technique, there have not been any multicenter randomized controlled studies comparing CT-guided localization with ENB-guided approach. Therefore, this trial intends to further explore the safety and efficacy of ENB-guided lung nodule labeling and CT-guided puncture localization through a prospective, open-labeled, non-inferiority multicenter study to provide new ideas for the development of lung nodule localization techniques.

The NOVEL trial is designed to assess the safety and effectiveness of the ENB-guided localization method for patients with small pulmonary nodules undergoing VATS sub-lobar resection. This will be compared with the traditional CT-guided localization approach. The study's specific goals are: (I) to evaluate and compare the success rates of both ENB and CT-guided techniques; (II) to examine the differences in complication rates between the two methods; (III) to analyze the time required for each localization procedure; and (IV) to assess the accuracy of resection margins in specimens obtained using each technique.

The hypothesis of the NOVEL trial is that the success rate of preoperative localization of pulmonary small lesions using the ENB-guided technique will be non-inferior to that of the CT-guided technique, with fewer complications in the ENB group. This hypothesis is supported by the following considerations (according to previous research): (I) the overall mean success rate of CT-guided hook-wire localization was 0.96 [95% confidence interval (CI): 0.95–0.97] (15); (II) the mean pneumothorax rate associated with hook-wire was 0.35 (95% CI: 0.28–0.43) (15); (III) the mean hemorrhage rate associated with hook-wire was 0.16 (95% CI: 0.11–0.23) (15); (IV) the success rate of the ENB-guided technique varies from 93.3% to 100% (9,11-13,16); (V) in the ENB-guided hook-wire technique, the pneumothorax

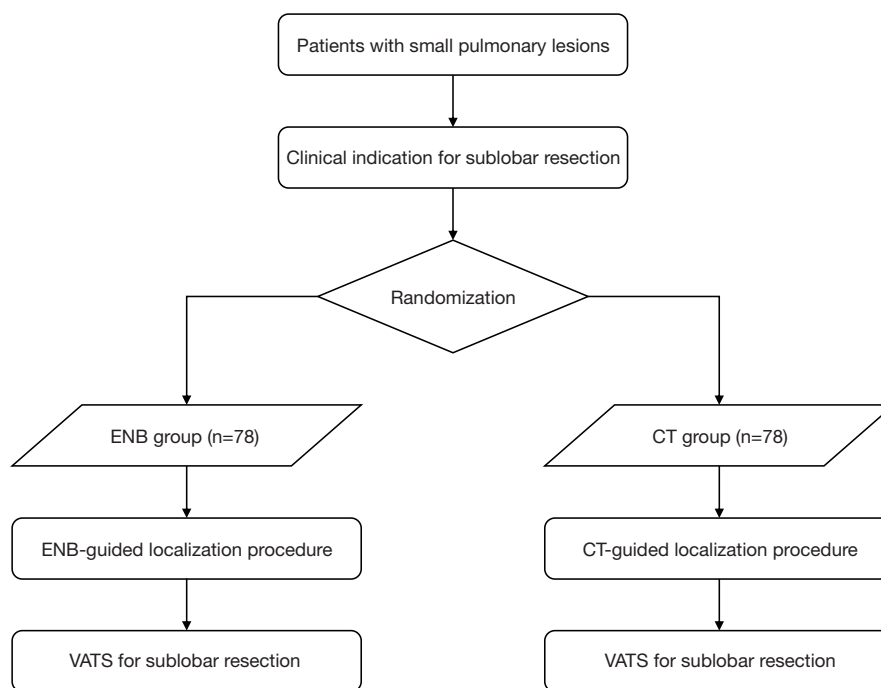


Figure 1 Overall study design of NOVEL trial. ENB, electromagnetic navigation bronchoscopy; CT, computed tomography; VATS, video-assisted thoracoscopic surgery.

rates range is from 0 to 6.7% (13); and (VI) there have been no reports of fatal complications associated with the two techniques. We present this article in accordance with the SPIRIT reporting checklist (available at <https://tldr.amegroups.com/article/view/10.21037/tlcr-24-641/rc>).

Methods

Overall study design

NOVEL is a prospective, multicenter, randomized controlled, non-inferiority phase III trial. It aims to compare the procedure success and complication rates between the ENB-guided and CT-guided localization techniques for individuals undergoing minimally invasive lung surgery for small lung lesions. The primary endpoint is to determine if the ENB-guided technique is non-inferior to the CT-guided approach in terms of procedural success, while also assessing its potential superiority in reducing complications. This trial will be conducted across four selected hospitals in China, with the goal of recruiting 156 participants. The participants will be randomly assigned in a 1:1 ratio to either the ENB-guided group or the CT-guided group, based on the established inclusion criteria. The participating hospitals

are Shanghai Chest Hospital, Shanghai Ruijin Hospital, Shanghai Putuo People's Hospital, and Zhejiang Putuo Hospital. All study participants will undergo preoperative lung localization using either a dye or hook-wire. After the localization procedures, VATS sub-lobar resection will be performed by experienced thoracoscopic surgeons within several hours after the localization (*Figure 1*). The coordinating center will be based at Shanghai Chest Hospital and will be responsible for trial oversight, and coordination between study sites.

Ethical approval was obtained from the Institutional Review Board of Shanghai Chest Hospital (IRB approval date: 20 July 2021 and approval number: IS2177). All participating hospitals/institutes were informed and agreed the study. The study will be conducted in accordance with the Declaration of Helsinki (as revised in 2013), and informed consent will be taken from all individual participants.

Study population

Participants with small pulmonary lesions, indicated for sub-lobar resection via VATS, will undergo screening and

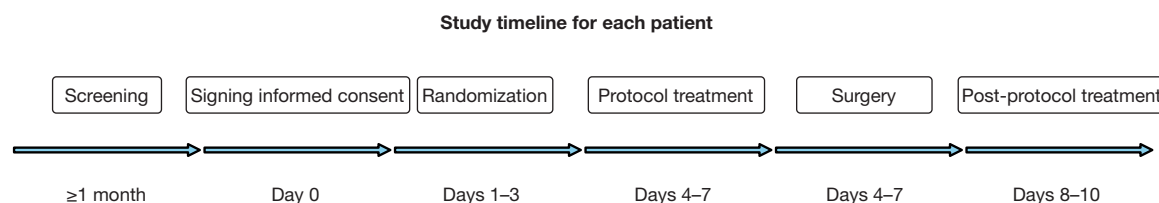


Figure 2 Study timeline for each patient is presented.

enrollment at designated sites based on specific inclusion criteria. All lesions should undergo examination using thin-section CT with a slice thickness of ≤ 3 mm.

The inclusion criteria are as follows:

- (I) Age between 18 and 80 years;
- (II) Pulmonary lesion diameter ranging from 0.5 to 3 cm;
- (III) CT imaging features which include:
 - (i) Pure ground-glass opacity (GGO);
 - (ii) Mixed GGO with over 50% GGO component;
 - (iii) Solid nodule with a diameter of ≤ 1 cm;
- (IV) Lesion persistence or growth observed in a minimum 1-month follow-up;
- (V) Intention for sub-lobar resection via VATS;
- (VI) No contraindications to localization procedures or surgery;
- (VII) Willingness to provide informed consent.

The exclusion criteria are as follows:

- (I) Inability or unwillingness to provide consent;
- (II) History of thoracic surgery;
- (III) Presence of pulmonary alveolus;
- (IV) Unwillingness to cooperate;
- (V) Simultaneous participation in another clinical trial involving investigational drugs or devices;
- (VI) Pregnancy.

Pure GGO is defined as a hazy area in the lung on a CT scan that does not obscure underlying bronchial structures or vascular markings. Mixed GGO is defined as a lesion in the lung that contains areas of GGO along with areas of consolidation or solid components. Solid nodule is defined as a well-defined lesion on a CT scan that completely obscures the lung parenchyma within it. There is no ground-glass appearance; instead, it appears denser.

All study participants will be subjected to study procedures only after providing their informed consent. Informed consent will be executed by the surgeon or trained resident, who will conduct the informed consent in a language the patient can understand. The study timeline for each participant is presented in *Figure 2*.

Randomization

The randomization process utilized the randomizeR (17) package in R language, a well-acknowledged tool for generating random sequences in clinical research. This ensures a truly random assignment. The sequence was generated by a biostatistician who was not involved in the patient recruitment or the intervention procedures.

To prevent selection bias and ensure that the upcoming allocation will not be foreseen, the generated sequence will be kept concealed from the research team until the patient is deemed eligible and has consented to participate. The sequence will be stored in sealed, opaque, and sequentially numbered envelopes.

Once a patient is deemed eligible and has provided informed consent, the next sequentially numbered envelope will be taken. The envelope will be opened to reveal the group assignment: group A (ENB-guided) or group B (CT-guided).

Although it is not possible to blind the medical staff performing the localization procedures due to the nature of the interventions, outcome assessment and data analysis will be conducted by team members blinded to group assignments, ensuring unbiased results.

To account for potential confounding variables, stratification will be incorporated into the randomization. Lesion size, categorized as small (< 2 cm) or large (≥ 2 cm), is the main variable to be considered. This stratified approach guarantees an equitable distribution of these variables across both intervention groups, thereby reinforcing the study's robustness.

Procedures

On the day of surgery, patients will receive preoperative localization for their pulmonary nodule using either the ENB-guided or CT-guided method, based on the randomization results. Following localization, VATS sub-lobar resection will be carried out by skilled thoroscopic

surgeons within a few hours. First, a wedge resection or segmental lung resection will be performed, and the specimen will be sent for intraoperative pathology. The surgeon can then determine the extent of surgical resection based on the pathology results. The follow-up technologist or trained resident will record the localization time, localization method, operation time, operation method, and the shortest distance between the node and the localizer.

ENB-guided localization

The CT scan will be obtained and loaded into the navigation system software (either superDimension™ Navigation System or Veran SPiN Thoracic Navigation System). The radiologist or pulmonologist will map the location and trajectory to the target lesion. A three-dimensional (3D) model of the airways will be created using the CT data. The patient will be brought into the bronchoscopy suite and placed under general anesthesia and intubated. The ENB system will be used to navigate the airways to the target lesion. An electromagnetic field will be generated to track the location of the ENB catheter tip in real-time. Endobronchial markers, primarily Methylene Blue, will be used to mark the pathway to the lesion. Occasionally, indocyanine green (ICG) may be used if a fluorescent scope is available, but the choice of marker is left to the discretion of each participating center based on their clinical practice. The pleura will be marked during the procedure. Once the ENB catheter has reached its target, the endobronchial marker will be deployed near the lesion to aid in guiding the VATS incision. In this trial, the ENB localization procedures are performed by surgeons.

CT-guided localization

CT-guided hook-wire localization will be performed within the CT room using ≥16-slice multidetector CT (MDCT). The hook-wire is composed of a positioning line that is made of flexible material and four hooks on the needle help further stabilize the positioning. A needle puncture site will be selected, and the distance between the puncture site and the center of the lesion will be measured. After sterilization of skin around the puncture site and the administration of local anesthesia, the introducer needle will first puncture then release the localization anchor.

Throughout the procedure, the patient's vital signs, including blood pressure, respiratory rate, and arterial oxygen saturation (SaO₂), will be closely monitored. Potential complications such as pneumothorax, hemorrhage,

and wire dislodgement will also be carefully assessed. If no complications arise, a confirmatory CT scan will be performed to ensure proper positioning of the hook-wire. The external part of the hook-wire will be secured on the skin using gauze dressings before the patient is transferred to the operating room.

VATS

Upon successful preoperative localization of the pulmonary nodule, patients will be promptly transferred to the operating room within 1 hour. The surgery will commence with a wedge resection or segmentectomy as the primary approach. Once the specimen has been excised, it will immediately be subjected to intraoperative frozen section analysis. In instances where invasive adenocarcinoma is identified, the lead surgeon will make a decision, tailored to the patient's specific clinical scenario, on whether to proceed with a lobectomy. Systematic lymph node dissection will be performed for all cases of invasive cancer to ensure comprehensive cancer staging and optimal therapeutic management.

For patients in the ENB group, after the specimen's removal, the assisting surgical staff will record if the marker encapsulated the nodule. In cases where the nodule is not fully covered by the marker, the precise distance between the marker and the nodule will be diligently documented.

Effectiveness and safety evaluation

Study primary endpoints

The primary endpoint for this investigation is the procedure success rate of the respective localization techniques. A successful procedure is characterized as effectively marking the small pulmonary lesion within a 1 cm range, ensuring there is no pleural leakage of the marker or any dislodgement of the hook-wire. The formula for calculating the procedure success rate is as follows: procedure success rate (%) = (number of successful procedures/total number of procedures) × 100%.

These success rates will be meticulously analyzed and juxtaposed both across the entire patient cohort and within specific subgroups. These subgroups will be defined based on several criteria: tumor dimensions, tumor position, nodule type, presence or absence of a "bronchus sign", and individual patient features such as their smoking habits.

Secondary endpoints

Procedure-related complication rate

The complication rate stands for the percentage of

complications that are inextricably linked with the localization process relative to the totality of procedures carried out. Directly-associated complications are those observed during or immediately post-procedure that can be unequivocally attributed to the procedure itself. Examples include, but are not limited to, pneumothorax, hemothorax, hemoptysis, hemorrhage, and air embolism.

Duration of localization procedure

This refers to the time span between the initiation and completion of the localization technique. For patients in the ENB group, procedure termination will be recognized at the moment of bronchoscope removal from the lungs post-marker administration. For those undergoing the hook-wire method, the procedure will conclude upon the successful insertion and anchoring of the hook-wire to the target lesion.

Interim analysis plan

We have planned an interim analysis to be conducted after data collection reaches 100 participants. This interim analysis will provide an opportunity to evaluate the trial's progress, assess safety, and examine preliminary efficacy data. Based on the results of the interim analysis, adjustments to the trial protocol may be considered if necessary to ensure participant safety and the integrity of the study.

Statistical methods

Sample size estimation

Assuming a rate of success of 97% in both localization groups, a noninferiority margin of 7 percentage points, 80% power, and a one-sided alpha level of 0.025 and using the method of Farrington and Manning (18), we assume that 136 patients are required for each group. Under the assumption of a 97% rate of success in both groups, a noninferiority margin of 10 percentage points, a one-sided alpha level of 0.025, and 78 patients for each group, there was 80.4% power to show noninferiority in the intention-to-treat population.

To further elucidate, the success rate of CT-guided localization is already high. The introduction of ENB-guided localization is not aimed at further increasing this success rate, but rather to harness the unique advantages of ENB. Taking into consideration the feasibility of the trial and after consulting experts who weighed various factors, the non-inferiority margin was determined to be set at 10%.

To achieve this target, we have developed a multi-faceted enrollment strategy that leverages both the extensive networks of the participating centers and innovative recruitment methods. Each of the four qualified hospitals has a strong patient base and is well-respected within the community. We will work closely with these centers to utilize their existing patient databases and referral systems to identify potential participants who meet the study criteria.

We will engage with thoracic surgeons, pulmonologists, and radiologists within and outside of the participating hospitals to establish a referral network. Information sessions will be held to inform them about the study and the importance of their referrals.

Primary statistical analysis

To test the non-inferiority of the ENB group's localization success rate in comparison to the CT group, we will employ the Farrington and Manning's likelihood score test. This test will be conducted with an alpha of 0.025 and one-sided. Baseline characteristics between the two groups will be compared using appropriate tests depending on the nature of the data: continuous variables will be assessed using *t*-tests or Mann-Whitney *U* tests, and categorical variables will be assessed using Chi-square or Fisher's exact tests.

Discussion

The NOVEL trial presents a rigorous and well-designed comparison of two techniques for localizing small pulmonary nodules: ENB-guided and CT-guided localizations. As the prevalence of small pulmonary nodules detected through LDCT scanning grows, the necessity for accurate and effective localization methods before lung cancer resection has become increasingly crucial.

VATS is a primary modality for treating pulmonary nodules, yet its applicability is limited when localizing certain nodules and the process is challenging. Although several techniques exist to assist in preoperative nodule localization, their use remains controversial due to variations in advantages, drawbacks, and their clinical efficacy. This trial aims to shed light on this gap in knowledge, especially since no multicenter randomized controlled studies have compared CT-guided localization with the ENB-guided approach.

The primary goal of the trial is to assess the efficacy and safety of the ENB-guided technique compared to

the traditional CT-guided technique. The overarching hypothesis posits that the ENB technique will be non-inferior in terms of procedure success rate but might lead to reduced complications.

Notably, CT-guided localization has been historically recognized for its high success rate. The introduction of the ENB-guided technique does not necessarily aim to surpass this rate, but to offer potential advantages like lower complication rates. Ma *et al.* (19) found that CT-guided localization poses several challenges, such as pneumothorax and marker displacement, emphasizing the necessity of exploring ENB as an alternative. Xia *et al.* (20) demonstrated that ENB significantly reduces complications and shortens procedure times, particularly in minimizing risks of pneumothorax and hemorrhage. The trial's data around complication rates, such as pneumothorax and hemorrhage, seem promising for the ENB-guided technique, highlighting its potential to be a safer alternative.

The strength of the NOVEL trial lies in its robust methodology. A randomized, controlled, non-inferiority trial design ensures that bias is minimized and that a direct comparison of the two techniques is achieved. Stratification during randomization, based on lesion size, further bolsters the credibility of the results, accounting for a significant confounding variable.

Moreover, the clear definition of success rates and complications, along with well-structured inclusion and exclusion criteria, facilitates the accumulation of a homogeneous cohort, ensuring that the results are consistent and generalizable.

The findings from the NOVEL trial are expected to have significant clinical implications. If the ENB-guided technique is shown to be non-inferior or even superior in specific outcomes, it may facilitate it becoming a preferred method of localization, particularly in cases where there is apprehension about complications.

The data from this trial will also serve as a foundation for further research, potentially delving into specific subgroups or nuanced clinical scenarios to tailor nodule localization techniques better.

Furthermore, although the study focuses primarily on the technical aspects of localization, future research could also consider the patients' perspective, assessing their experiences, pain levels, and overall satisfaction with the procedure.

Despite the robustness of the trial's design, potential limitations may arise. The non-inferiority margin set at

10% might be considered wide, possibly affecting the interpretation of the results. A narrower margin might provide a more definitive indication of the true differences between the techniques.

Additionally, the trial focuses on short-term technical success and complications. Long-term outcomes, such as the impact on overall survival or recurrence rates, would provide a more comprehensive understanding of the techniques' effectiveness.

Acknowledgments

The NOVEL trial group thanks all the patients and medical staff participating in this study.

Funding: This work was supported by the Science and Technology Commission of Shanghai Municipality (No. 21Y31900104), the Industry-University-Research Projects of Shanghai University Teachers (No. RC.202111.001), the Scientific Research Project of Traditional Chinese Medicine of Shanghai Municipal Health Commission (No. 2020LZ004), the Collaborative Innovation Center for Clinical and Translational Science by Chinese Ministry of Education & Shanghai (No. CCTS-2022209), and the Technology Transfer Promotion Program of Shanghai Jiaotong University (No. ZT202113).

Footnote

Reporting Checklist: The authors have completed the SPIRIT reporting checklist. Available at <https://tlcr.amegroups.com/article/view/10.21037/tlcr-24-641/rc>

Peer Review File: Available at <https://tlcr.amegroups.com/article/view/10.21037/tlcr-24-641/prf>

Conflicts of Interest: All authors have completed the ICMJE uniform disclosure form (available at <https://tlcr.amegroups.com/article/view/10.21037/tlcr-24-641/coif>). A.W. has done some consulting work for Noah Medical, Ambu, and Medtronic; speaks for Biodesix; and has also done some medicolegal work in the area of lung nodules. The other authors have no conflicts of interest to declare.

Ethical Statement: The authors are accountable for all aspects of the work in ensuring that questions related to the accuracy or integrity of any part of the work are appropriately investigated and resolved. Ethical approval was obtained from the Institutional Review Board of

Shanghai Chest Hospital (IRB approval date: 20 July 2021 and approval number: IS2177). All participating hospitals/institutes were informed and agreed the study. The study will be conducted in accordance with the Declaration of Helsinki (as revised in 2013), and informed consent will be taken from all individual participants.

Open Access Statement: This is an Open Access article distributed in accordance with the Creative Commons Attribution-NonCommercial-NoDerivs 4.0 International License (CC BY-NC-ND 4.0), which permits the non-commercial replication and distribution of the article with the strict proviso that no changes or edits are made and the original work is properly cited (including links to both the formal publication through the relevant DOI and the license). See: <https://creativecommons.org/licenses/by-nc-nd/4.0/>.

References

- Jonas DE, Reuland DS, Reddy SM, et al. Screening for Lung Cancer With Low-Dose Computed Tomography: Updated Evidence Report and Systematic Review for the US Preventive Services Task Force. *JAMA* 2021;325:971-87.
- Mazzone PJ, Lam L. Evaluating the Patient With a Pulmonary Nodule: A Review. *JAMA* 2022;327:264-73.
- Chow SC, Ng CS. Recent developments in video-assisted thoracoscopic surgery for pulmonary nodule management. *J Thorac Dis* 2016;8:S509-16.
- Davini F, Ricciardi S, Zirafa CC, et al. Treatment of pulmonary nodule: from VATS to RATS. *J Vis Surg* 2018;4:36.
- Liu B, Gu C. Expert consensus workshop report: Guidelines for preoperative assisted localization of small pulmonary nodules. *J Cancer Res Ther* 2020;16:967-73.
- Tsai TM, Hung WT, Lin MW, et al. Computed tomography-guided dye localization prior to uniportal thoracoscopic surgery for lung nodules: A propensity score matching analysis. *J Formos Med Assoc* 2019;118:783-9.
- Klinkenberg TJ, Dinjens L, Wolf RFE, et al. CT-guided percutaneous hookwire localization increases the efficacy and safety of VATS for pulmonary nodules. *J Surg Oncol* 2017;115:898-904.
- Refai M, Andolfi M, Barbisan F, et al. Computed tomography-guided microcoil placement for localizing small pulmonary nodules before uniportal video-assisted thoracoscopic resection. *Radiol Med* 2020;125:24-30.
- Jeong JH, Park H, Choi CM, et al. Preoperative electromagnetic navigation bronchoscopy-guided one-stage multiple-dye localization for resection of subsolid nodules: A single-center pilot study. *Thorac Cancer* 2022;13:466-73.
- Zhang Y, Huang H, Cao S, et al. Clinical value of an electromagnetic navigation system for CT-guided percutaneous lung biopsy of peripheral lung lesions. *J Thorac Dis* 2021;13:4885-93.
- Tian Y, Wang C, Yue W, et al. Comparison of computed tomographic imaging-guided hook wire localization and electromagnetic navigation bronchoscope localization in the resection of pulmonary nodules: a retrospective cohort study. *Sci Rep* 2020;10:21459.
- Mariolo AV, Vieira T, Stern JB, et al. Electromagnetic navigation bronchoscopy localization of lung nodules for thoracoscopic resection. *J Thorac Dis* 2021;13:4371-7.
- Kuo SW, Tseng YF, Dai KY, et al. Electromagnetic Navigation Bronchoscopy Localization Versus Percutaneous CT-Guided Localization for Lung Resection via Video-Assisted Thoracoscopic Surgery: A Propensity-Matched Study. *J Clin Med* 2019;8:379.
- Chaudry FA, Thivierge-Southidara M, Molina JC, et al. CT-Guided vs. Navigational Bronchoscopic Biopsies for Solitary Pulmonary Nodules: A Single-Institution Retrospective Comparison. *Cancers (Basel)* 2023;15:5258.
- Park CH, Han K, Hur J, et al. Comparative Effectiveness and Safety of Preoperative Lung Localization for Pulmonary Nodules: A Systematic Review and Meta-analysis. *Chest* 2017;151:316-28.
- Bowling MR, Folch EE, Khandhar SJ, et al. Pleural dye marking of lung nodules by electromagnetic navigation bronchoscopy. *Clin Respir J* 2019;13:700-7.
- Uschner D, Schindler D, Hilgers RD, et al. randomizeR: an R package for the assessment and implementation of randomization in clinical trials. *J Stat Softw* 2018;85:1-22.
- Farrington CP, Manning G. Test statistics and sample size formulae for comparative binomial trials with null hypothesis of non-zero risk difference or non-unity relative risk. *Stat Med* 1990;9:1447-54.
- Ma Y, Cheng S, Li J, et al. Preoperative CT-guided localization of pulmonary nodules with low-dose radiation. *Quant Imaging Med Surg* 2023;13:4295-304.

20. Xia T, Li Y, Shen Z, et al. Comparison of safety and anxiety/depression in computed tomography-guided hook-wire localization versus electromagnetic navigation bronchoscopy-guided localization: a retrospective cohort

study. *J Thorac Dis* 2024;16:401-13.

(English Language Editor: J. Jones)

Cite this article as: Xie J, Han D, Zhou Y, Huang B, Ge C, Seguin-Givelet A, Wagh A, Kim YW, Kong W, Xu C, Li H, Zhang J; the NOVEL study group. Navigation of video-assisted thoracoscopic surgery using electromagnetic versus CT-guided localization (NOVEL): a study protocol for comparing procedural success and complication rates in a prospective, multicenter, randomized controlled, non-inferiority phase III trial. *Transl Lung Cancer Res* 2024;13(10):2838-2846. doi: 10.21037/tlcr-24-641