



Perivesicular Abscess Drainage with Lumen-Apposing Self-Expanding Metal Stents

Gabriel Melki ^{1,*}, Abdalla Mohamed ¹, Yana Cavanagh ¹, Walid Baddoura ¹,
Matthew Grossman ¹

1. Department of Medicine, St. Joseph's University Medical Center, Paterson NJ, USA

ABSTRACT

Abdominal and pelvic abscesses can occur due to a number of reasons, the most common being surgery. They are associated with significant morbidity and mortality. The treatment approach for these types of collections is often the initiation of broad-spectrum antibiotics, accompanied by drainage. Multiple diagnostic and therapeutic modalities have been described, including; percutaneous, transvaginal, endoscopic, and surgical drainage. Due to the complexity of pelvic anatomy, minimally invasive approaches such as percutaneous drainage are usually difficult. Pelvic abscesses have been historically drained through surgery. Endoscopic ultrasound (EUS)-guided interventions have emerged as an alternative for the management of difficult abdominal and pelvic abscesses. Endoscopic interventions have classically included diagnostic and therapeutic aspiration, utilizing drainage catheters with or without placement of plastic stents. More recently, the use of lumen apposing self-expanding metal stents has become a treatment option for deep pelvic abscesses. Lumen apposing metal stents (LAMS) have a saddle-shaped design with two large-diameter flanges on both ends of the stent to anchor the stent edges within the respective lumens as well as a central waist that allows for communication between the two lumens. LAMS were originally designed for transmural pancreatic fluid collection drainage; however, they have been successfully implemented for numerous other off-label uses, including the drainage of pelvic and abdominal abscesses. We present the case of a 34-year-old woman who presented with a septated abscess located between the urinary bladder and the rectum, which was successfully and definitively drained with LAMS.

KEYWORDS:

Perivesicular Abscess, Axios Stent, Lumen-apposing self-expanding metal stents

Please cite this paper as:

Melki G, Mohamed A, Cavanagh Y, Baddoura W, Grossman M. Perivesicular Abscess Drainage with Lumen-Apposing Self-Expanding Metal Stents. *Middle East J Dig Dis* 2020;12:206-210. doi: 10.34172/mejdd.2020.183.

INTRODUCTION

The use of a lumen apposing metal stents (LAMS) was first reported by Binmoeller and Shah in 2011.¹ The AXIOS lumen-apposing stent was the first of its kind and was indicated for endoscopic drainage of symptomatic pancreatic pseudocysts and walled-off necrosis.² To date, numerous studies have focused on the efficacy, safety, and complications of the LAMS. In a retrospective study by Itoi and colleagues, 15 patients with symptomatic pancreatic pseudocysts underwent successful LAMS placement without complication. All pseudocysts resolved after a single drainage procedure with a median time to LAMS removal of 35 days.³

* Corresponding Author:

Ramazan Sari, MD
Orhantepe mah. Guzelbahce sk. No: 10/A
Kartal, Istanbul, Turkey
Tel: +1 973 7542439
Fax: +1 973 7543376
Email: gabriel.melki@mail.mcgill.ca

Received: 10 Jan. 2020
Accepted: 28 Apr 2020



© 2020 The Author(s). This work is published by Middle East Journal of Digestive Diseases as an open access article distributed under the terms of the Creative Commons Attribution License (<https://creativecommons.org/licenses/by-nc/4.0/>). Non-commercial uses of the work are permitted, provided the original work is properly cited.

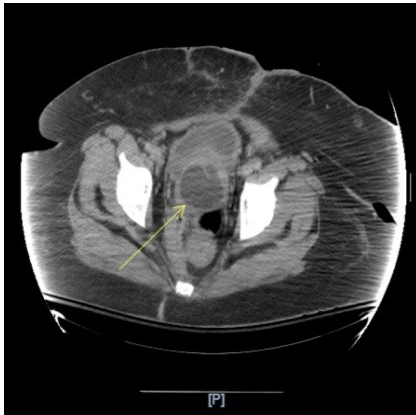


Fig.1: Computed tomogram revealing multiple complex pelvic abscesses. The largest is located between the rectum and the urinary bladder, measuring 5.8 × 4.2 cm.

There was no pseudocyst recurrence during the 11.4-month median follow-up period, and no recurrences of symptoms were observed during a median follow-up period of 9 months.³ Since then, multiple studies have been conducted with similar efficacy. LAMS are also being used off label in the drainage of abdominal, rectal, and pelvic abscesses with increasing frequency.^{4,5,6} Javed and co-workers reported successful drainage of a perirectal abscess using a LAMS. Manvar and others suggest that the use of LAMS is more effective than either endoscopic ultrasound (EUS) drainage with catheters or plastic stents.^{4,5} Lopez-Fernandez and colleagues reported that their use of LAMS EUS-guided drainage of three cases of postsurgical pelvic abscess resulted in a complete resolution of symptoms at 6-9 months follow-up.⁶

CASE REPORT

A 34-year-old woman with a medical history of uncontrolled insulin-dependent diabetes mellitus, hypertension, morbid obesity, and ovarian cysts presented with acute bilateral flank pain as well as lower abdominal pain. She denied any changes in her bowel or bladder function with no underlying constitutional symptoms. Upon examination, she was in mild distress secondary to pain. Tenderness was elicited to palpation in the bilateral lower quadrants. There was no guarding, rebound tenderness, or rigidity. The rectal exam revealed

guaiac negative stool, and her vital signs were unremarkable. Her initial laboratory findings were consistent with microcytic anemia (hemoglobin 7.8 g/dL, hematocrit of 23.8%, and a mean corpuscular volume of 75.8u3) and acute kidney injury evidenced by a creatinine of 1.87 mg/dL and a blood urea nitrogen (BUN) of 27 mg/dL. Iron studies revealed the presence of underlying iron deficiency anemia (IDA) with an iron level of 17 ug/dL and iron saturation of 6%.

A computed tomography (CT) of the abdomen and pelvis was obtained, which revealed severe bilateral hydronephrosis extending to the level of a complex mass in the pelvis. The mass was located near the uterus and involved the right adnexal region, measuring approximately 12.2 × 9.3 cm. There was a significant mass effect on the urinary bladder displacing it anteriorly. An additional cystic structure measuring approximately 6.5 × 6.0 cm was also seen superior to the prior mass, and this was thought to represent an infectious process.

Bilateral percutaneous nephrostomy tubes were placed, and the patient underwent exploratory laparotomy for further evaluation. Extensive intra-abdominal and pelvic adhesions were encountered intra-operatively. Significant dissection was necessary to access the desired planes and gain access to the patient's pelvis; however, no discrete mass was identified. Cytological evaluation of the biopsy sample of the region correlating to the radiographically described "mass" was negative for dysplasia or malignancy. The pelvic cyst seen on CT was identified and surgically debrided. A Jackson-Pratt (JP) drain was placed for continued drainage.

On postoperative day 5, the patient began developing fecopurulent drainage in the JP drain. The culture of the fluid grew *Enterococcus faecium*, and subsequently, intravenous (IV) formulations of meropenem and levofloxacin were started for the patient. She underwent repeat CT, which revealed multiple complex pelvic abscesses. The largest was located between the rectum and the urinary bladder, measuring 5.8 × 4.2 cm (figure 1). Interventional radiology was unable to access the collection, and therefore, advanced and therapeutic gastroenterology/interventional gastroenterology was consulted for transrectal drainage.

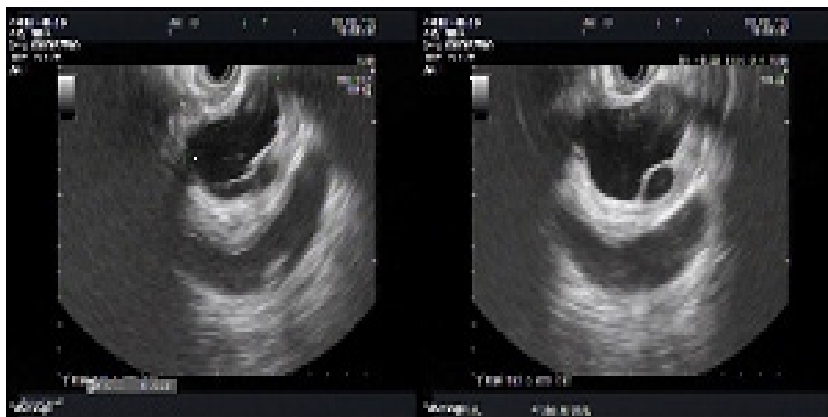

Fig.2: Rectal EUS revealed a 6.3 cm fluid collection. The collection appeared septated and did not communicate with the bladder. A 2 cm margin was observed between the abscess and the urinary bladder.

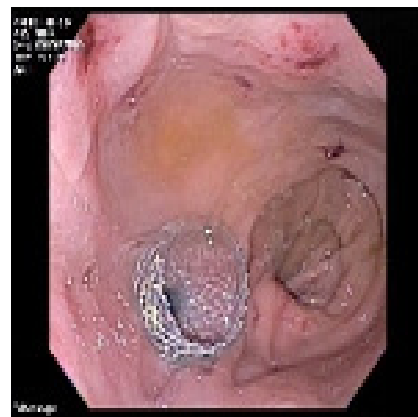


Fig.3: Endoscopic image revealing the successful placement of Axios stent (LAMS) between the fluid collection and rectum.

Rectal EUS was performed, which revealed a 6.3 cm fluid collection that coincided with the largest pelvic abscess, previously seen on cross-sectional imaging. The collection appeared septated and did not communicate with the bladder. A 2-cm margin was observed between the abscess and the urinary bladder (figure 2). Considering this favorable anatomic location, a 19-gauge non-coring needle was initially used to access the fluid collection and obtain a diagnostic specimen. The aspirated fluid was grossly purulent and was sent for culture. A long endoscopic guidewire was passed through the needle and coiled within the collection. The needle was then withdrawn to allow for exchange with the AXIOS LAMS introduction catheter and deployment device. The lumen apposing stent was advanced over the guidewire to the rectal mucosa. Electrocautery was implemented to advance the catheter transmurally and into the peri-vesicular fluid collection. The LAMS was subsequently deployed in accordance with the conventional EUS-guided deployment protocol (figure 3). LAMS placement allowed for direct communication between the purulent collection and the rectum, with spontaneous and successful drainage (figures 4 and 5). 9 days after LAMS (AXIOS lumen-apposing stent, Xlumena Inc., Mountain View, California, USA) placement, the stent was removed via endoscopy. The defect was clipped closed with a 15-mm over the scope clip (Over The Scope Clip, OTSC, Ovesco Endoscopy GmbH, Turbingen, Germany) (figures 6 and 7). Culture

of the fluid aspirated prior to LAMS placement grew *Enterococcus faecium* and *Bacteroides ovatus*. As a result, daptomycin was added to the patient's antibiotic coverage. The patient received 7 days of IV antibiotics, including daptomycin, levofloxacin, and meropenem. The patient experienced complete resolution of the intervened upon pelvic collection during her hospital course and was discharged with close outpatient follow-up. At an interval of 17 months after initial intervention with LAMS, she has not had any recurrent symptoms and has not required repeat endoscopic procedures.

DISCUSSION

Pelvic collections are difficult to manage with conventional approaches due to their inherently complicated anatomic locations. The advent of endoscopically placed LAMS, performed under EUS guidance, offers a practical therapeutic advantage to this management dilemma. LAMS allow for safe, minimally invasive internal drainage of troublesome collections located within the deep pelvis. Manvarand colleagues are among a number of authors who suggest that EUS-guided LAMS drainage of pelvic abscesses has a favorable safety profile and is more efficacious when compared with EUS-guided drainage with catheters and plastic stents.⁵ Our case demonstrated the applicability of a novel, off-label use of a lumen-apposing self-expanding metal stent. Although more clinical evidence is needed to be able to recommend this off-label use, we conclude that this modality can be considered as a viable option when alternate modalities are unsuccessful

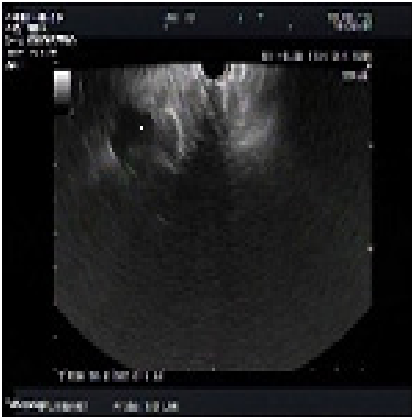

Fig.4: Endoscopic ultrasound image revealing the successful placement of Axios stent (LAMS) between the fluid collection and rectum.

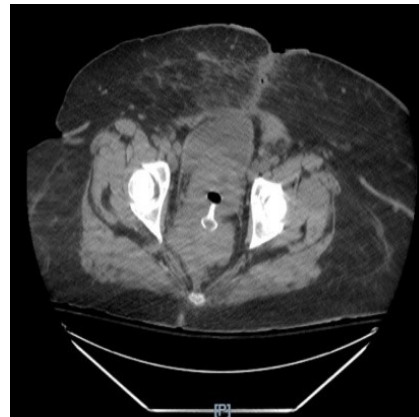


Fig.5: Abdominopelvic computed tomogram showing AXIOS stent in place between fluid collection and rectum.

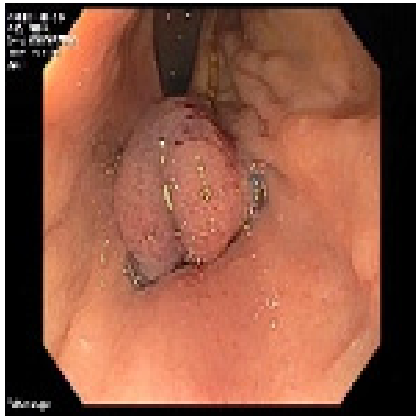


Fig.6: Endoscopic image of the fistulous tract after being clipped.

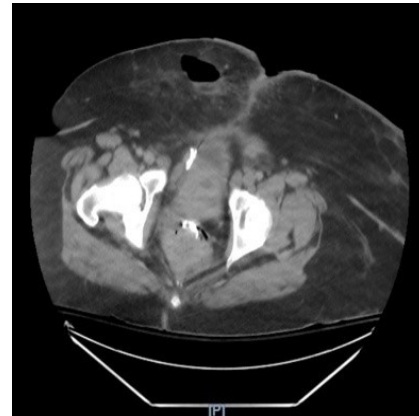


Fig.7: Abdominopelvic computed tomogram after AXIOS stent removal and clip placement.

or technically not possible. With further investigation and mounting evidence, we believe that minimally invasive, internalized drainage options will become the gold standard and the preferred initial treatment modality for collections located in the abdomen and pelvis.

ACKNOWLEDGMENT

We thank Dr. Patrick Michael (Program Director of the Internal Medicine Residency), Dr. Michael Agnelli (Associate Program Director of the Internal Medicine Residency), Dr. Monisha Singhal (Associate Program Director of the Internal Medicine Residency) and Dr. Robert Lahita (Chairman of the Department of Medicine) for their continuous support and guidance.

Financial Disclosure or Funding

No funding was provided to any of the authors.

Informed Consent:

Informed consent was obtained from the patient for this case report.

Author contributions:

All authors contributed to the revision and approval of the manuscript.

ETHICAL APPROVAL

There is nothing to be declared.

CONFLICT OF INTEREST

The authors declare no conflict of interest related to this work.

REFERENCES

1. Binmoeller KF, Shah J. A novel lumen-apposing stent for transluminal drainage of nonadherent extraintestinal fluid collections. *Endoscopy* 2011;**43**:337–42.
2. Bank JS, Adler DG. Lumen apposing metal stents: A review of current uses and outcomes. *Gastrointestinal Intervention* 2017;**6**:9-14. <https://doi.org/10.18528/gii160033>
3. Itoi T, Binmoeller KF, Shah J, Sofuni A, Fumihide Itokawa, Toshio Kurihara, et al. Clinical evaluation of a novel lumen-apposing metal stent for endosonography-guided pancreatic pseudocyst and gallbladder drainage (with videos) *Gastrointest Endosc* 2012;**75**:870–6
4. Javed S, Ho S. Endoscopic ultrasound guided perirectal abscess drainage using a novel lumen-apposing covered metal stent. *Am J Gastroenterol* 2016;**111**:1381.
5. Manvar A, Karia K, Ho S. Endoscopic ultrasound-guided drainage of pelvic abscess with lumen-apposing metal stents. *Endosc Ultrasound* 2017;**10**:4103.
6. LópezFernández E, Ruiz Zorrilla R, CuriesesLuengo M, ÁlvarezÁlvarez A, de la Coba Ortiz C. EUS-guided drainage of postsurgical pelvic abscesses using lumen-apposing metal stents. *Rev Esp Enferm Dig* 2019;**111**:566–8. doi:10.17235/reed.2019.6162/2019