

Middle Meningeal Artery Embolization Following Burr Hole in Chronic Subdural Hematoma

Abstract

Chronic subdural hematoma (CSDH) is a condition in which blood accumulates within the subdural space and may cause neurologic deficits. CSDH patients with neurologic deficits usually will undergo surgery, but reoccurrence is common. Middle meningeal artery (MMA) embolization has been proposed as one of the CSDH treatment options, either being used as a single treatment for the neurologically stable patients or certain conditions that may not allow patients to undergo surgery, or as a perioperative treatment. The authors reported a CSDH case with neurologic deficits who was on antiplatelet treatment that underwent both burr hole and MMA embolization for curation and prevention of rebleeding. The result showed near-complete blood resorption and no neurologic deficits.

Keywords: Burr hole, chronic subdural hematoma, middle meningeal artery embolization, minimally invasive

**Abrar Arham,
Nadya Zaragita**

*Department of Neurosurgery,
National Brain Center, Jakarta,
Indonesia*

Introduction

Chronic subdural hematoma (CSDH) is a pathological condition in which blood accumulates within the subdural space. Recurrence is common after surgical interventions, especially when patients present with comorbidities. Besides recurrences, surgical failures such as rebleeding and insufficient drainage in this condition have also been reported. Middle meningeal artery (MMA) embolization has been proposed as one of the effective modalities in treating and preventing the recurrence of CSDH.^[1] This study reported a case of CSDH who was treated with burr hole (BH) with drainage placement for clot removal followed by embolization of MMA. During follow-up, the patient showed no neurological deficit, and bleeding did not reoccur. MMA embolization can be considered as an adjunct in CSDH presenting with neurological deficits to prevent the reoccurrence.

Case Report

A 69-year-old female presented to the emergency department with a complaint of weakness of her right side of the body for the past 2 days, accompanied with the

inability to speak. She had a history of stroke and routinely took clopidogrel once daily. The patient had no history of trauma before this complaint. One day before the admission, she was taken to another hospital and had her computed tomography (CT) scan, which result was chronic subdural hemorrhage at the left frontotemporoparietal (170 cc) with a thickness of 3.1 cm and 9.8 mm subfalcine herniation [Figure 1].

Laboratory examination showed normal activated partial thromboplastin time and prothrombin time level; however, thrombocyte aggregation test was not performed due to the unavailability in the center.

Results

The patient then underwent BH after clopidogrel was discontinued for 5 days. During hospital stay, tranexamic acid was given for 3 days, but atorvastatin was not given. Two burr holes were made, and a drain was placed. Intraoperatively, bleeding was within the acceptable level. CT scan was repeated 24 h after surgery, showing slight pneumocephalus and a decrease of fluid collection within the subdural space. The patient had no neurologic deficit after the surgical

Address for correspondence:
Dr. Abrar Arham,
Department of Neurosurgery,
National Brain Center,
MT Haryono Kav. 11,
South Jakarta 13650, Indonesia.
E-mail: drabrar_arham@yahoo.com

This is an open access journal, and articles are distributed under the terms of the Creative Commons Attribution-NonCommercial-ShareAlike 4.0 License, which allows others to remix, tweak, and build upon the work non-commercially, as long as appropriate credit is given and the new creations are licensed under the identical terms.

For reprints contact: reprints@medknow.com

How to cite this article: Arham A, Zaragita N. Middle meningeal artery embolization following burr hole in chronic subdural hematoma. *Asian J Neurosurg* 2020;15:382-4.

Submitted: 15-Jan-2020 **Revised:** 08-Feb-2020
Accepted: 11 March 2020 **Published:** 29-May-2020

Access this article online

Website: www.asianjns.org

DOI: 10.4103/ajns.AJNS_15_20

Quick Response Code:



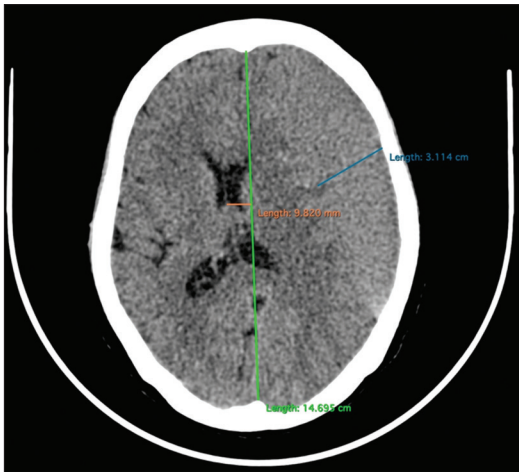


Figure 1: Computed tomography scan during the 1st day of hospital admission in National Brain Center. Chronic subdural hematoma thickness was 3.1 cm with a 9.8-mm midline shift

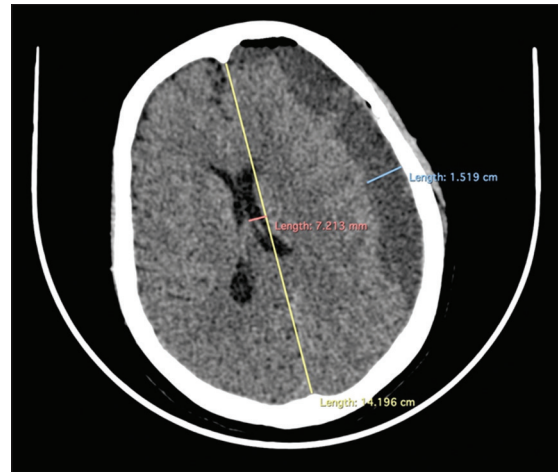


Figure 2: Computed tomography scan after burr hole and drainage. Chronic subdural hematoma thickness was 1.5 cm with a 7.2-mm midline shift

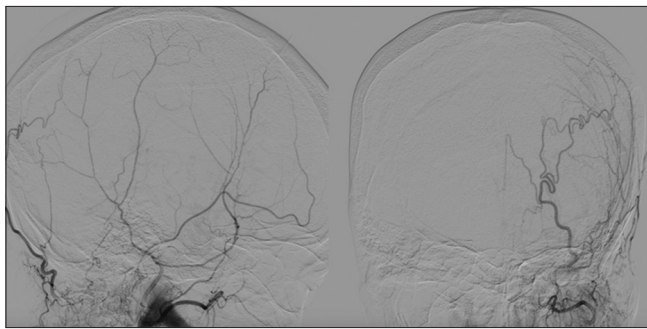


Figure 3: Before embolization

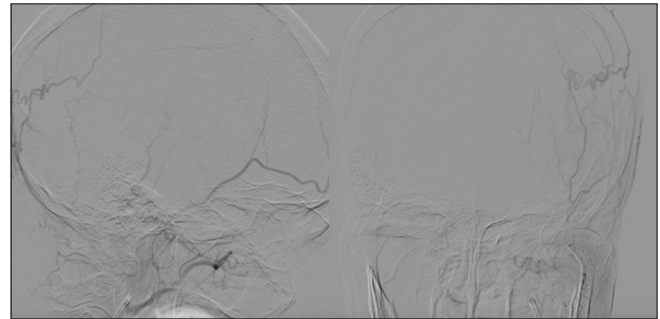


Figure 4: After embolization

procedure, but CT scan showed a 7.2-mm midline shift and a 1.5-cm thick hematoma [Figure 2].

MMA embolization was then performed to prevent the possibility of CSDH recurrence. Polyvinyl alcohol (PVA) was used as the embolizing agent due to its cost availability and the particle size. During the procedure, the patient was lightly sedated for comfort. Guiding catheter with a size of 6f and microcatheter with a size of 1.7f were used. The catheter was inserted from the right femoral artery, aimed to the left MMA. PVA with a size of 250 μ was injected to occlude the frontal branches of MMA. MMA was still visible during the DSA [Figure 3]. PVA embolization occluded frontal and parietal branches [Figure 4].

The patient came to the clinic after 1 week of hospital discharge without any complaints. CT scan was done during a 1-month follow-up and showed near-complete resorption of CSDH [Figure 5].

Discussion

CSDH is a pathological condition that in general is caused by the imbalance of fluid production within the subdural space and resorption. A traumatic event made a small portion (21%) of all CSDH cases, in which tearing of bridging vein is involved. More recent studies showed that

any continuous inflammatory processes within the subdural cavity lead to persistent fluid collection that may not be compensated with the same rate of fluid resorption. Broken fragile neovascularization within the dural wall has been believed to be responsible in most CSDH cases. When new vascularization is broken, more inflammatory mediators are released, including angiogenic factors, promoting further neovascularization. This process becomes a loop that may not be followed by the same speed of resorption.^[2,3]

Treatments of CSDH include medications and procedural. Medications that have been popularly used are tranexamic acid, atorvastatin, and also dexamethasone. Atorvastatin was proven to be effective in reducing hematoma volume, improving the neurological status of the patient, and considered safe.^[4,5] Despite studies that showed a good efficacy of atorvastatin therapy in CSDH, it has not been set as a mainstay therapy for CSDH in our center.

Surgical procedures for blood evacuation have been the mainstay procedure for CSDH patients presenting with neurological deficits. Surgical techniques to treat this condition include twist-drill craniostomy and BH, followed by drainage, and both procedures showed no significant difference of clinical outcomes.^[6] However, after surgical treatments, reoccurrence of CSDH is usual (2%–37%) and often requires immediate reoperation.^[2] Recurrence is

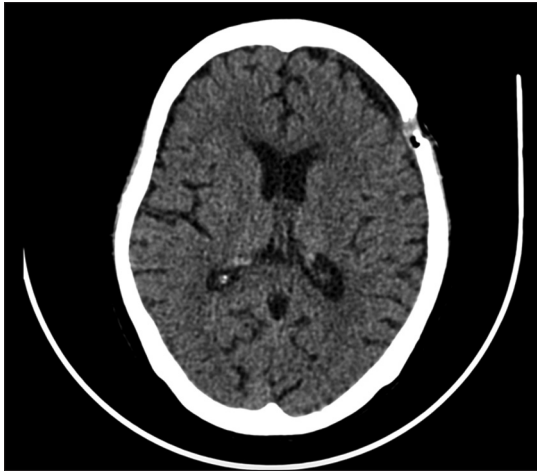


Figure 5: Computed tomography scan during the 1-month follow-up. Bone defect could be seen. Hematoma decreased to minimum level

defined as an increase of hematoma thickness and change in hematoma density. Factors that are commonly linked to recurrence include advanced age, coagulopathy, hypertension, diabetes mellitus, brain atrophy, bilateral CSDH, arachnoid cyst, cerebrovascular disease, and tumor.^[7]

MMA embolization is a procedure believed to be able to prevent further bleeding or fluid collection; thus, the resorption can take place and gradually fluid decreases. This procedure can take place as a single treatment or as an adjuvant for surgical procedures in CSDH cases.^[2] It has been considered as a safe single treatment for neurologically stable patients with a low rate of recurrence. Data showed that MMA embolization performed perioperatively was more successful compared to the conventional treatments only. Recurrence has been reported to be low in cases where perioperative MMA embolization was done.^[1,8] Meta-analysis showed that the reoccurrence rate was as low as 2.1% compared to the conventional treatment which was 27.7%.^[8] Rescue surgical procedure was also significantly lower in the group who underwent MMA embolization compared to the group which underwent conventional treatment.^[1]

Besides the low recurrence, MMA embolization can be considered as a less invasive treatment option, especially in CSDH patients who are at great risk of surgical procedures, since the disease itself often occur in population of older age and/or accompanied with various morbidities.^[2,9] CSDH patients who are under antiplatelet and anticoagulant therapy are more preferable to undergo MMA embolization due to the risk of rebleeding and reoccurrence.^[8]

Possible troubles that can be encountered during the embolization are that since CSDH occurs more often in older age group, MMA diameter tends to be very small. Microcatheters are often larger than the diameter of the targeted blood vessel itself, and it is likely that the embolizing agent amount to be injected is little.^[10] PVA was considered to be superior compared to other embolizing agents due to its ability to travel distally and widely to

prevent collateralization.^[2] However, it is important to be cautious during embolizing agent injection because of the collateral branches to the orbit.^[9] Although treatment is considered promising, it has not been set as a routine mainstay treatment for CSDH. In addition, embolization itself is not covered by Indonesia's national health coverage, and thus, not all CSDH patients can afford this treatment despite being a suitable candidate.

Declaration of patient consent

The authors certify that they have obtained all appropriate patient consent forms. In the form the patient(s) has/have given his/her/their consent for his/her/their images and other clinical information to be reported in the journal. The patients understand that their names and initials will not be published and due efforts will be made to conceal their identity, but anonymity cannot be guaranteed.

Financial support and sponsorship

Nil.

Conflicts of interest

There are no conflicts of interest.

References

- Ban SP, Hwang G, Byoun HS, Kim T, Lee SU, Bang JS, *et al.* Middle meningeal artery embolization for chronic subdural hematoma. *Radiology* 2018;286:992-9.
- Link TW, Boddu S, Paine SM, Kamel H, Knopman J. Middle meningeal artery embolization for chronic subdural hematoma: A series of 60 cases. *Neurosurgery* 2019;85:801-7.
- Edlmann E, Giorgi-Coll S, Whitfield PC, Carpenter KL, Hutchinson PJ. Pathophysiology of chronic subdural haematoma: Inflammation, angiogenesis and implications for pharmacotherapy. *J Neuroinflammation* 2017;14:108.
- Jiang R, Zhao S, Wang R, Feng H, Zhang J, Li X, *et al.* Safety and efficacy of atorvastatin for chronic subdural hematoma in Chinese patients: A randomized clinical trial. *JAMA Neurol* 2018;75:1338-46.
- Qiu S, Zhuo W, Sun C, Su Z, Yan A, Shen L. Effects of atorvastatin on chronic subdural hematoma: A systematic review. *Medicine (Baltimore)* 2017;96:e7290.
- Thavara BD, Kidangan GS, Rajagopalawarrier B. Comparative study of single burr-hole craniostomy versus twist-drill craniostomy in patients with chronic subdural hematoma. *Asian J Neurosurg* 2019;14:513-21.
- Jung YG, Jung NY, Kim E. Independent predictors for recurrence of chronic subdural hematoma. *J Korean Neurosurg Soc* 2015;57:266-70.
- Srivatsan A, Mohanty A, Nascimento FA, Hafeez MU, Srinivasan VM, Thomas A, *et al.* Middle meningeal artery embolization for chronic subdural hematoma: Meta-analysis and systematic review. *World Neurosurg* 2019;122:613-9.
- Kim E. Embolization therapy for refractory hemorrhage in patients with chronic subdural hematomas. *World Neurosurg* 2017;101:520-7.
- Fiorella D, Arthur AS. Middle meningeal artery embolization for the management of chronic subdural hematoma. *J Neurointerv Surg* 2019;11:912-5.