

# Hemolytic Uremic Syndrome in Children

Bora Gülhan<sup>1</sup> , Fatih Özaltın<sup>1,2</sup> 

<sup>1</sup>Nephrogenetics Laboratory, Department of Pediatrics, Hacettepe University School of Medicine, Ankara, Turkey

<sup>2</sup>Division of Pediatric Nephrology, Department of Pediatrics, Hacettepe University School of Medicine, Ankara, Turkey

## ABSTRACT

Hemolytic uremic syndrome (HUS) is a thrombotic microangiopathy (TMA), mainly affecting the kidney. The disease is characterized by microangiopathic hemolytic anemia, thrombocytopenia, and acute kidney injury. It is one of the most common causes of acute kidney injury in children. Under this umbrella, there are several different disorders: Shiga toxin-associated HUS, *Streptococcus pneumoniae*-associated HUS, and HUS associated with complement dysregulation. Several drugs and conditions may also cause HUS. There are many different classification systems, which have been developed during the history of the disease. In recent years, clinical and experimental studies have revealed abnormalities in different pathways beyond complement system. Besides, therapeutic options that are based on the pathophysiology have been available for HUS patients.

**Keywords:** Hemolytic uremic syndrome, complement system, eculizumab

## INTRODUCTION

Thrombotic microangiopathy (TMA) is a disease spectrum characterized by microangiopathic hemolytic anemia and thrombocytopenia. The main cause is an endothelial injury, which occurs in various organs including the brain, lungs, heart, gastrointestinal tract, and kidneys. There are 3 main diseases under this wide umbrella. These include hemolytic uremic syndrome (HUS), thrombotic thrombocytopenic purpura (TTP) and hemolysis, elevated liver enzymes, and a low platelet count (HELLP) syndrome. Among them, TTP is the most common form of TMA in adults. TTP occurs due to a severe deficiency of A Disintegrin And Metalloproteinase with a Thrombospondin type 1 motif, member 13 (ADAMTS13). The laboratory determination of this deficiency helps to distinguish TTP from HUS. HUS is the most common form of TMA in children.<sup>1</sup> It was first described by Conrad von Gasser and his colleagues in 1955, and was defined as microangiopathic hemolytic anemia, thrombocytopenia, and acute kidney injury.<sup>2</sup> After the first definition, enormous attempts have been made to understand the underlying pathogenetic and pathophysiological mechanisms. These paved the way for the discovery of new targeted therapies, which represent optimum examples of personalized medicine. In this review, we attempted to summarize the current diagnostic and therapeutic approaches in this rapidly evolving field.

## DEFINITIONS AND CLASSIFICATIONS

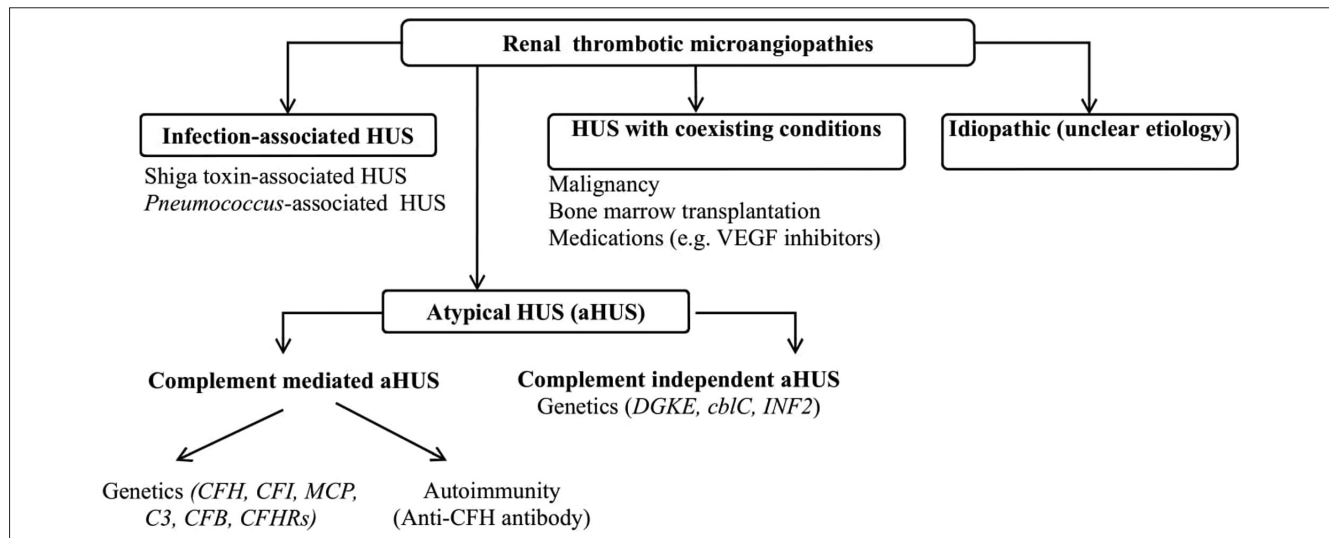
From the traditional point of view, HUS was classified as "diarrhea-positive" (typical) and "diarrhea-negative" (atypical). As diarrhea can be observed in both "typical" and "atypical" cases, this classification would be misleading, and therefore was abandoned. After the initial definition of the HUS, various classifications were made. The most common type of typical HUS is caused by STEC (Shiga toxin-producing *Escherichia coli*). This situation was named as STEC-HUS. Most of the remaining HUS cases are caused by pathogenic variants in the genes, which encode proteins in the alternative pathway. However, there are still debates on the definition of atypical hemolytic uremic syndrome (aHUS). Until recently,

Corresponding author:  
Fatih Ozaltin  
fozaltin@hacettepe.edu.tr  
Received: May 5, 2021  
Accepted: May 22, 2021

Content of this journal is licensed under a Creative Commons Attribution-NonCommercial 4.0 International License.



**Cite this article as:** Gülhan B, Özaltın F. Hemolytic uremic syndrome in children. *Turk Arch Pediatr.* 2021; 56(5): 415-422.



**Figure 1.** 2021 classification of renal thrombotic microangiopathies. (VEGF, vascular endothelial growth factor).<sup>5</sup>

all but STEC-HUS cases were named as aHUS. However, there are many different causes that may result in HUS. These are *Streptococcus pneumoniae* infection, transplantation, drugs, autoimmune diseases, malignant hypertension, cobalamin C deficiency, and *DGKE* mutations. The current classification divides HUS into etiologic subgroups. Therefore, the term “aHUS” was reserved for those that are related to the dysregulation of the alternative pathway and complementary independent mechanisms due to *DGKE*, *cbIC*, and *INF2* mutations (Figure 1).<sup>1,3-5</sup>

## SHIGA TOXIN-ASSOCIATED HUS

### Epidemiology

It occurs mostly in rural areas after acute gastroenteritis caused by Enterohemorrhagic *E. coli* (EHEC) or *S. dysenteriae*. It is mostly seen in children under 3-5 years of age.<sup>1</sup> Among all pediatric HUS cases, the proportion of STEC-HUS is 85-90%. In Europe and North America, the overall incidence is 0.6-0.8 cases/100 000 children under 15-18 years of age and 1.9-2.9 cases/100 000 children under 3-5 years of age.<sup>1,3</sup> Geography is probably another factor that affects the incidence of the disease, as its incidence is 10 times higher in Latin America than in other continents (10-17 cases/100 000 children under 5 years). Approximately 5-10% of the patients with sporadic STEC gastroenteritis develop HUS, which can even reach up to 20% during outbreaks. *E. coli* O157 was predominantly isolated in patients with STEC gastroenteritis. However, non-O157 strains of *E. coli* also increased after the year 2010. In the outbreak in Germany in 2011, *E. coli* O104:H4 was the most commonly isolated strain.<sup>5-7</sup> The STEC infection is caused by undercooked beef, contaminated water, or vegetables.<sup>1</sup>

### Pathogenesis

There are many studies on the pathogenesis of STEC-HUS. Most of the EHEC strains express the adhesin intimin, which allows Shiga toxin (Stx) to enter the circulation. Stx invades the endothelial cells via globotriaosylceramide (Gb3)-dependent and Gb3-independent pathways. It shows cytotoxic effects by the inhibition of protein synthesis and activation of the

CXCR4/CXCR7/SDF1 pathway.<sup>8</sup> In addition, Stx triggers endothelial secretion of the von Willebrand factor, via its proinflammatory and prothrombotic effects. It also activates the complement system and binds to complement factor H (CFH), and diminishes its regulatory effects.<sup>9,10</sup>

### Clinical Characteristics

Diarrhea starts after 3-8 days of ingestion of contaminated food. In the early stages, the diarrhea is usually watery and may become bloody during follow-up. Abdominal pain, nausea, vomiting, and fever may accompany the diarrhea. The typical signs of HUS usually begin 2-14 days after the onset of diarrhea.<sup>11</sup> The serotype of the bacteria (i.e., O157-H7), the type of the toxins (i.e., Stx2), the age of the patient (i.e., <5 years of age), fever, severe diarrhea, female gender, and leukocytosis increase the risk of the development of HUS.<sup>12</sup>

The laboratory parameters show microangiopathic hemolytic anemia, which is caused by the mechanical injury of the erythrocytes in the renal microcirculation, leading to fragmentation. The direct Coombs test is negative. Schistocytes and helmet cells are common findings in the peripheral blood smear. The hemoglobin level is less than 8-10 g/dL. Both the reticulocyte count and the lactate dehydrogenase (LDH) levels are increased. On the other hand, haptoglobin level is decreased.<sup>13</sup>

Renal presentation of the patients with STEC-HUS is variable, namely hematuria and/or nephrotic/non-nephrotic proteinuria. Intrinsic acute kidney injury and oligo/anuria are commonly observed. The renal ischemia caused by the TMA itself and associated oligo/anuria result in hypervolemia and hypertension. More than half of the patients require renal replacement therapy. Renal pathology reveals thickening of the glomerular capillaries and swelling of the endothelium, which results in obstruction of the capillary lumen. Rarely, ischemia may lead to cortical necrosis in some patients.<sup>1</sup>

The standard clinical triad (i.e., microangiopathic hemolytic anemia, thrombocytopenia, and acute kidney injury) may not coexist at presentation. Ardissino et al.<sup>14</sup> investigated 132 patients with documented HUS. They showed that only 41% of them had

all 3 components of the definition at disease onset. Among them, 25% were not anemic, 14% did not have renal failure, and 11% had low platelet count, although the disease was present.<sup>14</sup> Therefore, all suspected cases should be closely monitored for the development of laboratory indices.

Besides hematological and renal systems, other organs can also be involved. These systems are the central nervous system (CNS), and the cardiac, gastrointestinal, and musculoskeletal systems. The most common extrarenal involvement is the CNS involvement. The signs suggesting CNS involvement include irritability, lethargy, confusion, altered mental status, seizures, stroke, and coma. The other rare manifestations are hemiplegia, cortical blindness, dysphasia, diplopia, and facial nerve palsy.<sup>15</sup> Gastrointestinal system involvement may present as bowel ischemia, bowel necrosis, bowel wall thrombosis, perforation, pseudomembranous colitis, and rectal prolapse. An elevation in liver transaminases and serum bilirubin levels may be also observed. Insulin-dependent diabetes mellitus, pancreatic enzyme elevation and pancreatitis, and pancreatic necrosis, pericardial effusion/tamponade, depressed myocardial function, myocardial infarction and ischemic cardiomyopathy, rhabdomyolysis, and ulcerative gangrenous lesions have been reported as rare extrarenal findings.<sup>15</sup>

### Management

Specific treatment for STEC-HUS is absent and the current management can be summarized in 2 categories.

### Supportive Treatment

The first rule in the treatment of STEC-HUS is the correct management of the circulatory volume, especially at the beginning of the disease. In a study of Ardissino et al.,<sup>16</sup> it has been shown that early fluid infusion reduces the dialysis requirement, hospitalization and renal and extrarenal sequelae including CNS involvement.<sup>16</sup> In contrast, volume restriction should be maintained in anuric and hypervolemic patients. Dehydrated patients should be treated with 0.9% saline. On the other hand, in children with volume overload and oligoanuria, intravenous furosemide may be useful. Once they become euvolemic, neutral fluid balance should be achieved by replacing the insensible losses. Close monitoring of the electrolytes and acid–base status is needed, and any abnormality should be corrected immediately. Renal replacement therapy should be applied to patients who have electrolyte and/or acid–base abnormalities or hypervolemia not resolved by medical therapies.<sup>11</sup> There is no evidence that one dialysis modality is better than another.

For the treatment of hypertension, fluid overload, if present, should be corrected first. In the acute period, calcium channel blockers can be preferred. In emergency treatment of hypertension, intravenous esmolol or sodium nitroprusside can be used. In the acute period of the disease, angiotensin-converting enzyme inhibitors and/or angiotensin receptor blockers should be avoided.<sup>17</sup>

Blood products may be necessary, and most patients (up to 80%) may require at least 1 red blood cell transfusion for ongoing hemolysis. The ECUSTEC trial has recommended the following criteria for transfusion: hemoglobin level <7 g/dL or <7.5 g/dL, with decrease greater than 2 g/dL compared with

its previous 24-hour level. The decision for transfusion should be made with the nephrologist in charge, due to the risks of hyperkalemia and hypervolemia. Platelet consumption commonly leads to thrombocytopenia. Routine platelet infusion, unless bleeding is present, is not recommended, but may be given prophylactically before catheter insertion for hemodialysis or peritoneal dialysis.<sup>13</sup> The nutritional requirements of the patients should be also met, as these children are already in a catabolic state.

### Plasma-Based Therapy

Both plasma infusion (PI) and plasma exchange (PE) have been used to replace and remove the circulating factors, respectively, which is a salvage therapy for patients with CNS involvement.<sup>13</sup> There are different views about the benefits of PI or PE on the disease course. Several studies and anecdotal case reports have shown recovery following PE.<sup>18</sup> However, the efficiency of plasma therapies have not been confirmed in large-scale studies.<sup>19,20</sup> Eculizumab is a humanized monoclonal C5 antibody, and used successfully in aHUS. However, its usage in STEC-HUS has not been well validated. It was given in a small number of patients with serious neurological involvement of STEC-HUS, especially in the 2011 German epidemic. In these studies, it has had limited effects in the treatment of STEC-HUS. The Shiga toxin-binding agent and Shiga toxin neutralizing agent have also been studied in mice with HUS.<sup>21</sup> Among them, the Shiga toxin binding agent (SYNSORB Pk) did not have significant benefits.<sup>22</sup>

### Prognosis

The mortality in the acute period is 5%, and is even higher in patients with extrarenal involvement. The long-term renal sequelae (i.e., glomerular filtration rate (GFR) <80 mL/min/1.73m<sup>2</sup>, proteinuria, and/or hypertension) have been observed in nearly 25% of the survivors.<sup>1,11</sup>

### *S. pneumoniae*-Associated HUS

After the introduction of the 7-valent pneumococcal conjugate vaccine (PCV7), the frequency of invasive pneumococcal disease has decreased. However, the yearly incidence of SP-HUS has not decreased, and is around 0.06 cases/100 000 children younger than 18 years of age. This may be due to the increase in non-PCV7 serotypes (especially the 19A serotype). A total of 5% of all cases with HUS occur due to *S. pneumoniae* (SP-HUS).<sup>23,24</sup> The incidence of HUS following invasive pneumococcal infections is estimated about 0.4–0.6%. It usually occurs after pneumonia (complicated with empyema) and meningitis.<sup>25</sup> It has been hypothesized that removal of sialic acid from cell surfaces by the circulating neuraminidase produced by *S. pneumoniae* would be the main pathophysiologic underlying event. This results in exposure of the Thomsen-Friedenreich cryptantigen (T-antigen). Preformed IgM antibodies against T-antigen react with RBCs, platelets and endothelial cells, which leads to aggregation in the microcirculation and TMA.<sup>12</sup> Some pneumococcal serotypes have also been demonstrated by direct binding of factor H by bacterial-expressed proteins (such as Hic and surface protein C), and may inhibit its action.<sup>25</sup>

The signs and symptoms usually start 3–13 days (mostly within 7–9 days) after the beginning of the pneumococcal disease.

Children with SP-HUS are younger, and usually have more severe renal and/or hematological disease requiring longer hospitalization, and suffer from kidney injury due to cortical necrosis more often than those with STEC-HUS.<sup>26</sup>

Its management includes the treatment of pneumococcal infection, and remains supportive, as described above. Packed RBCs are recommended to be washed with dextran, because of the concern that anti-T antibodies may exist in blood products. Fresh frozen Pls should be avoided due to the same reason. In severe cases, eculizumab has been given, and this causes an increase in thrombocytes.<sup>26</sup>

The mortality rate in the acute period is 12.3%. In the long term, 23% of the patients developed chronic kidney disease (CKD), 28% proteinuria and 19% hypertension. It has been reported that those patients who require dialysis longer than 20 days have the highest risk for CKD.<sup>25</sup>

### ATYPICAL HEMOLYTIC UREMIC SYNDROME

#### Epidemiology

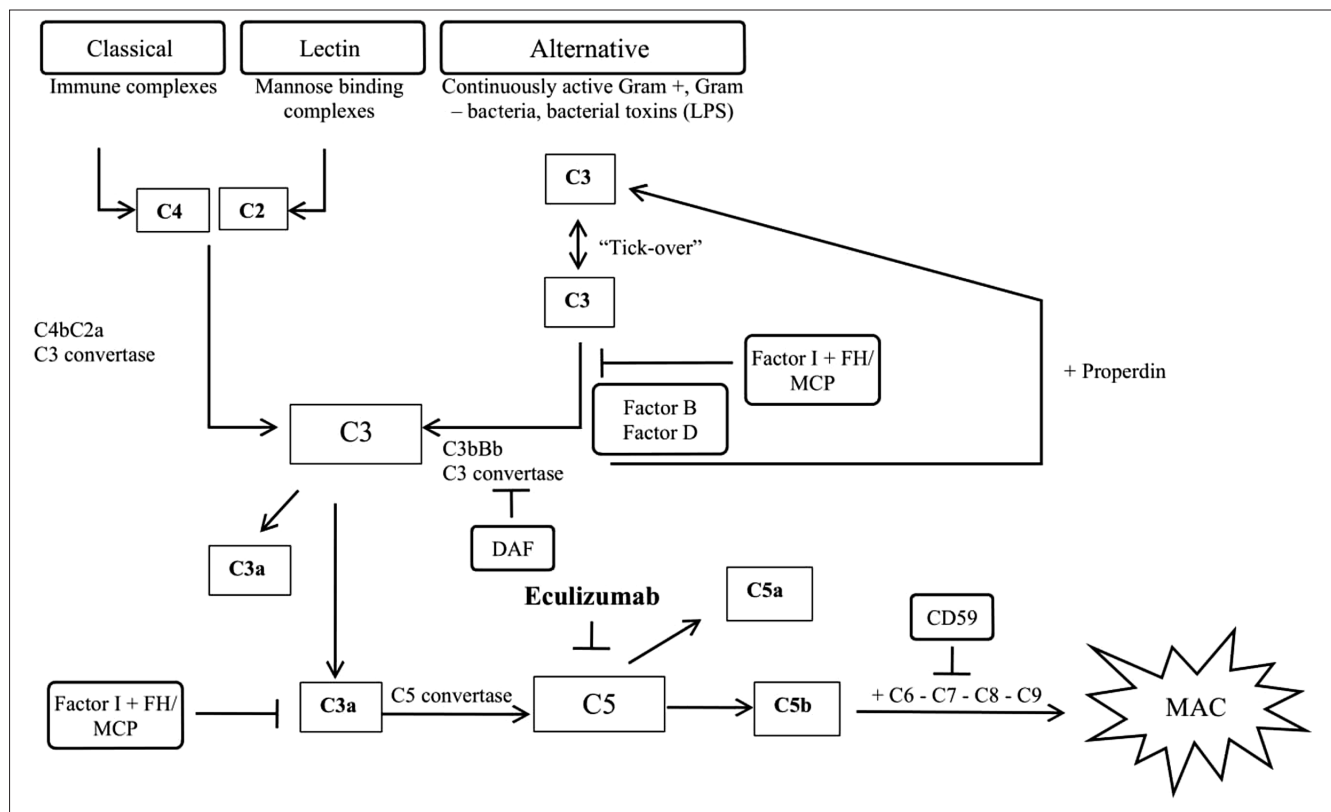
The data of incidence differ according to the definition of the disease, and vary between 0.23 cases and 0.42 cases/million population (0.1-0.11 in children under the age of 16-17 years/million population).<sup>1</sup> Approximately 70% of the children have their first episode before 2 years of age, and 25% of them before 6 months. The frequency is equal between boys and girls.<sup>27</sup> Atypical hemolytic uremic syndrome constitutes 5-10% of all HUS cases in the pediatric age group.<sup>1</sup>

#### Pathogenesis

Most of the patients have a mutation in the genes encoding the proteins and/or antibodies against proteins in the alternative complement pathway. The complement system is composed of classical, lectin, and alternative pathways. Among these pathways, the alternative complement system is constantly active, due to the spontaneous hydrolysis of C3. Activated C3 is deposited on cell surfaces, generating an amplification loop. This results in the cleavage of C5 to C5a (potent anaphylatoxin) and C5b (Figure 2).<sup>28</sup>

The types of mutations are different in aHUS pathogenesis. Loss-of-function mutations in the genes encoding regulatory proteins (complement factor H (CFH), complement factor I (CFI), membrane cofactor protein (MCP, CD46), thrombomodulin) and gain-of-function mutations in the genes encoding complement factor B (CFB), complement 3 (C3), and/or neutralizing antibody against CFH (anti-CFH antibodies) cause dysregulation and/or overactivation in the alternative pathway. These genetic abnormalities result in the production of C5b-9 membrane attack complex (MAC), perforating the cellular surfaces, and leading to osmotic lysis.<sup>28</sup>

The most common mutations causing aHUS are detected on CFH, which also relate to the worst prognosis. The CFH is the most important protein for the regulation of the alternative pathway. CFH competes with CFB for binding to C3 convertase, and CFB can no longer form the C3 convertase. MCP mutations are generally associated with a favorable prognosis when compared to other complement gene mutations. It should be



**Figure 2.** Complement system pathways and regulatory proteins. DAF, decay accelerating factor; FH, factor H; MCP, membrane co-factor protein

**Table 1.** Characteristics of the Proteins in the Alternative Pathway<sup>28</sup>

Protein	Function	Frequency in aHUS (%)	ESRD After 5 years (%)	Recurrence	Recurrence After Kidney Transplantation (%)
CFH	Cofactor for factor I	21-25	70-80	30-50	68-90
MCP/CD46	Membrane-bound complement regulatory	5-22.8	10-50	58-90	11-20
CFI	Inactivation of C3b and C4b	6-16.6	45-60	10-30	70-80
CFB	Allows the formation of C3 and C5 convertases	1.9-4	70	Rare	Rare
C3	Necessary for complement cascade activation	6-9	45-65	50	40-50
FHR	Circulating proteins similar to factor H, associated with autoantibodies against FH	4.5-35	30-63	23-60	20
THBD/CD141	Degradation C3b	2-5	53-60	23-30	Rare

emphasized that up to 70% of the patients may have a mutation in the genes that are already known to be associated with aHUS when mutated.<sup>27,28</sup> We established a web-based, national registry system ([www.ahusnet.org](http://www.ahusnet.org)) in the year 2013. Analysis of the patients in the registry ( $n = 146$ ) showed that MCP mutation is the most common one among Turkish aHUS patients (16.3%).<sup>29</sup> Mutation screening is not a prerequisite for aHUS diagnosis. However, it helps to determine the prognosis and the recurrence risk (Table 1).<sup>28</sup>

### Clinical Findings

More than half of the patients have a history of infection (upper respiratory tract infections or acute gastroenteritis) that overly activate the alternative complement pathway.<sup>11</sup> Pallor, vomiting, fatigue, and edema are commonly observed. Most of the patients have the classical triad. However, some findings may develop during the disease course. The cases that show normal platelet levels at the beginning but a >25% decrease from baseline during the disease course should also be followed up for aHUS. Although aHUS primarily targets the kidney, extrarenal system involvement (i.e., CNS, cardiovascular system, lungs, skin, retinal vascular system, gastrointestinal tract) may be observed in nearly 20% of the patients. CNS involvement is the most common extrarenal involvement, and is observed in 8-48% of the patients.<sup>30</sup> In the national registry of Turkey, CNS involvement was found to be the most common extrarenal system involvement, with 27.2%.<sup>31</sup> The most common signs and symptoms of CNS involvement are irritability, drowsiness, seizures, diplopia, cortical blindness, hemiparesis or hemiplegia, stupor, and coma.<sup>11,31</sup> Magnetic resonance imaging may show bilateral lesions in deep white matter, brain stem, and basal ganglia. The common conditions of cardiovascular system involvement are infarction in the myocardium, myocarditis, heart failure, cardiomyopathy, and coronary artery disease. Rarely, gangrenous lesions on distal extremities may be observed. Abdominal distention, bloody diarrhea, and perforation are findings of gastrointestinal system involvement.<sup>31,32</sup> A basic diagnostic approach in patients with TMA is shown in Figure 3.

### Management

Management can be divided into 2 parts, as supportive and specific treatment. Supportive treatment is the same that has been given above, for STEC-HUS.

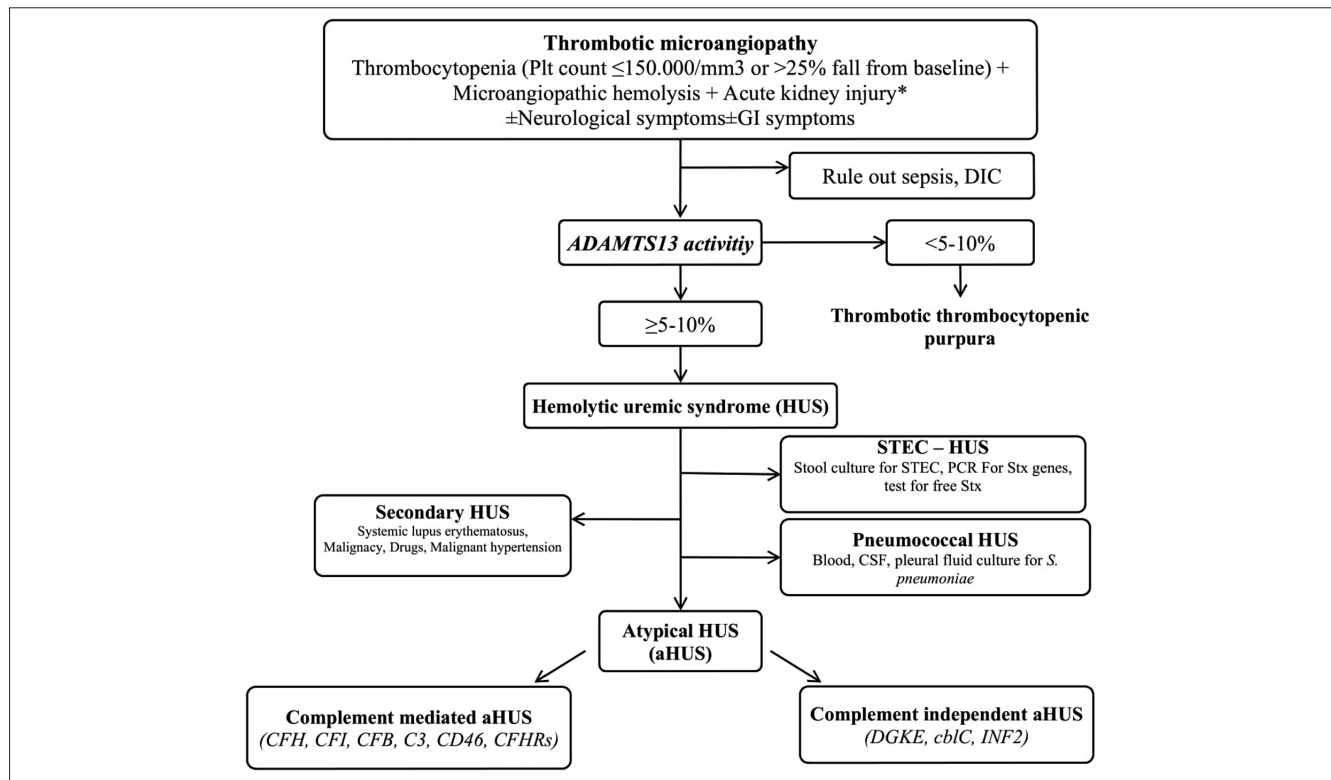
### Specific Treatment

Fresh frozen plasma contains normal amounts of CFH and CFI, along with PE, mutant CFH, CFI, CFB, and anti-factor H antibodies, which can be removed from the circulation while the supplying normal factors. In the treatment of aHUS, PE was used at 60-75 mL/kg and PI was administered at 10-20 mL/kg. Plasma-based therapies (PI and/or PE) were the cornerstones of the management for many years. However, PE and PI may cause volume overload, especially in oliguric patients. There is no strong evidence for the efficacy of plasma therapy in aHUS. In a study, plasma therapy induced hematological remission in 78% and 53% of the children and adults, respectively. However, half of the children and two-thirds of the adults progressed to ESRD or died at 3 years of follow-up.<sup>33</sup> Recently, we evaluated the outcome of 7 aHUS patients who were treated with PE ( $n = 3$ ) and PI ( $n = 4$ ). The median follow-up duration was 3.7 years (IQR: 2.7-6.5). At the end of the follow-up 2 patients underwent a renal transplantation (one with CFH mutation and the other with CFH antibody/CFHR1/3 deletion). Except for 1 patient who was lost to follow-up, and one who underwent renal transplantation and experienced a rejection episode, the remaining 5 patients had a GFR >90 mL/min/1.73 m<sup>2</sup> with complete hematological remission (This study has recently been accepted for the publication in Turkish Journal of Pediatrics.). Catheter-related complications that could be seen in up to 31% of the cases, and may complicate the course of the disease.<sup>34</sup>

In the last 10 years, eculizumab opened a new road and reversed the poor prognosis of the patients. Eculizumab is the humanized, recombinant, monoclonal, IgG type of C5 antibody, which prevents the cleavage of C5 into C5a and C5b, and thereby the formation of MAC. With this inhibitory effect, the activity of the alternative complement pathway is decreased, and not only proinflammatory but prothrombotic and lytic functions of the complement system are also prevented. Animal studies showed the passage of the drug through the placental barriers, causing fetal morbidity and mortality. The half-life of the drug is  $11 \pm 3$  days, and maintenance treatment is given every 2 weeks (Table 2).<sup>35</sup>

Eculizumab treatment was approved for the treatment of paroxysmal nocturnal hemoglobinuria in 2008. Later reports showed the potential effects of eculizumab in aHUS patients.





**Figure 3.** Basic algorithm for TMA diagnostic work-up (ADAMTS13, A disintegrin and metalloproteinase with a thrombospondin type 1 motif, member 13; CSF, cerebrospinal fluid; DIC, disseminated intravascular coagulation; GI, gastrointestinal; PCR, polymerase chain reaction; Plt, platelet; STEC, Shiga toxin-producing *Escherichia coli*; Stx, Shiga toxin \*Renal biopsy can be considered, in suspicious cases).

**Table 2.** Induction and Maintenance Doses of Eculizumab in the Treatment of aHUS

Weight (kg)	Dose of Eculizumab (mg)					Maintenance (mg/frequency)
	Induction					
	Week 1	Week 2	Week 3*	Week 4*	Week 5*	
5 to <10	300	300	-	-	-	300/3 weeks
10 to <20	600	300	-	-	-	300/2 weeks
20 to <30	600	600	600	-	-	600/2 weeks
30 to <40	600	600	900	-	-	900/2 weeks
≥40	900	900	900	900	1200	1200/2 weeks

\*Maintenance treatment should be initiated in the weeks that are marked with "-".

In 2011, the FDA (Food and Drug Administration) and the EMA (European Medicine Agency) approved eculizumab in aHUS treatment. A prospective study included aHUS patients who were treated with eculizumab.<sup>27</sup> In all patients, plasma therapy was stopped and eculizumab was initiated. The TMA activity ceased in most patients (80-88%). Besides, eGFR was increased and dialysis could be discontinued in most patients, who were on dialysis at the time of eculizumab initiation.<sup>36</sup> The efficacy of the eculizumab treatment was also shown in pediatric aHUS patients. Greenbaum et al.<sup>37</sup> prospectively evaluated 22 children with aHUS, who were treated with eculizumab over 26 weeks. By week 26, 14 patients achieved complete TMA remission, 18 achieved hematologic normalization, 16 had 25% or better improvement in serum creatinine level and PE/PI was discontinued in all patients.<sup>37</sup> The first pediatric aHUS patient who was treated successfully with eculizumab in Turkey was diagnosed neonatally. After diagnosis, he achieved remission with PI. However life-threatening disease recurrences occurred

at 1, 3, and 6 months of age, and eculizumab was initiated. He had uncontrolled hypertension and acute kidney injury on last relapse, while he was receiving PI. After the initiation of eculizumab, the TMA was brought under control. Genetic analysis of the *CFH* gene showed a novel homozygous p. Tyr1177Cys mutation.<sup>38</sup> After these experiences, eculizumab is recommended as a first-line agent in the treatment of aHUS and should be initiated as soon as possible (within 24 hours, if available). If eculizumab is not available, PE with fresh frozen plasma is indicated (PI, if PE is not available). Measuring the 50% hemolytic complement activity (CH50) can be used to check the level of the complement blockade. The optimal complement blockade is generally defined as CH50 <10%. Measurement of plasma eculizumab level is another tool and it is recommended to maintain its level as >100 µg/mL although the threshold level ≥50 µg/mL is also sufficient for complement blockade. Patients resistant to eculizumab should be investigated for a variant in the eculizumab C5 binding site, which is mostly present in Asian

patients. The other reasons may be urinary loss of eculizumab in proteinuric patients, or an insufficient dose.<sup>4,39</sup>

Eculizumab blocks the activation of the terminal complement pathway. Therefore, the patients would be susceptible to infections with encapsulated bacteria like *Neisseria meningitidis*. Ideally, patients should be vaccinated at least 2 weeks prior to therapy. However, the sudden onset of the disease renders this strategy nearly impossible. In this case, prophylactic antibiotics should be administered. Furthermore, immunizations against *S. pneumoniae* and *H. influenzae* type B should also be considered before starting eculizumab. The other severe side effects of eculizumab include infections (24%), hypertension (5%), chronic renal impairment (5%), and allergic reactions. Some other side effects (headache, diarrhea, hypertension, abdominal pain, vomiting, nasopharyngitis, anemia, cough, peripheral edema, nausea, and pyrexia) have also been reported.<sup>32</sup>

The most common limitation of eculizumab usage is its high cost during treatment, that is >\$300 000/year.<sup>40</sup> Therefore, studies regarding the cessation of the treatment are increasing during recent years.<sup>41</sup> Eculizumab discontinuation should be taken into consideration after at least 6 months of treatment (3 months in patients with MCP mutations) and after normalization or stabilization of renal functions in those patients who meet some specific criteria.<sup>39</sup>

Isolated kidney transplantation can be performed in aHUS patients with end-stage renal disease (ESRD). The risk of the disease recurrence varies in different mutations in the genes encoding alternative complement proteins. In patients with MCP mutation, the recurrence rate is lower than in the patients with CFH mutation.<sup>17</sup>

In the alternative complement pathway, CFH, CFB, and C3 are the proteins that are synthesized in the liver. Liver transplantation or combined liver–kidney transplantation (CLKT) may be a therapeutic approach for selected aHUS patients to cure the disease. Although eculizumab came to the stage with its success, CLKT should not be completely discarded. Every patient should be evaluated with his/her own characteristics, and the risk/benefit ratio of life-long eculizumab treatment should be discussed extensively with the family.<sup>4</sup>

### Immunosuppressive Treatment

Immunosuppressive treatment (steroids, cyclophosphamide, and rituximab) can be given to the patients with aHUS developing secondary to anti-CFH antibody.<sup>17</sup>

### Cobalamin C HUS

Cobalamin C HUS is a form of aHUS, which is an autosomal recessive disorder of cobalamin metabolism that causes TMA and multiorgan involvement. The mutations are on the *MMACHC* gene, which encodes methylmalonic aciduria and homocystinuria type C (MMACHC) protein. The mutations in this gene lead to hyperhomocysteinemia, decreased plasma methionine levels, and methylmalonic aciduria. To date, numerous mutations have been identified, and among them, 271dupA has accounted for 40% of all cases. The clinical presentation can be divided into 2 categories according to the age of onset, as early-onset (<1 year) and late-onset (>4 year) disease.

Early-onset disease has more severe CNS, kidney, and multi-system involvement, like feeding difficulties, failure to thrive, lethargy, and hypotonia. In the early-onset type, hypertension may be observed. Late-onset disease usually has milder findings, and may cause chronic TMA.<sup>11</sup> Recently, we have reported 2 early-onset patients who carry the p. R161\*[c.481C>T] and 271dupA mutations, respectively.<sup>42</sup> Hydroxocobalamin, betaine, and folic acid are used for treatment. Therefore, it is unlikely that classical treatment with eculizumab, PI, or PE will have any additional therapeutic effect.<sup>11</sup>

### Diacyl Glycerol Kinase Epsilon (DGK $\epsilon$ )-Associated aHUS

Recent developments on the pathophysiology of aHUS have uncovered a new link between the mutations in the gene encoding diacylglycerol kinase epsilon (DGK $\epsilon$ ), and glomerular microangiopathy mimicking membranoproliferative glomerulonephritis or HUS.<sup>43,44</sup> Mutations in the corresponding gene are mostly the loss-of-function type, and lead to recurrent thrombosis in the renal microvasculature. Therefore, DGK $\epsilon$  is speculated to play an essential role in preventing thrombosis.<sup>45</sup> Whereas a group of patients with DGK $\epsilon$  mutations have been shown to have glomerular microangiopathy, which gives an appearance of membranoproliferative glomerulonephritis,<sup>43</sup> in the others who presented with HUS, it typically manifests at less than 1 year of age. In the latter, the phenotype is characterized with heavy proteinuria, in addition to the classical triad of HUS, and those patients are generally unresponsive to eculizumab.<sup>44</sup>

### CONCLUSION

A better understanding of the pathophysiology and the recent developments in the treatment of HUS in the last 2 decades have yielded better management of this highly fatal disease. As of now, these patients can be efficiently treated and protected from short-term and long-term complications. Therefore, every physician taking care of HUS patients should have knowledge about the disease and the therapeutic options available to avoid disease-related mortality and morbidity.

**Peer Review:** Externally peer-reviewed.

**Author Contributions:** Writing- B.G.; Supervision and Critical Reviews - F.Ö.

**Conflict of Interest:** The authors have no conflict of interest to declare.

**Financial Disclosure:** The authors declared that this study has received no financial support.

### REFERENCES

1. Fakhouri F, Zuber J, Frémeaux-Bacchi V, Loirat C. Haemolytic uraemic syndrome. *Lancet*. 2017;390(10095):681–696. [CrossRef]
2. Gasser C, Gautier E, Steck A, Siebenmann RE, Oechslin R. Hemolytic-uremic syndrome: bilateral necrosis of the renal cortex in acute acquired hemolytic anemia. *Schweiz Med Wochenschr*. 1955;85(38–39):905–909.
3. Loirat C, Frémeaux-Bacchi V. Atypical hemolytic uremic syndrome. *Orphanet J Rare Dis*. 2011;6:60. [CrossRef]
4. Loirat C, Fakhouri F, Ariceta G, et al. An international consensus approach to the management of atypical hemolytic uremic syndrome in children. *Pediatr Nephrol*. 2016;31(1):15–39. [CrossRef]

5. Lemaire M, Noone D, Lapeyraque AL, Licht C, Frémeaux-Bacchi V. Inherited kidney complement diseases. *Clin J Am Soc Nephrol*. 2021;16(6):942-956. [\[CrossRef\]](#)
6. Ong KL, Apostal M, Comstock N, et al. Strategies for surveillance of pediatric hemolytic uremic syndrome: foodborne diseases Active Surveillance Network Foodnet, (2000-2007). *Clin Infect Dis*. 2012;54(suppl 5):S424-S431. [\[CrossRef\]](#)
7. Ruggenenti P, Remuzzi GA. German outbreak of hemolytic uremic syndrome. *Lancet*. 2011;378(9796):1057-1058. [\[CrossRef\]](#)
8. Petruzzello-Pellegrini TN, Yuen DA, Page AV, et al. The CXCR4/CXCR7/SDF-1 pathway contributes to the pathogenesis of Shiga toxin-associated hemolytic uremic syndrome in humans and mice. *J Clin Invest*. 2012;122(2):759-776. [\[CrossRef\]](#)
9. George JN, Nester CM. Syndromes of thrombotic microangiopathy. *N Engl J Med*. 2014;371(7):654-666. [\[CrossRef\]](#)
10. Thurman JM, Marians R, Emlen W, et al. Alternative pathway of complement in children with diarrhea-associated hemolytic uremic syndrome. *Clin J Am Soc Nephrol*. 2009;4(12):1920-1924. [\[CrossRef\]](#)
11. Cody EM, Dixon BP. Hemolytic uremic syndrome. *Pediatr Clin North Am*. 2019;66(1):235-246. [\[CrossRef\]](#)
12. Salvadori M, Bertoni E. Update on hemolytic uremic syndrome: diagnostic and therapeutic recommendations. *World J Nephrol*. 2013;2(3):56-76. [\[CrossRef\]](#)
13. Walsh PR, Johnson S. Treatment and management of children with haemolytic uremic syndrome. *Arch Dis Child*. 2018;103(3):285-291. [\[CrossRef\]](#)
14. Ardissino G, Possenti I, Tel F, Testa S, Paglialonga F. Time to change the definition of hemolytic uremic syndrome. *Eur J Intern Med*. 2014;25(2):e29. [\[CrossRef\]](#)
15. Khalid M, Andreoli S. Extrarenal manifestations of the hemolytic uremic syndrome associated with Shiga toxin-producing *Escherichia coli* (STEC HUS). *Pediatr Nephrol*. 2019;34(12):2495-2507. [\[CrossRef\]](#)
16. Ardissino G, Tel F, Possenti I, et al. Early volume expansion and outcomes of hemolytic uremic syndrome. *Pediatrics*. 2016;137(1):e20152153. [\[CrossRef\]](#)
17. Canpolat N. Hemolytic uremic syndrome. *Turk Pediatr Ars*. 2015;50(2):73-82. [\[CrossRef\]](#)
18. Colic E, Dieperink H, Titlestad K, Tepel M. Management of an acute outbreak of diarrhoea-associated haemolytic uraemic syndrome with early plasma exchange in adults from southern Denmark: an observational study. *Lancet*. 2011;378(9796):1089-1093. [\[CrossRef\]](#)
19. Kielstein JT, Beutel G, Fleig S, et al. Best supportive care and therapeutic plasma exchange with or without eculizumab in Shiga-toxin-producing *E. coli* O104:H4 induced haemolytic-uraemic syndrome: an analysis of the German STEC-HUS registry. *Nephrol Dial Transplant*. 2012;27(10):3807-3815. [\[CrossRef\]](#)
20. Nathanson S, Kwon T, Elmaleh M, et al. Acute neurological involvement in diarrhea-associated hemolytic uremic syndrome. *Clin J Am Soc Nephrol*. 2010;5(7):1218-1228. [\[CrossRef\]](#)
21. Nishikawa K. Recent progress of Shiga toxin neutralizer for treatment of infections by Shiga toxin-producing *Escherichia coli*. *Arch Immunol Ther Exp (Warsz)*. 2011;59(4):239-247. [\[CrossRef\]](#)
22. Trachtman H, Cnaan A, Christen E, et al. Effect of an oral Shiga toxin-binding agent on diarrhea-associated hemolytic uremic syndrome in children: a randomized controlled trial. *JAMA*. 2003;290(10):1337-1344. [\[CrossRef\]](#)
23. Veessenmeyer AF, Edmonson MB. Trends in US hospital stays for *Streptococcus pneumoniae*-associated hemolytic uremic syndrome. *Pediatr Infect Dis J*. 2013;32(7):731-735. [\[CrossRef\]](#)
24. Banerjee R, Hersh AL, Newland J, et al. *Streptococcus pneumoniae* associated hemolytic uremic syndrome among children in North America. *Pediatr Infect Dis J*. 2011;30(9):736-739. [\[CrossRef\]](#)
25. Spinale JM, Ruebner RL, Kaplan BS, Copelovitch L. Update on *Streptococcus pneumoniae* associated hemolytic uremic syndrome. *Curr Opin Pediatr*. 2013;25(2):203-208. [\[CrossRef\]](#)
26. Copelovitch L, Kaplan BS. *Streptococcus pneumoniae*-associated hemolytic uremic syndrome. *Pediatr Nephrol*. 2008;23(11):1951-1956. [\[CrossRef\]](#)
27. Loirat C, Frémeaux-Bacchi V. Atypical hemolytic uremic syndrome. *Orphanet J Rare Dis*. 2011;6:60. [\[CrossRef\]](#)
28. Feitz WJ, van de Kar NCA, Orth-Höller D, van den Heuvel LPJW, Licht C. The genetics of atypical hemolytic uremic syndrome. *Med Genet*. 2018;30(4):400-409. [\[CrossRef\]](#)
29. Besbas N, Gulhan B, Soylemezoglu O, et al. Turkish pediatric atypical hemolytic uremic syndrome registry: initial analysis of 146 patients. *BMC Nephrol*. 2017;18(1):6. [\[CrossRef\]](#)
30. Formeck C, Swiatecka-Urban A. Extra-renal manifestations of atypical hemolytic uremic syndrome. *Pediatr Nephrol*. 2019;34(8):1337-1348. [\[CrossRef\]](#)
31. Fidan K, Göknaar N, Gülhan B, et al. Extra-renal manifestations of atypical hemolytic uremic syndrome in children. *Pediatr Nephrol*. 2018;33(8):1395-1403. [\[CrossRef\]](#)
32. Raina R, Krishnappa V, Blaha T, et al. Atypical hemolytic-uremic syndrome: an update on pathophysiology, diagnosis, and treatment. *Ther Apher Dial*. 2019;23(1):4-21. [\[CrossRef\]](#)
33. Noris M, Caprioli J, Bresin E, et al. Relative role of genetic complement abnormalities in sporadic and familial aHUS and their impact on clinical phenotype. *Clin J Am Soc Nephrol*. 2010;5(10):1844-1859. [\[CrossRef\]](#)
34. Johnson S, Stojanovic J, Ariceta G, et al. An audit analysis of a guideline for the investigation and initial therapy of diarrhea negative (atypical) hemolytic uremic syndrome. *Pediatr Nephrol*. 2014;29(10):1967-1978. [\[CrossRef\]](#)
35. Gruppo RA, Rother RP. Eculizumab for congenital atypical hemolytic-uremic syndrome. *N Engl J Med*. 2009;360(5):544-546. [\[CrossRef\]](#)
36. Legendre CM, Licht C, Muus P, et al. Terminal complement inhibitor eculizumab in atypical hemolytic-uremic syndrome. *N Engl J Med*. 2013;368(23):2169-2181. [\[CrossRef\]](#)
37. Greenbaum LA, Fila M, Ardissino G, et al. Eculizumab is a safe and effective treatment in pediatric patients with atypical hemolytic uremic syndrome. *Kidney Int*. 2016;89(3):701-711. [\[CrossRef\]](#)
38. Besbas N, Gulhan B, Karpman D, et al. Neonatal onset atypical hemolytic uremic syndrome successfully treated with eculizumab. *Pediatr Nephrol*. 2013;28(1):155-158. [\[CrossRef\]](#)
39. Fakhouri F, Loirat C. Anticomplement therapy in atypical and typical hemolytic uremic syndrome. *Semin Hematol*. 2018;55(3):150-158. [\[CrossRef\]](#)
40. Gatault P, Brachet G, Ternant D, et al. Therapeutic drug monitoring of eculizumab: rationale for an individualized dosing schedule. *mAbs*. 2015;7(6):1205-1211. [\[CrossRef\]](#)
41. Fakhouri F, Fila M, Hummel A, et al. Eculizumab discontinuation in children and adults with atypical haemolytic uremic syndrome: a prospective multicentric study. *Blood*. 2020;137(18):2438-2449.
42. Topaloglu R, İnözü M, Gülhan B, et al. Do not miss rare and treatable cause of early-onset hemolytic uremic syndrome: cobalamin C deficiency. *Nephron*. 2019;142(3):258-263. [\[CrossRef\]](#)
43. Ozaltın F, Li B, Rauhauser A, et al. DGKE variants cause a glomerular microangiopathy that mimics membranoproliferative GN. *J Am Soc Nephrol*. 2013;24(3):377-384. [\[CrossRef\]](#)
44. Lemaire M, Frémeaux-Bacchi V, Schaefer F, et al. Recessive mutations in DGKE cause atypical hemolytic-uremic syndrome. *Nat Genet*. 2013;45(5):531-536. [\[CrossRef\]](#)
45. Epand RM, So V, Jennings W, et al. Diacylglycerol kinase-epsilon: properties and biological roles. *Front Cell Dev Biol*. 2016;4:112. [\[CrossRef\]](#)