

Different Clinical Applications of Bondable Reinforcement Ribbond in Pediatric Dentistry

Nuray Tuloglu^a
Sule Bayrak^b
Emine Sen Tunc^b

ABSTRACT

Ribbond is a bondable, biocompatible, esthetic, translucent and easy-to-use reinforced ribbon. By virtue of its wide spectrum of intended properties, it enjoys various applications in clinical dentistry. This case report demonstrates usage of Ribbond as a space maintainer, a fixed partial denture with a natural tooth pontic, an endodontic post and cores and a splint material in children. Ribbond can be used as an alternative to conventional treatment in pediatric dentistry. (Eur J Dent 2009;3:329-334)

Key words: Ribbond; Fixed partial denture; Endodontic post; Trauma splint; Space maintainer.

INTRODUCTION

The development of fiber-reinforced composite (FRC) technology has brought a new material into the realm of metal-free, adhesive esthetic dentistry.¹ Not only has the combination of composite resin and FRC been shown to have significant benefits in terms of mechanical properties,² the possibility of direct chairside application and the ability

to bond to tooth structure make FRC an attractive choice for a variety of dental applications.³⁻⁵

Different fiber types such as glass fibers, carbon fibers, kevlar fibers, vectran fibers, polyethylene fibers have been added to composite materials.⁶ Glass fibers consisting of glass interlaced filaments, improve the impact strength of composite materials. They have excellent esthetic properties, but do not easily stick to resinous matrix.⁷ Carbon fibers prevent fatigue fracture and strengthen composite materials, but they have a dark color, which is undesirable esthetically.^{6,8,9} Kevlar fibers made of an aromatic polyamide, are the evolution of nylon polyamide.⁶ They increase the impact strength of composite materials. However, they are also unesthetic, and hence, their use is limited.¹⁰ Vectran fibers are synthetic fibers of a new generation, made of aromatic polyesters. They show a good resistance to abrasion and im-

^a Research Assistant, DDS, PhD, Assistant Professor, Department of Pediatric Dentistry, Faculty of Dentistry, Ondokuz Mayıs University, Samsun, Turkey.

^b Assistant Professor, DDS, PhD, Department of Pediatric Dentistry, Faculty of Dentistry, University of Ondokuz Mayıs, Samsun, Turkey.

■ Corresponding author: Sule Bayrak
Faculty of Dentistry, Department of Pediatric Dentistry
Ondokuz Mayıs University
55139, Kurupelit, Samsun, Turkey.
Phone: +90 362 3121919/3365
Fax: +90362457603
E-mail:suleb76@yahoo.com

compact strength, but they are expensive and not easily wielded.⁶ Polyethylene fibers improve the impact strength, modulus elasticity, and flexural strength of composite materials. Unlike carbon and Kevlar fibers, polyethylene fibers are almost invisible in a resinous matrix and for these reasons, seem to be the most appropriate and esthetic strengtheners of composite materials.⁸

Ribbon is a spectrum of 215 fibers with a very high molecular weight. First introduced to the market in 1992, Ribbon consists of bondable, reinforced ultra-high-strength polyethylene fibers¹¹ with a high elasticity coefficient (117 GPa) that makes them highly resistant to stretch and distortion⁶ and a high resistance to traction (3 GPa)⁶ that allows them to easily adapt to tooth morphology and dental-arch contours.¹² Ribbon fibers easily absorb water because of the “gas-plasma” treatment to which they are exposed. This treatment reduces the fibers’ superficial tension, ensuring a good chemical bond to composite materials.⁶ Ribbon is biocompatible, esthetic, translucent, practically colorless and disappears within the composite or acrylic without show-through.^{6,11-14} Ribbon fibers are also characterized by an impact strength five times higher than that of iron.⁶

Ribbon can be used in stabilizing traumatized teeth, restoring fractured teeth and creating a

fixed partial denture and for direct-bonded endodontic posts and cores, orthodontic fixed lingual retainers and space maintainers.^{3,4,6,12-22} Despite this versatility, there are few reports on the use of Ribbon in pediatric dentistry. Therefore, this case report aimed to present four different applications of Ribbon as an alternative procedure in pediatric dentistry.

CASE REPORTS

Case 1: Fixed space maintainer

A 7-year-old girl was referred to the pediatric dental clinic with an extracted primary maxillary right second molar. According to the patient’s parents, the molar had been extracted one month earlier (Figure 1a). Following clinical and radiographic examinations, the decision was made to create a fixed-space maintainer using Ribbon (Ribbon Inc., Seattle, WA, USA). The length of the dental arch between the neighboring teeth (54-16) was measured (21 mm), and the required length of 2-mm-wide Ribbon was cut with the special scissors supplied by the manufacturer to prevent unraveling. The Ribbon was wetted with Single Bond (3M/ESPE, St. Paul, MN, USA) and protected from exposure to light until ready for use. The palatal surfaces of the abutment teeth were cleaned with a non-fluoridated pumice paste, etched with 37% phosphoric acid (Etch-37 with BAC, Bisco, USA), rinsed and dried. Single Bond and a flowable composite resin (Aelite Flo, Bisco, Inc., Schaumburg, USA) were applied to the enamel surfaces, the Ribbon was placed, and slight pressure was applied using a rounded instrument to create close contact during the curing process. The Ribbon was coated with flowable composite, the excess composite was removed, and the composite was cured for 20 s using an LED curing unit (Elipar Free Light II, 3M/ESPE, St. Paul, MN, USA; light intensity:1000mV/cm²). The embrasures were shaped to facilitate good oral hygiene, and the composite was polished using a polishing disc (Figure 1b).

Case 2: Fixed partial denture with a natural tooth pontic

A 12-year-old girl was referred to the pediatric dental clinic with the chief complaint of having lost a permanent maxillary right lateral incisor. According to the parents, the tooth was jarred

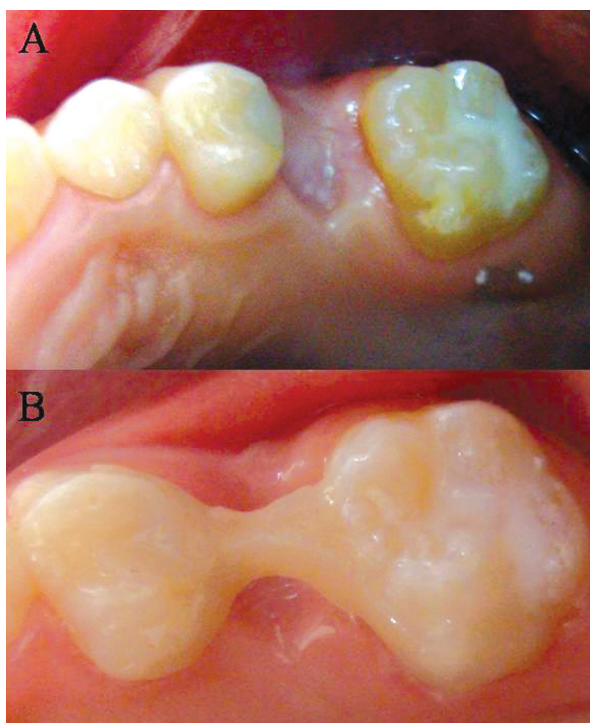


Figure 1 (A). Intraoral view of Case 1 before space maintainer application; (B). Occlusal view of the Ribbon fixed space maintainer.

from its socket as the result of a sports accident six days earlier. Immediately following the injury, the tooth was wrapped in a paper towel. Following clinical and radiographic examinations, the decision was made to create a fixed partial denture reinforced with Ribbond using the natural tooth as a pontic (Figure 2a). The root of the tooth was removed below the cemento-enamel junction, and the coronal pulp chamber was cleaned and filled with a light-cured composite resin (Z250, 3M/ESPE, St. Paul, MN, USA). The lingual surface of the crown was trimmed and polished. Following completion of etching and bonding procedures, a thin layer of flowable composite resin was applied (without curing) to the lingual and interproximal surfaces of the abutment teeth, a length of 2-mm-wide Ribbond was placed on the lingual surface of the teeth, and slight pressure was applied with a hand instrument to create close contact at the interproximal area. The excess resin composite was removed, and the Ribbond was light-cured for 20 s. The lingual surface of the pontic was then prepared for bonding. A thin layer of flowable composite was applied to the natural tooth pontic, which was placed in the desired position on the Ribbond and cured for 20 s (Figure 2b). The patient's occlusion was checked for premature contacts, and the resin composite was polished using a polishing disc (Figure 2c).

Case 3: Endodontic post and core

A 10-year-old girl was referred to the pediatric dental clinic with a complaint of dental caries. Intraoral and radiographic examination revealed hypoplasia of the mandibular left second premolar (Figure 3a,b). Treatment plan was developed that aimed to avoid any future malocclusion by maintaining the mandibular left second premolar for as long as possible, after which time an implant replacement would be inserted. Due to extensive damage to the tooth structure, the decision was made to restore the mandibular left second premolar tooth using an endodontic post. The endodontic procedure was performed, and the root canal was obturated using gutta-percha (Spident, SPI Dental Mfg. Inc, Korea) and Seal Apex sealer (Kerr, Italia). The post hole was shaped using Gates Glidden drills (Roydent, West Palm Beach, FL), cleaned with 5% sodium hypochlorite and dried. The depth of the post space was measured using a

periodontal probe, and two lengths of 3-mm-wide Ribbond were cut, each measuring twice the depth of the post space and 3-4 times the height of the core build-up. The root canal wall was etched for 15 s, washed for 30 s and then gently air-dried. Excess water was removed from the post space using paper points (Spident, SPI Dental Mfg. Inc, Korea). The adhesive system (Ed Primer II A&B) was applied using a microbrush in 2 consecutive coats and gently air-dried to evaporate the solvent. The Ribbond was wetted using a bonding agent, folded in a V-shape and coated with dual-curing resin cement (Panavia, Kuraray Medical Inc., Japan). The first piece of ribbon was then placed in the post space in a facial-lingual direction, and a second length of ribbon was placed inside the first piece at a right angle (Figure 3c). Excess resin cement

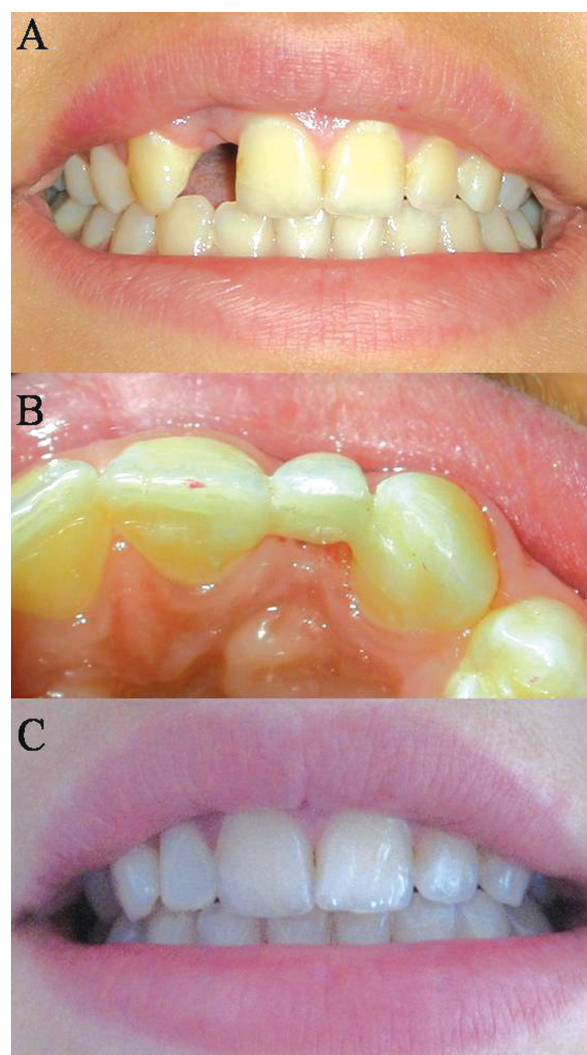


Figure 2 (A). Intraoral view of Case 2 at the first visit to the clinic; (B). Palatal view of polyethylene fiber-reinforced composite fixed partial denture; (C). Polyethylene fiber-reinforced composite fixed partial denture constructed with a natural tooth following anterior tooth trauma.

was removed, and the cement was cured for 20 s. The restorative procedure was completed by building up the tooth using Z250 composite resin (Figure 3d,e).

Case 4: Splint traumatized teeth

An 11-year-old girl was referred to the pediatric dental clinic two hours after a traumatic injury resulting from a sports accident. Clinical examination revealed subluxation and moderate mobility of the permanent maxillary central incisors. The decision was made to splint the primary canine and canine teeth for patient comfort using a 2-mm-wide strip of Ribbon. The labial surfaces of the teeth were etched, rinsed and dried, and Single Bond was applied. To insure semi-rigidity, the interproximal region was not etched or bonded. After applying a flowable composite to the enamel surfaces, the Ribbon was pressed through the composite against the teeth and cured. The Ribbon was then coated with additional flowable composite and cured again for 20 s (Figure 4a). Two weeks later, the Ribbon splint at the interproximals was cut with a diamond bur. Then, the splint was removed from the abutment by sliding a scalpel blade between the Ribbon and the teeth on the most distal end. The remaining adhesive

was removed with a tungsten carbide bur (Komet H284; Brasseler Co., Lemgo, Germany) in a low-speed handpiece under coolant water and surfaces were polished with disks (Figure 4b).

DISCUSSION

Not only do polyethylene fibers improve the impact and flexural strength and the modulus of elasticity of composite materials,⁶ they are barely visible within the resin matrix. For these reasons, polyethylene fibers appear to be the most appropriate and esthetic strengtheners of composite materials.^{8,23} This article presents 4 different applications of the polyethylene fiber Ribbon in pediatric dentistry.

Space maintainer

Various types of space maintainers can be used to avoid malocclusion as a result of premature loss of primary teeth. Removable appliances may be broken or lost, and they provide inadequate treatment results if not worn as prescribed.¹⁶ Properly designed, fixed appliances are not only less of a nuisance to the child patient than removable appliances, they are also less damaging to oral tissue.²⁴ Polyethylene fiber-reinforced composite used as a fixed space maintainer offers many advantages.

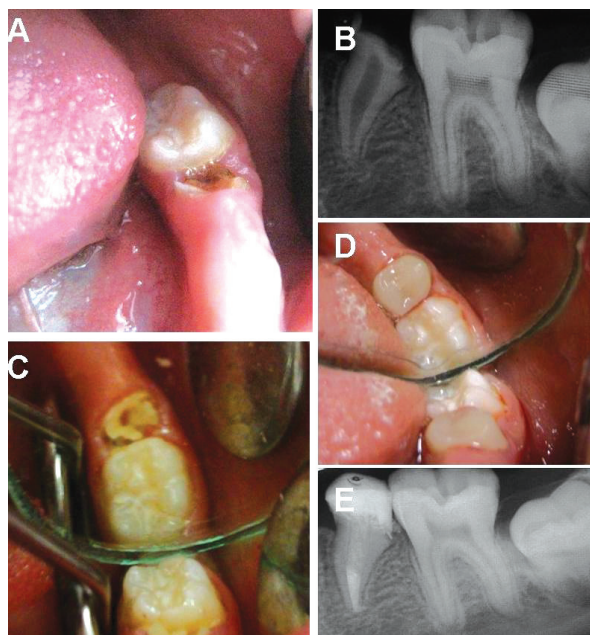


Figure 3 (A). Intraoral view of a hypoplastic mandibular left second premolar; (B). Radiographic appearance of hypoplastic mandibular left second premolar; (C). View of Case 3 after Ribbon has been inserted into the root canal; (D). Occlusal view of Case 3 after completion of Ribbon-composite endodontic post and core; (E). Final radiographic appearance of hypoplastic mandibular left second premolar.

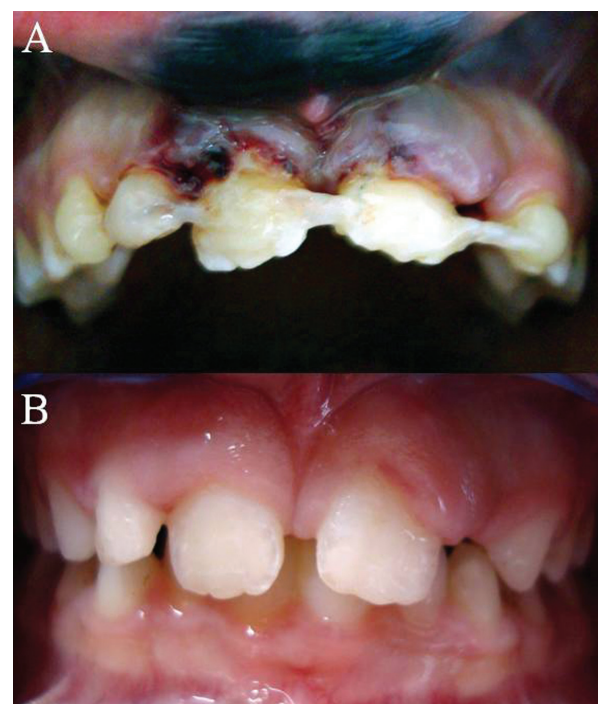


Figure 4. Frontal view of Case 4 after stabilization with a Ribbon-composite splint; (B). Frontal view of Case 4 after healing.

FRC has an esthetic appearance, is easily manipulated, can be quickly inserted in a single-visit procedure that requires no laboratory services, poses no risk of damage to abutment teeth and is easy to clean.^{16,17}

Fixed partial denture

The loss of maxillary incisors in childhood has always been problematic, requiring immediate attention to restore both esthetics and function.¹⁸ An FRC prosthesis can be used for fixed-tooth replacement following traumatic tooth loss in pediatric and adolescent patients. It is a more conservative treatment option than conventional fixed partial dentures and can be more cost-effective than other types of metal-free tooth replacements.^{19,20} A preliminary retrospective clinical study by Piovesan et al²⁵ suggested that polyethylene FRC fixed partial dentures (FPDs) could be a functional and esthetic alternative to replace a lost tooth. Unlu and Belli²⁶ concluded that polyethylene FRC FPDs functioned adequately during a mean clinical follow-up time of 3 years. In another report, a functional survival rate of 95% after a follow-up period of 4.3 years was described.²⁷ Also, for the child patients, this treatment could be considered as an interim treatment that can provide acceptable function and esthetics by replacing missing teeth and tissues until a definitive restoration can be performed.

The patient's natural tooth, an acrylic tooth, or composite resin can be used as a pontic. In the case reported here, good esthetics, availability, short working time and the possibility of direct chairside application dictated the use of the patient's natural tooth as the pontic.

Endodontic post and core

Developmental tooth hypoplasia represents a challenge to the dentist due to the difficulties involved in tooth restoration. Due to insufficient tooth structure, an endodontic post and core may be necessary to provide support to the restoration. Various types of FRC posts have recently come into widespread use as an alternative to cast or prefabricated metal posts in the restoration of endodontically treated teeth.²¹ Grandini et al²⁸ suggested that restoration of endodontically treated teeth with fiber post and direct resin composites is a treatment option, that in the short

term conserves remaining tooth structure and results in good patient compliance. In the case reported here, Ribbond was chosen for its esthetic properties and because its application required no additional tooth preparation.

Splint

Dental splinting is frequently needed following traumatic injury to stabilize subluxated, luxated, avulsed, or root-fractured teeth.²² Many different types of splinting techniques have been described in the literature.^{29,30} Ribbond can be used in the treatment of multiple displaced teeth. A Ribbond splint is esthetic, thin, smooth and non-irritating to the lip. This material is expensive and this is Ribbond's disadvantage.

CONCLUSIONS

Ribbond can be used as an alternative to conventional treatment in pediatric dentistry. However, long-term clinical studies are needed to evaluate the effects of prolonged use of Ribbond in pediatric dentistry.

ACKNOWLEDGEMENTS

The authors thank David N. Rudo (D.D.S.) for supplying the Ribbond needed to conduct this study.

REFERENCES

1. Meiers JC, Kazemi RB, Donadio M. The influence of fiber reinforcement of composite on shear bond strengths to enamel. *J Prosthet Dent* 2003;89:388-393.
2. Vallittu PK. Flexural properties of acrylic resin polymers reinforced with unidirectional and woven glass fibers. *J Prosthet Dent* 1999;81:318-326.
3. Vallittu PK, Sevelius C. Resin-bonded, glass fiber-reinforced composite fixed partial dentures: a clinical study. *J Prosthet Dent* 2000;84:413-418.
4. Ahlstrand WM, Finger WJ. Direct and indirect fiber-reinforced fixed partial dentures: case reports. *Quintessence Int* 2002;33:359-365.
5. Tezvergil A, Lassila LV, Vallittu PK. Strength of adhesive-bonded fiber-reinforced composites to enamel and dentin substrates. *J Adhes Dent* 2003;5:301-311.
6. Vitale MC, Caprioglio C, Martignone A, Marchesi U, Botticelli AR. Combined technique with polyethylene fibers and composite resins in restoration of traumatized anterior teeth. *Dent Traumatol* 2004;20:172-177.

7. Vallittu PK, Vojtkova H, Lassila VP. Impact strength of denture polymethyl methacrylate reinforced with continuous glass fibers or metal wire. *Acta Odontol Scand* 1995;53:392-396.
8. Uzun G, Hersek N, Tincer T. Effect of five woven fiber reinforcements on the impact and transverse strenght of a denture base resin. *J Prosthet Dent* 1999;81:616-620.
9. DeBoer J, Vermilyea SG, Brady RE. The effect of carbon fiber orientation on the fatigue resistance and bending properties of two denture resins. *J Prosthet Dent* 1984;51:119-121.
10. Berrong JM, Weed RM, Young JM. Fracture resistance of Kevlar-reinforced poly(methyl methacrylate) resin: a preliminary study. *Int J Prosthodont* 1990;3:391-395.
11. Ganesh M, Tandon S. Versatility of ribbond in contemporary practice. *Trends Biomater Artif Organs* 2006;20:53-58.
12. Karaman AI, Kir N, Belli S. Four applications of reinforced polyethylene fiber material in orthodontic practice. *Am J Orthod Dentofacial Orthop* 2002;121:650-654.
13. Miller TE. A new material for periodontal splinting and orthodontic retention. *Compendium* 1993;14:800-812.
14. Belli S, Ozer F. A simple method for single anterior tooth replacement. *J Adhes Dent* 2000;2:67-70.
15. Hornbrook DS, Hastings JH. Use of bondable reinforcement fiber for post and core build-up in an endodontically treated tooth: maximizing strength and aesthetics. *Prac Periodontics Aesthet Dent* 1995;7:33-44.
16. Kargul B, Caglar E, Kabalay U. Glass fiber-reinforced composite resin as fixed space maintainers in chidren: 12-month clinical follow-up. *J Dent Child* 2005;72:109-112.
17. Kirzioglu Z, Erturk MS. Success of reinforced fiber material space maintainers. *J Dent Child* 2004;71:158-162.
18. Chan DC, Giannini M, Goes MF. Provisional anterior tooth replacement using nonimpregnated fiber and fiber-reinforced composite resin materials: A clinical report. *J Prosthet Dent* 2006;95:344-348.
19. Vallittu PK. Survival rates of resin-bonded, glass fiber-reinforced composite fixed partial dentures with a mean follow-up of 42 months: a pilot study. *J Prosthet Dent* 2004;91:241-246.
20. Shuman IE. Replacement of a tooth with fiber-reinforced direct bonded restoration. *Gen Dent* 2000; 48:314-318.
21. Garoushi S, Vallittu PK, Lassila LV. Direct restoration of severely damaged incisors using short fiber-reinforced composite resin. *J Dent* 2007;35:731-736.
22. Yildirim Oz G, Ataoglu H, Kir N, Karaman AI. An alternative method for splinting of traumatized teeth: case reports. *Dent Traumatol* 2006;22:345-349.
23. Samadzadeh A, Kugel G. Fracture strengths of provisional restorations reinforced with plasma-treated woven polyethylene fiber. *J Prosthet Dent* 1997;78:447-449.
24. Qudeimat MA, Fayle SA. The longevity of space maintainers: a retrospective study. *Pediatr Dent* 1998;20:267-272.
25. Piovesan EM, Demarco FF, Piva E. Fiber-reinforced fixed partial dentures: a preliminary retrospective clinical study. *J Appl Oral Sci* 2006;14:100-104.
26. Unlu N, Belli S. Three-year clinical evaluation of fiber-reinforced composite fixed partial dentures using prefabricated pontics. *J Adhes Dent* 2006;8:183-188.
27. Freilich MA, Meiers JC, Duncan JP, Eckrote KA, Goldberg AJ. Clinical evaluation of fiber-reinforced fixed bridges. *J Am Dent Assoc* 2002;133:1524-1534.
28. Grandini S, Goracci C, Tay FR, Grandini R, Ferrari M. Clinical evaluation of the use of fiber posts and direct resin restorations for endodontically treated teeth. *Int J Prosthodont* 2005;18:399-404.
29. Ebeleseder KA, Glockner K, Pertl C, Städtler P. Splints made of wire and composite: an investigation of lateral tooth mobility in vivo. *Endod Dent Traumatol* 1995;11:288-293.
30. von Arx T, Filippi A, Lussi A. Comparison of a new dental trauma splint device (TTS) with three commonly used splinting techniques. *Dent Traumatol* 2001;17:266-274.