

External iliac vein aneurysm treated via balloon-assisted aneurysmorrhaphy with a contemporary review of the literature

Kyle W. Prochno, BA,^a Michael Qaqish, MD,^b Dawn M. Salvatore, MD,^b Babak Abai, MD,^b Paul J. DiMuzio, MD, MBA,^b and Michael J. Nooromid, MD,^b Philadelphia, PA

ABSTRACT

Isolated external iliac vein aneurysm is exceedingly rare, not well-described in the literature, and presents several potential surgical approaches. Herein, we describe the case of a 72-year-old woman who presented with incidentally found 4.3 cm × 3.4 cm × 5.6 cm right external iliac vein aneurysm after undergoing magnetic resonance imaging for orthopedic work-up. She was treated via parallel supra- and infra-inguinal incisions and novel combination of primary aneurysmorrhaphy with intraluminal balloon mandrel-assisted closure. The patient was discharged on postoperative day two, and 6-month follow-up ultrasound showed a normal caliber vessel with normal compressibility, suggesting this technique is safe and effective for appropriately selected patients. (*J Vasc Surg Cases Innov Tech* 2022;8:698-700.)

Keywords: Aneurysm; Aneurysmorrhaphy; Balloon; External iliac vein; Iliac vein

Venous aneurysms can occur anywhere throughout the body, but are an uncommon occurrence overall.¹ Aneurysmal disease of the iliac venous system in particular is exceedingly rare, and the least likely anatomic location for venous aneurysm formation—to date, just over 50 cases have been reported in the literature.² Of this small subset, 31 had isolated aneurysms located in the external iliac vein, with a smaller number having isolated common or internal iliac vein aneurysms or some combination. The etiology of iliac venous aneurysm in the majority of men is traumatic arteriovenous fistula (AVF), whereas for the majority of women, it is primary aneurysm; the most common etiology overall is AVF of any type.²

Diagnostic modalities for iliac vein aneurysms are several, and include duplex ultrasound, conventional venography, computed tomography venography, and magnetic resonance venography—with additional arterial imaging where appropriate, such as in suspected AVF.^{1,3} It is yet unclear which of these methods may be superior, and although venography may allow for the

highest fidelity visualization, it may also introduce an increased risk of iatrogenic rupture.²

For patients ultimately diagnosed with iliac vein aneurysm, it is common for this to occur as a result of incidental finding on imaging.⁴⁻⁷ Presentation of this rare pathology varies widely and occurs across the second to eighth decades of life, with patients most commonly experiencing limb swelling or pain.^{2,8} Asymptomatic presentation is common, whereas others may present with feared sequelae of either pulmonary embolism or rupture/shock.^{2,9} Presentation less commonly may mimic groin hernias, lymphadenopathy, or urinary tract pathology.¹⁰

Herein, we describe a case of incidentally found primary right external iliac vein aneurysm extending beneath the inguinal ligament treated via balloon-assisted aneurysmorrhaphy utilizing two parallel oblique supra- and infra-inguinal ligament-sparing incisions. Patient consent for case and image publication was obtained.

CASE REPORT

A 72-year-old woman with a past medical history of hypertension, hyperlipidemia, diabetes mellitus type 2, osteoporosis, and bilateral knee arthroplasties originally presented to her primary care physician with complaints of right groin pain. The pain had been present for approximately 3 to 4 months and was mostly felt when transitioning from a sitting to a standing position. She was first referred to orthopedic surgery to evaluate for hip pain. A magnetic resonance imaging showed a 2.8-cm right external iliac vein aneurysm, but the study was of poor quality. She was then referred for vascular surgery evaluation. A computed tomographic venogram was performed, showing a 4.3 cm × 3.4 cm × 5.6 cm right external iliac vein aneurysm without thrombus, as seen in Fig 1. The patient reported no prior surgical or medical history to suggest a likely etiology for her aneurysm. Although it was unlikely to be the cause of her pain, a discussion was initiated regarding surgical intervention

From the Sidney Kimmel Medical College at Thomas Jefferson University, Philadelphia^a; and the Division of Vascular and Endovascular Surgery, Department of Surgery, Thomas Jefferson University Hospital, Philadelphia.^b

Author conflict of interest: none.

Correspondence: Michael J. Nooromid, MD, Division of Vascular and Endovascular Surgery, Department of Surgery, Thomas Jefferson University Hospital, 111 S 11th St, Ste 6210, Philadelphia, PA 19107 (e-mail: michael.nooromid@jefferson.edu).

The editors and reviewers of this article have no relevant financial relationships to disclose per the Journal policy that requires reviewers to decline review of any manuscript for which they may have a conflict of interest.

2468-4287

© 2022 The Authors. Published by Elsevier Inc. on behalf of Society for Vascular Surgery. This is an open access article under the CC BY-NC-ND license (<http://creativecommons.org/licenses/by-nc-nd/4.0/>).

<https://doi.org/10.1016/j.jvscit.2022.09.014>

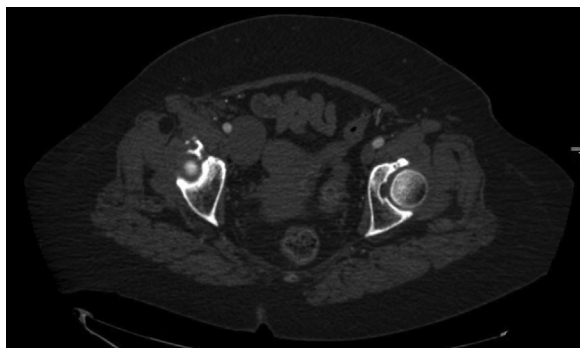


Fig 1. Computed tomography venogram showing 4.3 cm × 3.4 cm × 5.6 cm right external iliac vein aneurysm.

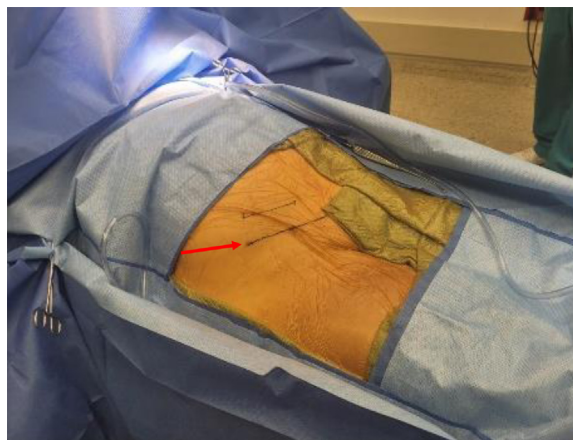


Fig 2. Patient placed supine with the right abdomen and groin prepped; the red arrow marks the location of the inguinal ligament.

given the size and concern for potential thrombosis, embolization, and rupture. The patient was subsequently scheduled for elective repair with plan for aneurysmorrhaphy vs interposition graft.

To establish and maintain adequate proximal and distal control of the vessel, it was determined that both a supra-inguinal and infra-inguinal incision would be required, as seen in Fig 2. First, the infra-inguinal oblique incision was made, and the common femoral vein was dissected out circumferentially to gain control proximal to the saphenofemoral junction. Silastic vessel loops were placed around the vein, and the supra-inguinal oblique incision was made to access the retroperitoneal space. The right external iliac vein was then dissected and controlled with a vessel loop, just distal to the common iliac vein bifurcation, as shown in Fig 3, A-D. Once proximal and distal control of the vein had been established, the patient was heparinized, and the vein was clamped.

Once the aneurysmal segment of the vein was dissected from the surrounding tissues, the vein was opened longitudinally. The posterior wall had a normal appearance, and the decision was made to resect the thinned-out anterior wall and close the vein primarily. A 12-mm balloon was placed intraluminally to facilitate sizing the vein closure, and 4-0 Prolene (Ethicon, Cincinnati, OH) suture was used to close the anterior wall of the external iliac vein in a running fashion. There was good hemostasis on completion and adequate caliber of the repaired vein segment. The patient was closed and admitted for postoperative monitoring. She was discharged on postoperative day two after an uneventful hospital course. A 6-month follow-up ultrasound showed a normal caliber right external iliac vein measuring 1.4 cm × 1.1 cm with normal compressibility.

DISCUSSION

Management of iliac vein aneurysm may be either conservative or operative, with no widely accepted standard criteria, and, as such, will be dictated by patient characteristics, presenting symptoms, and anatomical location of the aneurysm, as well as surgeon judgement and risk assessment. The majority of cases in the literature describe operative management techniques—of 31 patients reported as presenting with isolated external iliac

vein aneurysms, 21 were treated via open surgery and another three were treated endovascularly—though this may represent a component of publication bias.^{1,2} Nonetheless, operative intervention is commonly advocated to decrease the likelihood of the predictable yet devastating outcomes of aneurysm rupture, pulmonary embolism, or paradoxical thromboembolism, all of which have been described.^{9,11,12} Open repair, however, carries a not-insignificant risk of hemorrhage, given the anatomic location and course of the iliac venous system.¹³

Regarding operative intervention, multiple open techniques have been described, the choice of which is dependent upon aneurysm etiology, extent, and location.⁵ Those arising secondary to AVF may be treated with simple AVF ligation, and have more recently been treated via arterial stent graft placement for select cases.^{3,9} Aneurysm resection is the common treatment modality for primary aneurysm and can be completed using venous interposition graft, patch venoplasty, or venous aneurysmorrhaphy.² Cases utilizing stenting, coil embolization, staple plication with balloon assistance, and primary ligation have also been described.^{2,12-16}

The operative technique described in this case, to our knowledge, is a novel approach to the repair of isolated external iliac venous aneurysm that utilizes a combination of previously described techniques. The combination of supra- and infra-inguinal oblique incisions enables sparing of the inguinal ligament while maintaining adequate proximal and distal vessel control, thus providing a safe technique, which also may facilitate reduced postoperative pain and earlier patient ambulation compared with an approach requiring division of the ligament or a longitudinal incision for femoral cutdown. The use of an intraluminal balloon mandrel has been previously described in the setting of staple plication,¹⁶ but to our knowledge, this is the first use of an intraluminal balloon to facilitate primary aneurysmorrhaphy closure using running suture.

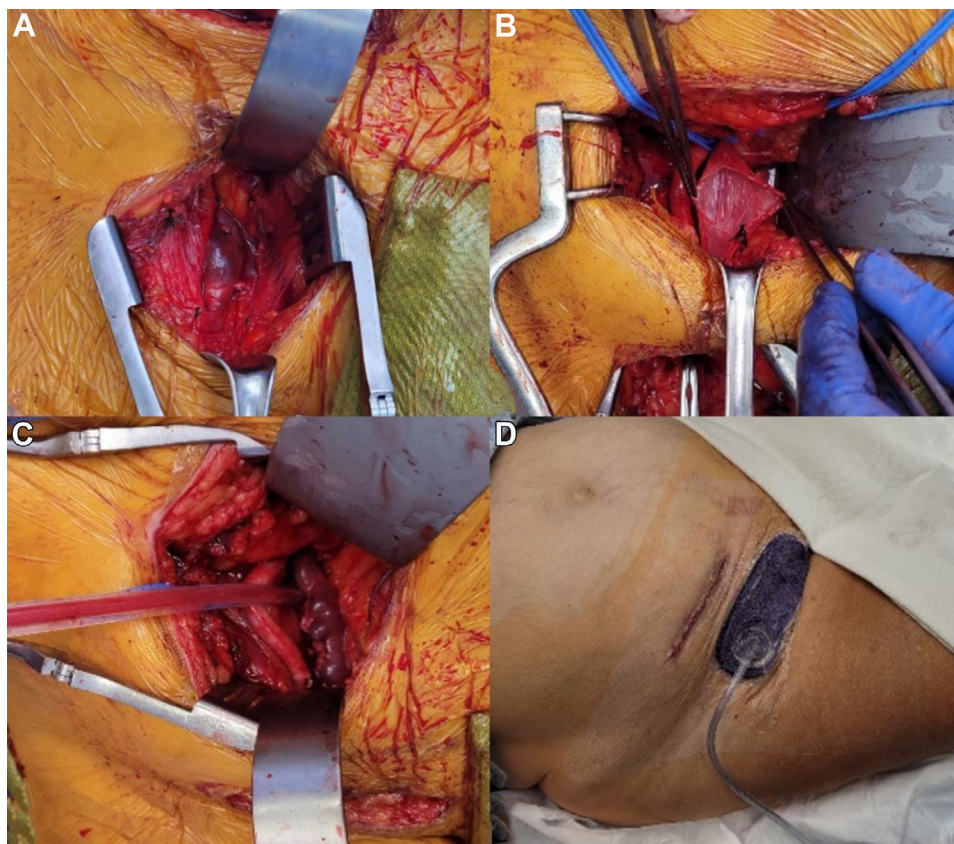


Fig 3. **A**, Right external iliac vein aneurysm prior to repair; **B**, Longitudinally opened aneurysm showing clean and normal appearing posterior wall; **C**, Vein post-closure following use of intraluminal 12-mm balloon; **D**, Primary closure of suprainguinal incision with skin glue and primary closure of infrainguinal incision with vacuum dressing.

Finally, this case also corroborates prior reports that open repair of asymptomatic external iliac vein aneurysm is safe and effective in the hands of an experienced surgeon for the prevention of possible future complications or mortality resulting from the formation and migration of embolism or aneurysm rupture.

REFERENCES

1. Teter KA, Maldonado TM, Adelman MA. A systematic review of venous aneurysms by anatomic location. *J Vasc Surg Venous Lymphat Disord* 2018;6:408-13. Erratum in: *J Vasc Surg Venous Lymphat Disord* 2018;6:563.
2. Zarrintan S, Tadayon N, Kalantar-Motamedi SMR. Iliac vein aneurysms: a comprehensive review. *J Cardiovasc Thorac Res* 2019;11:1-7.
3. Gabriel S, Eisenberg N, Kim D, Jaber A, Roche-Nagle C. Primary venous aneurysms: A 20-year retrospective analysis. *Vascular* 2020;28:577-82.
4. Tetik O, Ergunes K, Yurekli I, Gokalp O, Bademci M, Aslan O, et al. Surgical treatment of a giant external-iliac-vein aneurysm in a patient with a post-traumatic femoral arteriovenous fistula. *Tex Heart Inst J* 2011;38:187-90.
5. Kotsis T, Mylonas S, Katsenis K, Arapoglou V, Dimakakos P. External iliac venous aneurysm treated with tangential aneurysmectomy and lateral venorrhaphy: a case report and review of the literature. *Vasc Endovascular Surg* 2008;42:615-9.
6. DeWane MP, Fares WH, Ochoa Chaar CI. Endovascular treatment of a large iliac vein aneurysm and high-flow arteriovenous fistula. *Ann Vasc Surg* 2018;53:266.e5-7.
7. Banno H, Yamanouchi D, Fujita H, Nagata J, Kobayashi M, Matsushita M, et al. External iliac venous aneurysm in a pregnant woman: a case report. *J Vasc Surg* 2004;40:174-8.
8. Ahmad Z, Shabir S, Ilyas M, Gojwari T. External iliac vein aneurysm due to arteriovenous fistula between popliteal artery and popliteal vein—a rare entity. *Indian J Thorac Cardiovasc Surg* 2018;34:435-6.
9. Park JS, Kim JY, Kim M, Park SC, Lee KY, Won YS. Ruptured aneurysm of the external iliac vein. *J Vasc Surg Venous Lymphat Disord* 2016;4:92-4.
10. Fanshawe AE, Hamilton HEC, Constantinou J. External iliac vein aneurysm: a case report and review of the literature. *J Surg Case Rep* 2018;2018:rjy115.
11. Calligaro KD, Ahmad S, Dandora R, Dougherty MJ, Savarese RP, Doerr KJ, et al. Venous aneurysms: surgical indications and review of the literature. *Surgery* 1995;117:1-6.
12. Shah SK, Shah KB, Clair DC. External iliac vein aneurysm as a cause of paradoxical embolism. *J Vasc Surg Venous Lymphat Disord* 2015;3:322-4.
13. Chang K, Quinones-Baldrich W, Kwon M, Archie M, Finn P. Repair of a large iliac vein aneurysm secondary to a high-flow pelvic arteriovenous malformation under deep hypothermic circulatory arrest. *J Vasc Surg Venous Lymphat Disord* 2019;7:258-9.
14. Todorov M, Hernandez D. Endovascular exclusion of a large external iliac vein aneurysm. *J Vasc Surg Venous Lymphat Disord* 2013;1:301-3.
15. Cookson D, Hawkins S, O'Donoghue B, Mahadevan G. Percutaneous endovascular repair of an external iliac vein aneurysm in a patient with multiple arteriovenous fistulae. *J Vasc Interv Radiol* 2019;30:1706-9.e3.
16. Jayaraj A, Meissner M. Novel repair of an external iliac vein aneurysm. *Ann Vasc Surg* 2012;26:859.e13-5.

Submitted Aug 8, 2022; accepted Sep 27, 2022.