

Ocrelizumab-induced alopecia areata—A series of five patients from Ontario, Canada: A case report

SAGE Open Medical Case Reports
JCMS Case Reports
Volume 8: 1–3
© The Author(s) 2020
Article reuse guidelines:
sagepub.com/journals-permissions
DOI: 10.1177/2050313X20919614
journals.sagepub.com/home/sco



Laura D Chin¹ and Mohn'd AbuHilal²

Abstract

Background: Ocrelizumab is a humanized monoclonal antibody that targets the CD20 antigen found on B-cells. It is indicated in the treatment of both relapsing–remitting multiple sclerosis and primary progressive multiple sclerosis.

Objective: The aim of this study is to report and describe the characteristics of alopecia areata following treatment with ocrelizumab for multiple sclerosis.

Results: Five patients were reported, two female and three male. Four of the five patients had alopecia areata of the scalp, one of the five having alopecia to the beard area. All patients responded well to conventional treatment with topical and intralesional corticosteroids and topical minoxidil foam. Ocrelizumab can be associated with the development of alopecia areata. Initiation of proper treatment may lead to quick improvement or resolution of this potentially reversible adverse effect.

Keywords

Ocrelizumab, alopecia areata, multiple sclerosis, alopecia, hair loss, anti-CD20, monoclonal antibody

Introduction

Ocrelizumab is a humanized monoclonal antibody that targets the CD20 antigen found on B-cells.¹ It acts to deplete the human body's B-cell stores by enhancing antibody-dependent cellular cytotoxicity and, to a lesser extent, complement-dependent cytotoxicity with a half-life of 26 days.^{1–4} It is indicated in the treatment of both relapsing–remitting multiple sclerosis (RRMS) and primary progressive multiple sclerosis (PPMS). Ocrelizumab is given as two 300 mg infusions separated by 14 days, with subsequent 600 mg doses every 6 months. Patients receive premedication with methylprednisolone (or equivalent) and an antihistamine.⁵ Reported side effects of ocrelizumab include infusion-related reactions, depression, pain to the extremities, and peripheral edema.⁶ Patients on ocrelizumab also have increased risk of infections and malignancy.^{1,6,7}

Alopecia areata (AA) is an autoimmune disorder that causes non-scarring hair loss. AA is clinically characterized by well-demarcated round to oval patches of alopecia, most commonly on the scalp but can involve other areas such as the beard, eyebrows, or eyelashes.⁸ Alopecia is a known side effect of immunomodulatory and chemotherapy agents used in multiple sclerosis (MS), such as teriflunomide and mitoxantrone.^{9,10} AA has also been reported as a side effect of other monoclonal antibody therapies for MS, including anti-CD52

agent, alemtuzumab, and anti-CD25 agent, daclizumab,^{11–13} but has not yet been documented as a side effect of ocrelizumab. There are also no reports of any anti-CD20 monoclonal antibody therapies inducing AA in the literature. On the contrary, there are several reports of anti-CD20 agent, rituximab, reducing risk of alopecia in lymphoma management as well as resolving cases of frontal fibrosing alopecia.^{14–16}

Here, we report a case series in which five patients diagnosed with MS developed AA following initiation of ocrelizumab.

Case presentations

Five patients presented to the dermatology clinic with new-onset patches of AA within 4 months of starting treatment with ocrelizumab for MS. Summaries of each patient case can be found in Table 1. Each patient's AA fully recovered following combined treatments of intralesional triamcinolone

¹Cumming School of Medicine, University of Calgary, Calgary, AB, Canada

²Division of Dermatology, Department of Medicine, McMaster University, Hamilton, ON, Canada

Corresponding Author:

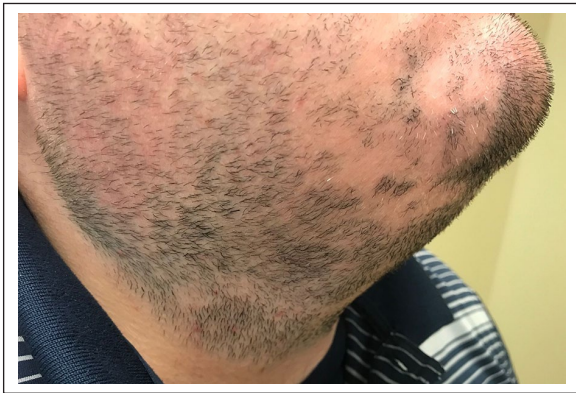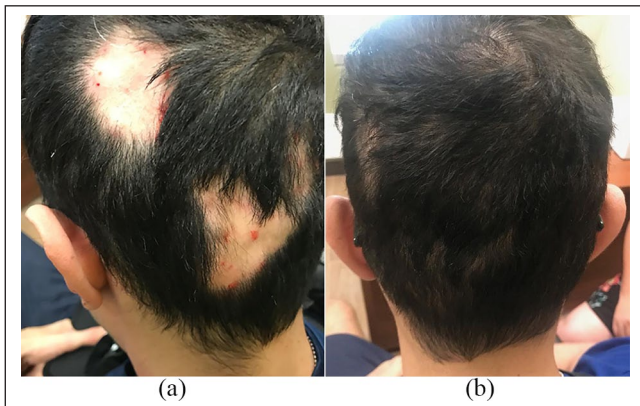
Laura D Chin, Cumming School of Medicine, University of Calgary, Calgary, AB T2N 1N4, Canada.
Email: laura.chin@ucalgary.ca



Table 1. Summary of patients who developed AA following ocrelizumab treatment for multiple sclerosis.

Patient	Age	Sex	MS subtype	Date ocrelizumab received	AA site	Onset to AA (months)	Concurrent medical conditions	AA treatment
1	42	Male	RRMS	January 2019	Beard	3	Hypothyroidism	ILK, BMV, Minoxidil
2	43	Male	Unspecified	December 2018	Scalp	4	None	ILK, BMV, Minoxidil
3	33	Male	PPMS	November 2018	Scalp	4	None	ILK, BMV, Minoxidil
4	31	Female	PPMS	February 2018	Scalp	3	None	ILK, BMV, Minoxidil
5	26	Female	RRMS	January 2018	Scalp	2	Hypothyroidism	ILK, BMV, Minoxidil

AA: alopecia areata; MS: multiple sclerosis; RRMS: relapsing–remitting multiple sclerosis; ILK: intralesional Kenalog (triamcinolone acetate) injections (concentrations ranged from 3 to 8 mg/mL); BMV: betamethasone valerate topical solution (0.1%, applied daily); Minoxidil (5% foam, applied nightly); PPMS: primary progressive MS.

**Figure 1.** Patches of alopecia areata of the beard of patient 1 before treatment.**Figure 2.** (a) Multiple patches of alopecia areata on the scalp of patient 3 immediately after first intralesional triamcinolone acetate injections. (b) Scalp of patient 3 eight weeks after one session of intralesional triamcinolone acetate injection and treatment with once daily betamethasone valerate 0.1% lotion and once daily minoxidil 5% foam application.

acetate injections (concentrations ranged from 3 to 8 mg/mL), topical betamethasone valerate 0.1% lotion, and 5% minoxidil foam, all of which are standard treatment of patchy AA (Figures 1 and 2).

Discussion

Despite the extensive list of adverse effects of ocrelizumab in the treatment of MS, AA has not yet been reported as a side effect of the medication from the OPERA I/II and ORATORIO studies that assessed the efficacy and safety of ocrelizumab in RRMS and PPMS, respectively,¹⁷ or on the Food and Drug Administration or Health Canada product monograph for ocrelizumab.¹⁸ In fact, no autoimmune diseases have been reported as adverse effects of ocrelizumab.^{6,7,18,19} AA has been reported as a side effect of other disease-modifying treatments, including teriflunomide, mitoxantrone, alemtuzumab, and daclizumab,^{9–13} which are also used in the treatment of RRMS. However, to our knowledge, there have been no reports documenting the occurrence of AA following treatment with ocrelizumab in the management of MS or other diseases as of yet.

The prevalence of AA in the general global population is approximately 1.7% to 2.1%.^{8,20} It is possible that the diagnosis of AA in our patients presented was unrelated pathologically from ocrelizumab administration, as both AA and MS are autoimmune processes. However, the onset of AA within a few weeks to months of starting ocrelizumab treatment as well as the highly reported side effect of AA following other disease-modifying therapies in the treatment of MS makes it difficult to ignore the likelihood of ocrelizumab treatment being a causative factor in the development of AA in these cases.

In cases of AA development following alemtuzumab (an anti-CD52 treatment for both RRMS and chronic lymphocytic leukemia), secondary autoimmunity as a result of lymphocyte reconstitution has been a commonly proposed mechanism.^{11,12,21} Although the pathogenesis of this potential ocrelizumab side effect is currently unclear, it is possible that the pathology of AA development following ocrelizumab mirrors the secondary autoimmunity mechanism illustrated in research around alemtuzumab.

Although a confirmed causative relationship between ocrelizumab and AA in these cases cannot be proven, the cosmetic and psychosocial impact on patients cannot be overlooked.^{8,22} Therefore, both physician and patient awareness of this potential side effect are important. Since

discontinuing ocrelizumab may not be feasible from an MS management standpoint, prompt diagnosis and initiation of treatment for AA may lead to quick improvement or resolution of this potentially reversible adverse effect, leading to improved patient quality of life and reduced morbidity.

Declaration of conflicting interests

The author(s) declared no potential conflicts of interest with respect to the research, authorship, and/or publication of this article.

Funding

The author(s) received no financial support for the research, authorship, and/or publication of this article.

Informed consent

The patients included in this report provided consent for publication of the case report.

References

- Juanatey A, Blanco-Garcia L and Tellez N. Ocrelizumab: its efficacy and safety in multiple sclerosis. *Rev Neurol* 2018; 66(12): 423–433.
- Milo R. Therapies for multiple sclerosis targeting B cells. *Croat Med J* 2019; 60(2): 87–98.
- Ancau M, Berthele A and Hemmer B. CD20 monoclonal antibodies for the treatment of multiple sclerosis: up-to-date. *Expert Opin Biol Ther* 2019; 19(8): 829–843.
- Kausar F, Mustafa K, Sweis G, et al. Ocrelizumab: a step forward in the evolution of B-cell therapy. *Expert Opin Biol Ther* 2009; 9(7): 889–95.
- Elliott W and Chan J. Ocrelizumab injection (ocrevus). *Intern Med Alert* 2017; 39(9).
- Rommer PS and Zettl UK. Managing the side effects of multiple sclerosis therapy: pharmacotherapy options for patients. *Expert Opin Pharmacother* 2018; 19(5): 483–498.
- Hauser SL, Bar-Or A, Comi G, et al. Ocrelizumab versus interferon beta-1a in relapsing multiple sclerosis. *N Engl J Med* 2017; 376(3): 221–234.
- Pratt CH, King LEJ, Messenger AG, et al. Alopecia areata. *Nat Rev Dis Prim* 2017; 3: 17011.
- O'Connor P, Wolinsky JS, Confavreux C, et al. Randomized trial of oral teriflunomide for relapsing multiple sclerosis. *N Engl J Med* 2011; 365(14): 1293–1303.
- Martinelli Boneschi F, Vacchi L, Rovaris M, et al. Mitoxantrone for multiple sclerosis. *Cochrane Database Syst Rev* 2013; 5: CD002127.
- Zimmermann J, Buhl T and Muller M. Alopecia Universalis following alemtuzumab treatment in multiple sclerosis: a barely recognized manifestation of secondary autoimmunity—report of a case and review of the literature. *Front Neurol* 2017; 8: 569.
- Alcala C, Pzere-Miralles F, Gascon F, et al. Recurrent and universal alopecia areata following alemtuzumab treatment in multiple sclerosis: a secondary autoimmune disease. *Mult Scler Relat Disord* 2019; 27: 406–408.
- Oh J, Saidha S, Cortese I, et al. Daclizumab-induced adverse events in multiple organ systems in multiple sclerosis. *Neurology* 2014; 82(11): 984–988.
- Kerl K, Prins C, Saurat JH, et al. Intralesional and intravenous treatment of cutaneous B-cell lymphomas with the monoclonal anti-CD20 antibody rituximab: report and follow-up of eight cases. *Br J Dermatol* 2006; 155(6): 1197–1200.
- Tavakolpour S, Mahmoudi H, Abedini R, et al. Frontal fibrosing alopecia: an update on the hypothesis of pathogenesis and treatment. *Int J Womens Dermatol* 2019; 5(2): 116–123.
- Imai Y, Isoda K, Ito E, et al. Primary cutaneous follicle center cell lymphoma of the scalp successfully treated with anti CD20 monoclonal antibody and CHOP combination therapy with no subsequent permanent loss of hair. *J Dermatol* 2003; 30(9): 683–688.
- Mayer L, Kappos L, Racke MK, et al. Ocrelizumab infusion experience in patients with relapsing and primary progressive multiple sclerosis: results from the phase 3 randomized OPERA I, OPERA II, and ORATORIO studies. *Mult Scler Relat Disord* 2019; 30: 236–243.
- OCREVUS (ocrelizumab) injection, 2017, https://www.accessdata.fda.gov/drugsatfda_docs/label/2017/7610531bl.pdf (accessed 3 January 2020).
- Montalban X, Hauser SL, Kappos L, et al. Ocrelizumab versus placebo in primary progressive multiple sclerosis. *N Engl J Med* 2017; 376(3): 209–220.
- Anzai A, Wang EHC, Lee EY, et al. Pathomechanisms of immune-mediated alopecia. *Int Immunol* 2019; 31(7): 439–447.
- Costelloe L, Jones J and Coles A. Secondary autoimmune diseases following alemtuzumab therapy for multiple sclerosis. *Expert Rev Neurother* 2012; 12(3): 335–341.
- Matzer F, Egger JW and Kopera D. Psychosocial stress and coping in alopecia areata: a questionnaire survey and qualitative study among 45 patients. *Acta Derm Venereol* 2011; 91(3): 318–327.