

Hand-arm vibration syndrome: A rarely seen diagnosis

Rebecca A. Campbell, BA, Matthew R. Janko, MD, and Robert I. Hacker, MD, FACS, *Cleveland, Ohio*

ABSTRACT

Hand-arm vibration syndrome (HAVS) is a collection of sensory, vascular, and musculoskeletal symptoms caused by repetitive trauma from vibration. This case report demonstrates how to diagnose HAVS on the basis of history, physical examination, and vascular imaging and its treatment options. A 41-year-old man who regularly used vibrating tools presented with nonhealing wounds on his right thumb and third digit. Arteriography revealed occlusions of multiple arteries in his hand with formation of collaterals. We diagnosed HAVS, and his wounds healed after several weeks with appropriate treatment. HAVS is a debilitating condition with often irreversible vascular damage, requiring early diagnosis and treatment. (*J Vasc Surg Cases and Innovative Techniques* 2017;3:60-2.)

Hand-arm vibration syndrome (HAVS) is a potential health hazard to workers in any occupation involving repetitive use of vibrating tools. HAVS is a collection of sensory, vascular, and musculoskeletal symptoms caused by repetitive trauma from vibration. The vascular abnormalities are due to arterial spasm, stenosis, and occlusion; injury to the intima, leading to thrombosis; and injury to the media, leading to aneurysm formation.^{1,2} The first symptoms are usually neurologic with numbness and tingling, whereas vascular manifestations typically present later and involve periodic ischemic episodes triggered by cold or stress. The nonused extremity is normal.^{1,3}

Several diagnoses must be considered when one is confronted with isolated pathologic changes in the hand: peripheral arterial disease, embolism from a central source, autoimmune hypercoagulability, Buerger disease, hypothenar hammer syndrome (HHS), and thenar hammer syndrome (THS). HHS is caused by stenosis or occlusion of the ulnar artery as it passes over the hamate bone due to single or repetitive blunt trauma to this area.⁴ THS is caused by damage to the radial artery at the wrist and presents similarly to HHS except in a thenar distribution.⁵ Differentiation of HAVS, HHS, and THS is based on a complete history and guided by clinical suspicion.

Our aim was to report a case of HAVS with digital artery thrombosis in a patient who consented to appear in this study. HAVS should be suspected whenever vascular or neurologic damage of the hands is present in a worker exposed to vibration. HAVS can be identified with a combination of occupational history, neurovascular symptoms, and vascular imaging.

CASE REPORT

This 41-year-old right-handed man presented to a vascular clinic in 2015 with nonhealing wounds on his right thumb and third digit that had been present for 5 months. Before noticing the ulcerations, he had been experiencing numbness and tingling in his right hand. His left hand was asymptomatic. He had no past medical history. He had no history of previous Raynaud phenomenon or symptoms before this event, and no other extremities were affected. His significant past surgical history included bilateral rotator cuff repairs and bilateral carpal tunnel releases. He was a current smoker with a 5 pack-year smoking history. As a plumber, he reported on average 20 hours of power tool use a week, including jackhammers, drills, and power saws. Although some tools are two handed, he described primarily using his dominant right hand with the left hand for stabilization.

On examination, he had a normal right brachial pulse with a diminished right radial pulse and a monophasic right radial artery signal. A 1.5-cm wound with 0.25-cm eschar on his right third digit and a 0.25-cm dry eschar on his right thumb were found. His examination was otherwise unremarkable. Results of laboratory studies, including erythrocyte sedimentation rate, C-reactive protein level, antiphospholipid antibody, antinuclear antibody titer, lupus anticoagulant, gene 2021A mutation, and factor V Leiden, were all normal.

Noninvasive vascular studies showed normal brachial pressures, wrist-brachial indices, radial indices, and ulnar indices bilaterally. Finger pressures were unable to be performed at our hospital but would have been included in his preoperative workup if available. Angiography was chosen as the next step because of his symptoms. Computed tomography (CT) angiography demonstrated patent arteries from the thoracic arch to

From the Case Western Reserve School of Medicine, MetroHealth Hospital.

Author conflict of interest: none.

Presented as a poster at the Thirtieth Annual Meeting of the Eastern Vascular Society, Philadelphia, Pa, September 15-17, 2016.

Correspondence: Robert Hacker, MD, FACS, Vascular Surgery, MetroHealth Medical Center, 2500 MetroHealth Dr, Cleveland, OH 44109 (e-mail: roberthackermd@gmail.com).

The editors and reviewers of this article have no relevant financial relationships to disclose per the Journal policy that requires reviewers to decline review of any manuscript for which they may have a conflict of interest.

2468-4287

© 2017 The Authors. Published by Elsevier Inc. on behalf of Society for Vascular Surgery. This is an open access article under the CC BY-NC-ND license (<http://creativecommons.org/licenses/by-nc-nd/4.0/>).

<http://dx.doi.org/10.1016/j.jvscit.2017.01.002>

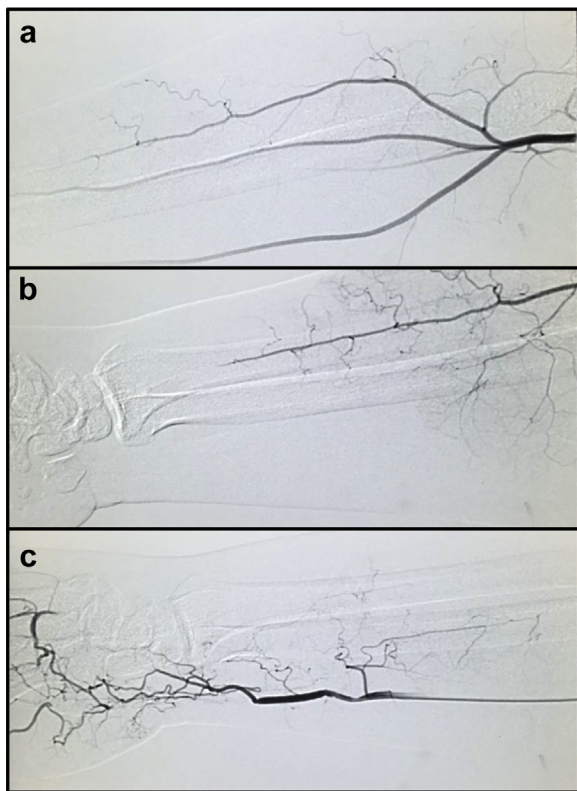


Fig 1. Right upper extremity arteriogram demonstrating (a) patent radial, ulnar, and interosseous arteries at the distal forearm, (b) occlusion of the radial artery before the wrist, and (c) occlusion of the ulnar artery proximal to the wrist with collaterals providing blood supply to the lateral aspect of the hand.

the right wrist. Selective right arm arteriography showed normal ulnar, radial, and interosseous arteries in the proximal right forearm (Fig 1, a). Distally, there was occlusion of the radial artery before the wrist (Fig 1, b). The interosseous artery appeared to feed the medial aspect of the hand normally supplied by the radial artery. The ulnar artery was occluded proximal to the wrist (Fig 1, c). Collaterals arising from the ulnar and interosseous arteries provided blood supply. The superficial and deep palmar arches were patent in two small areas (Fig 2). These occlusions were consistent with arterial thrombosis, but no source was found in the proximal arteries on arteriography, CT angiography, or echocardiography. The left arm was not imaged because of his lack of physical examination findings and symptoms.

Given the microvasculature involvement, this patient's disease was not amenable to surgery. We provided medical management to prevent further damage, including topical nitroglycerin and a calcium channel blocker. We also recommended cessation of smoking and use of vibrating tools. Because he was the owner of the business, the patient agreed to abstain from all tool use and to delegate responsibility. At his 1-month follow-up, the patient reported that he was compliant with his treatment strategy, including abstaining from tool use; his wounds had decreased to small scabs, and

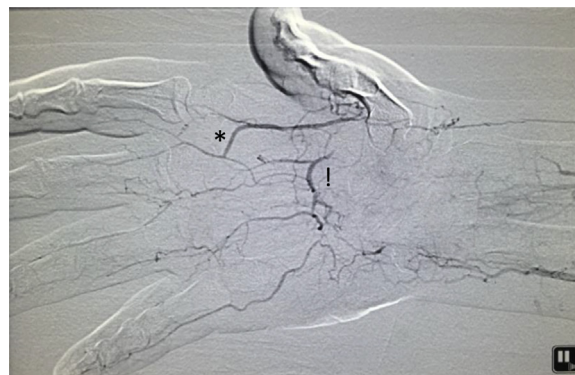

Fig 2. Right upper extremity arteriogram demonstrating patency of two small areas of the superficial (*) and palmar (!) arches with absence of blood supply to the thumb and diminished blood supply to the second to fifth digits.

his other symptoms of numbness, tingling, and pain had mostly resolved.

DISCUSSION

This patient was found on arteriography to have occlusions of his ulnar, radial, superficial palmar, deep palmar, and multiple digital arteries with formation of collaterals. His symptoms and vascular imaging together suggested HAVS or possibly combined HHS and THS. Combined HHS and THS has been previously described in a case report of a 40-year-old man with symptomatic occlusion of both the radial and ulnar arteries of his right hand, thought to be caused by repetitive use of his right palm as a hammer.⁶ In this case, the patient's prolonged exposure to vibrating tools made HAVS most likely. Differentiating HAVS, HHS, and THS is crucial because the hammer syndromes may be amenable to thrombolysis, aneurysm excision with end-to-end reconstruction, or venous or arterial bypass grafts.⁴ On the other hand, there is a lack of evidence to show that surgery is beneficial for patients with HAVS, and these cases are often managed conservatively with smoking cessation, protection against vibrating tools, and calcium channel blocker medication.⁷⁻¹⁰ Although data suggest that systemic oral nitroglycerin can produce vasodilation and globally decrease flow to the affected extremity, locally applied nitro paste may be effective. This strategy involves the recruitment of localized capillary beds and should increase oxygen delivery to the affected area.^{8,10}

Other potential causes of digital ischemia were also ruled out. Normal wrist-brachial indices and CT arteriography with patent right upper extremity vasculature to the level of the wrist argued against significant peripheral arterial insufficiency. No proximal source of emboli was found on CT angiography and echocardiography. Classic features of Buerger disease were lacking, such as significant smoking history, bilaterality, and "corkscrew" appearance of vessels on angiography.¹¹ Occlusive vasculopathy due to autoimmune disease were deemed

less likely because systemic disorders tend to involve more than one extremity and because the patient lacked signs of inflammation on laboratory studies.¹²

The patient's multiple vascular occlusions are most likely due to arterial thrombosis or intimal hyperplasia caused by chronic exposure to vibration. Thompson and House described three individuals who had >10-year histories of occupational vibration exposure and HAVS diagnosed on vascular studies as well as digital artery thrombosis on angiography. The authors suggested that vibration may be contributing to thrombus development and that screening for arterial occlusions should be included in the HAVS workup.¹³ One hypothesis for the relationship of HAVS and arterial thrombosis is that vibration-induced shear stress damage on the vascular endothelium leads to activation of the coagulation cascade.¹⁴ Other studies have shown increased release of endothelin-1, a potent vasoconstrictor, by endothelial cells in response to vibration and diminished release of nitric oxide from damaged endothelium.² If these pathophysiology theories are correct, withdrawal of vibration should help prevent further arterial thrombosis.

HAVS can lead to disability, occupation difficulties, and poor quality of life. One questionnaire given to 149 HAVS patients determined that two-thirds of these patients either stabilized or continued to decline after diagnosis and that their symptoms significantly affected their self-perceived health, quality of life, and work ability.¹⁵ Another study examined manipulative dexterity in 115 workers with exposure to hand-transmitted vibration and found significantly worse dexterity scores in workers exposed to hand-transmitted vibration compared with controls.¹⁶ Furthermore, disability can extend beyond the workplace to impair a patient's ability to complete activities of daily living, such as writing, opening lids, or buttoning clothes.^{7,17} One study found that 42% of workers with HAVS experienced one or more difficulties in performing activities of daily living, which was strongly correlated with reduced grip strength and pain.¹⁷ Prompt recognition of HAVS is important so that exposure to vibration can be limited to prevent further damage in the affected tissue, allowing the patient a chance for a good quality of life and to continue working in some capacity.

REFERENCES

1. Noel B. [The vibration syndrome]. *J Mal Vasc* 1998;23:251-6.
2. White CR, Haidekker MA, Stevens HY, Frangos JA. Extracellular signal-regulated kinase activation and endothelin-1 production in human endothelial cells exposed to vibration. *J Physiol* 2004;555(Pt 2):565-72.
3. Noel B. Pathophysiology and classification of the vibration white finger. *Int Arch Occup Environ Health* 2000;73:150-5.
4. Schrottler A, Czihal M, Lottspeich C, Kuhlencordt P, Nowak D, Hoffmann U. Hypothenar hammer syndrome. *Vasa* 2015;44:179-85.
5. Youakim S. Thenar hammer syndrome: a case report. *Occup Med (Lond)* 2006;56:507-9.
6. McCready RA, Bryant MA, Divilbiss JL. Combined thenar and hypothenar hammer syndromes: case report and review of the literature. *J Vasc Surg* 2008;48:741-4.
7. Friden J. Vibration damage to the hand: clinical presentation, prognosis and length and severity of vibration required. *J Hand Surg Br* 2001;26:471-4.
8. Anderson ME, Moore TL, Hollis S, Jayson MI, King TA, Herrick AL. Digital vascular response to topical glyceryl trinitrate, as measured by laser Doppler imaging, in primary Raynaud's phenomenon and systemic sclerosis. *Rheumatology (Oxford)* 2002;41:324-8.
9. Thompson AE, Pope JE. Calcium channel blockers for primary Raynaud's phenomenon: a meta-analysis. *Rheumatology (Oxford)* 2005;44:145-50.
10. Franks AG Jr. Topical glyceryl trinitrate as adjunctive treatment in Raynaud's disease. *Lancet* 1982;1:76-7.
11. Rivera-Chavarria IJ, Brenes-Gutierrez JD. Thromboangiitis obliterans (Buerger's disease). *Ann Med Surg (Lond)* 2016;7:79-82.
12. Sharma A, Dhooria A, Aggarwal A, Rathi M, Chandran V. Connective tissue disorder-associated vasculitis. *Curr Rheumatol Rep* 2016;18:31.
13. Thompson A, House R. Hand-arm vibration syndrome with concomitant arterial thrombosis in the hands. *Occup Med (Lond)* 2006;56:317-21.
14. Shunto R, Shirakami A, Ohara A, Toibana N, Saito S. Activation of blood coagulation and fibrinolysis in vibration syndrome. *Int Arch Occup Environ Health* 1991;63:293-6.
15. Sauni R, Toivio P, Paakkonen R, Malmstrom J, Uitti J. Work disability after diagnosis of hand-arm vibration syndrome. *Int Arch Occup Environ Health* 2015;88:1061-8.
16. Rui F, D'Agostin F, Negro C, Bovenzi M. A prospective cohort study of manipulative dexterity in vibration-exposed workers. *Int Arch Occup Environ Health* 2008;81:545-51.
17. Cederlund R, Nordenskiöld U, Lundborg G. Hand-arm vibration exposure influences performance of daily activities. *Disabil Rehabil* 2001;23:570-7.

Submitted Nov 11, 2016; accepted Jan 30, 2017.