

Correlation of semi-quantitative findings of endolymphatic hydrops in MRI with the audiometric findings in patients with Meniere's disease

Mohammad Ali Kazemi ^{a,b}, Ali Ghasemi ^{c,*}, Jan W. Casselman ^{d,e,f}, Mohammad Shafiei ^b, Masoud Motasaddi Zarandy ^{g,h}, Hashem Sharifian ^a, Hassan Hashemi ^b, Kavous Firouznia ^b, Behnaz Moradi ^{b,i}, Kianosh Kasani ^j, Azin Etemadimanesh ^c

^a Department of Radiology, Amiralam Hospital, Tehran University of Medical Sciences, Tehran, Iran

^b Department of Radiology, Advanced Diagnostic and Interventional Radiology Research Center (ADIR), Medical Imaging Center, Imam Khomeini Hospital Complex, Tehran University of Medical Sciences, Tehran, Iran

^c Faculty of Medicine, Tehran University of Medical Sciences, Tehran, Iran

^d Department of Radiology, AZ St. Jan Brugge-Oostende av, Campus Brugge, Ruddershove 10, B-8000, Brugge, Belgium

^e University Ghent, Gent, Belgium

^f Department of Radiology, AZ St. Augustinus, Oosterveldlaan 24, B-2610, Antwerpen, Belgium

^g Otorhinolaryngology Research Center, Tehran University of Medical Sciences, Tehran, Iran

^h Department of Otorhinolaryngology, Amiralam Hospital, Tehran University of Medical Sciences, Tehran, Iran

ⁱ Department of Radiology, Yas Complex Hospital, Tehran University of Medical Sciences, Tehran, Iran

^j Bachelor of Radiology, Rajaie Cardiovascular Medical and Research Center, Iran University of Medical Sciences, Tehran, Iran

ARTICLE INFO

Article history:

Received 22 November 2021

Received in revised form

3 April 2022

Accepted 12 April 2022

Keywords:

Magnetic resonance imaging

Meniere disease

Endolymphatic hydrops

Pure-tone audiometry

ABSTRACT

Purpose: To investigate the correlation between vestibular hydrops (VH), cochlearhydrops (CH), vestibular aqueduct non-visibility (VANV), and visually increased perilymphatic enhancement (VIPE) with the findings of pure-tone audiometry (PTA) in Meniere's disease (MD) patients.

Methods: In this cross-sectional study, 53 ears belonging to 48 patients were divided into two groups and evaluated. In group "MD patients," there were 24 ears of 19 patients diagnosed with the definite MD (14 patients with unilateral and 5 patients with bilateral involvements). The "control group" consisted of 29 non-symptomatic ears belonging to patients diagnosed with unilateral sudden sensory-neural hearing loss or unilateral schwannoma. All the patients underwent 2 sessions of temporal bone MRI using the same 3T system: an unenhanced axial T1, T2, and 3D-FLAIR MRI, an intravenous gadolinium-enhanced axial T1 fat-sat, and 4 h after the injection, an axial 3D-T2 cube and 3D-FLAIR session. VH, CH, VANV, and VIPE were assessed. Subsequently, the correlation between EH indices and PTA findings (in three frequency domains of low, middle, and high) were evaluated, and the predictive value of MRI was calculated.

Results: VH was significantly correlated with the hearing threshold in the low, middle, and high-frequency domains. CH was also correlated with the hearing threshold in the low and middle domains. Contrarily, VIPE was not associated with hearing thresholds, and VANV was only correlated with the hearing threshold in low frequencies.

Conclusion: The grade of VH, CH, and VANV were significantly correlated with the hearing thresholds in PTA.

© 2022 PLA General Hospital Department of Otolaryngology Head and Neck Surgery. Production and hosting by Elsevier (Singapore) Pte Ltd. This is an open access article under the CC BY-NC-ND license (<http://creativecommons.org/licenses/by-nc-nd/4.0/>).

* Corresponding author. Faculty of Medicine, Tehran University of Medical Sciences, Poursina St., Tehran, Iran.

E-mail addresses: ma-kazemi@sina.tums.ac.ir (M.A. Kazemi), ghasemi-a@alumnus.tums.ac.ir (A. Ghasemi), jan.casselmann@azsintjan.be (J.W. Casselman), mohammad.sh6810@gmail.com (M. Shafiei), motesadi@sina.tums.ac.ir (M.M. Zarandy), hashemsharifian@gmail.com (H. Sharifian), hashemi_mic@yahoo.com (H. Hashemi), k.firouznia@yahoo.com (K. Firouznia), b.moradi80@gmail.com (B. Moradi), kianosh.kasani@gmail.com (K. Kasani), azinetemadi1@gmail.com (A. Etemadimanesh).

Peer review under responsibility of PLA General Hospital Department of Otolaryngology Head and Neck Surgery.

1. Introduction

Meniere's disease (MD) is an inner ear disease characterized by episodes of vertigo, tinnitus, feeling of fullness in the ear, and progressive hearing and balance disorders. Typically, MD affects only one ear; however, progression to bilateral involvement is possible. Women are more frequently affected by MD, and it usually starts in the 5th to 7th decade of life (Gürkov et al., 2016; Lopez-Escamez et al., 2015). The exact pathophysiology of MD is still unclear. Genetic mutations aside, some studies have suggested the relationship between the incidence of endolymphatic hydrops (EH) and MD (Liu et al., 2020; Martin-Sierra et al., 2017). EH is dilatation of the endolymph-containing structures such as the cochlear duct, saccule, and utricle. It is contemplated that the changes in the endolymphatic volume are strongly associated with the symptoms of MD (Salt and Plontke, 2010; Pender, 2014). Further studies concluded that EH should be mainly considered a histologic marker for MD, not a true pathophysiologic cause (Lingam et al., 2018). In histopathologic studies, the bulging of Reissner's membrane into the scala vestibuli is the hallmark of EH.

In a collaboration between several scientific societies to formulate the diagnostic criteria for MD, the classification committee of the Barany Society categorized MD into two types based on the clinical findings: definite and probable (Lopez-Escamez et al., 2015). Nonetheless, MD can be difficult to diagnose clinically, especially when the symptoms are unusual, such as isolated fluctuating hearing loss (cochlear MD). In such cases, MRI would be helpful as a reliable imaging modality to diagnose MD (Lingam et al., 2018). Accordingly, the Japan Society for Equilibrium Research proposed a new criteria that also included the findings of magnetic resonance imaging (MRI) of the inner ear. They categorized MD into certain, definite, and probable, in which the presence of endolymphatic hydrops (EH) was necessary for the diagnosis of certain MD (Horii Arata, 2017).

Radiological visualization of EH has become an important goal in studies on MD patients. Radiologic assistance eliminates the need for very invasive diagnostics, such as endolymphatic sac biopsy during surgery. Initial studies tried to detect EH by three-dimensional fluid-attenuated inversion recovery magnetic resonance imaging (3D-FLAIR MRI) after intratympanic injection of gadolinium (Nakashima et al., 2007). Pyykkö et al. utilized a delayed 3-D-FLAIR MRI 4 h after the intravenous injection of gadolinium to visualize EH. They visualized EH in 93% of the symptomatic MD patients and all of the definite cases (Pyykkö et al., 2013). The diagnostic criteria in this study was based on the clinical manifestations and balance tests, and they showed that the MRI findings in MD are strongly correlated with the clinical diagnostic criteria.

The association between MRI findings and hearing-balance function tests in MD patients is still controversial. The presence of EH on MRI has been linked to hearing loss; however, EH was found to be unrelated to the electrocorticography (ECoG) and distortion product otoacoustic emissions (DPOAE) results (Quatre et al., 2019). Also, there are a few available studies on the correlation between EH and audiometric evaluations such as pure-tone audiometry (PTA), and little is known about the prevalence of EH among the population (Liu et al., 2015; Sepahdari et al., 2015; Fang et al., 2012). Although the MRI is not the gold standard for the diagnosis of EH, the combined magnetic resonance (MR) evaluation of EH in the inner ear and PTA results might significantly facilitate the diagnosis of MD (Naganawa and Nakashima, 2014). In this study, we utilized a semi-quantitative grading system to evaluate the incidence of EH in the ears of patients with definite MD and healthy controls. A brief report of the EH findings in the asymptomatic ears of unilateral MD patients is also provided. In addition,

we examined the correlation between the grade of EH and PTA results. Finally, the predictive values of the MRI findings in both MD affected and healthy inner ears were calculated.

2. Materials and methods

This single-center cross-sectional study was conducted from April 2019 to September 2020 at a referral hospital for MD patients. A total of 53 ears belonging to 48 patients were enrolled and divided into 2 groups: the "MD group" and the "control group". The MD group included 19 patients who were recently diagnosed (within 2 weeks) with definite MD, of whom 14 patients were unilaterally and 5 bilaterally affected, resulting in a total of 24 ears with definite MD. An expert otolaryngologist had confirmed the definite MD diagnosis according to the Barany Society criteria (Lopez-Escamez et al., 2015). The control group consisted of 29 unaffected ears of 29 patients who had either sudden sensorineural hearing loss (SSNHL) ($n = 24$) or unilateral hearing loss caused by schwannoma ($n = 5$).

Patients with a history of treated MD, diuretic therapy, renal dysfunction with a glomerular filtration rate (GFR) less than 60 ml/min, fluid overload symptoms due to comorbidities including but not limited to severe heart failure and cirrhosis, and those who refused to participate in this study were excluded. The study protocol was completely explained to the patients, and written consent was obtained from all of the participants. Other than the contrast-enhanced MRI, which is a routine diagnostic study for the patients, no additional costs or invasive interventions were imposed on them. Also, patients were informed that they could withdraw from the study upon their request, and they were reassured that their identity would remain confidential. The entire study was conducted in accordance with the Helsinki declaration and its amendments.

MRIs were separately reviewed by two expert radiologists with at least five years of experience in head and neck imaging who were blinded from the study groups. Conflicts between the radiologists were settled by consensus.

Radiologists identified the grade of vestibular hydrops (VH), cochlear hydrops (CH), vestibular aqueduct non-visibility (VANV), and visually increased perilymphatic enhancement (VIPE) in MRIs.

To quantify the grade of VH, the modified four-grade system proposed by Bernaerts et al. was implemented (Bernaerts et al., 2019). VH was classified into 4 grades, including G0, when there was no evidence of hydrops; G1, when the saccule was equal to or larger than the utricle but with clear separation of both structures; G2, when the saccule and utricle were no longer distinguishable from one another but still surrounded by an enhancing perilymph rim; and G3, when the surrounding enhancing perilymph rim was interrupted. The Barath classification was used to assess CH and included G0 when there was no hydrops in the cochlea; G1, when only irregular or nodular dilatation was seen at the periphery of the scala vestibuli caused by the enlargement of the scala media and the displacement of Reissner's membrane; and G2, whenever the cochlear duct or scala media entirely occupied the scala vestibuli (Baráth et al., 2014). VANV was evaluated in T2 cube sequences and classified into G0, G1, and G2: in G0, the VA was completely visible; in G1, the VA was partially visible; and in G2, the VA was completely invisible. VIPE was determined visually as positive or negative for each ear based on the judgment of radiologists. Additionally, PTA was used to identify the hearing threshold in three frequency domains (low hearing frequency (LHF): below 1000 Hz, middle hearing frequency (MHF): between 1000 and 4000 Hz, and high hearing frequency (HHF): more than 4000 Hz).

2.1. MRI protocol

The MRI sessions were performed on a 3T system with a 32-channel array head coil (Discovery MR750, GE Healthcare, Waukesha, WI, USA). All patients underwent an MRI session with intravenous gadolinium-enhanced axial T1 fat-sat and an unenhanced axial T2 and 3D-FLAIR MRI of the temporal bone. Subsequently, intravenous gadolinium (Dotarem® - Gadoteric acid - Gadoterate meglumine, Roissy CdG, France, 0.1 mmol/kg – 0.2 mg/kg) was administered. Four hours after the gadolinium administration, axial 3D-T2 cube images (frequency FOV: 14 Hz, slice thickness: 0.6 mm, TR: 1800.0 ms, TE: 90.0 ms, NEX: 1, the maximum number of slices: 256, echo train length: 50, bandwidth: 83.3 Hz/pixel, and scan time: 5 min and 48 s) and axial 3D-FLAIR images (Brainview® technique, frequency FOV: 24 Hz, slice thickness: 1.2 mm, TR: 6800.0 ms, TE: 115.0 ms, auto inversion time: 1826 ms, NEX: 2, the maximum number of slices: 256, echo train length: 200, voxel size: 0.8*0.8*1.2 mm, bandwidth: 41.67 Hz/pixel, and scan time: 6 min and 24 s) of the temporal bone were acquired. The relatively isotropic voxel size of 0.4*0.4*0.6 mm allowed for making high-quality reformatted images.

2.2. Statistical analysis

Data were analyzed using SPSS software version 25 (USA, IBM). The normal distribution of the continuous variables was assessed by the Shapiro-Wilk test for normality, and correspondingly, they are described as mean (± standard deviation) or median (inter-quartile range). Categorical variables are presented as absolute frequency (percentage). Also, Cohen's kappa was calculated to measure the inter-rater reliability. In the comparative analysis, cross tables, Pearson Chi-Square test, Mann Whitney test, and median test were used. Furthermore, the diagnostic value of MRI-detected EH in the definite MD patients was assessed with the calculated sensitivity, specificity, positive predictive value (PPV), and negative predictive value (NPV) for each parameter. Using the operators "AND" and "OR," we also tested the combination of VH grade with CH, VIPE, and VANV to achieve the optimal diagnostic value. A p-value < 0.05 was considered significant in all of the tests. Lastly, the Benjamini-Hochberg method was employed to detect the false discovery rate.

3. Results

In this study, 53 ears of 48 individuals, including 21 males and 27 females, were evaluated. The mean age of the participants was 50.1 ± 10.8 years. Nineteen definite MD patients, a total of 24 ears, were enrolled in the study. Among them, there were 11 females and 8 males with a mean age of 50.6 ± 12.1 years, of whom 72.4% (n = 14) and 26.6% (n = 5) had unilateral and bilateral MD, respectively. Also, 29 otherwise healthy ears were studied, including 5 healthy ears of the patients with unilateral schwannoma and 24 healthy ears of the patients with unilateral SSNHL. The inter-rater reliability among the radiologists was formidable (kappa = 82%).

A within-group comparison was performed in the control group, and no significant difference was found between the normal ears of unilateral schwannoma patients and those of the SSNHL patients. Between-group comparison, however, showed a significant difference regarding all of the EH indices. Table 1 summarizes the details of EH in the groups as well as their comparisons.

Non-symptomatic ears of the unilateral MD patients were also reviewed, and there were 5 patients with EH. Table 2 illustrates a comprehensive picture of the MRI findings in those five non-involved ears and their corresponding involved ears.

Figs. 1–5 demonstrate various grades of EH in three definite MD patients and their level of hearing loss.

Subsequently, the diagnostic value of the findings in MRI for MD was investigated among definite MD patients. Concerning VH, the increase in the grade led to a decrease in sensitivity but an increase in specificity. Similar results were observed regarding CH and VANV. The details of sensitivity, specificity, PPV, and NPV are shown in Table 3.

Using the operator "OR," we tested the combination of the VH grading with CH, VIPE, and VANV, which showed increased sensitivity and decreased specificity. Notwithstanding, the application of the "AND" operator resulted in decreased sensitivity and increased specificity. Regardless of the operator, an increase in the grade prompted a decline in sensitivity and an increase in specificity. Considering the changes in specificity, PPV, and NPV, the best diagnostic value was achieved when VH and VANV were combined using the "AND" operator. Sensitivity, specificity, PPV, and NPV for the combination of VH > G1 and VANV > G2 were 45.8%, 100%, 100%, and 50% using the "AND" operator, and 100%, 84.6%, 92.3%,

Table 1
The description of MRI findings.

	Ears with definite MD (n = 24)		Asymptomatic ears of MD patients (n = 14)		Ears of the control group (n = 29)		Between-group (definite MD- control) comparison (sig.)
Grade of VH	G0	0 (0%)	G0	13 (92.9%)	G0	25 (86.3%)	<0.001
	G1	7 (29.2%)	G1	1 (7.1%)	G1	4 (13.7%)	
	G2	13 (54.2%)	G2	0 (0%)	G2	0 (0%)	
	G3	4 (16.7%)	G3	0 (0%)	G3	0 (0%)	
Grade of CH	G0	5 (20.8%)	G0	13 (92.9%)	G0	22 (75.9%)	<0.001
	G1	11 (45.8%)	G1	1 (7.1%)	G1	7 (24.1%)	
	G2	8 (33.3%)	G2	0 (0%)	G2	0 (0%)	
Grade of VANV	G0	2 (8.3%)	G0	10 (71.4%)	G0	20 (68.9%)	<0.001
	G1	12 (50%)	G1	3 (21.5%)	G1	9 (31.1%)	
	G2	10 (41.7%)	G2	1 (7.1%)	G2	0 (0%)	
VIPE	Pos.	10 (41.7%)	Pos.	3 (21.5%)	Pos.	7 (24.2%)	0.011
	Neg.	14 (58.3%)	Neg.	11 (78.5%)	Neg.	22 (75.8%)	

CH = cochlear hydrops.

G = grade.

MD = Meniere's disease.

Sig. = asymptomatic significance (2-sided).

VANV = vestibular aqueduct non-visibility.

VH = vestibular hydrops.

VIPE = visually increased perilymphatic enhancement.

Table 2
MRI findings in the asymptomatic ears of the MD patients with their corresponding involved ear.

Index	Patient 1		Patient 2		Patient 3		Patient 4		Patient 5	
	M	H	M	H	M	H	M	H	M	H
VH grade	G2	G1	G2	G0	G2	G0	G2	G0	G3	G0
CH grade	G0	G0	G1	G1	G2	G0	G1	G0	G2	G0
VANV grade	G1	G1	G0	G0	G2	G0	G1	G0	G1	G2
VIPE	Pos.	Pos.	Pos.	Neg.	Pos.	Pos.	Neg.	Pos.	Pos.	Neg.

CH = cochlear hydrops.
G = grade.
H = the healthy ear.
M = the ear with Meniere's disease involvement.
VANV = vestibular aqueduct non-visibility.
VH = vestibular hydrops.
VIPE = visually increased perilymphatic enhancement.

and 100% using the “OR” operator, respectively.

Concerning the definite MD ears, the grade of VH was significantly associated with hearing loss in LHF, MHF, and HHF. The grade of CH was also associated with PTA results in LHF and MHF in this group. However, the grade of VANV was only related to the hearing loss in the LHF. Furthermore, the presence of VIPE was not

associated with the PTA findings. As the grade of EH increased, the hearing loss in LHF and MHF significantly deteriorated. There was no significant association between the PTA findings and the grades of VH, CH, VANV, and VIPE in the control group. Table 4 provides more details regarding the PTA results and MRI findings of the definite MD ears.

4. Discussion

In this study, we investigated the correlation between the EH grade in MRI and PTA results in clinically diagnosed MD ears. Also, the diagnostic value of the EH indices for MD was assessed. Of all 53 studied ears, 24 belonged to 19 patients with definite MD (5 bilateral and 14 unilateral). VH and CH were graded using the semi-quantitative system presented by Bernaerts et al. (VH) and Barath et al. (CH) (Bernaerts et al., 2019; Baráth et al., 2014).

4.1. Endolymphatic hydrops and hearing loss

Only a few studies have investigated the correlation between the semi-quantitative grading of EH and PTA findings in MD patients. Our evaluation of the hearing loss at LHF, MHF, and HHF showed that MD-related hearing loss occurs at LHF and MHF.

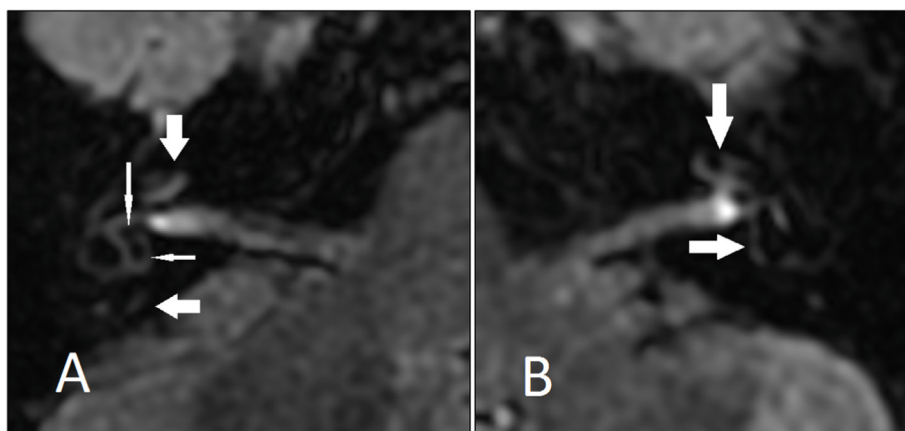


Fig. 1. A 36-year-old female with confirmed definite Meniere's disease on the left side. (A) Normal vestibular utricle (horizontal thin arrow), saccule (vertical thin arrow), cochlea (vertical thick arrow), and vestibular aqueduct (horizontal thick arrow) of the right ear. (B) Grade 2 vestibular (horizontal arrow) and grade 2 cochlear (vertical arrow) hydrops of left ear. The vestibular aqueduct was not visible in this ear. She presented with 50 dB hearing loss on the left side.

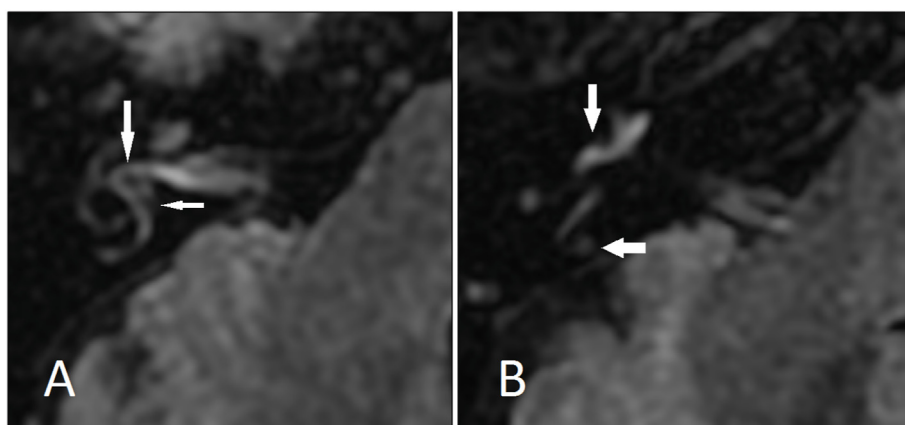


Fig. 2. A 69-year-old female with confirmed definite Meniere's disease in the right ear. (A) Saccule (vertical arrow) is larger than vestibule, suggestive of grade 1 vestibular hydrops. No imaging sign of cochlear hydrops is present. (B) Vestibular aqueduct (horizontal arrow) is completely visible (grade 0) and visualized increased perilymphatic enhancement (vertical arrow) is present. 20 dB hearing loss of the right ear was detected.

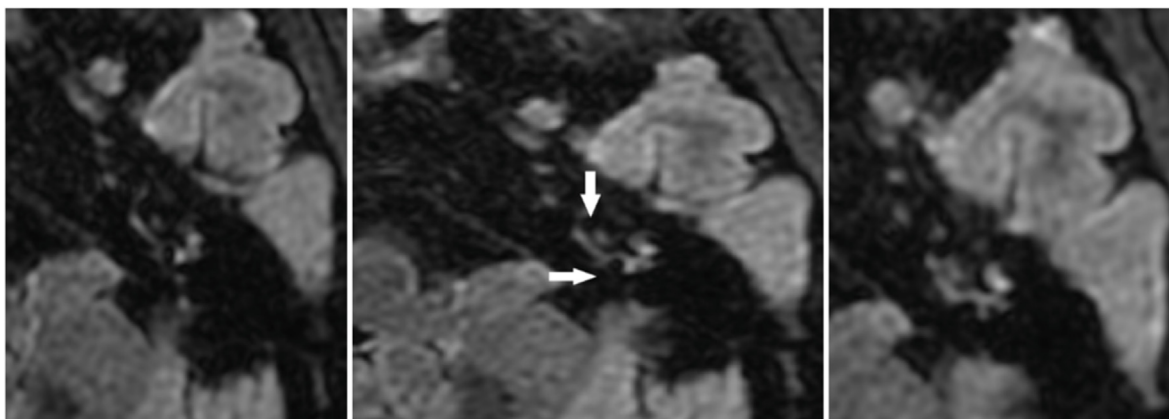


Fig. 3. A 68-year-old female with confirmed definite Meniere's disease of the left ear. Complete obliteration of cochlear scala vestibuli (vertical arrow) in favor of grade 2 cochlear hydrops and near-complete vestibular perilymphatic obliteration suggestive of grade 3 vestibular hydrops are present. 60 dB hearing loss was recorded in this ear. The lower and upper sections are presented on the left and right, respectively.

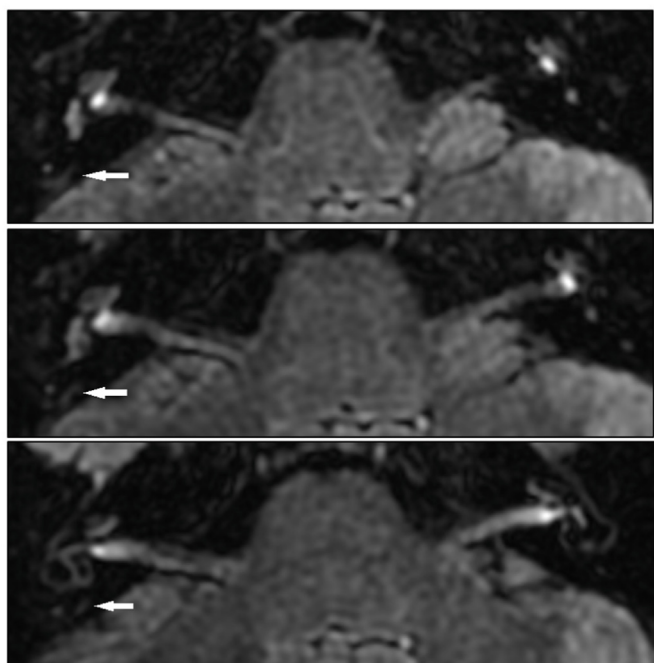


Fig. 4. Three consecutive axial sections of the patient in Fig. 3. The vestibular aqueduct is completely visible in the right ear (normal ear); however, the vestibular aqueduct is invisible in all three sections on the left side with a confirmed diagnosis of definite MD.

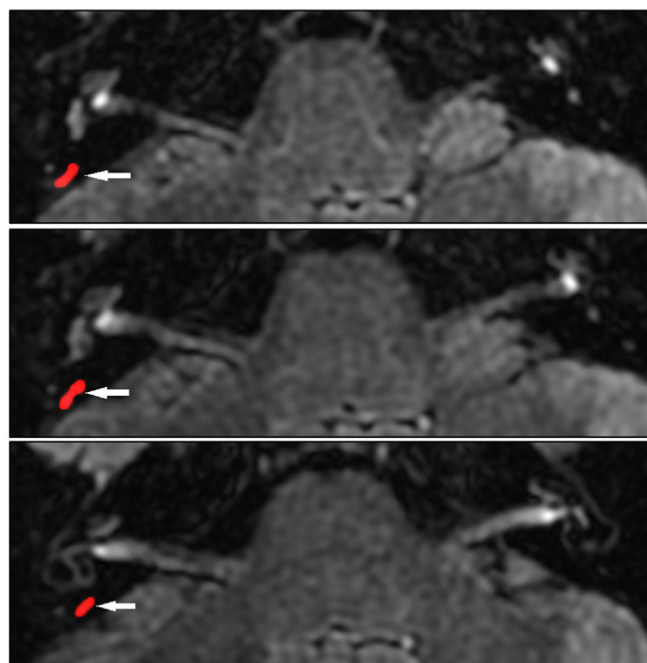


Fig. 5. The same figure as Fig. 4 but with highlighted visible vestibular aqueducts in red overlays.

Similar to our findings, Wu et al. stated that low-and mid-frequency hearing loss was associated with the size of the negative signal area in all cochlear turns (Wu et al., 2016).

Our results showed a significant relationship between hearing loss and VH, CH, and VANV. The rate of hearing loss was proportional to the grade of VH and CH. Similarly, Seo et al. reported that CH has a significant relationship with an abnormal auditory threshold in PTA and ECoG (Seo et al., 2013). In a study by Jasińska et al., the grade of EH and the endolymphatic space dilation were significantly related to the level of hearing loss (Jasińska et al., 2021). Pyykkö et al. have shown that CH and/or VH were detected in 55–90% of patients with unilateral vertigo, tinnitus, or hearing loss in the symptomatic ear (Pyykkö et al., 2013).

4.2. Endolymphatic hydrops in the control group

We investigated 29 healthy ears (5 ears of the patients with unilateral schwannoma and 24 ears of unilateral SSNHL patients). There were 4 ears (13.7%) with VH grade 1 among the control group. We found 7 (24.1%) cases of CH grade 1 among the ears in the control group. Additionally, there was one ear with VH grade 1 (7.1%) and one with CH grade 1 (7.1%) among the non-symptomatic ears of the unilateral MD patients (n = 14). Attye et al. reported that evidence of EH was found on MRI of 22%–65% of asymptomatic ears in MD patients (Attye et al., 2017). Wu et al. also identified mild CH in the opposite asymptomatic ear of 9 (16.7%) unilateral MD patients (Wu et al., 2016). Furthermore, Yoshida et al. considered vestibular EH a specific indicator of definite MD, which is rarely present in healthy ears (Yoshida et al., 2018). In a meta-analysis of

Table 3
Sensitivity, specificity, PPV, and NPV of the evaluated MRI indices in definite MD patients.

MRI index	Grade	Sensitivity (%)	Specificity (%)	PPV (%)	NPV (%)
Grade of VH	≥ G1	100	92.3	96	100
	≥ G2	70.8	100	100	65
	G3	16.7	100	100	39.4
Grade of CH	≥ G1	79.2	92.3	95	70.6
	G2	33.3	100	100	44.8
VANV	≥ G1	91.7	69.2	84.6	81.8
	G2	41.7	92.3	90.9	46.2
VIPE	Positive	58.3	76.9	82.4	50

CH = cochlear hydrops.
G = grade.
NPV = negative predictive value.
PPV = positive predictive value.
VANV = vestibular aqueduct non-visibility.
VH = vestibular hydrops.
VIPE = visually increased perilymphatic enhancement.

the EH and MD relationship, two studies showed EH presence in patients with no history of MD (Pender, 2014). These findings indicate that MD patients can present evidence of EH in both symptomatic and asymptomatic ears; therefore, clinical assessment alone may not provide a reliable assessment of bilateral MD. Temporal bone histopathology studies have also reported a 14% risk of bilateral progression in MD patients (House et al., 2006). In this study, none of the ears in the control group demonstrated VH or CH grade 2 or above, and there was only one instance of VANV grade 2 in an asymptomatic ear of a unilateral MD patient. All cases of VH or CH grade 2 or higher were among definite MD patients.

As some studies suggest, different grades of EH occur in the contralateral asymptomatic ears of unilateral MD patients. Therefore, we reported findings from the healthy ears of the MD patients separately from the non-MD ones to avoid statistical oversight.

Table 4
The comparison of the hearing thresholds (in dB) in different grades of each MRI finding in the MD patients.

EH			The hearing threshold in frequency domains of PTA					
Among the MD ears			LHF		MHF		HHF	
Index	Grade	N	Median (IQR) [min-max]	Sig.	Median (IQR) [min-max]	Sig.	Median (IQR) [min-max]	Sig.
VH	G0	0	-	0.003	-	0.007	-	0.014
	G1	7	10.0 (10.0) [10.0–20.0]		10.0 (10.0) [10.0–20.0]		10.0 (10.0) [10.0–20.0]	
	G2	13	40.0 (55.0) [0.0–60.0]		40.0 (55.0) [0.0–60.0]		40.0 (50.0) [0.0–60.0]	
	G3	4	45.0 (17.0) [40.0–60.0]		40.0 (45.0) [0.0–60.0]		40.0 (45.0) [0.0–60.0]	
CH	G0	6	20.0 (32.5) [0.0–40.0]	0.002	20.0 (32.5) [0.0–40.0]	0.034	20.0 (32.5) [0.0–40.0]	0.127
	G1	10	10.0 (32.5) [0.0–60.0]		10.0 (32.5) [0.0–60.0]		10.0 (32.5) [0.0–60.0]	
	G2	8	50.0 (17.5) [40.0–60.0]		50.0 (20.0) [0.0–60.0]		45.0 (47.5) [0.0–60.0]	
VANV	G0	2	5.0 (N/A) [0.0–10.0]	0.031	5.0 (N/A) [0.0–10.0]	0.140	5.0 (N/A) [0.0–10.0]	0.275
	G1	12	20.0 (37.5) [0.0–60.0]		20.0 (37.5) [0.0–60.0]		20.0 (37.5) [0.0–60.0]	
	G2	10	50.0 (25.0) [10.0–60.0]		45.0 (42.5) [0.0–60.0]		40.0 (45.0) [0.0–60.0]	
VIPE	Neg.	10	15.0 (45.0) [0.0–60.0]	0.214	15.0 (45.0) [0.0–60.0]	0.680	15.0 (45.0) [0.0–60.0]	0.697
	Pos.	14	40.0 (32.5) [0.0–60.0]		40.0 (35.0) [0.0–60.0]		30.0 (40.0) [0.0–60.0]	

CH = cochlear hydrops.
EH = endolymphatic hydrops.
G = grade.
HHF = high hearing frequency.
IQR = interquartile range.
LHF = low hearing frequency.
MD = Meniere’s disease.
MHF = middle hearing frequency.
N/A = not attributable.
Sig. = asymptomatic significance (2-sided).
VANV = vestibular aqueduct non-visibility.
VH = vestibular hydrops.
VIPE = visually increased perilymphatic enhancement.

Morita et al. reported that the progression of MD from unilateral to bilateral occurs 13–21 years after the disease onset (Morita et al., 2009). Hence, regular follow-ups seem necessary, as there is a potential risk of Meniere’s involvement in the asymptomatic ear, and it is clear that the detection of EH in the asymptomatic ear warns us of a probable MD development and future hearing loss. To estimate the diagnostic value of MRI in healthy ears of unilateral MD patients, further investigations are required.

4.3. Diagnostic value of semi-quantitative grading of EH in MD

Our results showed that the sensitivity decreases and the specificity increases with higher grades of VH, CH, and VANV. The combination of VH, CH, VANV, and VIPE increases sensitivity and decreases specificity compared to the findings of VH alone. In our study, the presence of VH and VANV grade ≥1 resulted in the highest predictive value of MD. Attyé et al. found the sensitivity and specificity of VANV grades 1 and 2 on MRI in the detection of MD to be 90% and 60% for grade 1 and 45% and 85% for grade 2, respectively (Attyé et al., 2020). Finally, Jasinska et al. reported a sensitivity of 81.6% in CH and 63.2% in VH using the Barath grading system. (Jasińska et al., 2021).

The limitations of this study included a short study time frame and lack of MRI follow-up due to time and facility limitations, as well as the impossibility of comparing the MRI findings with the histopathology of the inner ear in MD patients. Further studies on a larger cohort with MR follow-up could be helpful in the long-term prediction and treatment of MD patients.

5. Conclusion

MRI is a valuable technique in the detection of EH and the diagnosis of MD. The results of this study show a significant

association between “the grade of VH, CH, and VANV” and “the PTA findings” in MD patients. Notably, a few cases of low-grade VH, CH, and VANV were found in the asymptomatic ears of the unilateral MD patients and the control group.

Funding

This research did not receive any specific grants from funding agencies in the public, commercial, or not-for-profit sectors.

Declaration of competing interest

The authors of the study entitled: “Correlation of semi-quantitative findings of endolymphatic hydrops in MRI with the audiometric findings in patients with Meniere's disease” declare no conflict of interests.

References

- Arata, Horii, 2017. Symposium 1 “diagnostic criteria for vertigo diseases - diagnostic criteria of the Japanese society of vertigo and Equilibrium medicine and new diagnostic criteria of the Barany society” new classification of psychogenic vertigo and diagnostic criteria for persistent postural-perceptual dizziness (PPPD) by the Barany society. *Equilib. Res.*
- Attyé, A., Eliezer, M., Boudiaf, N., Tropes, I., Chechin, D., Schmerber, S., et al., 2017. MRI of Endolymphatic Hydrops in Patients with Meniere's Disease: a Case-Controlled Study with a Simplified Classification Based on Saccular Morphology. *European radiology*.
- Attye, A., Barma, M., Schmerber, S., Dumas, G., Eliezer, M., Krainik, A., 2020. The vestibular aqueduct sign: magnetic resonance imaging can detect abnormalities in both ears of patients with unilateral Meniere's disease. *J. Neuroradiol.* <https://doi.org/10.1016/j.neurad.2018.10.003>.
- Baráth, K., Schuknecht, B., Naldi, A.M., Schrepfer, T., Bockisch, C.J., Hegemann, S.C.A., 2014. Detection and grading of endolymphatic hydrops in Meniere disease using MR imaging. *AJNR. Am. J. Neuroradiol.* <https://doi.org/10.3174/ajnr.A3856>.
- Bernaerts, A., Vanspauwen, R., Blaivie, C., Van Dinther, J., Zarowski, A., Wuyts, F.L., et al., 2019. The value of four stage vestibular hydrops grading and asymmetric perilymphatic enhancement in the diagnosis of Meniere's disease on MRI. *Neuroradiology.* <https://doi.org/10.1007/s00234-019-02155-7>.
- Fang, Z., Chen, X., Gu, X., Liu, Y., Zhang, R., Cao, D., et al., 2012. A new magnetic resonance imaging scoring system for perilymphatic space appearance after intratympanic gadolinium injection, and its clinical application. *J. Laryngol. Otol.*
- Gürkov, R., Pyykö, I., Zou, J., Kentala, E., 2016. What is Meniere's disease? A contemporary re-evaluation of endolymphatic hydrops. *J. Neurol.*
- House, J.W., Doherty, J.K., Fisher, L.M., Derebery, M.J., Berliner, K.I., 2006. Meniere's Disease: Prevalence of Contralateral Ear Involvement. *Otology & Neurotology.*
- Jasińska, A., Lachowska, M., Wnuk, E., Pierchała, K., Rowiński, O., Niemczyk, K., 2021. Correlation between Magnetic Resonance Imaging Classification of Endolymphatic Hydrops and Clinical Manifestations and Audiovestibular Test Results in Patients with Definite Ménière's Disease. *Auris Nasus Larynx.*
- Lingam, R., Connor, S., Casselman, J., Beale, T., 2018. MRI in otology: applications in cholesteatoma and Ménière's disease. *Clin. Radiol.*
- Liu, F., Huang, W., Chen, Q., Gao, Z., 2015. Comparison of noninvasive evaluation of endolymphatic space in healthy volunteers in different age groups using magnetic resonance imaging. *Acta Otolaryngol.*
- Liu, Y., Yang, J., Duan, M., 2020. Current status on researches of Meniere's disease: a review. *Acta Otolaryngol.*
- Lopez-Escamez, J.A., Carey, J., Chung, W.-H., Goebel, J.A., Magnusson, M., Mandalà, M., et al., 2015. Diagnostic criteria for Meniere's disease. *J. Vestib. Res.*
- Martin-Sierra, C., Gallego-Martinez, A., Requena, T., Frejo, L., Batuecas-Caletrio, A., Lopez-Escamez, J.A., 2017. Variable expressivity and genetic heterogeneity involving DPT and SEMA3D genes in autosomal dominant familial Meniere's disease. *Eur. J. Hum. Genet.* <https://doi.org/10.1038/ejhg.2016.154>.
- Morita, N., Kariya, S., Farajzadeh Derooe, A., Cureoglu, S., Nomiya, S., Nomiya, R., et al., 2009. Membranous Labyrinth Volumes in Normal Ears and Meniere Disease: a Three-dimensional Reconstruction Study. *The Laryngoscope.*
- Naganawa, S., Nakashima, T., 2014. Visualization of endolymphatic hydrops with MR imaging in patients with Ménière's disease and related pathologies: current status of its methods and clinical significance. *Jpn. J. Radiol.*
- Nakashima, T., Naganawa, S., Sugiura, M., Teranishi, M., Sone, M., Hayashi, H., et al., 2007. Visualization of Endolymphatic Hydrops in Patients with Meniere's Disease. *The Laryngoscope.*
- Pender, D., 2014. Endolymphatic hydrops and Ménière's disease: a lesion meta-analysis. *J. Laryngol. Otol.*
- Pyykkö, I., Nakashima, T., Yoshida, T., Zou, J., Naganawa, S., 2013. Meniere's disease: a reappraisal supported by a variable latency of symptoms and the MRI visualisation of endolymphatic hydrops. *BMJ Open.*
- Quatre, R., Attyé, A., Karkas, A., Job, A., Dumas, G., Schmerber, S., 2019. Relationship between Audio-Vestibular Functional Tests and Inner Ear MRI in Meniere's Disease. *Ear Hear.*
- Salt, A.N., Plontke, S.K., 2010. Endolymphatic hydrops: pathophysiology and experimental models. *Otolaryngol. Clin.*
- Seo, Y.J., Kim, J., Choi, J.Y., Lee, W.S., 2013. Visualization of Endolymphatic Hydrops and Correlation with Audio-Vestibular Functional Testing in Patients with Definite Meniere's Disease. *Auris Nasus Larynx.*
- Sepahdari, A.R., Ishiyama, G., Vorasubin, N., Peng, K.A., Linetsky, M., Ishiyama, A., 2015. Delayed intravenous contrast-enhanced 3D FLAIR MRI in Meniere's disease: correlation of quantitative measures of endolymphatic hydrops with hearing. *Clin. Imag.*
- Wu, Q., Dai, C., Zhao, M., Sha, Y., 2016. The Correlation between Symptoms of Definite Meniere's Disease and Endolymphatic Hydrops Visualized by Magnetic Resonance Imaging. *The Laryngoscope.*
- Yoshida, T., Sugimoto, S., Teranishi, M., Otake, H., Yamazaki, M., Naganawa, S., et al., 2018. Imaging of the Endolymphatic Space in Patients with Ménière's Disease. *Auris Nasus Larynx.*