

Received: 2021.02.26
Accepted: 2021.04.13
Available online: 2021.04.15
Published: 2021.05.22

Ewing Sarcoma Misdiagnosed as a Traumatic Hematoma: A Case from Family Practice

Authors' Contribution:
Study Design A
Data Collection B
Statistical Analysis C
Data Interpretation D
Manuscript Preparation E
Literature Search F
Funds Collection G

ABCDEFG **Malak Al Shamhari**

Department of Family and Community Medicine, Imam Abdulrahman Bin Faisal University, Dammam, Saudi Arabia

Corresponding Author: Malak Al Shamhari, e-mail: moalshammari@iau.edu.sa
Conflict of interest: None declared

Patient: Female, 13-year-old
Final Diagnosis: Ewing sarcoma
Symptoms: Swelling
Medication: —
Clinical Procedure: —
Specialty: Family Medicine

Objective: Mistake in diagnosis





Background: Timely diagnosis of cancers is crucial, as delays can adversely affect a patient's outcome and experience. Since soft tissue hematoma is a common clinical condition following trauma, soft tissue tumors can be misdiagnosed as hematomas due to the similar clinical features.

Case Report: A 13-year-old girl presented with a gradually expanding swelling in the left arm that developed following minor trauma. She was seen by several general practitioners, and the swelling was managed as a soft tissue hematoma with the application of ice packs and compression, which did not result in any improvement. The initial plain radiograph of the left humerus revealed a large soft tissue swelling with areas of calcifications and minimal periosteal changes. The swelling was further evaluated by ultrasound, showing a hypoechoic lesion with internal septation and increased vascularity. These findings were mistakenly interpreted as a traumatic hematoma. Considering the prolonged duration and the progressive nature of the condition, the patient was referred for magnetic resonance imaging, which showed a soft tissue lesion involving the humeral shaft and sparing the proximal and distal epiphyses. An ultrasound-guided biopsy confirmed the diagnosis of Ewing sarcoma.

Conclusions: Ewing sarcoma may present with a clinical picture similar to that of a traumatic hematoma. Hence, this case highlights the need for considering soft tissue tumors as a differential diagnosis in patients presenting with an expanding swelling. Primary care physicians should have a high index of suspicion for malignancies and should not be reluctant to refer patients for further investigations in cases exhibiting an unusual course of the clinical condition.

Keywords: Hematoma • Sarcoma, Ewing • Soft Tissue Neoplasms • Case Reports

Full-text PDF: <https://www.amjcaserep.com/abstract/index/idArt/931843>

 1098  —  3  15



Background

The timely recognition of cancers is crucial, as delays can adversely affect a patient's outcome and experience [1,2]. The missed diagnosis of cancer represents a leading cause of malpractice claims [3]. Primary care physicians, the first level of contact within the healthcare system, have a vital role in shortening the time of diagnosis by making early, appropriate referrals [4]. Considering their limited access to diagnostic tools, primary care physicians substantially rely on their history-taking skills to make a diagnosis. However, the presenting symptoms of malignancies can easily be overlooked and attributed to benign conditions owing to their low predictive values [5].

Soft tissue hematoma is a common clinical condition following trauma. Although it typically regresses over time, a hematoma could enlarge and may be mistaken for a tumor [6,7]. Conversely, soft tissue tumors may be misdiagnosed as hematomas because of their similar clinical and imaging features [8]. Here, we present the case of a 13-year-old girl who, following minor trauma, developed arm swelling that was due to Ewing sarcoma but was misdiagnosed as a hematoma, despite the radiographic and sonographic findings.

Case Report

A 13-year-old girl was brought to our primary healthcare center with a gradually expanding swelling in the left arm that developed following a fall, which occurred 6 weeks before presentation while the patient was playing in school. She sustained significant superficial abrasions as a result of this fall. She was seen by several general practitioners who managed her case as a traumatic hematoma and advised the application of ice packs and compression to the injured area. However, these conservative measures did not result in any improvement. The patient was otherwise healthy and did not have any history of prolonged bleeding. Her past medical and family history was unremarkable.

On examination, the swelling was firm, immobile, and tender with no changes in the overlying skin. The swelling measured 10×5 cm. The plain radiograph of the left humerus obtained 2 weeks following the trauma demonstrated a large soft tissue mass with areas of calcification. Additionally, irregular cortex and periosteal reactions were noted (**Figure 1**). However, these radiographic findings were not recognized or considered in the initial encounters. Basic laboratory investigations, including a coagulation profile, showed normal results.

The family medicine physician, with 5 years of experience in general ultrasound examination, performed a bedside ultrasound of the left upper arm, which revealed the previously

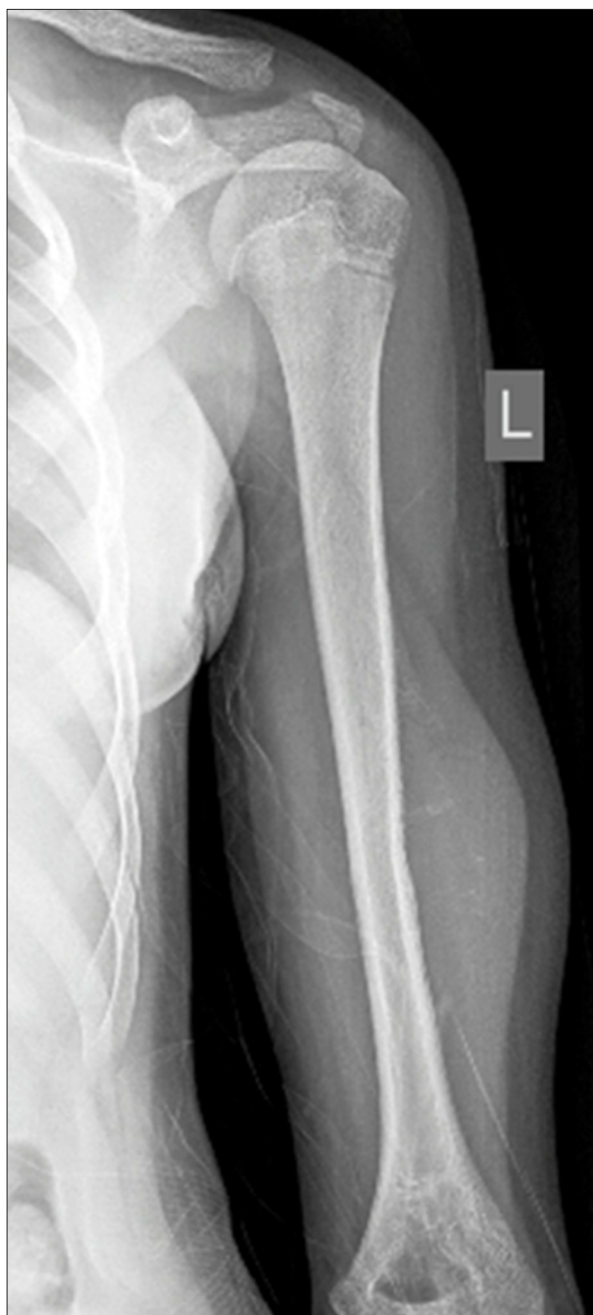

Figure 1. Plain radiograph of left humerus showing a soft tissue swelling with irregular cortex and periosteal reaction.

described lesion as a hypoechoic mass, measuring 5.0×1.8 cm, with internal septation and increased vascularity (**Figure 2**). The underlying bone was irregular and had a periosteal reaction. Given the patient's history, such findings were mistakenly interpreted as a subcutaneous hematoma with granulation tissue. Considering the prolonged duration and progressive nature of the swelling, the patient was referred for magnetic resonance imaging (MRI) of the left arm for further characterization of the lesion.

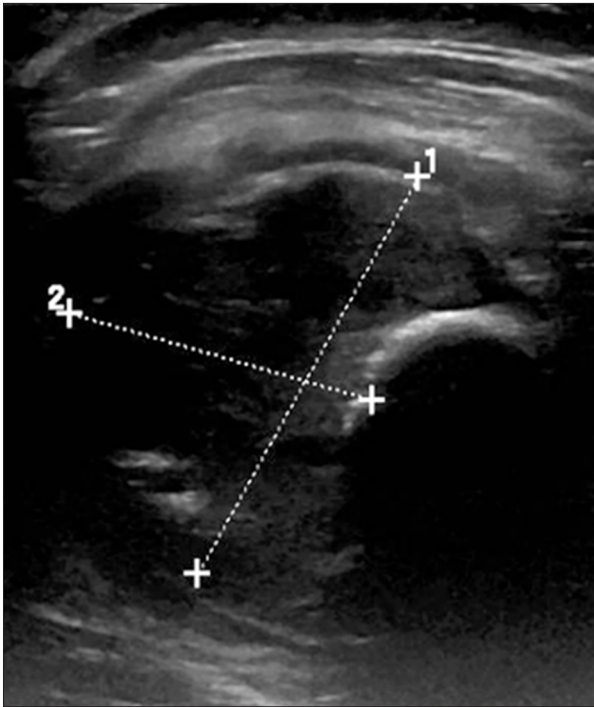


Figure 2. Ultrasound image showing the mass as a hypoechoic lesion with foci of calcification.

The MRI was performed without intravenous contrast because the patient was not cooperative. The scan demonstrated a large soft tissue mass, measuring 9.4×3.4×3.0 cm, arising from the midshaft of the left humerus, encasing the entire circumference of the diaphysis, and protruding anteriorly. The mass had a signal intensity similar to that of skeletal muscles on both T1- and T2-weighted images, with a heterogeneous area of high T2 and low T1 signal intensities seen in the diaphysis, which had an ill-defined margin and wide zone of transition. The lesion had an interrupted and irregular periosteal reaction peripherally. The proximal and distal epiphyses, however, were spared (**Figure 3**). The presumptive diagnosis based on these findings was high-grade osteosarcoma.

An ultrasound-guided biopsy of the lesion was performed with the patient under sedation. Histopathological examination revealed broad sheets of small round cells with scant cytoplasm in a background having scant stroma, with coagulative necrosis and reactive new bone formation. Immunohistochemistry results showed strong positivity for CD99, vimentin, and synaptophysin, but were negative for cytokeratin, desmin, and CD45, confirming the diagnosis of Ewing sarcoma. Subsequently, a bone scan was performed as part of the staging protocol, showing no evidence of distant metastases.

The patient was referred to a specialized oncology center, where she underwent wide, local resection with reconstruction with a vascularized fibular graft after completion of a

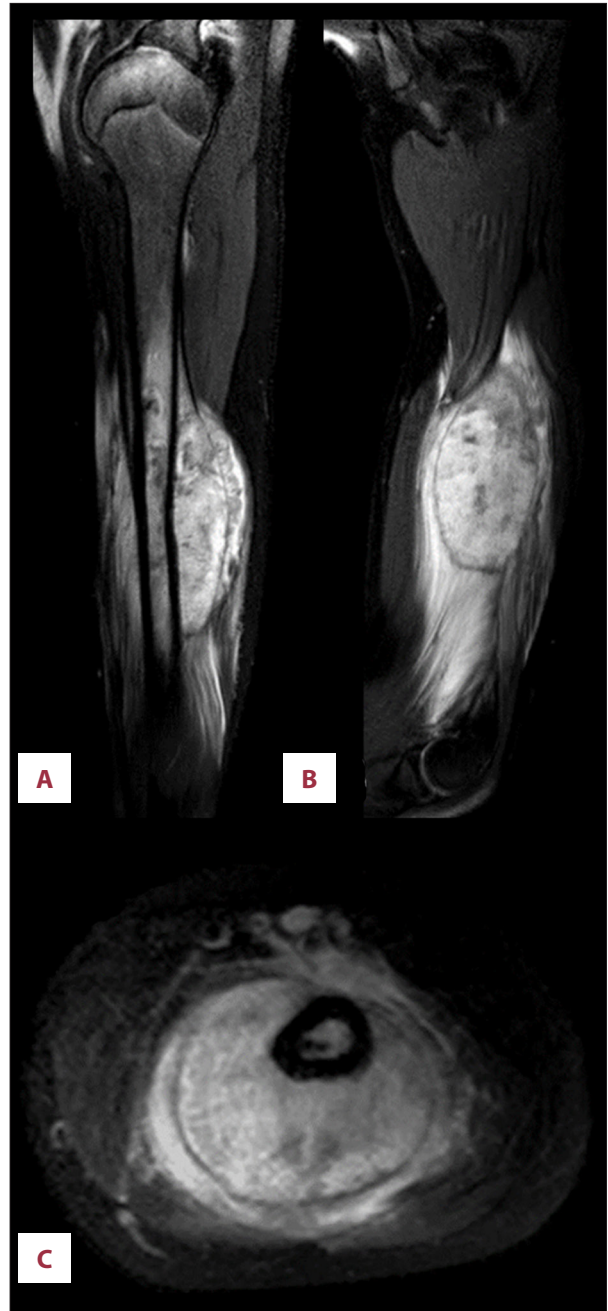


Figure 3. T2-weighted magnetic resonance images in the (A) sagittal, (B) coronal, and (C) axial planes of the left humerus, demonstrating a heterogenous soft tissue mass arising from and encasing the entire circumference of the midshaft of the humerus. Irregular periosteal reaction is noted at the periphery of the mass.

chemotherapy course. The operative course was uneventful and without complication. The outcome of the patient was favorable at her 12-month follow-up, with the radiograph showing proper alignment. It is worth noting that the diagnosis was delayed for over 6 months from the time of initial presentation.

Discussion

We presented a case of Ewing sarcoma that developed following a minor trauma and was mistakenly diagnosed and managed as a traumatic hematoma. Misdiagnosis of soft tissue tumors is not uncommon owing to several factors, including their rarity, broad spectrum of clinical and histological presentations, and the low index of suspicion by physicians [9].

Prompt diagnostic evaluation by MRI and biopsy is essential to avoid delay in the management. Ultrasound examination has insufficient accuracy in the evaluation of soft tissue masses [10]. For example, misdiagnosis of soft tissue tumors by ultrasound examination conducted by radiologists is common, reaching up to 25%. Interestingly, the most common misdiagnosis of soft tissue tumors is hematoma [11].

Early referral to a specialized center has been shown to lower the mortality and morbidity of soft tissue sarcomas [12]. The management of soft tissue tumors requires a multidisciplinary approach so that the treatment can involve multimodal therapy including chemotherapy, radiotherapy, and surgery. To avoid diagnostic delays, it is advised that patients with a solid mass for more than 4 weeks should undergo proper diagnostic evaluation. An excisional biopsy is recommended for tumors less than 5 cm, while MRI followed by an incisional biopsy is advised for larger tumors [13].

References:

1. Arhi CS, Burns EM, Bottle A, et al. Delays in referral from primary care worsen survival for patients with colorectal cancer: A retrospective cohort study. *Br J Gen Pract.* 2020;70(696):e463-e71
2. Neal RD, Tharmanathan P, France B, et al. Is increased time to diagnosis and treatment in symptomatic cancer associated with poorer outcomes? Systematic review. *Br J Cancer.* 2015;112(Suppl 1):S92-107
3. Aaronson EL, Quinn GR, Wong CI, et al. Missed diagnosis of cancer in primary care: Insights from malpractice claims data. *J Healthc Risk Manag.* 2019;39(2):19-29
4. Tørring ML, Murchie P, Hamilton W, et al. Evidence of advanced stage colorectal cancer with longer diagnostic intervals: A pooled analysis of seven primary care cohorts comprising 11 720 patients in five countries. *Br J Cancer.* 2017;117(6):888-97
5. Lyratzopoulos G, Neal RD, Barbiere JM, et al. Variation in number of general practitioner consultations before hospital referral for cancer: findings from the 2010 National Cancer Patient Experience Survey in England. *Lancet Oncol.* 2012;13(4):353-65
6. Negoro K, Uchida K, Yayama T, et al. Chronic expanding hematoma of the thigh. *Joint Bone Spine.* 2012;79(2):192-94
7. Nishida Y, Kobayashi E, Kubota D, et al. Chronic expanding hematoma with a significantly high fluorodeoxyglucose uptake on (1)(8)F-fluorodeoxyglucose positron emission tomography, mimicking a malignant soft tissue tumor: A case report. *J Med Case Rep.* 2014;8(1):349
8. Le C-K, Harvey G, McLean L, Fischer J. Point-of-care ultrasound use to differentiate hematoma and sarcoma of the thigh in the pediatric emergency department. *Pediatr Emerg Care.* 2017;33(2):135-36
9. Brouns F, Stas M, De Wever I. Delay in diagnosis of soft tissue sarcomas. *Eur J Surg Oncol.* 2003;29(5):440-45
10. Kwok HC, Pinto CH, Doyle AJ. The pitfalls of ultrasonography in the evaluation of soft tissue masses. *J Med Imaging Radiat Oncol.* 2012;56(5):519-24
11. Doyle AJ, Miller MV, French JG. Ultrasound of soft-tissue masses: Pitfalls in interpretation. *Australas Radiol.* 2000;44(3):275-80
12. Lehnhardt M, Daigeler A, Homann HH, et al. [Importance of specialized centers in diagnosis and treatment of extremity-soft tissue sarcomas. Review of 603 cases]. *Chirurg.* 2009;80(4):341-47 [in German]
13. Bannasch H, Eisenhardt SU, Grosu AL, et al. The diagnosis and treatment of soft tissue sarcomas of the limbs. *Dtsch Arztebl Int.* 2011;108(3):32-38
14. Burchill SA. Ewing's sarcoma: Diagnostic, prognostic, and therapeutic implications of molecular abnormalities. *J Clin Pathol.* 2003;56(2):96-102
15. Patnaik S, Yarlagadda J, Susarla R. Imaging features of Ewing's sarcoma: Special reference to uncommon features and rare sites of presentation. *J Cancer Res Ther.* 2018;14(5):1014-22

Ewing sarcoma is the second most common malignant bone tumor in children [14]. It involves the long bones and presents radiologically as a destructive bone lesion with interrupted periosteal reaction. However, uncommon radiological features are reported to occur in 8% of cases. For example, soft tissue calcification, as observed in the present case, is considered an unusual radiological finding and represents debris of a periosteal bone reaction [15]. In addition to its diagnostic role, MRI permits accurate anatomic analysis and biopsy planning [13].

Conclusions

Ewing sarcoma can present with a clinical picture similar to that of a traumatic hematoma. Hence, this case highlights the need to consider soft tissue tumors as a differential diagnosis in patients presenting with an expanding swelling. Primary care physicians should have a high index of suspicion for malignancies and should not be reluctant to refer patients for further investigations in cases exhibiting an unusual clinical course of the condition.

Conflicts of Interest

None.