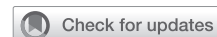

# Surgery for posterior wall rupture of a left main trunk coronary artery aneurysm



Hiroko Taguchi, MD, Kikuko Obase, MD, PhD, Junichiro Eishi, MD, Shun Nakaji, MD, PhD, Takashi Miura, MD, PhD, and Kiyoyuki Eishi, MD, PhD, Nagasaki, Japan

From the Department of Cardiovascular Surgery, Nagasaki University Hospital, Nagasaki, Japan.

Disclosures: The authors reported no conflicts of interest.

The *Journal* policy requires editors and reviewers to disclose conflicts of interest and to decline handling or reviewing manuscripts for which they may have a conflict of interest. The editors and reviewers of this article have no conflicts of interest.

Received for publication June 27, 2022; revisions received Aug 8, 2022; accepted for publication Aug 18, 2022; available ahead of print Aug 27, 2022.

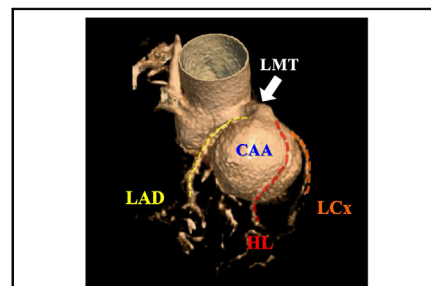
Address for reprints: Takashi Miura, MD, PhD, Department of Cardiovascular Surgery, Nagasaki University Hospital, 1-7-1 Sakamoto, Nagasaki-City 852-8501, Japan (E-mail: [takashiren@yahoo.co.jp](mailto:takashiren@yahoo.co.jp)).

JTCVS Techniques 2022;16:96-8

2666-2507

Copyright © 2022 The Author(s). Published by Elsevier Inc. on behalf of The American Association for Thoracic Surgery. This is an open access article under the CC BY-NC-ND license (<http://creativecommons.org/licenses/by-nc-nd/4.0/>).

<https://doi.org/10.1016/j.jtc.2022.08.014>



The CAA at the bifurcation of the LMT and the course of HL branches on the CAA.

## CENTRAL MESSAGE

A ruptured giant CAA is a remarkably rare and fatal condition. This case report provides an important example of a successful life-saving surgical treatment.

▶ Video clip is available online.

The incidence of left main coronary artery aneurysms (CAAs) is 0.1%.<sup>1</sup> Most patients with CAAs are asymptomatic; however, symptomatic patients can experience severe life-threatening complications such as rupture.<sup>2</sup>

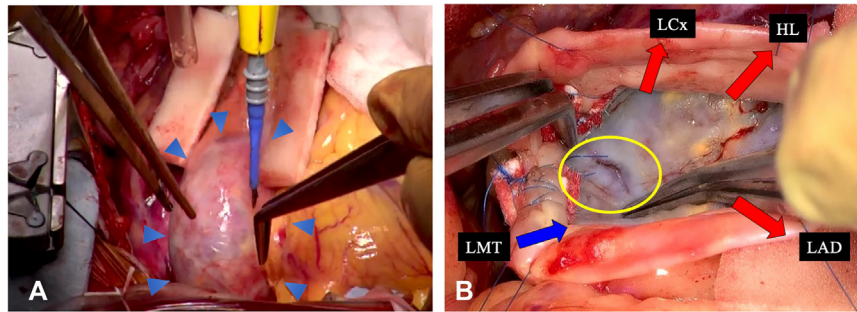
## CASE

A 77-year-old woman presented to our emergency department unconscious. She had no history of Kawasaki disease or other infectious/inflammatory diseases. On admission, her systolic blood pressure and heart rate were 70 mm Hg and 105 beats per minute, respectively. Electrocardiography confirmed ST depression in leads V<sub>3</sub>, V<sub>4</sub>, V<sub>5</sub>, and V<sub>6</sub>, and transthoracic echocardiography revealed pericardial effusion and diastolic collapse of the right atrium and ventricle. Enhanced computed tomography (CT) imaging was performed for suspected aortic dissection. A large CAA (3.9 × 4.2 cm) at the left main trunk (LMT) bifurcation, pericardial effusion, and a hematoma on the left ventricle lateral wall were detected.

The patient underwent emergency surgery for CAA rupture-induced cardiac tamponade. After median sternotomy, a moderate amount of bloody effusion was removed through a small pericardiotomy opening, and her blood pressure was carefully controlled. After cardiopulmonary bypass was established with ascending aortic perfusion and right atrium drainage, the hematoma in the cardiac sac was removed. No bleeding was observed on the aneurysm surface (Figure 1, A). Cold blood cardioplegia was

performed via injection into the aortic root after cross-clamping the ascending aorta.

When cardioplegia and bypass were established, coronary artery bypass grafting (CABG) with 2 saphenous veins was performed. The grafts were anastomosed to the left anterior descending artery (LAD) and posterolateral coronary artery. The aneurysm was opened. The LMT inlet and outlets of the LAD, left circumflex artery (LCx), and high lateral branches were confirmed in the lumen. The rupture site was detected at the bottom of the aneurysm, closely attached to the myocardium (Figure 1, B; Video 1). The inlet, 3 outlets, and tear were closed with pledgeted suturing. The opened aneurysmal wall was partially resected and closed with pledgeted suturing to avoid a pseudoaneurysm. Preoperative CT imaging showed the proximal LMT was not aneurysmal, and a boundary between the aneurysm and LMT was clear; hence, the aorta was not opened to inspect the orifice. Additional cardioplegia was induced by injection through the saphenous vein grafts (SVGs). Subsequently, 1 of the 2 SVGs, which were anastomosed to the posterolateral artery, was anastomosed to the high lateral branch in a side-to-side sequential fashion. Finally, the proximal ends of the SVGs were anastomosed to the ascending aorta.



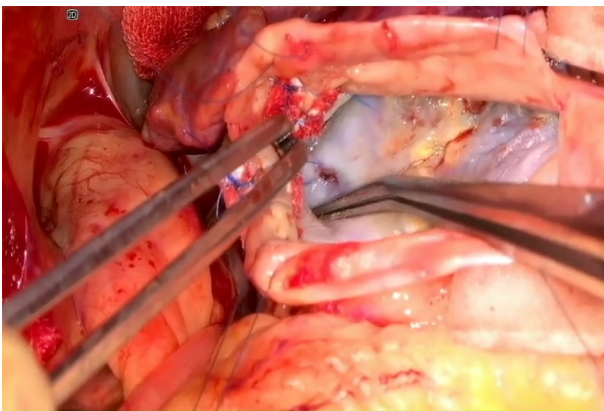
**FIGURE 1.** Intraoperative images. A, Active bleeding was not observed on the surface of the aneurysm. *Blue triangles* indicate the aneurysm. B, After opening the aneurysm, the rupture site (indicated with the *yellow circle*) was detected at the rear wall. The *blue* and *red arrows* indicate the inflow and the 3 outflows of the aneurysm, respectively. *LCx*, Circumflex coronary artery; *HL*, high lateral branch; *LMT*, left main trunk; *LAD*, left anterior descending artery.

Aortic crossclamp and cardiopulmonary bypass times were 170 and 231 minutes, respectively. The postoperative course was uneventful, and the patient was discharged on postoperative day 28. Postoperative enhanced CT imaging showed CAA disappearance and coronary artery bypass graft patency (Figure 2). The patient provided written informed consent for publication of this case report. Nagasaki University Hospital Clinical Research Ethics Committee approved the case report and publication of data (approval number.: 22062027; approval date: June 20, 2022).

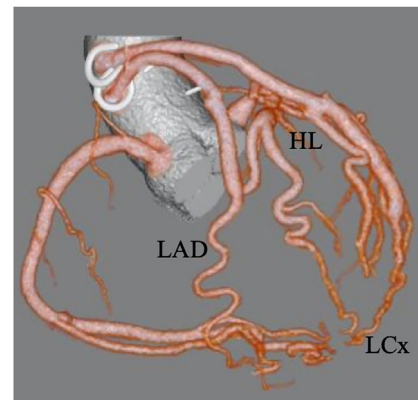
## DISCUSSION

CAA is a coronary dilatation that exceeds the diameter of normal adjacent segments by 1.5-fold.<sup>2</sup> The most common site is the right coronary artery, followed by the LAD and LCx. Left main CAAs are extremely rare.<sup>1</sup> Among 3 previously reported cases of ruptured left main CAAs,<sup>2-4</sup> 1 underwent successful endovascular treatment; however, postmortem diagnosis was made in the others without mention of the exact rupture sites.

CAAs can be managed with surgical treatment, percutaneous coronary intervention, or medical treatment,<sup>5-7</sup> although the treatment choice is uncertain. Surgical treatment is selected on the basis of aneurysm size and shape and the presence or absence of fistulas. Surgical strategies include reconstruction, resection, and ligation with concomitant CABG.<sup>1,6,7</sup> This patient underwent aneurysmal removal with CABG, commonly used for ruptured CAAs because of its emergency nature. One concern about this operation is the potential risk of pseudoaneurysm formation at the closed terminal LMT. The proximal suture ligation of the LMT is technically challenging. In this case, the boundary between the aneurysm and LMT was clear; therefore, the proximal of the LMT was not closed. If the aneurysm was present in the proximal LMT, we would have opened the aorta and reconstructed the Valsalva sinus with patch materials such as bovine pericardium. The interposition technique might also be considered using an internal thoracic artery graft from the left main coronary artery to the LCx; it might be preferable for pseudoaneurysm-related concerns.<sup>5</sup> Although



**VIDEO 1.** The rupture site was detected at the bottom of the aneurysm. Video available at: [https://www.jtcvs.org/article/S2666-2507\(22\)00453-9/fulltext](https://www.jtcvs.org/article/S2666-2507(22)00453-9/fulltext).



**FIGURE 2.** Postoperative computed tomography image. The aneurysm had disappeared, and the 2 saphenous vein grafts bypassed to the left anterior descending artery (*LAD*), high lateral branch (*HL*), and circumflex coronary artery (*LCx*; enhanced).

the internal thoracic artery remains the gold standard for LAD grafting, we chose SVGs to secure a route for cardioplegia injection during surgery. Our case suggests that a posterior wall rupture close to the myocardium, in contrast to a surface rupture, might balance a patient's hemodynamics under the special conditions of cardiac tamponade, allowing time for emergency surgery, thereby saving the patient's life.

A question surrounding cardiac tamponade treatment is whether to perform subxiphoid pericardiocentesis before surgery. Hypertension after tamponade release might cause repeat rupture.<sup>2</sup> In cases with stable hemodynamics with medical treatment, emergency surgery without pericardiocentesis is reasonable to save the patient's life. Pericardiotomy with careful blood pressure control is required during surgery.

### References

1. Sokmen G, Tuncer C, Sokmen A, Suner A. Clinical and angiographic features of large left main coronary artery aneurysms. *Int J Cardiol.* 2008;123:79-83.
2. Daneshvar DA, Czak S, Patil A, Wasserman PG, Coplan NL, Garratt KN. Spontaneous rupture of a left main coronary artery aneurysm. *Circ Cardiovasc Interv.* 2012;5:e63-5.
3. Blackman A, Mohammed W. Giant coronary artery aneurysm at autopsy. *BMJ Case Rep.* 2018;2018:bcr-2017222816.
4. Torii S, Ohta H, Morino Y, Nakashima M, Suzuki Y, Murata S, et al. Successful endovascular treatment of rupture of mycotic left main coronary artery aneurysm. *Can J Cardiol.* 2013;29:1014.e7-9.
5. De Hous ND, Haine S, Oortman R, Laga S. Alternative approach for the surgical treatment of left main coronary artery aneurysm. *Ann Thorac Surg.* 2019;108:e91-3.
6. Sheikh AS, Hailan A, Kinnaird T, Choudhury A, Smith D. Coronary artery aneurysm: evaluation, prognosis, and proposed treatment strategies. *Heart Views.* 2019; 20:101-8.
7. Beckman E, Rustum S, Marquardt S, Merz C, Shrestha M, Martens A, et al. Surgical treatment of coronary artery aneurysms. *J Card Surg.* 2017;32:674-9.