

Bilious pleuritis due to hepatic microwave ablation

Two illustrative cases and literature review

Meimei Wu, MS^{a,b}, Qi Zhu, BS^a, Lingling Chen, MS^a, Dong Yan, MD^{b,c,*}

Abstract

Ultrasound guided percutaneous thermal ablation has been well acknowledged in treating hepatic malignancy. Although thermal ablation is safe for the treatment, it may induce some lethal complications such as diaphragmatic injury, bile-stained pleural fistula, and bilious pleuritis.

We presented 2 cancer patients in hepatic diaphragmatic dome showed diaphragmatic injury, bile-stained pleural fistula, and bilious pleuritis after microwave ablation (MVA). The symptoms were attenuated after chest drainage and anti-infection therapy. In the literature review, 17 articles published in the recent 10 years on diaphragmatic injury after MVA for treating hepatic cancer were available. Twenty-three cases were obtained, among which 2 showed bilious pleuritis after radiofrequency treatment. Most of the lesions were adjacent to the diaphragm. Among the articles reporting the localization of lesions, most of the cases showed lesions in S8, 2 in S7, 3 in S4, and 3 in S5, respectively. Surgical recovery was required for the patients with massive diaphragmatic injury. Only 2 cases underwent thoroscopic surgery. After chest drainage and anti-infection, their symptoms were attenuated to some extent.

Radiofrequency or MVA may induce pleural effusion, and special attention should be paid to the diaphragmatic injury induced by thermal ablation.

Abbreviations: CT = computer tomography, MVA = microwave ablation, RFA = radiofrequency ablation, TACE = transcatheter arterial chemoembolization.

Keywords: artificial ascites, bilious pleuritis, hepatic, microwave ablation

1. Introduction

Ablation is one of the major treatment options for metastatic liver cancer and primary liver cancer. Currently, there are several ablation

Editor: Leyi Wang.

This study was supported by the National Science and Technology Major Project (2018ZX10101-001).

The authors have no conflicts of interest to disclose.

The datasets generated during and/or analyzed during the current study are available from the corresponding author on reasonable request.

^a Department of Hepatobiliary Surgery, Fuzhou Second Hospital Affiliated to Xiamen University, Fuzhou, ^b Department of Infection, the First Affiliated Hospital, Zhejiang University, Hangzhou, China., ^c State Key Laboratory for Diagnosis and Treatment of Infectious Diseases, National Clinical Research Center for Infectious Diseases, National Medical Center for Infectious Diseases, Collaborative Innovation Center for Diagnosis and Treatment of Infectious Diseases, The First Affiliated Hospital, College of Medicine, Zhejiang University 79 Qingchun Rd, Hangzhou, China.

* Correspondence: Dong Yan, Collaborative Innovation Center for Diagnosis and Treatment of Infectious Diseases, State Key Laboratory for Diagnosis and Treatment of Infectious Diseases, The First Affiliated Hospital, College of Medicine, Zhejiang University, Hangzhou 310003, China (e-mail: yandongh@163.com).

Copyright © 2020 the Author(s). Published by Wolters Kluwer Health, Inc. This is an open access article distributed under the terms of the Creative Commons Attribution-Non Commercial License 4.0 (CCBY-NC), where it is permissible to download, share, remix, transform, and buildup the work provided it is properly cited. The work cannot be used commercially without permission from the journal.

How to cite this article: Wu M, Zhu Q, Chen L, Yan D. Bilious pleuritis due to hepatic microwave ablation: two illustrative cases and literature review. *Medicine* 2020;99:44(e22763).

Received: 22 November 2019 / Received in final form: 4 August 2020 /

Accepted: 14 September 2020

<http://dx.doi.org/10.1097/MD.00000000000022763>

techniques, such as cryotherapy, laser ablation, microwave ablation (MVA), radiofrequency ablation (RFA), high power focused ultrasound ablation, and dehydrated alcohol injection. Among these techniques, MVA and RFA have been frequently utilized in clinical settings as they can hamper the cancer tissues via heat energy.^[1,2] Although thermal ablation is proved to be safe, it induces some complications such as postoperative infection, hemorrhage, pneumothorax, and adjacent organ damages.^[3,4] The most severe complications for MVA and RFA are diaphragmatic injury and perforation. In particular, the ablation to the adjacent diaphragmatic lesions may subsequently leads to empyema, bilious pleuritis, and bronchopleural fistula. In this study, we presented 2 cases with HCC presenting MWV-induced diaphragmatic perforation, and bile-stained pleural fluid. Besides, a literature review was performed to further summarize the treatment experiences on it.

2. Case presentation

A 46-year-old male patient presented to our department on October 25, 2016, due to dyspnea and shortness of breath for 2 days. He was diagnosed with hepatic cancer on September 15, 2016. Three months later, he received transcatheter arterial chemoembolization (TACE), ultrasound-guided fine-needle aspiration biopsy and MWV for treating hepatic tumor. Chest radiography and computer tomography (CT) indicated massive pleural effusion at the right body side. Then release of hydrothorax was performed via thoracentesis, and the dyspnea and shortness of breath showed attenuation. Nevertheless, repetitive fever occurred with a body temperature of up to 39.0°C. CT scan demonstrated deposition of lipiodol in the lesions beneath the diaphragm near the right liver, part of which leaked to the thoracic cavity. Additionally, effusion was noticed

in the right thoracic cavity. Routine blood examination findings were as follows: WBC, $7.5 \times 10^9/L$; neutrophil percentage, 83%; platelet, $339 \times 10^9/L$; C-reactive protein, 334.8 mg/L. Persistent thoracic drainage was given. The hydrothorax was in a brown color with a turbid texture, and the cell count was more than $10 \times 10^9/L$. The lactate dehydrogenase (LDH) was 24,783 U/L. The germculture for hydrothorax was negative. Hepatic CT scan and contrast enhanced scan indicated leakage of lipiodol into the thoracic cavity (Fig. 1). On this basis, diaphragmatic injury was considered. For the treatment, persistent thoracic drainage and anti-infection therapy were given for more than 1 month, and then the symptoms were eliminated. Pulmonary CT indicated the pleural effusion was almost absorbed. Finally, the patient was discharged from our department, and no pleural effusion related complications were available in the 1-year follow-up. Written informed consent was obtained from the patient. The study

protocols were approved by the Ethical Committee of Zhejiang University.

A 62-year-old female patient referred to our hospital on July 1, 2018, due to fever combined with upper abdominal pain for 4 days. The patient was diagnosed with hepatic cancer on July 2017. For the treatment, she received 4 courses of TACE and chemotherapy. Hepatic MR performed in May 2018 indicated postoperative TACE conditions for space-occupying lesions in right liver, and postoperative interventional conditions in liver S7, together with peripheral cancer activities. Additionally, small liver carcinoma was noticed in S7. Compared with the previous findings on March 4, the enhanced lesions showed increase in size. Therefore, color ultrasound-guided MVA was performed to the bilateral lesions on June 5, 2018. The power was set at 60 W, and the ablation duration was 6 minute. Three weeks after discharge, she showed fever (up to 39.9°C) and upper abdominal discomforts. No obvious dyspnea or shortness of breath was noticed. Pulmonary CT indicated right pleural effusion and less pneumatosis, combined with atelectasis in the superior lobe of right lung. Part of the effusion was wrapped. Deposition of lipiodol was observed in the thoracic cavity (Fig. 2). Hepatic MR demonstrated diaphragmatic defect (3.8 cm). Routine blood examinations findings were as follows: WBC, $8.8 \times 10^9/L$; neutrophil percentage, 78.6%; hemoglobin, 100 mg/L; platelet,

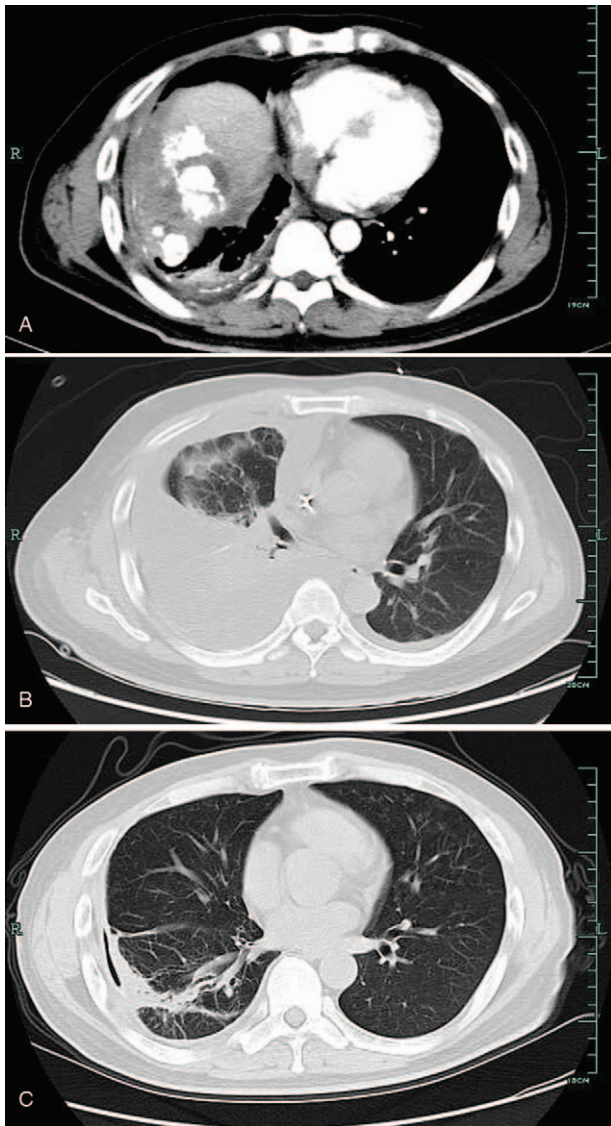


Figure 1. A. The liver capsule was not intact, and leakage of lipiodol was noticed in the right thoracic cavity. B. Massive pleural effusion. C. The pleural effusion was absorbed almost as revealed by computer tomography scan.

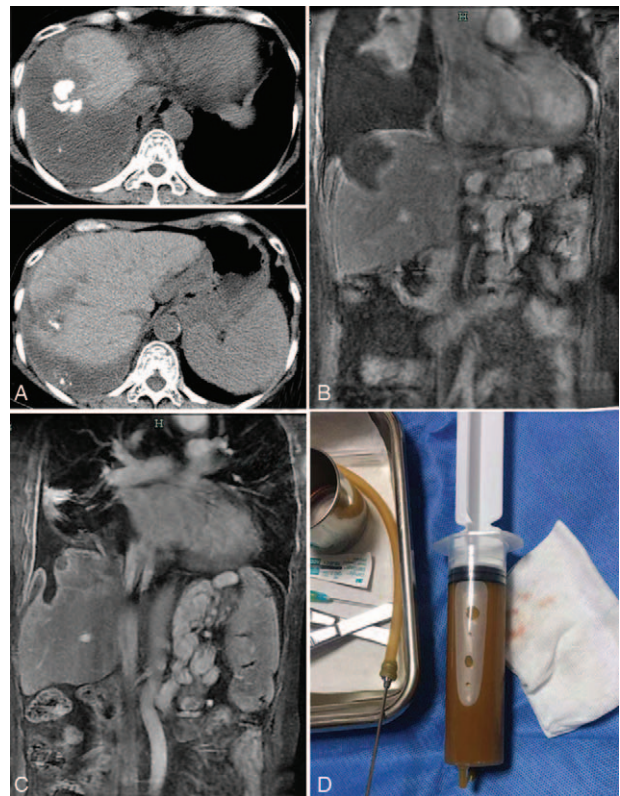


Figure 2. A. Massive pleural effusion was observed in the upper part, and leakage of lipiodol was noticed in the thoracic cavity. B. The liver capsule was almost coincident with the diaphragma. Local defect was noticed in diaphragma (3.8 cm). The liver ablation area was communicated with the thoracic cavity. C. Obvious attenuation was noticed in the volume of hydrothorax about 1 month after treatment. The size of the diaphragmatic defect showed significant decline (1.7 cm). D. hydrothorax was in a color of chocolate.

$103 \times 10^9/L$; C-reactive protein, 159.9 mg/L. Hydrothorax in a chocolate color (700 mL) was observed after thoracentesis. The Rivalta test findings were negative. The cell count was $7500/\mu L$. The percentage of neutrophil was 93%. The LDH concentration was 10,186 U/L. For the hydrothorax culture, multidrug resistance of *Escherichia coli* and *Enterococcus faecalis* was observed. On this basis, primary liver cancer (post-MVA) was considered, together with diaphragmatic injury, bilious pleuritis and bile-stained pleural fluid. Subsequently, the symptoms were attenuated after anti-infection therapy using tigecycline and linezolid, and the drainage volume from thoracic cavity showed gradual decrease. Finally, the drainage tube was removed and the patient was discharged from our department. The patient was followed up until now, and she showed no disease progression, fever or pleural effusion.

3. Discussion

The most effective strategy for treating HCC is liver transplantation, as it may lead to attenuation of the potential hepatic diseases. Nevertheless, due to rarity of donor organs, most of the HCC cases do not receive liver transplantation. During the RFA and MWA, thermal ablation may trigger cell apoptosis and the migration of antigen presenting cells and immune effector cells, which promoted the specific anti-cancer immunological reactions.^[5] Therefore, percutaneous thermal ablation, RFA and MWA were considered an alternation for the surgery. RFA and MWA show high safety for treating cancer nodules. The major complications for RFA are thermal injuries to the adjacent organs of liver, with a prevalence of 3.54%. In most cases, the complications are characterized by hemorrhage, liver functional lesions, liver failure, infection, intestinal perforation, pneumothorax and hemothorax. Generation of radiofrequency induced pleural effusion is usually associated with the injury of pleura. In rare conditions, patients may present diaphragmatic injury and bilious pleuritis, which may be related to the application of telescopic lobes and inadequate RF localization.^[6] In a previous study, Kobayashi et al reported a 84-year-old male HCC patients presenting right thoracalgia about 24 days after ablation. Imaging technique indicated massive pleural effusion. Contrast enhanced CT scan revealed leakage of contrast media from hepatic lesions to thoracic cavity, which proved that there might be communication between lesions and thoracic cavity. The sagittal plan of the CT clearly displayed diaphragmatic defect. After thoracoscopic repairment and nasobiliary drainage, the symptoms showed attenuation.^[7] Recently, Kalin et al reported a 55-year-old liver metastasis patient presenting dyspnea, shortness of breath and upper abdominal pain about 6 weeks after RF. Imaging technique and examination confirmed pleural effusion and the hydrothorax was in a brown color. The bilirubin level was 185 mmol/L. Hydrothorax culture indicated presence of gastro-enteric bacteria (i.e., *E faecalis* and *E coli*). Besides, there were bilirubin and gastrointestinal tract organisms in the hydrothorax. On this basis, communication between liver and pleural space was considered. Afterwards, thoracic and abdominal CT sagittal reconstruction demonstrated diaphragmatic defect, together with communication between the ablation area and supradiaphragmatic thoracic cavity.^[8]

Our cases were similar with these 2 cases presenting bilious pleuritis after RFA above mentioned. All the cases showed a history of TACE. Meanwhile, CT scan revealed leakage of

lipiodol from the hepatic lesions to the thoracic cavity, which indicated the lesions were communicated with the thoracic cavity. Indeed, there are some differences. The complications in our cases were induced by MVA. Actually, MVA and RFA utilize heat energy to ablate the tumor via the probes, which shows similarity in complications. Compared with RFA, MVA is featured by large ablation area, high intra-tumor temperature, short ablation duration and rapid temperature rising. These cases showed lesions with a size of > 5 cm, all of whom received MVA for the treatment. The lesions were close to the envelope in distance, and the lesion of HCC was large (> 5 cm). The microwave ablation size was large. On this basis, diaphragmatic inflammation and perforation triggered by thermal injury were considered. As the perforated diaphragm was adhered with the local liver capsule, no symptoms of acute abdomen were observed.^[9] In the ablation region, there might be small cholangitic lesions and injuries, which may trigger bile leakage to the thoracic cavity. Pleural aspirate confirmed fluid culture grew gastrointestinal tract bacteria (*E. faecum*, *E coli*). Additionally, similar with previous study,^[10] the inflammatory reaction and bile may stimulate the generation of pleural effusion, which then resulted in bile-stained empyema (Figs. 1A and 2A). For the treatment, anti-infection therapy was given using antibiotics together with persistent drainage to the pleural effusion. For Case 1, the pleural effusion showed gradual decrease after treatment until complete absorption (Fig. 1D). For Case 2, antibiotic-based anti-infection therapy and persistent thoracic close drainage were given, and 1 month later, the fever and shortness of breath showed attenuation. Nevertheless, brown liquid in a volume of 60 to 80 mL was drained. The diaphragmatic defect showed obvious decrease in size as revealed by sagittal view of CT. Two months later, the drainage volume was only 3 to 5 mL. CT scan indicated the volume of pleural effusion was small, and the effusion was wrapped. Then the drainage tube was removed, followed by local dressing. No exudate was noticed in the gauze 1 week later, and the pleural effusion was almost absorbed as revealed by CT scan.

Diaphragmatic defect or perforation and biliary duct injury are the major causes for bilious pleural fistula. We searched the PubMed and Embase databases using the following We conducted a literature review in the recent 10 years; and a total of 18 articles^[7,8,11-26] involving 23 cases on ablation induced diaphragmatic defect were obtained (Table 1). Among the 23 cases; 90% of the lesions were localized near the diaphragm. Among the articles reporting the localization of lesions; 14 cases showed lesions in S8; 2 in S7; 3 in S5, and 3 in S4; respectively. No one received MVA; and 21 received RFA. About 60% of the cases showed pleural effusion; among which 1 showed bilious pleural effusion.^[15] For the articles reporting liver function; about 60% of the cases showed a Child-plgh grade of B (7-9 score). The diagnosis duration was about 28 months. One case presented diaphragmatic perforation 24 days after ablation; and the resting cases showed diaphragmatic perforation at least 2 months after ablation in which 1 showed perforation 8 years after ablation.^[13] Our cases and another 2 cases with bilious pleuritis were initially manifested as pleural effusion with or without infection related symptoms. The prevalence of pleural effusion after thermal ablation was 7.4%.^[25] In cases of repetitive pleural effusion after ablation; special attention should be paid to the diaphragmatic defect induced by persistent ablation. Specially; diaphragmatic injury should be considered in the presence of ablation near the adjacent lesions of diaphragm.^[14] Moreover; bilious pleural effusion may also serve as an indirect sign for diaphragmatic

Table 1
Information of the publications.

| Author, year | Gender | Age | Tumor position/size | Time to the last ablation (mo) | Symptoms | With or without pleural effusion | Obvious abdominal pain | Treatment | Prognosis and survival |
|----------------------------|--------|-----|--|--------------------------------|---|----------------------------------|--|---|---|
| Koda M et al, 2003 | F | 61 | S8/2.5 | 8 | Intestinal obstruction, pleural effusion | With | No | Surgery | 1 mo, rupture |
| Shibuya A et al, 2006 | M | 72 | S8/1, peri-diaphragm S4, S8/2.8, peri-diaphragm | 18 | Abdominal pain and dyspnea | Without | Yes | Surgery | Discharged with satisfactory conditions |
| di Francesco F et al, 2008 | M | 49 | Right liver/5.4, peri-diaphragm | 15 | | | | Surgery | Discharged with satisfactory conditions |
| Nawa T et al, 2010 | M | 50 | S8/2.2, peri-diaphragm | 20 | Chest pain and dyspnea | Without | Chest pain | Surgery | Discharged with satisfactory conditions |
| Lin MW et al, 2010 | M | 47 | Right liver, the size was not mentioned | 3 | Refractory pleural effusion | With | No | Laparoscopy | Discharged with satisfactory conditions |
| Yamegami T et al, 2010 | F | 71 | S7/2.38, peri-diaphragm | 9 | Dyspnea | With | No | Conservative therapy | Discharged with satisfactory conditions |
| Boissier F et al, 2011 | F | 65 | S7, peri-diaphragm | 7 | | | | Surgery | Discharged with satisfactory conditions |
| Singh M et al, 2011 | F | 46 | S5/S8, 1.5, peri-diaphragm | 11 | Chest pain | Without | Chest pain | Laparoscopy | Discharged with satisfactory conditions |
| Zhou M et al, 2013 | F | 61 | S8/1.5, peri-diaphragm | 12 | Abdominal pain, intestinal obstruction | Empyema | Chest pain | Surgery | Discharged with satisfactory conditions |
| Kim JS et al, 2013 | M | 61 | Sub-diaphragm S5/1.0 | 22 | | | | Surgery | Discharged with satisfactory conditions |
| Kobayashi T et al, 2014 | M | 84 | S8/1.3 | 24 | Abdominal pain and dyspnea | With, bilious pleural effusion | No | Thoracoscopic repair and nose/ bile duct drainage | > 1 yr |
| Nomura R et al, 2014 | M | 62 | S8, peri-diaphragm | 96 | Dyspnea and intestinal obstruction | With | No | Laparoscopy | Discharged with satisfactory conditions |
| Nakamura T et al, 2014 | M | 81 | S4/S8 | 18 | Intestinal obstruction and abdominal pain | Without | Abdominal pain | Surgery | Discharged with satisfactory conditions |
| Ho CM et al, 2014 | M | 49 | Single onset (not available) | 2 | Fever and abdominal pain | With, bilious pleural effusion | Abdominal pain | Surgery | Death, 1 mo post-treatment |
| Tomoko et al, 2015 | M | 81 | Not available | 18 | None | With | No | Surgery | 23 d, died from liver failure |
| Tomoyuki Abe et al, 2016 | M | 72 | S8, peri-diaphragm | 15 | Abdominal pain, dyspnea | With | Abdominal pain | Surgery | Discharged with satisfactory conditions |
| Nagasu S et al, 2017 | M | 49 | S4/1.7, peri-diaphragm | 17 | Abdominal pain, dyspnea | Without | No | Laparoscopy | Discharged with satisfactory conditions |
| | M | 79 | S8/1.9, peri-diaphragm | 9 | Abdominal pain, dyspnea | With | Abdominal pain | Laparoscopy | Discharged with satisfactory conditions |
| | M | 68 | S8/2.6 | 21 | | With | Abdominal pain | Laparoscopy | Discharged with satisfactory conditions |
| | F | 70 | S6/2.3, peri-diaphragm | 8 | Dyspnea | With | No | Laparoscopy | Discharged with satisfactory conditions |
| | M | 65 | S8/2.1, peri-diaphragm | 16 | | Without | Abdominal pain | Laparoscopy | Discharged with satisfactory conditions |
| | F | 76 | S8/2.0, peri-diaphragm | 6 | | Without | No | Laparoscopy | Discharged with satisfactory conditions |
| Asli Kalin et al, 2017 | M | 55 | S8, peri-diaphragm | 1.5 | Abdominal pain, dyspnea and shortness of breath | Yes, 7 mo after treatment | Right upper abdomen and right chest pain | Antibiotics (iv) for 6 wk | Discharged with satisfactory conditions |

defect. Whereas; the bilious pleural effusion could be identified by evaluating pH value; bilirubin content^[7] or ratio of pleural effusion to serum bilirubin (>1).^[8]

Diaphragmatic injuries mainly consisted of needle tract injury and thermal injury. The needle tract injury is associated with the ablation path. For instance, the trans-thoracic RFA is easily to trigger pricking wound of diaphragm. Thermal injury is mainly related to the lesion location, size, and hepatic function.^[24] Particularly, thermal injury is easily triggered in cases of a distance of less than 1 cm from thermal injury margin to the hepatic surface.^[27] In this literature review, more than 90% of the lesions in the 21 cases were localized near the diaphragm. In order to reduce the possibility of thermal injury of diaphragm, it is crucial to increase the distance between the diaphragm and ablation area. The diaphragmatic perforation is presented at least 2 months after ablation. Such delay may be associated with the fact that the thermal injury of diaphragm did not trigger defect, but it triggered inflammation and fibrosis that finally resulted in defect even after attenuation.^[25] The other reason is that the subdiaphragmatic lesions showed atrophy and fibrosis after ablation, which led to generation of Chlaiditi sign. On this basis, the intestinal canal may enter such space, which may result in diaphragmatic hernia. This is consistent with the fact that about half of the cases with diaphragmatic defect combined with intestinal canal hernia.^[20]

Spontaneous recovery may be obtained in the majority of cases with slight diaphragmatic injuries. Thoracic drainage and anti-infection therapy are the major treatment options for bilious pleural fistula. In cases with severe defect, surgery especially transabdominal surgery is required. In this literature review, 2 cases received surgery under the guidance of thoracoscope. For the patients with poor tolerance to surgery, the following treatment options are usually given:

- (i) Nasobiliary drainage tube was placed in order to attenuate the intra-biliary tract pressure, which then inhibited the possibility of bilious pleural fistula. Some studies proposed the percutaneous transhepatic biliary drainage in the lesions sites.
- (ii) Re-ablation may induce solidification and necrosis of lesions to the thoracic cavity, which then inhibited the leakage of bile from the thoracic cavity.
- (iii) Liver transplantation is the basic method for primary lesions and bilious pleural fistula related complications. If possible, it should be the preferred treatment. Our cases showed gradual decrease in the drainage volume from thoracic cavity. Besides, the size of diaphragmatic injury site showed gradual decrease. After taking the health conditions and surgical risks into consideration, drainage and anti-infection therapy were given. All the cases showed satisfactory outcomes after surgery.

Nowadays, great advances have been achieved in the RF and MVA. Contrast enhanced US could provide accurate position for the thermal ablation and may serve as an effective method to evaluate the efficiency of ablation.^[28,29] Intraperitoneal water infusion (artificial ascites) and artificial pleural effusion can be used to ameliorate the diaphragmatic injuries induced by ablation of critical regions. These procedures contribute to the interference of gas on ultrasonic findings and increase of the distance between ablation area and diaphragm.^[30] During the color ultrasound guided ablation, the imaging of tumor is easily interfered by the air in lung due to sonic spread. Artificial ascites could improve the

ultrasonic images, and increase the distance between the lesions and diaphragm, which then protected the diaphragm and lung from thermal injuries.^[31] In this study, artificial ascites was utilized in this study, however, it is inevitable that diaphragmatic injury and bilious pleural fistula may occur.

In summary, diaphragmatic defect and bilious pleuritis are rare complications induced by thermal injury during ablation. Special attention should be paid to the hepatic tumor adjacent to the diaphragm. There might be possibilities of diaphragmatic injury in cases of postoperative thoracic infection. For the patients with refractory pleural effusion, it is necessary to identify whether it is bilious pleural effusion, or whether it is associated with diaphragmatic injury. This facilitates the early diagnosis and treatment for diaphragmatic injury.

Author contributions

WMM wrote the manuscript; YD revised the manuscript; ZQ did the data analysis; CLL did the data collection.

Conceptualization: Qi Zhu.

Data curation: Qi Zhu.

Formal analysis: Meimei Wu.

Funding acquisition: Qi Zhu.

Investigation: Qi Zhu.

Software: Lingling Chen.

Supervision: Lingling Chen.

Validation: Lingling Chen.

Visualization: Lingling Chen.

Writing – original draft: Meimei Wu.

Writing – review & editing: dong yan.

References

- [1] Solbiati L, Ierace T, Tonolini M, et al. Radiofrequency thermal ablation of hepatic metastases. *Eur J Ultrasound* 2001;13:149–58.
- [2] Andromanakos N, Filippou D, Papadopoulos V, et al. New concepts in the therapeutic options of liver metastases from colorectal cancer. *J Buon* 2007;12:445–52.
- [3] Livraghi T, Solbiati L, Meloni MF, et al. Treatment of focal liver tumors with percutaneous radiofrequency ablation: complications encountered in a multicenter study. *Radiology* 2003;226:441–51.
- [4] Goldberg SN, Gazelle GS, Mueller PR. Thermal ablation therapy for focal malignancy: a unified approach to underlying principles, techniques, and diagnostic imaging guidance. *AJR Am J Roentgenol* 2000;174:323–31.
- [5] Dumolard L, Ghelfi J, Roth G, et al. Percutaneous ablation-induced immunomodulation in hepatocellular carcinoma. *Int J Mol Sci* 2020;21:E4398.
- [6] Pascual S, Herrera I, Irurzun J. New advances in hepatocellular carcinoma. *World J Hepatol* 2016;8:421–38.
- [7] Kobayashi T, Katsumi S, Wada Y, et al. A case of hepatocellular carcinoma complicated by pleural effusion mixed with bile after radiofrequency ablation. *Nihon Shokakibyō Gakkai Zasshi* 2014;111:1128–34.
- [8] Kalin AMH. Bilious pleuritis following trans-pulmonary radio frequency ablation of liver metastases. *Thorax* 2018;73:493–4.
- [9] Kwon HJ, Kim PN, Byun JH, et al. Various complications of percutaneous radiofrequency ablation for hepatic tumors: radiologic findings and technical tips. *Acta Radiol* 2014;55:1082–92.
- [10] Kawai K, Yata YKH. A case of diaphragmatic hernia induced by percutaneous radiofrequency ablation under the artificial pleural effusion for the hepatocellular carcinoma after 13month period. *Kanzo* 2005;46:665–6.
- [11] Shibuya A, Nakazawa T, Saigenji K, et al. Diaphragmatic hernia after radiofrequency ablation therapy for hepatocellular carcinoma. *AJR Am J Roentgenol* 2006;186:S241–3.

- [12] di Francesco F, di Sandro S, Doria C, et al. Diaphragmatic hernia occurring 15 months after percutaneous radiofrequency ablation of a hepatocellular cancer. *Am Surg* 2008;74:129–32.
- [13] Nomura R, Tokumura H, Furihata M. Laparoscopic repair of a diaphragmatic hernia associated with radiofrequency ablation for hepatocellular carcinoma: lessons from a case and the review of the literature. *Int Surg* 2014;99:384–90.
- [14] Lin MW, Lee JM. Video-assisted thoracoscopic surgery for diaphragmatic defect complication with refractory hydrothorax related to radiofrequency ablation. *J Formos Med Assoc* 2010;109:673–5.
- [15] Yamagami T, Yoshimatsu R, Matsushima S, et al. Diaphragmatic hernia after radiofrequency ablation for hepatocellular carcinoma. *Cardiovasc Intervent Radiol* 2011;34(Suppl 2):S175–7.
- [16] Boissier F, Labbe V, Marchetti G, et al. Acute respiratory distress and shock secondary to complicated diaphragmatic hernia. *Intensive Care Med* 2011;37:725–6.
- [17] Singh M, Singh G, Pandey A, et al. Laparoscopic repair of iatrogenic diaphragmatic hernia following radiofrequency ablation for hepatocellular carcinoma. *Hepatol Res* 2011;41:1132–6.
- [18] Zhou M, He H, Cai H, et al. Diaphragmatic perforation with colonic herniation due to hepatic radiofrequency ablation: A case report and review of the literature. *Oncol Lett* 2013;6:1719–22.
- [19] Kim JS, Kim HS, Myung DS, et al. A case of diaphragmatic hernia induced by radiofrequency ablation for hepatocellular carcinoma. *Korean J Gastroenterol* 2013;62:174–8.
- [20] Nakamura T, Masuda K, Thethi RS, et al. Successful surgical rescue of delayed onset diaphragmatic hernia following radiofrequency ablation for hepatocellular carcinoma. *Ulus Travma Acil Cerrahi Derg* 2014;20:295–9.
- [21] Ho CM, Liang PC. Diaphragm perforation after radiofrequency ablation for liver malignancy. *Oxf Med Case Reports* 2014;2014:32.
- [22] Saito T, Chiba T, Ogasawara S, et al. Fatal diaphragmatic hernia following radiofrequency ablation for hepatocellular carcinoma: a case report and literature review. *Case Rep Oncol* 2015;8:238–45.
- [23] Abe T, Amano H, Takechi H, et al. Late-onset diaphragmatic hernia after percutaneous radiofrequency ablation of hepatocellular carcinoma: a case study. *Surg Case Rep* 2016;2:25.
- [24] Nagasu S, Okuda K, Kuromatsu R, et al. Surgically treated diaphragmatic perforation after radiofrequency ablation for hepatocellular carcinoma. *World J Gastrointest Surg* 2017;9:281–7.
- [25] Koda M, Ueki M, Maeda N, et al. Diaphragmatic perforation and hernia after hepatic radiofrequency ablation. *AJR Am J Roentgenol* 2003;180:1561–2.
- [26] Nawa T, Mochizuki K, Yakushijin T, et al. A patient who developed diaphragmatic hernia 20 months after percutaneous radiofrequency ablation for hepatocellular carcinoma. *Nihon Shokakibyō Gakkai Zasshi* 2010;107:1167–74.
- [27] Mulier S, Mulier P, Ni Y, et al. Complications of radiofrequency coagulation of liver tumours. *Br J Surg* 2002;89:1206–22.
- [28] Min JH, Lim HK, Lim S, et al. Radiofrequency ablation of very-early-stage hepatocellular carcinoma inconspicuous on fusion imaging with B-mode US: value of fusion imaging with contrast-enhanced US. *Clin Mol Hepatol* 2014;20:61–70.
- [29] Nishigaki Y, Hayashi H, Tomita E, et al. Usefulness of contrast-enhanced ultrasonography using sonazoid for the assessment of therapeutic response to percutaneous radiofrequency ablation for hepatocellular carcinoma. *Hepatol Res* 2015;45:432–40.
- [30] Kudo M. Radiofrequency ablation for hepatocellular carcinoma: updated review in 2010. *Oncology* 2010;78(Suppl 1):113–24.
- [31] Wang CC, Kao JH. Artificial ascites is feasible and effective for difficult-to-ablate hepatocellular carcinoma. *Hepatol Int* 2015;9:514–9.