

# Mapping of endometriosis in patients with unilateral endometrioma

Raquel Silveira da Cunha Araujo, MD, MSc<sup>a,b,\*</sup>, Sabina Bastos Maia, MD, PhD<sup>a</sup>,  
Juliane Dornelas Lúcio, MD, PhD<sup>a</sup>, Moisés Diogo de Lima, MD, PhD<sup>a</sup>,  
Helizabet Salomão Abdalla Ayroza Ribeiro, MD, PhD<sup>b</sup>, Paulo Augusto Ayroza Galvão Ribeiro, MD, PhD<sup>b</sup>

## Abstract

To map the distribution of the sites most affected by endometriosis in patients with unilateral ovarian endometriomas.

A descriptive case series of 84 patients with unilateral endometriomas undergoing laparoscopy for the treatment of endometriosis. To evaluate the distribution of the sites of endometriosis lesions, the peritoneal compartments were divided into 5 zones: *zone 1*/the anterior compartment, including the anterior uterine serosa, vesicouterine fold, round ligament, and bladder; *zone 2*/the lateral compartment, including the left and right ovary, ovarian fossa, tubes, mesosalpinx, uterosacral ligaments, parametrium, and the ureter; *zone 3*/the posterior compartment, including posterior uterine serosa, the pouch of Douglas, posterior vaginal fornix, and bowel; *zone 4* consisting of the abdominal wall; and *zone 5* consisting of the diaphragm.

Of the 5 zones evaluated, the lateral compartment (zone 2) was the most affected, with 60.7% of the patients having dense adhesions around the left ovarian fossa and 57.1% around the right ovarian fossa. The ovarian endometriomas were more commonly found on the left side (54.8%) compared to the right (45.2%). In the posterior compartment (zone 3), the posterior cul-de-sac was obliterated in 51.2% of the patients. In the anterior compartment (zone 1), there were lesions in the vesicouterine fold in 30.9% of the patients and in the bladder in 19%. Lesions were found in the abdominal wall (zone 4) and diaphragm (zone 5) in 21.4% and 10.7% of patients, respectively.

Unilateral endometriomas are important markers of the severity of endometriosis.

**Abbreviations:** ASRM = American Society for Reproductive Medicine, DIE = deep infiltrating endometriosis.

**Keywords:** endometrioma, endometriosis, laparoscopy, mapping

## 1. Introduction

Ovarian endometriomas, which affect 17% to 44% of women with pelvic pain and infertility,<sup>[1]</sup> may impact ovulation, the number of follicles produced, and activity in the adjacent ovarian tissue.<sup>[2,3]</sup> Controversy persists regarding the physiopathology of endometriomas as well as with respect to the benefits of

conservative vs surgical treatment.<sup>[4,5]</sup> Treatment options include aspiration of fluid from the endometrioma, drainage of the cyst followed by bipolar coagulation, fenestration and laser ablation, cystectomy, and ultimately, oophorectomy.<sup>[6–8]</sup>

Laparoscopic cystectomy may improve pelvic pain and reduce the recurrence of endometriomas<sup>[8–10]</sup>; however, ovarian function could be impaired as a result.<sup>[11]</sup> Nevertheless, although surgery can be detrimental,<sup>[12]</sup> the endometrioma per se could explain ovarian damage.<sup>[13]</sup>

Deep infiltrating endometriosis (DIE) constitutes an aggressive form of the disease in which penetration extends more than 5 mm below the peritoneal surface.<sup>[14]</sup> DIE is associated with infertility and a variable degree of pelvic pain. This multifocal disease primarily affects the posterior pelvic compartment and frequently involves the uterosacral ligament, rectouterine pouch, and rectovaginal septum, as well as the bladder, ureter, and rectal wall.<sup>[15,16]</sup> Previous studies have shown that associated ovarian endometriomas function as a marker of greater severity of DIE.<sup>[14,15,17–19]</sup> Although the association between bilateral endometriomas and DIE has already been established, there is little information available on the specific association between unilateral endometriomas and concomitant lesions and the precise location of these lesions.<sup>[14]</sup>

This present paper evaluates the distribution of the sites of DIE lesions associated with unilateral ovarian endometriomas.

## 2. Methods

### 2.1. Study design

This descriptive case series included 84 patients with unilateral endometriomas who underwent laparoscopy between June 2018

Editor: Burak Bayraktar.

The authors have no funding and conflicts of interest to disclose.

The datasets generated during and/or analyzed during the current study are available from the corresponding author on reasonable request.

<sup>a</sup>Department of Obstetrics and Gynecology, Lauro Wanderley University Hospital, Federal University of Paraíba, João Pessoa, Paraíba, Brazil, <sup>b</sup>Gynecological Endoscopy and Endometriosis Division, Department of Obstetrics and Gynecology, Santa Casa de São Paulo School of Medical Sciences, São Paulo, São Paulo, Brazil.

\* Correspondence: Raquel Silveira da Cunha Araujo, Department of Obstetrics and Gynecology, Lauro Wanderley University Hospital, Federal University of Paraíba, João Pessoa, Paraíba 58059-900, Brazil (e-mail: raquel.silveira@gmail.com).

Copyright © 2021 the Author(s). Published by Wolters Kluwer Health, Inc. This is an open access article distributed under the terms of the Creative Commons Attribution-Non Commercial License 4.0 (CCBY-NC), where it is permissible to download, share, remix, transform, and buildup the work provided it is properly cited. The work cannot be used commercially without permission from the journal.

How to cite this article: Araujo RS, Maia SB, Lúcio JD, Lima MD, Ribeiro HS, Ribeiro PA. Mapping of endometriosis in patients with unilateral endometrioma. *Medicine* 2021;100:33(e26979).

Received: 25 February 2021 / Received in final form: 12 July 2021 / Accepted: 27 July 2021

<http://dx.doi.org/10.1097/MD.00000000000026979>

and March 2020. The details of the endometriosis lesions present concomitantly with the unilateral endometrioma were characterized.

All patients had undergone pre-operative imaging exams such as magnetic resonance imaging and/or pelvic ultrasound with prior bowel preparation and in all cases endometriosis was confirmed through direct visualization during laparoscopy. The area examined was divided into 5 different compartments including the peritoneal surface of the organs: *zone 1*, consisting of the anterior compartment and including superficial and deep lesions of endometriosis in the vesicouterine fold, round ligament, and bladder; *zone 2*, consisting of the lateral compartment and including lesions on the left and right ovary, left and right ovarian fossa, left and right tubes and mesosalpinx, left and right uterosacral ligaments, ureters, and the hypogastric nerves; *zone 3*, consisting of the posterior compartment, including posterior uterine serosa, the pouch of Douglas, posterior vaginal fornix, and bowel; *zone 4*, consisting of the abdominal wall; and *zone 5*, consisting of the diaphragm. Figures 1 to 3 illustrate the zone mapping. The procedures performed to treat the endometriosis lesions were described for each individual zone.

This study was conducted in compliance with the Brazilian National Health Council, Resolution 466/2012. The internal review board of the Medical Sciences Center, Federal University of Paraíba, approved the study protocol under reference CAAE 71621717.9.0000.8069. All the participants signed an informed consent form.

## 2.2. Study population and setting

Patients in whom ultrasonography had detected a unilateral ovarian cyst suggestive of an endometrioma and who were receiving care at the gynecological endoscopy outpatient division of the Lauro Wanderley University Hospital during the study period were screened for inclusion in a randomized clinical trial as described in a previously published protocol.<sup>[20]</sup>

Women  $\geq 18$  years of age with regular menstrual cycles (21–35 days), who had been diagnosed with a unilateral cyst suggestive

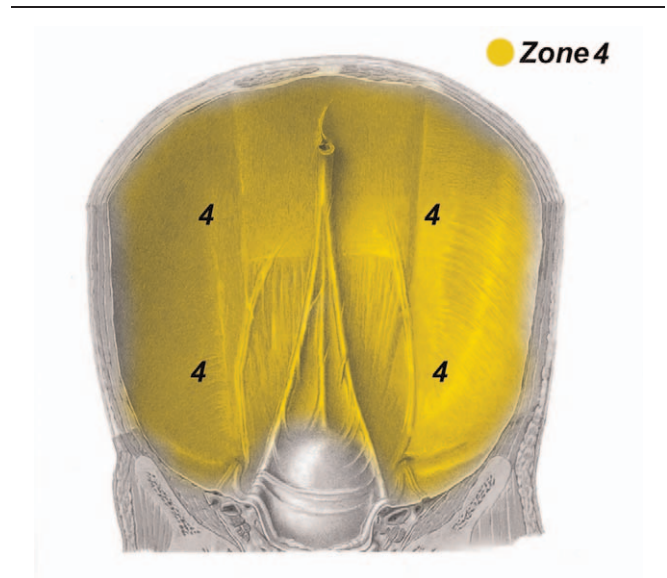


Figure 2. Schematic drawing showing zone 4.

of an endometrioma and for whom laparoscopic surgery was recommended to remove the cyst due to pelvic pain, infertility, or cyst recurrence, were eligible for inclusion in the study. The exclusion criteria for that original randomized clinical trial<sup>[20]</sup> consisted of: previous ovarian surgery; endocrine dysfunction such as diabetes, thyroid disorders, hyperprolactinemia, adrenal disease, and polycystic ovary syndrome; use of hormones in the preceding 3 months; suspected malignant ovarian neoplasm requiring oophorectomy; previous chemotherapy or radiotherapy; coagulation disorders; pregnancy; and autoimmune disease.

## 2.3. Procedures for laparoscopic surgery

In all cases, the procedures were performed under the management of the same multidisciplinary surgical team. Surgery was

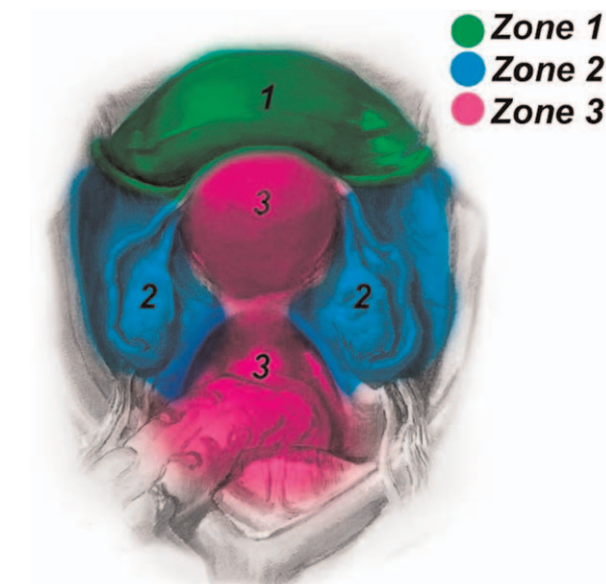


Figure 1. Illustration showing the distribution of pelvic zones 1, 2, and 3.

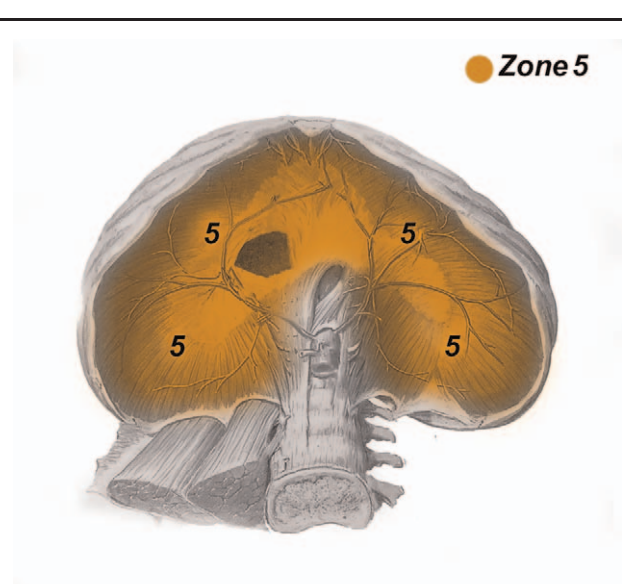


Figure 3. Schematic drawing showing zone 5.

**Table 1****Characteristics of the patients undergoing surgical laparoscopy for unilateral ovarian endometrioma (n=84).**

	Age	Weight	Height	Body mass index	Duration of surgery (minutes)	Size of the endometrioma
Mean	30.8	67.6	160.2	24.8	107.5	5.8
Median	31.0	66.0	160.5	25.0	108.0	5.3
Minimum	18	52	152	19	59	3.1
Maximum	44	84	170	32	138	12.4
Standard deviation	6.3	9.3	5.4	3.3	19.3	2.2
n	84	84	84	84	84	84

conducted under general anesthesia, with the woman in a semi-lithotomy position. Following insufflation into the peritoneal cavity and after pneumoperitoneum had been achieved a 10-mm umbilical puncture was performed to enable the camera to be placed into position. Three additional 5-mm punctures were made on the left and right iliac fossa and suprapubic area to allow instruments to be inserted. Intra-abdominal pressure was maintained at approximately 15 mm Hg.

Endometriosis staging was based on the 1997 revised American Society for Reproductive Medicine (ASRM) classification.<sup>[21]</sup> The fact that endometriomas were present meant that the initial score in this sample population was already indicative of stage III (16–40 points), or perhaps IV, bearing in mind that an endometrioma of 1 to 3 cm corresponds to 16 points.

For the lesions situated in zone 1, peritoneal resection of the vesicouterine fold and/or partial bladder resection was performed. For lesions in zone 2, the following procedures were performed: removal of the endometriomas using traction/counter-traction (stripping) techniques, ureterolysis, resection of the uterosacral ligaments, and re-implantation of the ureter. For the lesions situated in zone 3, the following procedures were performed: resection from the retrocervical region, dissection from the pararectal fossa, rectal shaving, segmental bowel resection, and resection of the posterior vaginal fornix. For lesions in zone 4, the peritoneal foci were resected. Lesions located in zone 5 were resected. Ureterolysis was performed prior to adhesiolysis in patients with dense adhesions in the ovarian fossa. Adhesiolysis was performed in all the zones and was used to separate the ovary from the adjacent structures whenever necessary. If a cyst ruptured, its contents were aspirated, and the site of spillage was thoroughly rinsed.

#### 2.4. Data collection, processing, and analysis

Data were collected prospectively on the day of the intervention onto a handwritten log. Statistical analysis was performed using Microsoft Excel and the SPSS statistical (SPSS, IBM Corp., Armonk, NY, US) software package for Windows, version 19.0.0. The categorical variables were described using frequency distribution, while measures of central tendency and dispersion were used for the numerical variables.

### 3. Results

Eighty-four women were included in this sample. Mean age was  $30.8 \pm 6.3$  years (range: 18–44 years). Mean weight was 67.6 kg, height 160.2 cm, and body mass index  $24.80 \pm 3.3$  kg/m<sup>2</sup>. The endometriomas varied in diameter from 3.1 to 12.4 cm and the mean duration of surgery was  $107.5 \pm 19.3$  minutes (Table 1). During surgery, significant differences were found in the

endometriomas, which ranged from a simple, low-complexity cyst to obliteration of the posterior cul-de-sac. In all cases, histopathology confirmed the presence of endometriosis at all the sites affected by lesions. All the participants had moderate or severe endometriosis, with 45 of the women (53.6%) being classified as stage III and 39 (46.4%) as stage IV according to the ASRM system. Table 2 shows the size of the endometriomas as a function of the patient's ASRM classification.

Mapping of the endometriotic lesions revealed that in zone 1/ the anterior compartment, lesions were located in the vesicouterine fold/uterine serosa in 26 women (30.9%) and on the bladder in 16 cases (19%). Regarding zone 2/the lateral compartment, 38 of the women (45.2%) had endometriomas on the right ovary and 46 (54.8%) on the left ovary; 48 (57.1%) had dense adhesions on the right ovarian fossa and 51 (60.7%) on the left ovarian fossa; 42 women (50%) had lesions on the right uterosacral ligament and 50 (59.5%) on the left uterosacral ligament; 29 women (34.5%) had lesions on the right mesosalpinx and 44 (37%) on the left mesosalpinx; and 4 (4.7%) had lesions on the ureter. In zone 3/the posterior compartment, the posterior cul-de-sac was completely obliterated in 43 patients (51.2%), while 32 women (38%) had bowel lesions and 19 (22.6%) had vaginal lesions. Foci of endometriosis were found on the abdominal wall/zone 4 in 18 women (21.4%), and 9 patients (10.7%) had lesions on the diaphragm/zone 5 (Table 3).

Regarding treatment, for the lesions in zone 1/the anterior compartment, in 26 cases (30.9%), resection was performed of the peritoneum that covers the vesicouterine fold and in 16 cases (19%) partial bladder resection was performed. In zone 2/the lateral compartment, right ureterolysis was performed in 48 cases (57.1%), left ureterolysis in 51 cases (60.7%), bilateral ureterolysis in 35 cases (41.6%), right oophoroplasty in 38 cases (45.2%), left oophoroplasty in 46 cases (54.8%), resection of the right uterosacral ligament in 42 cases (50%), resection of the left uterosacral ligament in 50 cases (59.5%), and re-implantation of the ureter in 2 cases (2.4%). For the lesions in zone 3/the posterior compartment, 43 resections of the retrocervical region were performed (51.2%), as well as 32 dissections of the pararectal fossa (38%), 18 rectal shavings (21.4%), 14 segmental rectal resections (16.6%), and 19 resections of the posterior vaginal

**Table 2****Distribution of the patients and the size of endometriomas according to the ASRM classification.**

ASRM classification	n	%	Size of the endometrioma (cm)
III	45	53.6	3.1–12.4
IV	39	46.4	3.2–9.6
Total	84	100.0	–

ASRM=American Society for Reproductive Medicine.

**Table 3**  
Mapping of endometriosis lesions in 84 patients with unilateral endometriomas.

Zone	Site	n (%)
1	Vesicouterine peritoneal reflection/anterior uterine serosa	26 (30.9%)
	Round ligament	0 (0%)
	Bladder	16 (19%)
2	Right ovary	38 (45.2%)
	Left ovary	46 (54.8%)
	Right ovarian fossa	48 (57.1%)
	Left ovarian fossa	51 (60.7%)
	Bilateral adhesions in the ovarian fossae	35 (41.6%)
	Right mesosalpinx	29 (34.5%)
	Left mesosalpinx	44 (37%)
	Right uterosacral ligament	42 (50%)
	Left uterosacral ligament	50 (59.5%)
	Ureter	4 (4.7%)
3	Pouch of Douglas/posterior uterine serosa	43 (51.2%)
	Bowel	32 (38%)
	Vagina	19 (22.6%)
4	Abdominal wall	18 (21.8%)
	Diaphragm	9 (10.7%)

fornix (22.6%). Resections of the peritoneum of the abdominal wall/zone 4 were performed in 18 patients (21.4%) and foci of endometriosis in the diaphragm/zone 5 were resected in 9 patients (10.7%) (Table 4).

#### 4. Discussion

There was a clear disparity in the distribution of the sites of endometriosis lesions in this sample of 84 patients submitted to laparoscopic surgery, reaffirming that DIE is a multifocal pathology.<sup>[22,23]</sup> This characteristic is relevant, since the effectiveness of the surgical treatment for DIE depends on the extent to which exeresis is required.<sup>[24]</sup>

The presence of endometriomas is strongly associated with a diagnosis of deep endometriotic lesions.<sup>[5,15,17]</sup> The mean number of DIE lesions has been found to be significantly higher in patients with a concomitant ovarian endometrioma compared

**Table 4**  
Treatment according to zone and site of deep endometrial lesions.

Zone	Procedure performed	n (%)	
1	Peritoneal resection of the vesicouterine fold	26 (30.9%)	
	Partial bladder resection	16 (19%)	
	Right ureterolysis	48 (57.1%)	
2	Left ureterolysis	51 (60.7%)	
	Bilateral ureterolysis	35 (41.6%)	
	Right oophoroplasty	38 (45.2%)	
	Left oophoroplasty	46 (54.8%)	
	Resection of the right uterosacral ligament	42 (50%)	
	Resection of the left uterosacral ligament	50 (59.5%)	
	Re-implantation of the ureter	2 (2.4%)	
	3	Resection of the retrocervical region	43 (51.2%)
		Dissection of the pararectal fossa	32 (38%)
		Rectal shaving	18 (21.4%)
Segmental bowel resection		14 (16.6%)	
Excision of the posterior vaginal fornix		19 (22.6%)	
4	Resection of the peritoneum of the abdominal wall	18 (21.4%)	
	5	Resection of foci in the diaphragm	9 (10.7%)

to those with no endometrioma ( $2.51 \pm 1.72$  vs  $1.64 \pm 1.0$ ).<sup>[17]</sup> Additionally, in those patients with an associated ovarian endometrioma, DIE lesions were more severe and the frequency of lesions in the bowel, vagina, and ureter was higher.<sup>[17,25]</sup>

In the present study, slightly more endometriomas (54.8% of the cases) were on the left side. In agreement with previous studies, dense adhesions tended to present bilaterally.<sup>[26–29]</sup> The tendency of endometriomas to develop on the left side could be explained by anatomical differences between the right and left hemipelvis. The presence of the sigmoid colon on the left side may decrease elimination of exfoliated endometrial fragments transiting through the Fallopian tubes during menstruation. Eradication of transplanted endometrial cells over menstrual cycles may be less effective in the left hemipelvis.<sup>[26]</sup> Other investigators have described a weaker and slower flow of peritoneal fluid in the left compared to the right hemipelvis.<sup>[30]</sup> Chapron et al<sup>[31]</sup> suggested that the pre-disposition of endometriosis for the left side is the result of the greater exposure of the right hemipelvis to progesterone due to the fact that progesterone levels are higher in the right ovary as a result of more frequent ovulation.

Currently, the most common method used for endometriosis staging is the ASRM classification system.<sup>[21]</sup> Despite being more comprehensive and detailed, this system fails to take lesions of the diaphragm and the abdominal wall into consideration and is to a certain extent impractical since it involves different scores for different aspects, which makes accurate daily recording difficult.

In our opinion, pinpointing the precise location of lesions is extremely difficult, since it is impossible to analyze each lesion individually due to the intensity of adhesions that distort and fuse the anatomy of structures. Consequently, we decided to analyze zones of adhesions rather than anatomical sites.

With respect to the anterior compartment (zone 1), 30.9% of the patients had lesions in the vesicouterine fold and 19% in the bladder. According to the results of previous studies, the bladder serosa is affected in 42.5% of cases, with involvement of the muscle itself in 4.26% of cases.<sup>[32]</sup> In the present study and in agreement with previous studies, both superficial and deep foci were found in zone 1. When dissecting in zone 1, the surgeon must be capable of removing superficial foci, performing adhesiolysis and resecting areas of the bladder, finally suturing the opening in 2 planes.

In zone 2, the lateral foci of endometriosis were present in the ovaries, in the peritoneum of the ovarian fossae, mesosalpinx, ureter, and uterosacral ligaments, including the parametrial area. This zone was the most likely site of endometriosis in all 84 patients. When there are adhesions in the contralateral ovarian fossa, the ovary is often affected by adhesions even when no endometrioma is present in that ovary. When dissecting in zone 2, the ability to perform ureterolysis is crucial, irrespective of whether or not the ureter is affected. Generally, with the presence of endometriomas, dense adhesions are present between the ovary and the homolateral ovarian fossae where the ureter lies below the peritoneum covering the fossae. Furthermore, the hypogastric nerve and the splanchnic nerve plexus are located just below the uterosacral ligament, as shown in previous studies.<sup>[33,34]</sup> The anatomy of the parametrium is critical in endometriosis, as reported by Mabrouk et al,<sup>[35]</sup> who evaluated a sample of 1360 patients and found endometriosis affecting this region in 17% of cases. When the parametrium is affected, surgery is more complex and there is a greater likelihood of functional postsurgical complications.<sup>[35,36]</sup> An important study

that described the possibility of assessing ureteral involvement prior to surgery by using ultrasound to detect whether the uterosacral ligament is affected may be useful when planning the surgical approach to be used in cases in which zone 2 is affected.<sup>[36]</sup>

With respect to the posterior compartment (zone 3), there was complete obliteration of the posterior Douglas pouch in 51.2% of the patients in this study and that finding is in agreement with the results of other previous studies.<sup>[17,19,32,37]</sup> The high prevalence of endometriotic lesions in the posterior pelvic compartment highlights the asymmetric distribution and supports the menstrual reflux theory of implantation following retrograde menstruation, with peritoneal flow patterns playing a key role in determining the anatomical spread of lesions.<sup>[38]</sup> Furthermore, the higher prevalence of enteric sites on the anti-mesenteric surface of the rectum could be explained by the fact that this organ represents an obstacle to intraperitoneal flow.<sup>[32]</sup> There were no cases of endometriosis affecting the appendix in the present sample; however, Mabrouk et al<sup>[39]</sup> performed a retrospective analysis of 1935 cases and found the appendix to be affected in 2.6% of cases, where it was associated with adenomyosis, a large endometrioma on the right side, bladder endometriosis, deep posterior pelvic endometriosis, left deep lateral pelvic endometriosis, and ileocecal involvement.

When dissecting in zone 3, the surgeon must be capable of performing lysis of dense adhesions in the posterior compartment, gaining access to the rectal fossa, including possible bowel resection. Resection can be performed using linear resection (or shaving), nodulectomy or segmental resection. The best approach regarding bowel surgery remains an issue for debate; however, data suggest that the most conservative approach is the most appropriate, since the risk of recurrence of the segmental resections would be the same, while complications such as changes to bowel and urinary habits could be avoided.<sup>[40]</sup>

The prevalence of diaphragmatic endometriosis was relatively low (10.5%) in the patients in the present study. The presence of endometriotic implants on the diaphragm may constitute a grave complication due to the elusive and often severe pain in addition to the risk of the disease spreading to the liver and pleura, consequently increasing the probability of major morbidity.<sup>[41]</sup>

There has been much debate on the subject of DIE with concomitant bilateral endometriomas<sup>[17,19,26]</sup>; however, up to the present time, only 1 study has dealt with the association between unilateral endometriomas and concomitant lesions of DIE. In the present study, there were significantly more DIE lesions in patients with a unilateral endometrioma compared to those reported for patients with bilateral ovarian endometriomas ( $2.76 \pm 1.52$  vs  $2.33 \pm 1.34$ ;  $P = .006$ ).<sup>[19]</sup> These results will add to currently existing data on the severity of unilateral endometriomas.

Ulukus et al<sup>[42]</sup> reported a greater prevalence of obliteration of the pouch of Douglas in patients with an endometrioma on the right side; however, this finding was not confirmed in the present study, perhaps because of the small sample size.

The importance of the anatomical distribution of lesions when making decisions regarding surgical management prompted us to propose a classification system for DIE lesions. Other classification systems, based essentially on the pathogenesis of DIE, have already been proposed.<sup>[14,29]</sup> The advantage of classifying lesion sites into zones, as proposed here, is that this system reflects what the surgeon is actually seeing in terms of the location of the adhesions. The surgeon will then be able to determine the optimal

strategy of access in accordance with the site of the lesions. In our opinion, classifying endometriosis into zones helps provide the surgeon with information regarding the complexity of the surgery. Chapron et al<sup>[17]</sup> and Abbott et al<sup>[43]</sup> reached similar conclusions. The more adhesions that are present, the more complex surgery will be. There are no diagnostic tests capable of accurately detecting adhesions resulting from endometriosis and missing a suspected adhesion may result in an underestimation of the complexity of surgery.<sup>[34]</sup> Transvaginal ultrasonography with prior bowel preparation is often helpful, since this is a dynamic examination that associates touch with the mobility of structures and is therefore able to diagnose sites of adhesion.

Our proposal is that a supplementary pre-operative diagnosis should be made in all cases of endometriomas through the use of magnetic resonance imaging or ultrasonography with prior bowel preparation; whichever is more readily accessible at each institute. The goal of this strategy is to avoid underestimating the extent of DIE lesions prior to surgery. Miscalculating the severity of DIE lesions is one of the reasons for incomplete surgical treatment. Ideally, the patient should be informed regarding how extensive surgery could be and conditions should be adequate for cases in which radical surgery proves necessary. The incomplete exeresis of DIE lesions may explain the high risk of recurrence, which is in fact the continued progression of lesions left behind during previous surgeries.<sup>[17,44,45]</sup>

Another extremely important factor to be taken into consideration is the lengthy surgical training involved. The skill required to enable a surgeon to dissect critical zones in retroperitoneal regions is acquired over time. Although there is a basic standardization that must be strictly adhered to when accessing the retroperitoneal spaces during surgery, the steps involved will vary to meet the requirements of each individual case. Since the surgical steps involved differ from case to case, step-by-step standardization is impossible, while the anatomical marks that serve to guide the surgeon's access to specific areas will be learned over time. Although bowel surgery involves the participation of a general surgeon, the experience of a gynecological surgeon is of the utmost importance in leading the team.

Together with an indispensable and accurate knowledge of anatomy, training should equip the surgeon with the ability to deal with endometriosis lesions at different sites. In this institute, surgery for endometriomas is always performed with a multidisciplinary team in the operating room or a trained surgeon capable of performing extensive dissections, including those in the diaphragm. As the treatment of endometriomas remains an enigma to be resolved, with no consensus having been reached up to the present moment, each case must be individualized as a function of the size of the cyst, the patient's complaints, and her age and fertility status.

The principal limitation of the present study probably lies in its small sample size. We emphasize the need for further prospective studies with larger sample sizes aimed at identifying factors associated with the site of foci of endometriosis.

Based on the present findings, it is quite clear that surgery for unilateral endometriomas cannot be performed as if it were for an isolated ovarian cyst. The proposal put forward here to classify lesions into zones will provide the surgeon with information on the main compartments affected in patients with unilateral endometriomas. This information highlights the importance of conducting a comprehensive pre-operative investigation that includes the use of pelvic magnetic resonance imaging and

transvaginal ultrasound with prior bowel preparation, as well as other forms of evaluation. The importance of a multidisciplinary team when performing surgery to treat endometriomas should not be underestimated.

### Author contributions

**Conceptualization:** Raquel Silveira da Cunha Araujo, Paulo Augusto Ayroza Ribeiro.

**Data curation:** Raquel Silveira da Cunha Araujo.

**Formal analysis:** Raquel Silveira da Cunha Araujo, Sabina Bastos Maia.

**Investigation:** Raquel Silveira da Cunha Araujo, Juliane Dornelas Lúcio, Moisés Diogo de Lima.

**Methodology:** Raquel Silveira da Cunha Araujo, Paulo Augusto Ayroza Ribeiro.

**Project administration:** Raquel Silveira da Cunha Araujo.

**Supervision:** Helizabet Salomão Abdalla Ayroza Ribeiro, Paulo Augusto Ayroza Ribeiro.

**Validation:** Raquel Silveira da Cunha Araujo, Paulo Augusto Ayroza Ribeiro.

**Visualization:** Raquel Silveira da Cunha Araujo, Helizabet Salomão Abdalla Ayroza Ribeiro, Paulo Augusto Ayroza Ribeiro.

**Writing – original draft:** Raquel Silveira da Cunha Araujo, Sabina Bastos Maia.

**Writing – review & editing:** Raquel Silveira da Cunha Araujo, Sabina Bastos Maia, Juliane Dornelas Lúcio, Moisés Diogo de Lima, Helizabet Salomão Abdalla Ayroza Ribeiro, Paulo Augusto Ayroza Ribeiro.

Raquel Silveira da Cunha Araujo: 0000-0002-9537-9943

### References

- Mehdizadeh Kashi A, Chaichian S, Ariana S, et al. The impact of laparoscopic cystectomy on ovarian reserve in patients with unilateral and bilateral endometrioma. *Int J Gynaecol Obstet* 2017;136:200–4.
- Benaglia L, Somigliana E, Vercellini P, Abbiati A, Ragni G, Fedele L. Endometriotic ovarian cysts negatively affect the rate of spontaneous ovulation. *Hum Reprod* 2009;24:2183–6.
- Muzii L, Panici PB. Reply: Endometrioma excision and ovarian reserve: do assessments by antral follicle count and anti-Müllerian hormone yield contradictory results? *Hum Reprod* 2014;29:2854–5.
- Jenkins S, Olive DL, Haney AF. Endometriosis: pathogenetic implications of the anatomic distribution. *Obstet Gynecol* 1986;67:335–8.
- Redwine DB. Ovarian endometriosis: a marker for more extensive pelvic and intestinal disease. *Fertil Steril* 1999;72:310–5.
- Chapron C, Vercellini P, Barakat H, Vieira M, Dubuisson JB. Management of ovarian endometriomas. *Hum Reprod Update* 2002;8:591–7.
- Hart R, Hickey M, Maouris P, Buckett W, Garry R. Excisional surgery versus ablative surgery for ovarian endometriomata: a Cochrane Review. *Hum Reprod* 2005;20:3000–7.
- Somigliana E, Berlanda N, Benaglia L, Viganò P, Vercellini P, Fedele L. Surgical excision of endometriomas and ovarian reserve: a systematic review on serum antimüllerian hormone level modifications. *Fertil Steril* 2012;98:1531–8.
- Celik HG, Dogan E, Okyay E, et al. Effect of laparoscopic excision of endometriomas on ovarian reserve: serial changes in the serum antimüllerian hormone levels. *Fertil Steril* 2012;97:1472–8.
- Ferrero S, Venturini PL, Gillott DJ, Remorgida V, Maggiore UL. Hemostasis by bipolar coagulation versus suture after surgical stripping of bilateral ovarian endometriomas: a randomized controlled trial. *J Minim Invasive Gynecol* 2012;19:722–30.
- Barakat CMF, Abdalla-Ribeiro HSA, Araujo R, Bernardo WM, Ribeiro PA. The impact on ovarian reserve of different hemostasis methods in laparoscopic cystectomy: a systematic review and meta-analysis. *Rev Bras Ginecol Obstet* 2019;41:400–8.
- Seyhan A, Ata B, Uncu G. The impact of endometriosis and its treatment on ovarian reserve. *Semin Reprod Med* 2015;33:422–8.
- Goodman LR, Goldberg JM, Flyckert RL, Gupta M, Harwalker J, Falcone T. Effect of surgery on ovarian reserve in women with endometriomas, endometriosis and controls. *Am J Obstet Gynecol* 2016;215:589.e1–6.
- Koninckx PR, Meuleman C, Demeyere S, Lesaffre E, Cornillie FJ. Suggestive evidence that pelvic endometriosis is a progressive disease, whereas deeply infiltrating endometriosis is associated with pelvic pain. *Fertil Steril* 1991;55:759–65.
- Chapron C, Fauconnier A, Vieira M, et al. Anatomical distribution of deeply infiltrating endometriosis: surgical implications and proposition for a classification. *Hum Reprod* 2003;18:157–61.
- Ye M, Guo H, Han J, et al. Relationship between endometriosis stage, characteristics of endometriotic lesions and severity of dysmenorrhoea. *Zhonghua Yi Xue Za Zhi* 2015;95:685–8.
- Chapron C, Pietin-Vialle C, Borghese B, Davy C, Foulot H, Chopin N. Associated ovarian endometrioma is a marker for greater severity of deeply infiltrating endometriosis. *Fertil Steril* 2009;92:453–7.
- Somigliana E, Infantino M, Candiani M, et al. Association rate between deep peritoneal endometriosis and other forms of the disease: pathogenetic implications. *Hum Reprod* 2004;19:168–71.
- Kwok H, Jiang H, Li T, et al. Lesion distribution characteristics of deep infiltrating endometriosis with ovarian endometrioma: an observational clinical study. *BMC Womens Health* 2020;20:111.
- Araujo RS, Maia SB, Barakat CM, et al. Ovarian function after the use of various hemostatic techniques during treatment for endometrioma: protocol for a randomized clinical trial. *Trials* 2019;20:410.
- Revised American Society for Reproductive Medicine classification of endometriosis: 1996. *Fertil Steril* 1997;67:817–21.
- Chapron C, Chopin N, Borghese B, et al. Deeply infiltrating endometriosis: pathogenetic implications of the anatomical distribution. *Hum Reprod* 2006;21:1839–45.
- Redwine DB, Wright JT. Laparoscopic treatment of complete obliteration of the cul-de-sac associated with endometriosis: long-term follow-up of en bloc resection. *Fertil Steril* 2001;76:358–65.
- Garry R, Clayton R, Hawe J. The effect of endometriosis and its radical laparoscopic excision on quality of life indicators. *BJOG* 2000;107:44–54.
- Leng JH, Lang JH, Zhao XY, Li HJ, Guo LN, Cui QC. Visual and histologic analysis of laparoscopic diagnosis of endometriosis. *Zhonghua Fu Chan Ke Za Zhi* 2006;41:111–3.
- Sznurkowski JJ, Emerich J. Endometriomas are more frequent on the left side. *Acta Obstet Gynecol Scand* 2008;87:104–6.
- Al-Fozan H, Tulandi T. Left lateral predisposition of endometriosis and endometrioma. *Obstet Gynecol* 2003;101:164–6.
- Vercellini P, Aimi G, De Giorgi O, Maddalena S, Carinelli S, Crosignani PG. Is cystic ovarian endometriosis an asymmetric disease? *Br J Obstet Gynaecol* 1998;105:1018–21.
- Audebert A, Petousis S, Margioulas-Siarkou C, Ravanos K, Prapas N, Prapas Y. Anatomic distribution of endometriosis: a reappraisal based on series of 1101 patients. *Eur J Obstet Gynecol Reprod Biol* 2018;230:36–40.
- Meyers MA. Distribution of intra-abdominal malignant seeding: dependency on dynamics of flow of ascitic fluid. *Am J Roentgenol Radium Ther Nucl Med* 1973;119:198–206.
- Chapron C, Fauconnier A, Dubuisson JB, Vieira M, Bonte H, Vacher-Lavenu MC. Does deep endometriosis infiltrating the uterosacral ligaments present an asymmetric lateral distribution? *BJOG* 2001;108:1021–4.
- Scioscia M, Bruni F, Ceccaroni M, Steinkasserer M, Stepniewska A, Minelli L. Distribution of endometriotic lesions in endometriosis stage IV supports the menstrual reflux theory and requires specific preoperative assessment and therapy. *Acta Obstet Gynecol Scand* 2011;90:136–9.
- Seracchioli R, Mabrouk M, Mastronardi M, et al. Anatomic cartography of the hypogastric nerves and surgical insights for autonomic preservation during radical pelvic procedures. *J Minim Invasive Gynecol* 2019;26:1340–5.
- Kondo W, Ribeiro R, Trippia C, Zomer MT. Deep infiltrating endometriosis: anatomical distribution and surgical treatment. *Rev Bras Ginecol Obstet* 2012;34:278–84.
- Mabrouk M, Raimondo D, Arena A, et al. Parametrial endometriosis: the occult condition that makes the hard harder. *J Minim Invasive Gynecol* 2019;26:871–6.
- Lima R, Abdalla-Ribeiro H, Nicola AL, Eras A, Lobao A, Ribeiro PA. Endometriosis on the uterosacral ligament: a marker of ureteral involvement. *Fertil Steril* 2017;107:1348–54.

- [37] Kondo W, Ribeiro R, Trippia CH, Zomer MT. Association between ovarian endometrioma and deep infiltrating endometriosis. *Rev Bras Ginecol Obstet* 2012;34:420–4.
- [38] Viganò P, Parazzini F, Somigliana E, Vercellini P. Endometriosis: epidemiology and aetiological factors. *Best Pract Res Clin Obstet Gynaecol* 2004;18:177–200.
- [39] Mabrouk M, Raimondo D, Mastronardi M, et al. Endometriosis of the appendix: when to predict and how to manage - a multivariate analysis of 1935 endometriosis cases. *J Minim Invasive Gynecol* 2020;27:100–6.
- [40] Mabrouk M, Raimondo D, Altieri M, et al. Surgical, clinical, and functional outcomes in patients with rectosigmoid endometriosis in the gray zone: 13-year long-term follow-up. *J Minim Invasive Gynecol* 2019;26:1110–6.
- [41] Vercellini P, Abbiati A, Viganò P, et al. Asymmetry in distribution of diaphragmatic endometriotic lesions: evidence in favour of the menstrual reflux theory. *Hum Reprod* 2007;22:2359–67.
- [42] Ulukus M, Yenieli AÖ, Ergenoglu AM, Mermer T. Right endometrioma is related with more extensive obliteration of the Douglas pouch. *Arch Gynecol Obstet* 2012;285:1483–6.
- [43] Abbott JA, Hawe J, Clayton RD, Garry R. The effects and effectiveness of laparoscopic excision of endometriosis: a prospective study with 2-5 year follow-up. *Hum Reprod* 2003;18:1922–7.
- [44] Fedele L, Bianchi S, Zanconato G, Berlanda N, Borruto F, Frontino G. Tailoring radicality in demolitive surgery for deeply infiltrating endometriosis. *Am J Obstet Gynecol* 2005;193:114–7.
- [45] Vignali M, Bianchi S, Candiani M, Spadaccini G, Oggioni G, Busacca M. Surgical treatment of deep endometriosis and risk of recurrence. *J Minim Invasive Gynecol* 2005;12:508–13.