

# The reverse sural fasciocutaneous flap for the treatment of traumatic, infectious or diabetic foot and ankle wounds: a retrospective review of 16 patients

Ioannis A. Ignatiadis, MD, PhD<sup>1,\*</sup>, Vassiliki A. Tsiampa, MD<sup>1</sup>, Spyridon P. Galanakos, MD<sup>1</sup>, Georgios D. Georgakopoulos, MD<sup>1</sup>, Nicolaos E. Gerostathopoulos, MD, PhD<sup>1</sup>, Mihai Ionac, MD, PhD<sup>3</sup>, Lucian P. Jiga, MD, PhD<sup>3</sup> and Vasilios D. Polyzois, MD, PhD<sup>2</sup>

<sup>1</sup>Hand Surgery-Upper Limb and Microsurgery Department, KAT General Hospital, Athens, Greece; <sup>2</sup>4th Orthopedic Department, KAT General Hospital, Athens, Greece; <sup>3</sup>Vascular Surgery Department, Timisoara University Hospital, Timisoara, Romania

The authors present their experience with the use of sural fasciocutaneous flaps for the treatment of various soft tissue defects in the lower limb. This paper is a review of these flaps carried out between 2003 and 2008. The series consists of 16 patients, 12 men and 4 women with an average age of 40 years (17–81) and with a follow-up period between 1 and 8 years. The etiology was major velocity accident in six cases, diabetes mellitus with osteomyelitis after ORIF for fractures (3), work accident in five, and another two cases with complications of lower limb injuries. The defect areas were located on calcaneus, malleolar area, tarsal area and lower tibia. Associated risk factors in the patients for the flap performance were diabetes (five patients) and cigarette smoking (eleven patients).

The technique is based on the use of a reverse-flow island sural flap combined with other flaps in three cases (medial plantar, peroneal, gastrocnemius). The anatomical structures which constituted the pedicle were the superficial and deep fascia, the sural nerve, the lesser saphenous vein and skin.

The flap was viable in all 16 patients. Five cases had a superficial necrosis that were skin grafted, 2 cases experienced a partial skin necrosis which were treated with a secondary flap (posterior tibial perforator and medial plantar artery) and another case demonstrated a delayed skin healing.

The sural fasciocutaneous flap is useful for the treatment of severe and complex injuries and their complications in diabetic and non diabetic lower limbs. Its technical advantages are easy dissection, preservation of more important vascular structures in the limb and complete coverage of the soft tissue defects in just one operation without the need of microsurgical anastomosis. Thus this flap offers excellent donor sites for repairing soft tissue defects in foot and ankle.

Keywords: *foot-ankle; necrosis; defects; sural flap; diabetic foot necrosis; neuropathy, wounds*

Received: 20 September 2010; Revised: 1 November 2010; Accepted: 16 November 2010; Published: 12 January 2011

## Introduction (1, 2)

The management of soft-tissue defects in the lower limbs due to an increase of high energy trauma currently has become a very frequent procedure. The reconstructive surgeon should be capable of carrying out an integral treatment of these wounds, including not only open reduction and internal or external fixation of the fracture fragments, but also the management of possible complications such as local skin necrosis. In

1992, Masquelet et al. described the use of the neurocutaneous flap for reconstruction of soft-tissue defects of the distal third of the leg (1). Among the main indications for a sural fasciocutaneous flap are soft-tissue defects of the heel and the lateral or medial perimalleolar regions (2). This flap can also be combined with other flaps in cases with some special soft-tissue defects (e.g. cases with simultaneous osteomyelitis, bone defect, and avascular necrosis).

## Materials and methods

This study is a retrospective review of the sural fasciocutaneous and neurocutaneous flaps carried out in 16 patients (Table 1): 12 men and 4 women with an average age of 40 years (ages 17–81) and a postoperative follow-up between 1 and 8 years. The soft-tissue defect in the lower limb in this study was located on the heel and calcaneal area in five cases, on the malleolar and paramalleolar area (Fig. 1a, b) in three cases, on the distal tibia in another three cases, dorsal tarsal area in four cases, and medial plantar area in one case. Five patients were diabetic and suffered from osteomyelitis (four pressure sores and one post-traumatic osteomyelitis). Eleven patients were smokers and only five were non-smokers.

In two cases where the fracture was treated with external fixation, the sural flap was performed to treat:

1. The soft-tissue defect in combination with the external fixation.
2. The post-traumatic infection due to pin track infection.

In another case, the flap was performed in order to treat the remaining soft-tissue defect due to residual osteomyelitis from post-traumatic infection of a distal tibial fracture, which was treated with surgical debridement and distraction osteogenesis with the Ilizarov technique. In the cases where the sural flap was used to cover defects due to osteomyelitis infection, the patients were diabetic except one case where the infection was a complication from an ankle arthroplasty.

One sural flap in a case with large local hematoma was preceded by a cross-leg emergency flap. The majority of flaps were fasciocutaneous except two (patients with calcaneal osteomyelitis) that were neurofasciocutaneous. During surgery all patients were positioned prone and were anaesthetized with spinal anesthesia. A tourniquet was placed in the proximal lower limb.

For the three diabetic patients with calcaneal osteomyelitis, the osteomyelitis was diagnosed with clinical and radiographic examinations and typical Radiographies. Intraoperative cultures and/or histological examinations confirmed the diagnosis for each of them. The dorsalis pedis and posterior tibial artery pulses were palpable in all patients. Broad spectrum antimicrobial therapy was administered to all patients. Postoperative antimicrobial treatments were adjusted according to the results of culture antibiograms for the microorganisms isolated from the deep-tissue specimens. The average therapy consisted of 3 to 4 weeks of intravenous treatment followed by 2–3 weeks of oral treatment in moderate infections and longer protocols of treatment in case of osteomyelitis. The duration of antibiotic therapy was determined on the basis of culture results and clinical assessments of the wound and

soft tissues. The patients' follow-up was between 1 and 8 years.

## Surgical technique

The sural fasciocutaneous flap is made up of skin and subcutaneous fat, the superficial and deep fascia of the posterior part of the leg, sural nerve, the sural vein, and the superficial sural artery. The flap is based initially on the vascularization that runs with the sural nerve. Flap vascularization is accomplished by distal reverse flow of the superficial sural artery dependent on perforators of the peroneal arterial system. There are numerous anastomosis between the peroneal artery and the vascular axis of the flap. The most distal is usually found at a distance of 4–5 cm above the tip of lateral malleolus; thus, it consists of the pivot point of the flap. Flap harvesting techniques have been well described in the literature (3–6).

The flap was outlined according the size of the defect on a zigzag line drawn from the popliteal fossa to the Achilles tendon along the posterior middle one-third of the leg. The pedicle consisted of subcutaneous tissue, deep fascia, the small saphenous vein, the sural nerve (in 2 cases), and accompanying arteries. The small saphenous vein and the sural nerve were ligated (proximally and distally) at the proximal border of the flap and then the lateral and medial border of the flap and pedicle were incised down to the muscle. Then the flap was rotated over its pedicle up to 180° (Fig. 2a, b) and adapted to the defect (Fig. 3a, b).

In two cases the pedicle of the flap included the distal peroneal perforator of the peroneal artery. Skin closure was achieved with sutures on the reapproximated tips of each triangle of the z incision, and free skin grafts covered the created defects. At the end of the procedure the tourniquet was deflated and adequate circulation of the flap verified. Numerous punctures of the flap using a 25 G needle were made to allow bleeding thus minimizing hyperemia and venous congestion. The limb was dressed with cotton and elastic bandages.

## Results

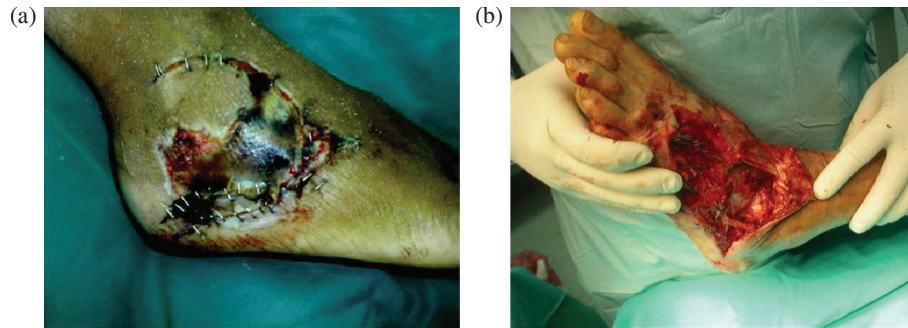
Demographic information, complications, and results are presented in Table 1. All flaps survived completely (Fig. 4a, b). In one case a slight venous congestion was managed with the vasodilating agent Buflomedil Hydrochloride (600 mg × 1/24 h) and oral micronized purified flavonoid fraction (MPFF) (Daflon) – a vasoprotector and venotonic agent. In four cases, a small superficial necrosis was observed that was managed with minor revision and the use of split thickness skin graft. In another two complex cases, the sural flap was combined with the posterior tibial artery perforator flap for complete defect closure and with a medial plantar neurovascular flap in order to provide sensation and ankle arthrodesis (case with calcaneal bone defect and Achilles tendon rupture).

Table 1. Patients treated with the reverse flow sural flap

Case	Age, gender and history of smoking	Type and location of defect	Type of flap and dimensions	Fractures and/or infection	Mechanism of Injury	Timing of defect prior to sural flap surgery	Complications and treatment	Last follow-up
1	49, Male Smoking History	Calcaneus	Sural flap 5 × 8 cm	Calcaneal osteomyelitis	Diabetic neuropathy and Infection	12 months	None	8 years
2	26, Female Smoking History	Malleolus	Sural flap 5 × 7 cm	Soft tissue necrosis	Motor Vehicle Accident (MVA)	2 weeks	None	7 years
3	56, Male Smoking History	Lower Distal Tibia	Sural flap 4.5 × 8 cm	Lower distal tibia posttraumatic osteomyelitis	MVA and History Of Diabetes mellitus	2 months	Delayed Skin healing (4 weeks)	1 year
4	26, Male	Tarsal dorsal area	Sural flap 6 × 9 cm	Second and third metatarsal fractures	Work related injury	1 month	Superficial necrosis treated with split thickness skin graft (STSG) 10 days postoperatively	4 years
5	31, Male Smoking History	Dorsum of the ankle	Sural flap 6.5 × 10 cm	Ankle Fracture treated with arthrodesis and postsurgical osteomyelitis	Work related injury	12 months	Superficial necrosis treated with STSG 5 days postoperatively	3 years
6	51, Female Smoking History	Diabetic decubitus calcaneus	Sural flap 6.5 × 16 cm	Calcaneal osteomuelitis	Diabetic neuropathy and Infection	2 months	Superficial necrosis treated with STSG 2 weeks postoperatively	4.5 years
7	17, Male	Medial plantar and tarsal area	Cross leg 7 × 11 cm followed by Sural flap 6 × 10 cm	Calcaneal avulsion fracture	Work related injury	3.5 weeks for the cross-leg flap followed by a sural flap 4 weeks later	None	4 years
8	35, Male	Lower tibia anteromedial aspect	Gastrocnemius 4 × 15 cm followed by Sural flap 4 × 6 cm	Open tibia comminuted fracture	MVA	3 weeks	None	3 years
9	33, Male	Calcaneus and Achilles area	Combined Sural & Peroneal perforator flaps 7 × 10 cm	Failed open reduction internal fixation of a calcaneal fracture	Work related injury	1 month	Partial necrosis treated with a tibial posterior artery perforator flap 10 days postoperatively	3.5 years

Table 1 (Continued)

Case	Age, gender and history of smoking	Type and location of defect	Type of flap and dimensions	Fractures and/or infection	Mechanism of Injury	Timing of defect prior to sural flap surgery	Complications and treatment	Last follow-up
10	29, Female Smoking History	Dorsum of the ankle	Combined-Sural & Peroneal perforator flaps 7 × 9 cm	Subluxation of Midfoot and Rearfoot joints and extensor tendon lacerations	MVA	Upon initial presentation	Superficial necrosis treated with STSG 1 week postoperatively	3 years
11	81, Male	Diabetic decubitus calcaneus	Sural flap 6 × 8 cm	Calcaneal osteomyelitis	Diabetic neuropathy and Infection	3 months	None	3 years
12	40, Male Smoking History	External paramalleolar areas	Sural flap 5 × 7 cm	Tibiocalcaneal arthrodesis with severe soft tissue necrosis	MVA and History Of Diabetes mellitus	1 month	None	4 years
13	42, Male Smoking History	Open Tibia Fracture Midshaft	Sural flap 5 × 7.5 cm	Posteromedial tibial area	MVA	1 month	Superficial necrosis treated with STSG 2 weeks postoperatively	1.5 years
14	35, Male Smoking History	Malleolar soft tissue necrosis	Sural flap 4.5 × 7 cm	Previously treated tibial fracture and postoperative osteomyelitis	Postraumatic	2 months	None	2 years
15	65, Female Smoking History	Dorsal Tarsal aspect	Sural flap 5 × 6 cm	Previous total ankle arthroplasty	Postraumatic	2 months	None	4 years
16	24, Male Smoking History	Calcaneus and Achilles area	Sural flap 6 × 10 cm	Severe calcaneal and Achilles tendon defects from injury	Work related injury	2 months	Secondary medial plantar flap 3 × 5 cm 5 weeks after the initial surgery followed by a 3 <sup>rd</sup> operation of a tibiocalcaneal arthrodesis 3 months later	1 year



*Fig. 1.* (a) Case 1 (female) and (b) case 2 (male) young patients with external malleolar and lateral tarsal area necrosis.

The average surgery time was 60–100 min (including flap dissection) and the average size of the flap  $5.6 \times 8.7$  cm. The flaps provided a successful coverage in all cases. Between 1.5 months and 3 months postoperatively, all patients walked without crutches (Fig. 4a, b) or with the utilization of external fixation devices.

### Discussion

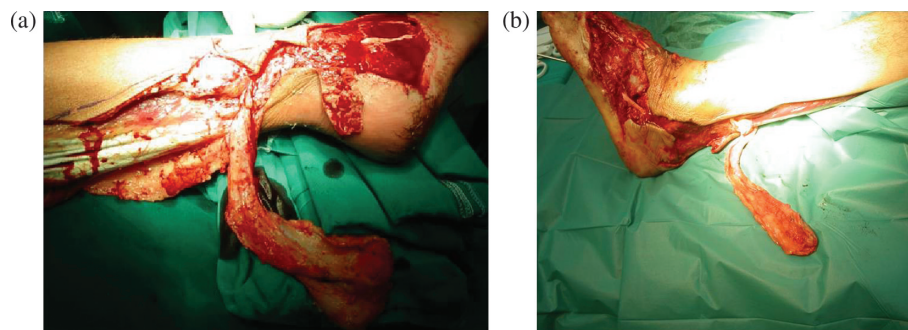
There is a large variety of pedicled or muscular flaps for the reconstruction of post-traumatic soft-tissue defects of the lower limb. These techniques are not all familiar to reconstructive surgeons. The potential for flap failure and donor side morbidity are common risk factors.

The main alternatives to sural flaps are free flaps, lateral supramalleolar skin flaps, and posterior tibial perforator flaps. Free flap reconstruction of defects requires lengthy and costly hospitalization, microsurgery training and experience, special instruments, and a two-team approach. The long operative time and functional donor-site morbidity are the major disadvantages of this method. Free flaps are advised for extensive skin defects (1).

The lateral supramalleolar skin flap offers a range of coverage similar to that of the sural flap, but the dissection is more difficult than for a sural flap and offers no advantages and the remaining non-sensitive area in sural flaps is smaller than the one left after the transection of the superficial peroneal nerve. Theoretically, the sural flap doesn't cover as distal as the supramalleolar

flap, but some authors stated that the distally based sural flap is more reliable than the lateral supramalleolar flap, especially regarding the venous congestion and have shown the usefulness of the sural flap for weight-bearing areas even when resensibilization is not performed. A lateral supramalleolar skin flap is not recommended for coverage in this areas. The global proportion of failures is almost four times as great for the supramalleolar skin flap (7). The posterior tibial perforator flap is another option (8). It is a very reliable flap and indicated in lower limb defects, especially in reconstruction of chronic Achilles tendon defects. A more difficult dissection and a larger learning curve are the main disadvantages. A medial distal septocutaneous flap (9) based on the intramuscular posterior tibial perforators is an alternative.

The advantages of the sural flap compared to the above mentioned flaps are the simplicity of the design and dissection of the pedicle that can be carried out with a loupe magnification and without the need of microsurgical instrumentation or anastomosis, the preservation of the principal vascularization of the lower limb, and the need for only one operation. It can also be combined with various osteosynthesis techniques as external fixation of comminuted fractures and Ilizarov, and also with other fasciocutaneous flaps (tibial, medial plantar), muscle flaps (gastrocnemius), or distant flaps (cross-leg).



*Fig. 2.* (a and b) Cases 1 and 2, sural flap harvesting.



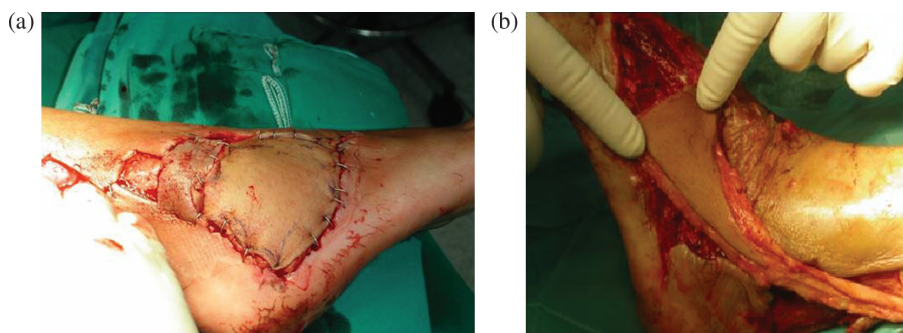


Fig. 3. (a and b) Cases 1 and 2, flap adjustment on the defects areas.

According to the treatment of calcaneal osteomyelitis (except the sural flap), various surgical methods have been used like debridement and coverage with local muscle or free muscle flaps (10–13), partial calcaneal resection (14–17), and total calcanectomy (18). Below-the-knee amputation has been recommended for cases with extensive and/or progressive involvement of the os calcis (19).

Useful local muscle flaps for calcaneal osteomyelitis treatment are the abductor digiti minimi and abductor hallucis muscles. The major disadvantage of these flaps is their small size especially when there is an extensive tissue loss. When local viable tissue is inadequate, free muscle transfers allow coverage. The rectus abdominis and gracilis muscle flaps are usually preferred for the treatment of calcaneal osteomyelitis (20). Coverage with the above mentioned flaps has demonstrated good functional results and adequate weight-bearing surfaces (11–13).

Muscle flaps have good vascularity for the treatment of infection, a positive effect on bone healing, and an obliteration effect because of their bulky tissue. However, free muscle flap reconstruction of calcaneal osteomyelitis associated defects requires lengthy and costly hospitalization, microsurgical training and experience, special instruments, and a two-team approach. The major disadvantages of this method are the long operative time and functional donor-site morbidity.

The fasciocutaneous sural flaps that were successfully used in our series (Table 1) have many advantages for the treatment of calcaneal osteomyelitis including easy dissection, short operative time, wide rotation arc, and acceptable donor-site morbidity. There is no need to sacrifice the major artery of the leg. Unlike free flaps, there is no need for a vascular anastomosis; thus, there is no risk for the blood supply of the foot. They can be elevated in relatively large sizes, so that part of the flap can be deepithelialized and used for obliteration of a bone cavity. Diabetes mellitus alone does not usually compromise the vascularity of these flaps if they present with adequate blood supply. In addition, other reports, on the literature confirm that they can be used safely for soft-tissue reconstruction of diabetic patients (21).

In conclusion, the reverse flow sural flap constitutes a reliable and versatile technique that may be a part of the reconstructive surgeon's armamentarium and thus facilitating the integral treatment of complex lower limb injuries with large defects in diabetic or non-diabetic patients.

### Conflict of interest and funding

The authors have not received any funding or benefits from industry or elsewhere to conduct this study.

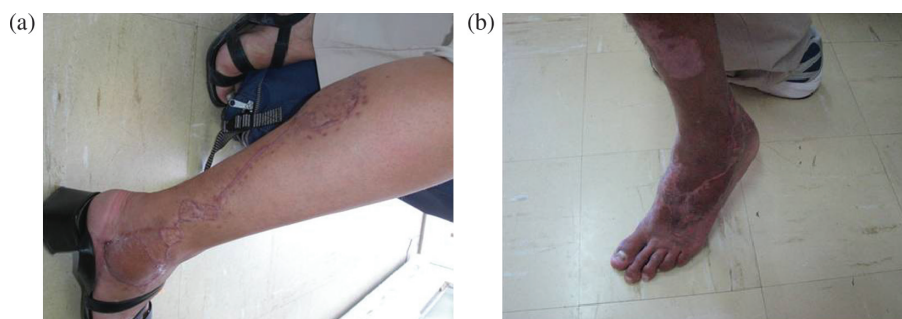


Fig. 4. (a and b) Cases 1 and 2: final results.

## References

---

1. Baumeister SP, Spierer R, Erdman R, Sweis R, Lewin LS, German GK, et al. A realistic complication analysis of 70 sural artery flaps in a multimorbid patients group. *Plast Reconstr Surg* 2003; 112: 129–40.
2. Rios-Luna A, Villanueva-Martinez M, Fahandezh-Saddi H, Villanueva-Lopez F, del Cerro-Gutiérrez M. Versatility of the sural fasciocutaneous flap in coverage defects of the lower limb. *Injury* 2007; 38: 824–31.
3. Hasegawa M, Torii S, Katoh H, Esaki S. The distally based superficial sural artery flap. *Plast Reconstruct Surg* 1994; 93: 1012–20.
4. Conskunfirat OK, Velidedeoglu HV, Sahin U, Demir Z. Reverse neurofasciocutaneous flaps for soft-tissue coverage of the lower leg. *Ann Plast Surg* 1999; 43: 14.
5. Jeng SF, Wei FC, Kuo YR. Salvage of the distal foot using distally based sural island flap. *Ann Plast Surg* 1999; 43: 499.
6. Yilmaz M, Karatas O, Barutçu A. The distally based superficial artery island: clinical experience and modifications. *Plast Reconstr Surg* 1998; 102: 2358.
7. Price MF, Capizzi PJ, Watterson PA, Lettieri S. Reverse sural artery flap: caveats for success. *Ann Plast Surg* 2002; 48: 496–504.
8. Cavadas PC, Landin L. Reconstruction of chronic Achilles tendon defects with posterior tibial perforator flap and soleus tendon graft: clinical series. *Plast Reconstruct Surg* 2006; 117: 266–71.
9. Costa Ferreira A, Reis J, Amarante J. Reconstruction of soft tissue defects of the heel with local fasciocutaneous flaps. *Ann Plast Surg* 2005; 54: 580–1.
10. Fitzgerald RH Jr, Ruttle PE, Arnold PG, Kelly PJ, Irons, GB. Local muscle flaps in the treatment of chronic osteomyelitis. *J Bone Joint Surg (Am)* 1985; 67: 175.
11. Wellisz T, Rechnic M, Douherty W, Sherman R. Coverage of bilateral lower extremity calcaneal fractures with osteomyelitis using a single split free gracilis muscle transfer. *Plast Reconstr Surg* 1990; 85: 457.
12. Anderson RB, Foster MD, Gould JS, Hanel DP. Free tissue transfer and calcanectomy as treatment of chronic osteomyelitis of the os calcis: a case report. *Foot Ankle* 1990; 11: 168–71.
13. Attinger C, Cooper P. Soft tissue reconstruction for calcaneal fractures or osteomyelitis. *Orthop Clin North Am* 2001; 32: 135–70.
14. Woll TS, Beals RK. Partial calcanectomy for the treatment of osteomyelitis of the calcaneus. *Foot Ankle* 1991; 12: 31–3.
15. Perez ML, Wagner SS, Yun J. Subtotal calcanectomy for chronic heel ulceration. *J Foot Ankle Surg* 1994; 33: 572.
16. Baravarian B, Menendez MM, Weinheimer DJ, Lowery C, Kosanovich R, Vidt L. Subtotal calcanectomy for the treatment of large heel ulceration and calcaneal osteomyelitis in the diabetic patient. *J Foot Ankle Surg* 1999; 38: 194.
17. Smith DG, Stuck RM, Ketner L, Sage RM, Pinzur MS. Partial calcanectomy for the treatment of large ulcerations of the heel and calcaneal osteomyelitis. *J Bone Joint Surg (Am.)* 1992; 74: 571–6.
18. Martini M, Martini-Benkeddache Y, Bekkechi T, Daoud A. Treatment of chronic osteomyelitis of the calcaneus by resection of the calcaneus: a report of twenty cases. *J Bone Joint Surg (Am)* 1974; 56: 542–8.
19. Crandall RC, Wagner FW Jr. Partial and total calcanectomy: a review of thirty-one consecutive cases over a ten-year period. *J Bone Joint Surg (Am)* 1981; 63: 152–5.
20. May JW Jr, Rohrich RJ. Foot reconstruction using free microvascular muscle flaps with skin grafts. *Clinics in Plastic Surgery* 1986; 13: 681.
21. Yildirim S, Akan M, Aköz T. Soft tissue reconstruction of the foot with distally based neurocutaneous flaps in diabetic patients. *Ann Plast Surg* 2002; 48: 258–64.

---

### \*Ioannis A. Ignatiadis

Hand Surgery-Upper Limb and Microsurgery Department  
 KAT General Hospital  
 Athens, Greece  
 Email: ignatioa@yahoo.com