



Shock Thyroid in a Patient with Septic Shock: A Case Report and Literature Review

패혈성 쇼크 환자에서 동반된 쇼크 갑상샘:
증례 보고 및 문헌 고찰

Wang Hyon Kim, MD¹ , Min Seon Kim, MD^{1*} , Jun Ho Kim, MD² ,
Kyung Hee Lee, MD¹ , Jung Hwan Lee, MD³

Departments of ¹Radiology and ³Hospital Medicine, Inha University Hospital, Inha University College of Medicine, Incheon, Korea

²Department of Radiology, Incheon St. Mary's Hospital, College of Medicine, The Catholic University of Korea, Incheon, Korea

Shock thyroid is a rare manifestation of the CT hypotension complex and can be diagnosed when thyroid and perithyroidal edemas are observed on CT during the onset of shock. Shock thyroid can be a useful CT sign for decompensated shock. This condition is reversible and recovers rapidly with adequate treatment. We present the case of an 84-year-old female with septic shock, exhibiting CT features consistent with a shock thyroid. We also reviewed the clinical and radiological findings reported in the literature. The present case emphasizes that shock thyroid can be an early indicator of impending hemodynamic instability and has important prognostic and therapeutic implications.

Index terms Thyroid; Septic Shock; Hypotension; Multidetector Computed Tomography

INTRODUCTION

Shock thyroid is an uncommon part of the CT hypotension complex (1, 2). Shock thyroid manifests as thyroid and perithyroidal edema, which is incidentally noted in CT of patients with shock conditions (1, 2). To our knowledge, only seven cases have been reported in the literature (1, 2), and because this disease is largely unknown to radiologists and clinicians, it is frequently underdiagnosed (2). The relationship between shock thyroids and poor prognosis remains unclear. However, shock itself is a life-threatening condition that can lead to multiple organ failure. Prompt diagnosis of shock is very im-

Received December 28, 2020

Revised January 25, 2021

Accepted February 1, 2021

*Corresponding author

Min Seon Kim, MD
Department of Radiology,
Inha University Hospital,
Inha University
College of Medicine,
27 Inhang-ro, Jung-gu,
Incheon 22332, Korea.

Tel 82-32-890-2769

Fax 82-32-890-2743

E-mail dudtkdgbdq@gmail.com

This is an Open Access article distributed under the terms of the Creative Commons Attribution Non-Commercial License (<https://creativecommons.org/licenses/by-nc/4.0>) which permits unrestricted non-commercial use, distribution, and reproduction in any medium, provided the original work is properly cited.

ORCID iDs

Wang Hyon Kim
<https://orcid.org/0000-0002-3696-5029>
Min Seon Kim
<https://orcid.org/0000-0002-9778-2760>
Jun Ho Kim
<https://orcid.org/0000-0002-7913-7506>
Kyung Hee Lee
<https://orcid.org/0000-0001-9019-0693>
Jung Hwan Lee
<https://orcid.org/0000-0001-7567-0664>

portant for proper treatment of the underlying condition. Thus, shock thyroid is a helpful imaging indicator to identify inadequate perfusion in patients with shock (1, 2).

Here, we present the case of a female with septic shock secondary to *Staphylococcus aureus* bacteremia of unknown source, and conduct a comprehensive review of the literature. Our study emphasizes that shock thyroid is not related to thyroid injury or primary disease, but is related to perfusion alterations. Shock thyroid must be distinguished from other pathologies of the thyroid gland to avoid unnecessary tests and to establish an appropriate treatment plan.

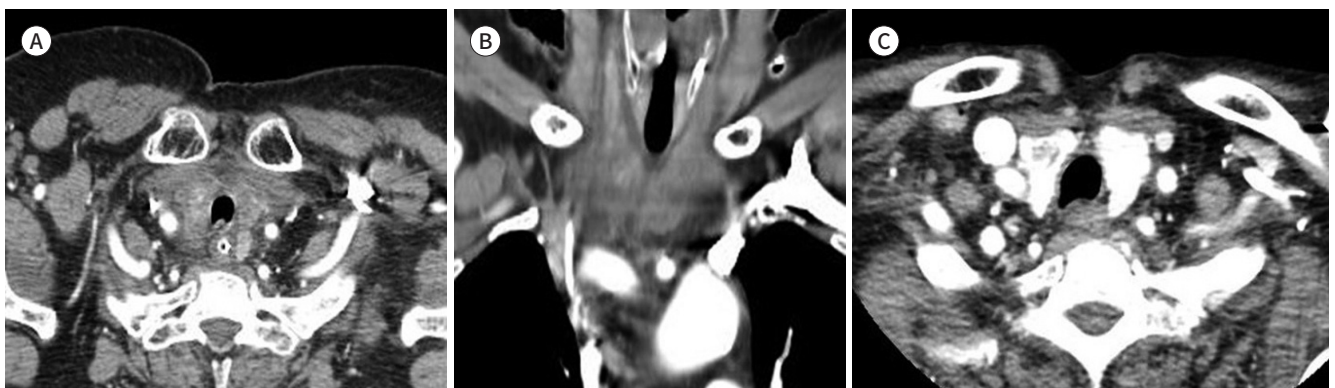
CASE REPORT

An 84-year-old incapacitated female with underlying Alzheimer's dementia presented to our emergency department with a chief complaint of fever. The patient had been admitted to our hospital 39 days previously, due to pulmonary thromboembolism and deep vein thrombosis. Her initial vital signs were as follows: blood pressure, 87/44 mm Hg; heart rate, 105 bpm; and body temperature, 38.2°. Laboratory analyses showed leukocytosis, elevated levels of C-reactive protein, and serum lactate level of 3.57 mmol/L. Her clinical presentation was characterized by septic shock. Initial blood culture revealed methicillin-resistant *Staphylococcus aureus* bacteremia.

Approximately 4 hours after arriving at the emergency department, the patient underwent contrast-enhanced chest and abdominal CT to identify the infection focus. Chest CT revealed multiple peripheral nodules in both lungs, indicating septic embolism. Additionally, CT demonstrated mild swelling and heterogeneous enhancement of the thyroid gland with perithyroidal fluid collection (Fig. 1A, B). CT scan obtained at the previous admission due to pulmonary thromboembolism did not show abnormalities in the thyroid gland, except a probable benign hypo-attenuating nodule in the right thyroid gland. The radiologic findings in the thyroid gland were interpreted as shock thyroid. However, there were no accompanying signs of the CT hypotension complex, such as shock bowel, collapse of the inferior vena cava

Fig. 1. An 84-year-old female with septic shock and shock thyroid.

A, B. Axial and coronal reconstruction images of the contrast-enhanced chest CT obtained at the emergency department demonstrate diffuse parenchymal swelling and heterogeneous enhancement of the thyroid gland. Perithyroidal fluid collection is also observed.
C. Follow-up contrast-enhanced CT image obtained 22 hours after (A) and (B) showing remarkable improvement. The thyroid gland demonstrates a normal size and homogenous enhancement with near-complete resolution of the perithyroidal fluid collection.



and aorta, and peripancreatic fluid (3) in concurrent abdominal CT.

The patient was admitted to the intensive care unit. The source of methicillin-resistant *Staphylococcus aureus* bacteremia was uncertain. Glycopeptide antibiotic and fluid resuscitation, with diluted norepinephrine, were administered through a central venous catheter. The patient became hemodynamically stable after resuscitation therapy. The attending physician performed follow-up neck CT and thyroid function tests to differentiate the primary thyroid gland disease. Neck CT taken 22 hours after the initial chest CT demonstrated normalization of size and enhancement pattern of the thyroid gland (Fig. 1C). Perithyroidal fluid collection was mostly resolved. The thyroid function test on the same day showed normal concentrations of serum free thyroxine (T4, 1.23 ng/dL) and serum thyroid-stimulating hormone (0.53 mIU/L), and low concentration of serum triiodothyronine (T3, 58.5 ng/dL). After 4 days in the intensive care unit, the patient was moved to the general ward.

This study was approved by the Institutional Review Board of our institution and the requirement for informed consent was waived (IRB No. 2020-07-033).

DISCUSSION

The CT hypotension complex refers to a spectrum of CT findings with severe hypotension (3, 4). It is mainly present in abdominal organs, but multiple organs can exhibit various atypical features (3, 4). In 2006, Brochert and Rafoth (1) reported thoracic CT findings of three traumatized patients with hypovolemic shock, showing heterogeneous thyroid contrast enhancement and fluid surrounding the thyroid. They described these CT findings as “shock thyroid” and considered as part of the CT hypotension complex rather than direct traumatic injury (1).

The exact incidence of shock thyroid remains unknown, and to our knowledge, only seven cases have been reported in the literature (Table 1) (1, 2). It is thus certain that shock thyroid is a relatively rare manifestation of the CT hypotension complex. In a previous study involving traumatized or non-traumatized 41 patients with shock bowel on abdominal CT, no shock thyroid cases were found (4). However, because of the low awareness about this disorder, it might be frequently misdiagnosed, as the findings might be attributed to other conditions, such as thyroiditis or traumatic injury (2).

Although the CT hypotension complex was reported for the first time in traumatic patients with hemodynamic instability (5), it may also occur in multiple other hypovolemic conditions, including neurogenic shock from head or spinal injury, blood loss, sepsis, and cardiac arrest (4). Similarly, shock thyroid can be present in patients with hypotension regardless of the underlying etiology (2). One of the seven previously reported patients was a case of shock thyroid secondary to septic shock, as in our patient (2).

The mechanism of the shock thyroid is yet clearly established. The CT hypotension complex is thought to reflect alterations in perfusion secondary to hypotension or hypovolemia affecting sympathetic splanchnic stimulations. Hypoperfusion may affect the thyroid gland, which is a highly vascular organ, resulting in cellular edema or death, as well as intracellular fluid exudation (1, 2). Alternatively, severe hypovolemia may trigger shock thyroid since it stimulates transient thyrotoxicosis, which maintains cardiac output by increasing the heart

Table 1. Summary of Cases of Shock Thyroid in the Literature

Reference	Underlying Disease	Cause	Age	Sex	TFT	Other Accompanying CT Hypotension Complex	Follow Up CT	Outcome
Brochert and Rafoth, 2006 (1)		Trauma (gunshot)	29	F	NA	Shock bowel	Post-trauma days 2 and 7; normalization	Discharge
Brochert and Rafoth, 2006 (1)		Trauma (vehicle collision)	31	F	WNL (initial and 2 months later)	Shock bowel Periportal edema	Post-trauma, 11 hours later and day 28	Discharge
Brochert and Rafoth, 2006 (1)		Trauma (vehicle collision)	12	M	NA	Shock bowel	Post-trauma day 12	Discharge
Han et al., 2017 (2)	Parkinson's disease	Septic shock secondary to pneumonia	79	M	NA	NA	NA	Discharge
Han et al., 2017 (2)	Bipolar I disorder	Cardiac arrest of unknown origin Post-ROSC	25	F	NA	NA	HD 14	Expire on HD 20
Han et al., 2017 (2)		Trauma Post-ROSC	22	F	NA	Shock bowel Peripancreatic edema	NA	Expired on HD 5
Han et al., 2017 (2)		Trauma (bicycle accident) Post-ROSC	17	M	NA	Shock bowel, periportal edema Small-caliber IVC	NA	Expired on HD 2
Our case, 2020	Alzheimer's dementia	Septic shock secondary to UTI	84	F	Low T3 level Normal FT4 and TSH level	NA	22 hours after initial CT	Discharge

F = female, FT4 = free thyroxine, HD = hospital day, IVC = inferior vena cava, M = male, ROSC = return of spontaneous circulation, TFT = thyroid function test, TSH = thyroid-stimulating hormone, T3 = triiodothyronine

rate (1, 2). However, in our patient, these morphological changes were not associated with alterations in thyroid function. Although, the results of the thyroid function test showed slightly decreased T3 levels, this finding may be attributed to the normal aging process (6). In the abovementioned previous study, thyroid function tests were performed only in one of the seven patients, and as in our patient, the levels were in the normal range (1).

Typical CT findings of shock thyroid include inhomogeneous enhancement or heterogeneous parenchymal attenuation of the thyroid gland with perithyroidal fluid collection, representing thyroid and perithyroidal edema (1, 2). These changes are reversible; however, the recovery time for the shock thyroid remains unknown (1, 2). In our patient, follow-up CT taken 22 hours later showed a normal enhancement pattern of the thyroid gland. Previous studies reported that the thyroid gland was almost normalized after only 11 hours in a patient with trauma (1). These findings suggest that regardless of the underlying cause, proper management of hypovolemia and hypotension results in rapid normalization of the thyroid gland and adjacent tissue. Shock thyroid may be accompanied by a constellation of findings, including diffusely thickened bowel loops with enhancing walls (shock bowel), collapse of the inferior vena cava and aorta, variable enhancement of the pancreas with peripancreatic fluid, delayed nephrogram, decreased enhancement of the spleen and liver, and increased enhancement of the adrenal glands (1-3). None of these findings were observed in our patient.

The clinical implications of the shock thyroid are unclear. Usually, the CT hypotension complex indicates poor prognosis (3-5). However, the relationship between poor prognosis and shock thyroid is unclear due to the lack of adequate reports and large studies. Although three out of eight reported patients expired shortly after the diagnosis, it might be dangerous to jump to hasty conclusions due to the limited number of reported cases (1, 2). However, early recognition of shock thyroid is essential because it is a critical condition leading to permanent organ damage and death. Clinicians and radiologists must recognize that shock thyroid is an indicator of hypoperfusion and initiate proper management immediately. We believe that awareness of this disorder will help distinguish shock thyroid from other pathologies.

In conclusion, shock thyroid is a useful early indicator of impending hemodynamic instability and is a reversible phenomenon. It is important for radiologists and clinicians to recognize and report shock thyroid as a manifestation of the CT hypotension complex, rather than a condition resulting from direct injury or other primary thyroid disorders.

Author Contributions

Conceptualization, all authors; data curation, K.W.H., K.M.S.; investigation, K.W.H., K.M.S.; project administration, K.M.S., K.J.H., L.K.H.; resources, L.J.H.; supervision, K.J.H., L.K.H., L.J.H.; visualization, K.W.H., K.M.S.; writing—original draft, all authors; and writing—review & editing, K.W.H., K.M.S.

Conflicts of Interest

The authors have no potential conflicts of interest to disclose.

Funding

None

REFERENCES

1. Brochert A, Rafoth JB. Shock thyroid: a new manifestation of the hypovolemic shock complex in trauma patients. *J Comput Assist Tomogr* 2006;30:310-312
2. Han DH, Ha EJ, Sun JS, Jung SL. Remarkable CT features of shock thyroid in traumatic and non-traumatic patients. *Emerg Radiol* 2017;24:319-324
3. Ryan MF, Hamilton PA, Sarrazin J, Chu P, Benjaminov O, Lam K. The halo sign and peripancreatic fluid: useful CT signs of hypovolaemic shock complex in adults. *Clin Radiol* 2005;60:599-607
4. Ames JT, Federle MP. CT hypotension complex (shock bowel) is not always due to traumatic hypovolemic shock. *AJR Am J Roentgenol* 2009;192:W230-W235
5. Taylor GA, Fallat ME, Eichelberger MR. Hypovolemic shock in children: abdominal CT manifestations. *Radiology* 1987;64:479-481
6. Mitrou P, Raptis SA, Dimitriadis G. Thyroid disease in older people. *Maturitas* 2011;70:5-9

패혈성 쇼크 환자에서 동반된 쇼크 갑상샘: 증례 보고 및 문헌 고찰

김양현¹ · 김민선^{1*} · 김준호² · 이경희¹ · 이정환³

쇼크 갑상샘(shock thyroid)은 CT 저혈압 복합체(CT hypotension complex)의 드문 발현 중 하나이며, 쇼크 상황에서 CT상 갑상샘과 갑상샘 주위에 부종이 관찰될 때 진단 가능하다. 쇼크 갑상샘은 비보상성 쇼크를 시사하는 유용한 CT 징후일 수 있다. 이 상태는 가역적이며 적절한 치료를 통해 빠르게 회복될 수 있다. 저자들은 쇼크 갑상선과 일치하는 CT 소견을 보인 패혈성 쇼크 상태의 84세 여자 환자의 증례를 보고한다. 이와 더불어, 문헌에 보고된 임상 및 영상 소견을 함께 고찰하고자 한다. 본 증례는 쇼크 갑상선이 임박한 혈류역학적 불안정성의 초기 지표가 될 수 있으며, 중요한 예후 및 치료적 함의가 될 수 있음을 강조한다.

인하대학교 의과대학 인하대학교병원 ¹영상의학과, ³입원외과,
²가톨릭대학교 의과대학 인천성모병원 영상의학과