

[CASE REPORT]

Crowned Dens Syndrome Associated with Bowel Cleaning for Colonoscopy

Naoto Kohno¹, Yoichiro Kobori¹ and Shuhei Yamaguchi²

Abstract:

A 77-year-old man was admitted with posterior cervical pain, lumbago, a low-grade fever, and anorexia after bowel cleaning with polyethylene glycol for colonoscopy. Computed tomography of the neck showed calcification of the transverse ligament of the atlas. He was diagnosed with crowned dens syndrome (CDS). His condition improved following treatment with corticosteroids. This represents a rare case of CDS after endoscopy with polypectomy. We should consider CDS in the differential diagnosis of patients with unexplained fever and posterior cervical pain after bowel preparation for colonoscopy.

Key words: crowned dens syndrome, pseudogout, polyethylene glycol, colonoscopy, computed tomography

(Intern Med 56: 2645-2647, 2017)

(DOI: 10.2169/internalmedicine.8527-16)

Introduction

Cervical pseudogout is known as crowned dens syndrome (CDS) because of the radiological findings of a crown-like feature surrounding the odontoid process (dens) (1). Patients with CDS are often misdiagnosed as having meningitis, discitis, spondylitis, epidural abscess, polymyalgia rheumatica, giant cell arthritis, rheumatoid arthritis, cervical spondylitis, or a metastatic spinal tumor (2-7), which may lead to unnecessary invasive investigations (e.g., lumbar puncture and biopsies), inappropriate treatment (antibiotics or antiviral drugs), and prolonged hospitalization (8). We herein report a case of CDS that was associated with bowel cleaning with polyethylene glycol in preparation for colonoscopy and polypectomy.

Case Report

A 77-year-old man was diagnosed with colonic polyps at a screening colonoscopy in Seto Inland Sea Hospital. He had no complications associated with the examination. He was admitted 5 weeks later and underwent endoscopic mucosal resection (EMR). His condition was good and he was discharged 2 days later. Polyethylene glycol (PEG) was used

for the bowel preparation before both of the colonoscopic examinations. The next day, he developed acute posterior cervical pain, lumbago, and low-grade fever. His fever developed 8 days after EMR and reached a peak temperature of 39.2°C. The patient was readmitted 10 days after EMR.

On admission, his temperature was 36.2°C. He had no symptoms of focal infection other than cervical pain. His cervical range of motion was very limited because of the pain, but there was no redness, warmth, or swelling of the neck. The laboratory data were consistent with an inflammatory reaction, with a leucocyte count of 11,200/mm³ and a C-reactive protein (CRP) level of 17.5 mg/dL. Slight electrolyte abnormalities were found: Na, 134 mmol/L (normal range: 136-148); K, 3.4 mmol/L (3.8-5.0); and Cl, 95 mmol/L (96-107). There were no significant abnormalities in the other laboratory findings, including the liver and renal function, and the levels of creatine kinase (CK), antinuclear antibodies, and rheumatoid factor. Blood cultures were subsequently reported as negative. Thoraco-abdominal computed tomography (CT) revealed no abnormalities. Intravenous ceftriaxone showed no effect. On day 4, he complained of arthralgia of both knees. At the time, the patient's leucocyte count was 10,900/mm³ and his CRP level was 16.3 mg/dL, but his electrolyte levels were normal. Cervical CT showed calcification of the transverse ligament of the atlas (Fig. 1)

¹Department of Internal Medicine, Seto Inland Sea Hospital, Japan and ²Department of Neurology, Faculty of Medicine, Shimane University, Japan

Received: November 11, 2016; Accepted: February 13, 2017; Advance Publication by J-STAGE: September 6, 2017

Correspondence to Dr. Naoto Kohno, nkohno@ikirukai.or.jp and kohnonaoto@gmail.com

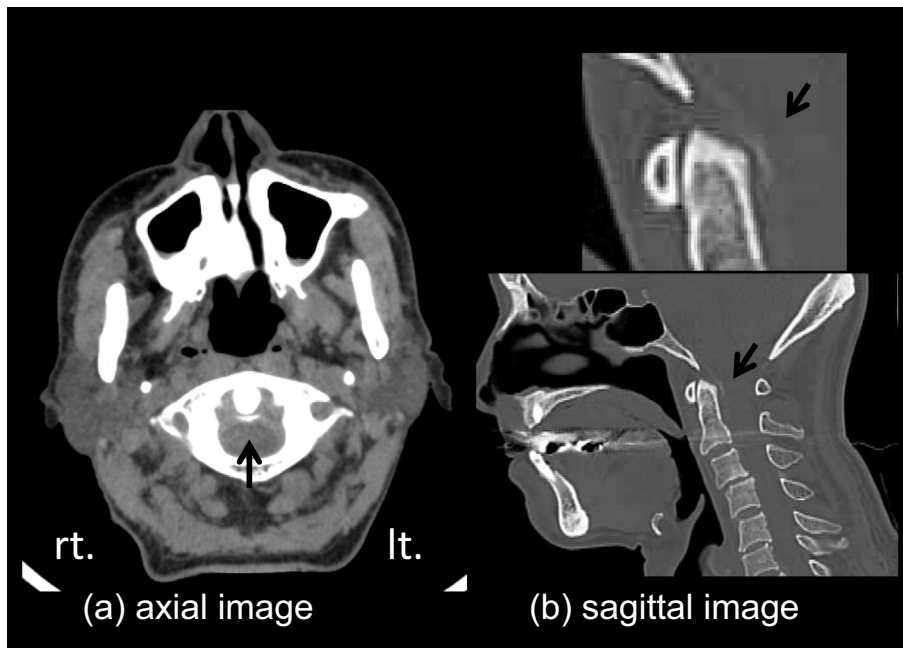


Figure 1. Cervical CT of the odontoid process (dens): (a) axial and (b) sagittal images show calcification of the transverse ligament of the atlas.

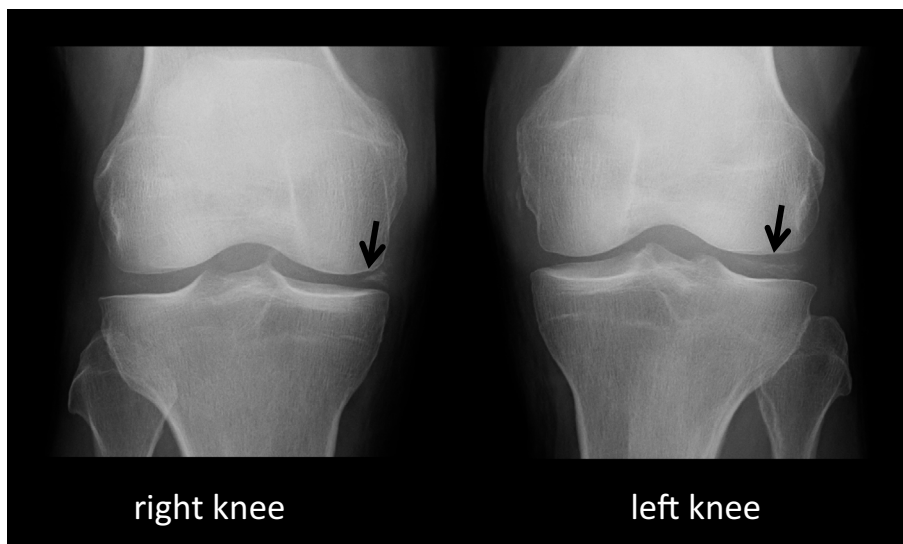


Figure 2. X-rays of both knees show calcification of the lateral meniscus of the right knee and the medial meniscus of the left knee.

and he was diagnosed with CDS. X-rays of both knees showed calcification of the meniscus (Fig. 2), strongly suggesting a diagnosis of pseudogout of the knee joints.

We stopped the antibiotics and initiated treatment with an oral non-steroidal anti-inflammatory drug but it was only minimally effective, and a serum analysis revealed the persistence of the inflammatory reaction. On day 8, treatment with oral prednisone was initiated at a dose of 10 mg/day. This was increased to 30 mg/day after limited improvement was observed with the initial dose. The patient's symptoms gradually improved, with a leucocyte count of 13,600/mm³ and a CRP level of 1.5 mg/dL. He was taking prednisone (10 mg/day) when he was discharged on day 90.

Discussion

The side effects of bowel preparation regimens with PEG for colonoscopy include abdominal pain, distension, nausea, vomiting, and dehydration. To date, only one case of pseudogout associated with the use of PEG for bowel preparation for colonoscopy has been reported. Mehta et al. (9) reported the case of an 83-year-old man who had an attack of polyarticular pseudogout, including CSD, soon after undergoing polypectomy for sigmoid polyps that was likely related to bowel cleansing with PEG. The authors hypothesized that PEG could cause electrolyte abnormalities, which

might have played a role in precipitating the patient's pseudogout; however, the laboratory assessment of the patient showed normal electrolyte levels.

Our patient was also given PEG to clean the bowel before the initial screening colonoscopy and the subsequent EMR. Our patient showed no complications after the first screening colonoscopy, but developed symptoms of polyarticular pseudogout, including CDS, 2 days after EMR. The risk factors for pseudogout include age, joint trauma, serious illness, hemochromatosis, electrolyte abnormalities, and endocrine disorders. The initial electrolyte data showed slight abnormalities, but they quickly returned to normal values. As in the case reported by Mehta et al., the significance of electrolyte abnormalities in the development of CDS was unclear in the present case.

To the best of our knowledge, our patient is the second case of CDS associated with bowel preparation for polypectomy. CDS should be considered in the differential diagnosis of patients with an unexplained fever and posterior cervical pain after bowel cleaning with PEG in order to initiate appropriate therapy without performing invasive and useless examinations, inappropriate treatment, or prolonged hospitalization. The accumulation of further cases will be necessary to study the pathophysiology of CDS after colonoscopy.

The authors state that they have no Conflict of Interest (COI).

References

1. Bouvet JP, le Parc JM, Michalski B, Benlahrache C, Auquier L. Acute neck pain due to calcifications surrounding the odontoid process: the crowned dens syndrome. *Arthritis Rheum* **28**: 1417-1420, 1985.
2. Aouba A, Vuillemin-Bodaghi V, Mutschler C, De Bandt M. Crowned dens syndrome misdiagnosed as polymyalgia rheumatica, giant cell arteritis, meningitis or spondylitis: an analysis of eight cases. *Rheumatology (Oxford)* **43**: 1508-1512, 2004.
3. Rajakulendran S, Smith D, Deighton C. Re: Aouba et al. Crowned dens syndrome misdiagnosed as polymyalgia rheumatica, giant cell arteritis, meningitis or spondylitis. *Rheumatology (Oxford)* **45**: 360-361, 2006.
4. Ishikawa K, Furuya T, Noda K, Okuma Y. Crowned dens syndrome mimicking meningitis. *Intern Med* **49**: 2023, 2010.
5. Takahashi T, Minakata Y, Tamura M, Takasu T, Murakami M. A rare case of crowned dens syndrome mimicking aseptic meningitis. *Case Rep Neurol* **5**: 40-46, 2013.
6. Lee GS, Kim RS, Park HK, Chang JC. Crowned dens syndrome: a case report and review of the literature. *Korean J Spine* **11**: 15-17, 2014.
7. Oka A, Okazaki K, Takeno A, et al. Crowned dens syndrome: report of three cases and a review of the literature. *J Emerg Med* **49**: e9-e13, 2015.
8. Koyfman A, Yaffe D. Crowned dens syndrome. A case report. *Neuroradiol J* **27**: 495-497, 2014.
9. Mehta BP, Shmerling RH, Moss AC. Pseudogout after polyethylene glycol bowel cleansing. *J Clin Gastroenterol* **43**: 95-96, 2009.

The Internal Medicine is an Open Access article distributed under the Creative Commons Attribution-NonCommercial-NoDerivatives 4.0 International License. To view the details of this license, please visit (<https://creativecommons.org/licenses/by-nc-nd/4.0/>).