

A Novel Funnel-Shaped Flap for Reconstruction Surgery after Total Laryngopharyngectomy with Total Glossectomy

Koreyuki Kurosawa, MD*

Yukinori Asada, MD†

Ko Matsumoto, MD‡

Takayuki Imai, MD†

Kazuto Matsuura, MD†

Takahiro Goto, MD*

Summary: Reconstruction following total laryngopharyngectomy with total glossectomy (TLPTG) is challenging. To reconstruct this extended range of mucosal defect, it is necessary to overcome the remarkable discrepancy of apertures of oral and esophageal sides. We report a case of reconstruction surgery for total laryngopharyngectomy with total glossectomy with a funnel-shaped rectus abdominis musculocutaneous flap. The patient recovered without major complications and could keep a relatively good swallowing function. We believe this simple method should contribute to cases with complicated ablation. (*Plast Reconstr Surg Glob Open* 2017;5:e1504; doi: 10.1097/GOX.0000000000001504; Published online 22 September 2017.)

Circumferential laryngopharyngeal defect should be reconstructed with a free jejunal transfer (FJT) or a tubed fasciocutaneous free flap.¹⁻⁴ FJT has been favored because of its natural tubular structure and the relatively low rate of fistula formation.^{2,3} FJT, however, entails significant donor-site morbidity associated with abdominal surgery requiring bowel reanastomosis, systemic fluid shift, and frequent postoperative ileus.^{1,2} Recently, reconstruction with a modified anterolateral thigh flap was reported, in which a good swallowing function and a low rate of fistula and stricture formation at distal anastomosis comparable with FJT were attained.⁵ With FJT reconstruction, a significant problem emerges when a complex large defect is created by extended surgery with glossectomy [total laryngopharyngectomy with total glossectomy (TLPTG)] because in such cases the anatomical circumference of the oral side is significantly greater than that of the jejunum.^{6,7} To overcome this difficulty, we invented a novel method of reconstructive surgery with a funnel-shaped rectus abdominis musculocutaneous flap (RAMCF) for TLPTG, which enabled a good swallowing function without major complications.

From the *Department of Plastic and Reconstructive Surgery, Miyagi Cancer Center, Natori, Japan; †Department of Head and Neck Surgery, Miyagi Cancer Center, Natori, Japan; and ‡Department of Diagnostic Radiology, Miyagi Cancer Center, Natori, Japan. Received for publication June 2, 2017; accepted July 31, 2017.

Copyright © 2017 The Authors. Published by Wolters Kluwer Health, Inc. on behalf of The American Society of Plastic Surgeons. This is an open-access article distributed under the terms of the Creative Commons Attribution-Non Commercial-No Derivatives License 4.0 (CCBY-NC-ND), where it is permissible to download and share the work provided it is properly cited. The work cannot be changed in any way or used commercially without permission from the journal. DOI: 10.1097/GOX.0000000000001504

CASE REPORT

A 64-year-old man had a recurrent hypopharyngeal carcinoma (cT4aN2cM0) 3 years after chemoradiotherapy. The tumor had extended from the hypopharynx to the oropharynx including the tongue. A surgery including TLPTG, soft-palate resection, bilateral modified neck dissection, and cervical skin resection was performed (Fig. 1). To reconstruct the surgical defects, a free RAMCF with the spindle-shaped skin was harvested from the right side of the abdominal wall with the deep inferior epigastric artery and vein.

With this flap, a funnel-shaped tube was fabricated before clamping vessels (Fig. 2). One of the lateral sides of the spindle-shaped flap was folded vertically and was rolled into a funnel-shaped tube with its skin surface inside after double-layer suturing of the skin (dermostitch and continuous suture). The funnel shape made it easy to reverse the tube inside out because the diameter of the oral side lent it enough space for that purpose. Another suturing was added to the subcutaneous adipose tissue, which all together gave the wall triple-layer suturing (Fig. 3). After flap elevation, donor site was sutured directly.

The bottom of funnel-shaped tube was sutured to the oral floor, oropharynx, and nasopharynx, whereas the apex of funnel-shaped tube was anastomosed to the end of esophagus. The posterior wall of esophagus was incised longitudinally to insert the triangular skin flap to prevent the late stricture. The deep inferior epigastric artery and vein were anastomosed to the left transverse cervical artery in an end-to-end manner and to the internal jugular vein in an end-to-side manner, respectively. The soft palate was not reconstructed. A deltopectoral flap was elevated

Disclosure: The authors have no financial interest to declare in relation to the content of this article. The Article Processing Charge was paid for by the authors.

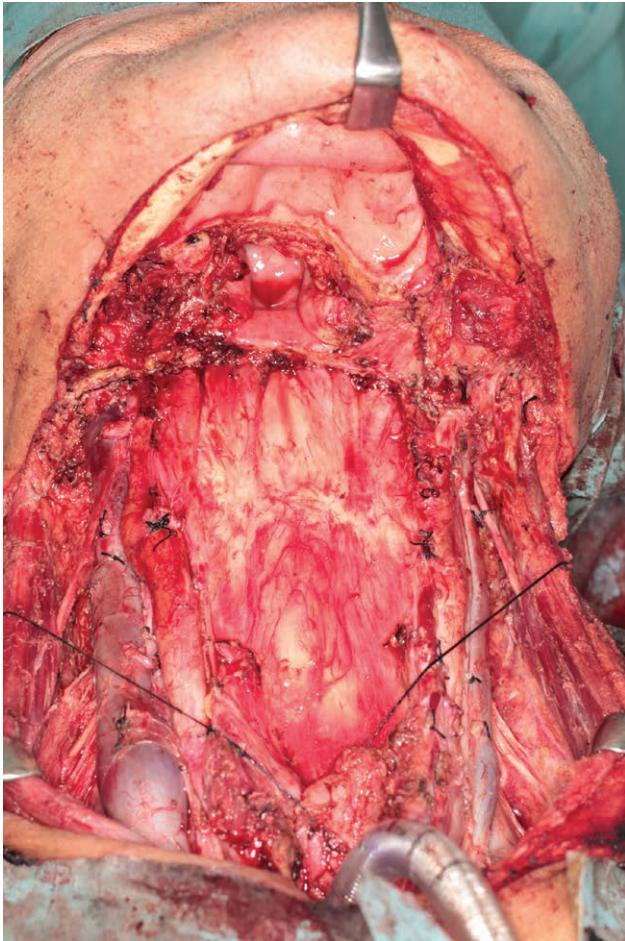


Fig. 1. The defect after tumor excision. TLPTG, soft palate resection, bilateral modified neck dissection, and cervical skin resection were performed.

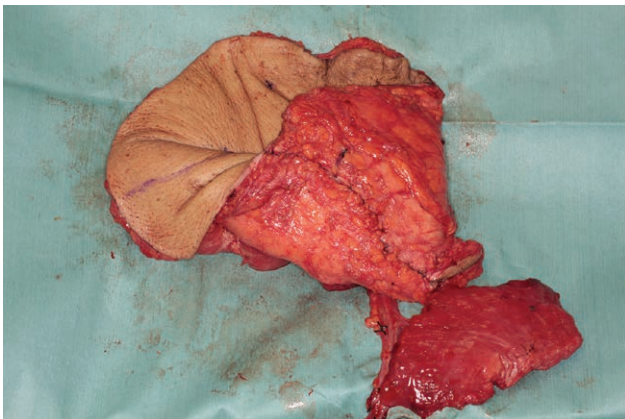


Fig. 2. Prefabricated funnel-shaped flap. The segmental muscle was made to cover the anastomosis part of esophagus side.

and transferred to make the tracheostoma. The resultant cervical skin defect was reconstructed with a pectoralis major muscle flap and a split-thickness skin graft (Fig. 4).

The patient recovered without major complications except for a residual cervical skin ulcer. After video fluorography at 21 days postoperatively, which demonstrated neither

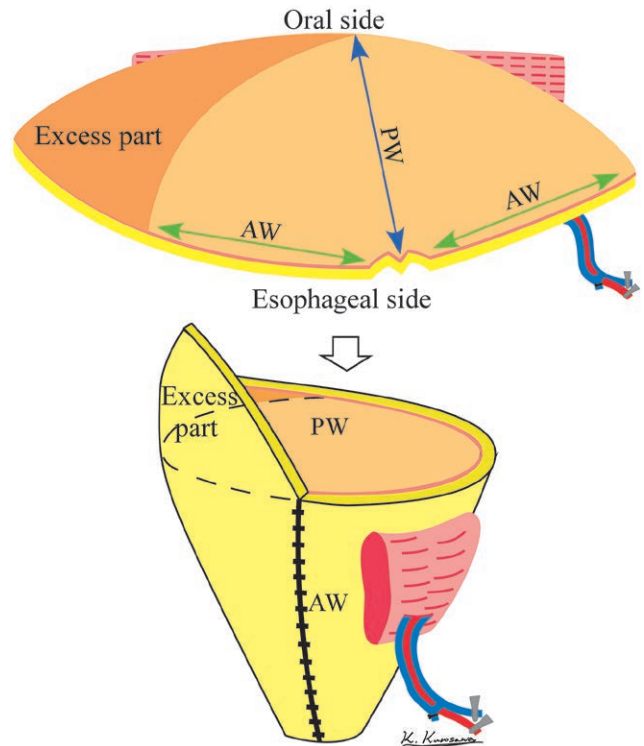


Fig. 3. Schematic representation of our surgical method. AW denotes the margins to be sutured for anterior wall shaping. PW for posterior wall. Note the tube is lined with cutaneous tissue inside (the flap reversed after skin suturing), and a piece of muscular tissue is attached on the outside for circulation.

leakage nor obstruction to the passage of food, he started oral intake with liquid and proceeded to pasty food. He resumed a soft diet without difficulty when discharged on foot from our hospital at 29 days postoperatively. He remained free of disease for 2 months after surgery and enjoyed oral intake of, for example, noodles. There was no evidence of stenosis by endoscopy and donor-site morbidity. Unfortunately, at 3rd month postoperatively, he died of local recurrence.

DISCUSSION

Reconstruction following TLPTG is challenging because a surgeon must solve the dilemma that there is a large difference between the apertures of food passage tube on the oral and esophageal sides.^{6,7} Also, to ensure food passage following the gravity, the inner surface of the tube must be smooth enough and nicely sloped (“a slide type slope”). Also, the transplanted tube is required to have as large surfaces as possible and to be properly housed in the neck space.

We invented a new method which met the aforementioned requirements of a transplanted tube by shaping the spindle-shaped cutaneous flap into a funnel shape so that it fitted the dimensions on oral and esophageal sides. This funnel-shaped tube provided the “slide type slope.” Post-operative leakage, which sometimes occurs with a fascio-cutaneous flap,²⁻⁵ seemed unlikely since the skin surfaces could be sutured water-tight as in usual skin suturing.

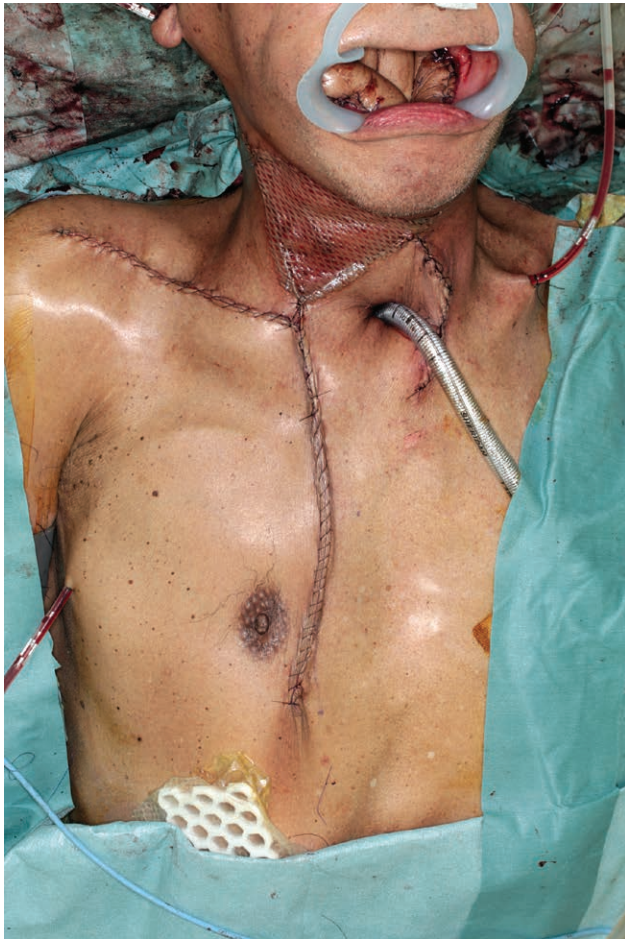

Fig. 4. Immediately postoperative appearance. A deltopectoral flap was elevated on the right side and transferred to make the tracheostoma. The resultant cervical skin defect was reconstructed with a right pectoralis major muscle flap and a split-thickness skin graft.

Furthermore, if the resection range of the primary lesion extends to the lateral and posterior walls of the oropharynx or even to the nasopharynx, the excessive part of the spindle-shaped flap allows itself filling the surgical defects by rotating the funnel-shaped tube (Fig. 3).

We adopted RAMCF, but in a case where the flap is too thick due to the adipose tissue to maintain the configuration of the funnel shape, the tube might easily collapse. In such a case, it is advisable to use anterolateral thigh flap (ALT), which normally has thin subcutaneous adipose tissue. Also, RAMCF might entail an abdominal wall herniation as a severe complication, about which we have been concerned. A special surgical technique to prevent the herniation and the patient's body shape made direct

suturing of the abdominal wall defect possible, whereas with ALT, skin graft would have been inevitable for the closure of the harvesting defect. The choice in future between RAMCF and ALT for the present purpose should depend on the patient's body shape.

Generally, the physical conditions of patients with a large tumor encompassing the oro- and hypopharynx and larynx are rather poor. Those patients, although technically operable, may not be indicated for surgery since the poor general conditions do not allow reconstruction involving abdominal open surgery and may be referred to a palliative care unit. In contrast, our novel reconstruction method with a funnel-shaped flap for TLPTG was simple with no open abdominal surgery and successfully provided a good postoperative deglutitive function without major complications. This new method would offer a curative treatment option with high quality of life for those patients who had no choice but to be referred to a palliative care unit.

Koreyuki Kurosawa, MD

Department of Plastic and Reconstructive Surgery
Miyagi Cancer Center
47-1 Nodayama Medeshima
Natori
Miyagi 981-1293
Japan

E-mail: koreyuki-kurosawa@miyagi-pho.jp; courajp@yahoo.co.jp

REFERENCES

1. Reece GP, Schuster MA, Miller MJ, et al. Morbidity and functional outcome of free jejunal transfer reconstruction for circumferential defects of the pharynx and cervical esophagus. *Plast Reconstr Surg.* 1995;96:1307-1316.
2. Yu P, Lewin JS, Reece GP, et al. Comparison of clinical and functional outcomes and hospital costs following pharyngoesophageal reconstruction with the anterolateral thigh free flap versus the jejunal flap. *Plast Reconstr Surg.* 2006;117:968-974.
3. Parmar S, Al Asaadi Z, Martin T, et al. The anterolateral fasciocutaneous thigh flap for circumferential pharyngeal defects—can it really replace the jejunum? *Br J Oral Maxillofac Surg.* 2014;52:247-250.
4. Murray DJ, Novak CB, Neligan PC. Fasciocutaneous free flaps in pharyngolaryngo-oesophageal reconstruction: a critical review of the literature. *J Plast Reconstr Aesthet Surg.* 2008;61:1148-1156.
5. Yu P, Hanasono MM, Skoracki RJ, et al. Pharyngoesophageal reconstruction with the anterolateral thigh flap after total laryngopharyngectomy. *Cancer.* 2010;116:1718-1724.
6. Jones NF, Eadie PA, Myers EN. Double lumen free jejunal transfer for reconstruction of the entire floor of mouth, pharynx and cervical oesophagus. *Br J Plast Surg.* 1991;44:44-48.
7. Rossmiller SR, Ghanem TA, Gross ND, et al. Modified ileocolic free flap: viable choice for reconstruction of total laryngopharyngectomy with total glossectomy. *Head Neck.* 2009;31:1215-1219.