

Efficacy and safety of balloon-assisted microdissection with Sapphire[®] II 1.0-mm balloon in balloon-uncrossable chronic total occlusion lesions

Yicong Ye^{1,*}, Xiliang Zhao^{1,*}, Jianjun Du^{2,*} and Yong Zeng¹ 

Abstract

Objective: Earlier studies have shown that the balloon-assisted microdissection (BAM) technique is feasible using a 1.2- to 1.5-mm small balloon in balloon-uncrossable chronic total occlusion (CTO) lesions. This study was performed to assess the efficacy and safety of the BAM technique with a Sapphire[®] II 1.0-mm balloon.

Methods: In this retrospective study, patients undergoing percutaneous coronary intervention for CTO were consecutively screened for balloon-uncrossable CTO lesions using BAM with the Sapphire[®] II 1.0-mm balloon. The patients' clinical and angiographic characteristics and procedural outcomes were collected for analyses.

Results: Twenty-four balloon-uncrossable CTO lesions were identified. Most of the CTO lesions were located in the right coronary artery, followed by the left anterior descending artery and left circumflex artery. The mean Japanese Multicenter CTO Registry (J-CTO) and Prospective Global Registry for the Study of Chronic Total Occlusion Intervention (PROGRESS CTO) scores were 1.96 and 1.38, respectively. The total technical success rates were 91.6% (22/24) and 75.00% (18/24) for the lesions that were successfully treated with BAM. No patients developed major complications with the exception of one patient who developed a femoral hematoma.

Conclusion: BAM with the Sapphire[®] II 1.0-mm balloon may be an effective and safe technique for balloon-uncrossable CTO lesions.

*These authors contributed equally to this work.

Corresponding author:

Yong Zeng, Department of Cardiology, Beijing Anzhen Hospital, Beijing Institute of Heart, Lung and Blood Vessel Diseases, Capital Medical University, Beijing, China
Chaoyan District, Beijing 100029, China.
Email: anzhenzy@163.com

¹Department of Cardiology, Beijing Anzhen Hospital, Beijing Institute of Heart, Lung and Blood Vessel Diseases, Capital Medical University, Beijing, China

²Department of Cardiology, Tongliao Hospital, Neimengu, China



Keywords

Chronic total occlusion, balloon-uncrossable, balloon-assisted microdissection, intentional balloon rupture, grenadoplasty, right coronary artery

Date received: 27 July 2020; accepted: 21 September 2020

Introduction

Several new techniques and equipment have recently been developed for treatment of chronic total occlusion (CTO). This has led to improvements in the effectiveness and feasibility of percutaneous coronary intervention (PCI) for CTO. Furthermore, such developments have improved the success rate of PCI for CTO, which has reached 85% to 90% in experienced centers.¹ The inability to pass through the CTO lesion with a balloon after successful guidewire crossing is one of the most common reasons for failure of PCI. This often occurs because of severe calcification and/or tortuosity at the occlusion site.² Data from the Prospective Global Registry for the Study of Chronic Total Occlusion Intervention (PROGRESS CTO) showed that balloon-uncrossable lesions accounted for 9% of all CTOs and were associated with significantly lower technical and procedural success compared with balloon-crossable lesions.³

Balloon-uncrossable lesions are primarily treated by increasing guiding catheter support and implementing plaque modification. Balloon-assisted microdissection (BAM), also known as intentional balloon rupture or grenadoplasty, is a plaque modification technique. A 1.2- to 1.5-mm balloon is pushed deep into the CTO lesion and intentionally inflated using an increasing level of high pressure until the balloon ruptures. However, this can lead to vessel perforation or dissection and resultant problematic removal of the ruptured

balloon.² The mechanism of the BAM technique involves modification of the plaque by rupture of the balloon; thus, the BAM balloon should be pushed against the CTO lesion as deeply as possible. The Sapphire[®] II 1.0-mm balloon (OrbusNeich, Hong Kong) is the smallest balloon for PCI and might be more easily inserted into a CTO lesion. In the current study, we aimed to determine the efficacy and safety of BAM using the Sapphire[®] II 1.0-mm balloon.

Methods

This retrospective study involved patients who underwent PCI for CTO from January 2018 to January 2020 at Beijing Anzhen Hospital and Tongliao Hospital. These patients were reviewed consecutively for balloon-uncrossable CTO lesions, which were defined as CTO lesions unable to be crossed by balloons despite an increase in guiding catheter support and appropriate balloon manipulation. The study was approved by the Institutional Review Board of Beijing Anzhen Hospital in Beijing (No. 2020027X; date of approval: 3 March 2020). All patients provided consent for treatment, and all patients' details have been de-identified.

As part of our routine practice, once the guidewire had successfully crossed the CTO lesion, an attempt was made to advance the antegrade microcatheter by replacing the CTO wire with the workhorse wire whenever possible. When the small semi-compliant predilation balloon and/or microcatheter

failed to cross the CTO lesion, small balloons (starting with a balloon diameter of ≤ 1.5 mm and ending with the Sapphire[®] II 1.0-mm balloon) were pushed against the CTO lesions with alternating forward and backward movements with inflation up to nominal pressure. Meanwhile, augmentation of guide catheter support with guide manipulation, an anchor balloon, and/or guide catheter extension was implemented whenever possible. The BAM technique with the Sapphire[®] II 1.0-mm balloon was applied when the above-mentioned attempts failed, before performing other crossing techniques such as excimer laser coronary atherectomy (ELCA) or rotational atherectomy (RA). As described previously,⁴ a rapid exchange Sapphire[®] II 1.0-mm balloon was replaced and pushed deep against the CTO lesion. The balloon was inflated to high pressure at 2 atm per second until it ruptured. To prevent blood from entering the balloon catheter, negative pressure was immediately applied, followed by neutral placement. BAM using other small balloons was not attempted.

CTOs were defined as occluded coronary lesions with at least 3 months of Thrombolysis in Myocardial Infarction (TIMI) grade 0 flow. Major adverse cardiac events (MACE) were defined as a composite of all-cause death, myocardial infarction, stroke, ischemia-driven revascularization, or cardiac tamponade requiring pericardiocentesis. Moderate calcification was defined as radiopaque densities observed only during the cardiac cycle (usually involving only one side of the vessel wall). Severe calcification was defined as radiopaque densities observed without cardiac motion prior to contrast injection (usually involving both sides of the vessel wall).⁵ Intravascular ultrasound (IVUS) revealed the largest arcs of calcium in the CTO segments, measured in degrees using a protractor centered on the lumen. Further, calcification was classified as 0° to 90° , 91° to 180° , 181° to 270° , or $>270^\circ$.⁶

BAM technical success was defined as successful delivery of the balloon into the CTO immediately after BAM and $<30\%$ residual angiographic stenosis with TIMI grade 3 flow after PCI. BAM procedural success was defined as achievement of $<30\%$ residual angiographic stenosis and restoration of TIMI grade 3 flow without MACE. The Japanese Multicenter CTO Registry (J-CTO) score and PROGRESS CTO score were calculated as described previously.^{7,8} Vascular complications were defined as femoral hematomas of ≥ 5 cm, retroperitoneal bleeding confirmed by computed tomography, any access-site surgical intervention, and femoral artery pseudoaneurysm confirmed by Doppler ultrasound.⁹

Categorical variables are presented as a percentage, and continuous variables are presented as mean \pm standardized deviation. Successful and unsuccessful BAM groups were compared using Fisher's exact test for categorical variables and the *t* test for continuous variables. The statistical tests were two-sided, and statistical significance was defined as $P < 0.05$. The statistical analyses were performed using SPSS Version 20.0 (IBM Corp., Armonk, NY, USA).

Results

In total, 263 cases of PCI for CTO were screened, and 24 patients with 24 balloon-uncrossable CTO lesions were included in the study. The patients' clinical and angiographic characteristics are listed in Table 1. The mean age of the patients was 61.3 years, and 66.7% of the study population was male. Conventional cardiovascular risk factors, including hypertension, diabetes, and smoking, were common among the patients, with a prevalence of 70.8%, 45.8%, and 50.0%, respectively. Most of the CTO lesions were located in the right coronary artery, followed by the left anterior descending artery and left circumflex

Table 1. Patients' clinical and angiographic characteristics.

Variables	Overall (n = 24)
Age, years	61.3 ± 10.1
Male	16 (66.7)
Smoking	12 (50.0)
Hypertension	17 (70.8)
Diabetes	11 (45.8)
Prior MI	6 (25.0)
Prior PCI	5 (20.8)
Prior CABG	2 (8.3)
CTO target vessel	
LAD	7 (29.2)
LCX	5 (20.8)
RCA	12 (50.0)
J-CTO score	1.96 ± 0.96
Blunt stump	8 (33.3)
Calcification	16 (66.7)
>45° bend	10 (41.7)
>20-mm length	10 (41.7)
Re-attempt	3 (12.5)
PROGRESS CTO score	1.38 ± 0.92
Proximal cap ambiguity	9 (37.5)
Tortuosity	5 (20.8)
LCX CTO	5 (20.8)
Absence of interventional collaterals	14 (58.3)

Data are presented as mean ± standard deviation or n (%). MI, myocardial infarction; PCI, percutaneous coronary intervention; CABG, coronary artery bypass grafting; CTO, chronic total occlusion; LAD, left anterior descending artery; LCX, left circumflex artery; RCA, right coronary artery; J-CTO score, Japanese Multicenter CTO Registry score; PROGRESS CTO score, Prospective Global Registry for the Study of Chronic Total Occlusion Intervention score.

artery. The mean J-CTO score was moderate because of the low proportion of reattempted cases.

The patients' procedural and clinical outcomes are listed in Table 2. Successful CTO wire crossing was achieved in all patients, mostly using the antegrade approach (91.7%). The BAM technique was applied in all patients, and the technical success rate was 75% (18 of 24 cases). Wire entrapment with balloon rupture occurred

Table 2. Patients' procedural and clinical outcomes.

Variable	Overall (n = 24)
Approach	
Antegrade	22 (91.7)
Retrograde	2 (8.3)
Fluoroscopy time, minutes	37.0 ± 17.5
Radiation dose, mGy	1585 ± 920
Intravascular ultrasound	8 (33.3)
Overall technical success	22 (91.6)
BAM technical success	18 (75.0)
Successful additional techniques	4 (16.6)
ELCA	2 (8.3)
RA	2 (8.3)
Overall procedural success	22 (91.6)
Vascular complication	1 (4.1)
In-hospital MACE	0 (0.0)
Coronary perforation	0 (0.0)
Coronary dissection	0 (0.0)

Data are presented as mean ± standard deviation or n (%). BAM, balloon-assisted microdissection; ELCA, excimer laser coronary atherectomy; RA, rotational atherectomy; MACE, major adverse cardiac event.

in one case; the ruptured balloon and wire were simultaneously removed, and recrossing the CTO was successful with the help of a new wire and balloon. A typical balloon-uncrossable CTO lesion in the right coronary artery is shown in Figure 1. This lesion was successfully treated using the BAM technique with the Sapphire® II 1.0-mm balloon.

The other advanced techniques that were applied to the lesions failed with use of the BAM technique. Four patients underwent successful recanalization with ECLA (n = 2) or RA (n = 2). Despite attempting all available techniques, treatment failure occurred in one patient. Another patient developed an uncontrolled femoral hematoma during the procedure. Neither coronary dissection nor perforation was identified during the procedure in any patients. No patients developed MACE during hospitalization.

The pressure at which the balloon ruptured was 12 atm in most cases, with the highest pressure being 20 atm (Figure 2 (a)). The patients in the unsuccessful BAM group were older and most had moderate or severe calcification compared with patients in the successful BAM group (Table 3). IVUS data were available for only eight patients (five in the successful BAM group and three in the unsuccessful BAM group). In the unsuccessful BAM group, the arc of calcification in IVUS was $>270^\circ$ (Figure 2(b)).

Discussion

In the current study, the technical success rate of BAM with the Sapphire[®] II 1.0-mm balloon reached 75% without coronary dissection or perforation. Therefore, this technique is suggested to be effective and safe for patients with balloon-uncrossable CTO lesions. Patients who underwent failed treatment with the BAM technique had more complex calcified lesions than those who underwent successful treatment with BAM.

The two main ways to manage balloon-uncrossable CTO lesions are augmentation of guide support and plaque modification.

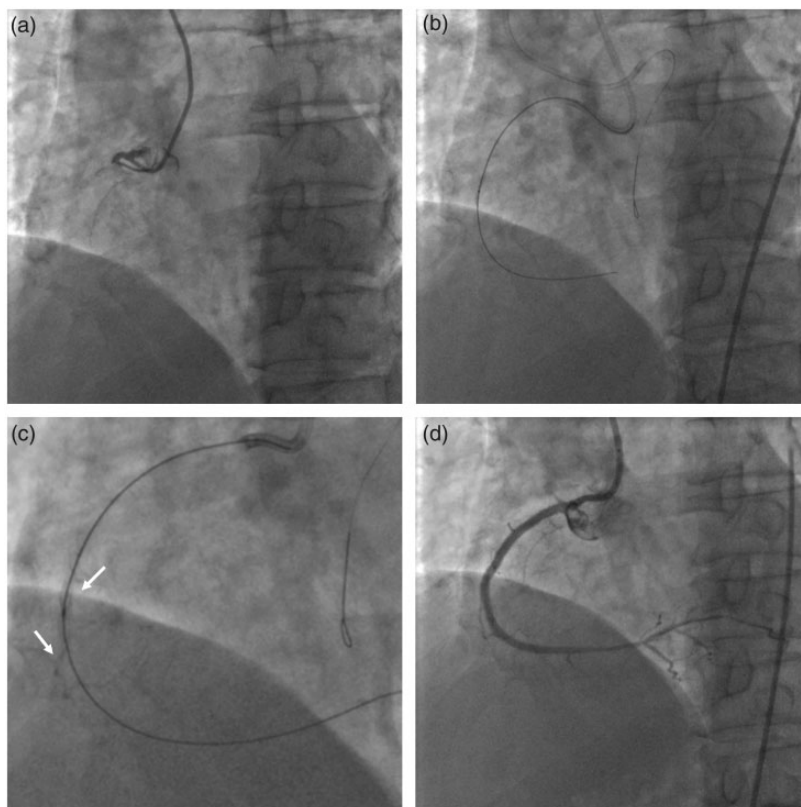


Figure 1. Uncrossable chronic total occlusion (CTO) lesion in the right coronary artery successfully treated with a Sapphire[®] II 1.0-mm balloon using the balloon-assisted microdissection (BAM) technique. (a) An angiogram indicated the CTO. (b) A small balloon still failed to cross the CTO lesion after balloon maneuvering and inflation. (c) BAM technique: rupture of Sapphire[®] II 1.0-mm balloon with contrast leakage (white arrows). (d) Final angiogram after recanalization.

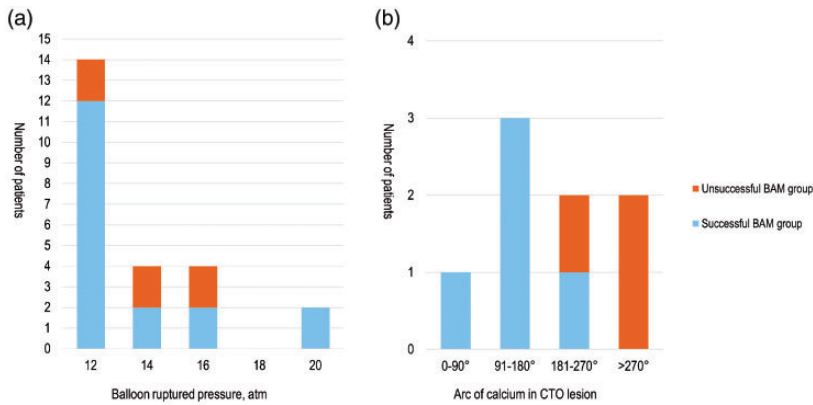


Figure 2. (a) Balloon rupture pressure in balloon-assisted microdissection (BAM) technique. (b) Largest calcium arc in the chronic total occlusion (CTO) segment assessed by intravascular ultrasound.

Several factors are associated with guide support, including vascular access (femoral artery) and the size and shape of the guiding catheter. For most cases, however, changes in the vascular access and/or guiding catheter are not allowed once wire crossing has been successfully performed in PCI for CTO lesions. In such circumstances, application of a guide extension or anchor balloon technique serves as an efficient means to enhance guide support. Kovacic et al.¹⁰ reported that guide extension, with a procedural success rate of 89.3%, is a simple, safe, and efficacious adjunctive device for balloon-uncrossable CTO. Thus, when appropriate, the guide extension and anchor balloon technique was used for all patients prior to BAM application in the present study.

Another approach to manage balloon-uncrossable CTO is plaque modification. BAM is one of the simplest and most widely used techniques and has a high technical success rate.^{3,4} However, if BAM fails, advanced techniques such as ELCA and RA are considered for atherectomy. In the LEONARDO Study, 80 patients with 100 complex coronary lesions, including CTO lesions, were treated using ECLA.¹¹ Technical success was achieved in 90 lesions

(93.7%) and procedural success was achieved in 88 lesions (91.7%), and no severe complications occurred.¹¹ Fernandez et al.¹² reported 58 cases of balloon failure in patients treated with ELCA, with or without RA. Further, the procedural success rate was 91%, with four procedure-related complications (including two coronary perforations).¹² The noteworthy advantage is the ability of ELCA to be performed over the CTO guidewires. However, ELCA may not be effective in patients with severely calcified long lesions, which is an indication for RA. Pagnotta et al.¹³ reported that in resistant CTO lesions, RA can achieve a success rate of up to 95% without increasing the risk of coronary perforation. However, although RA is highly effective in terms of crossing different types of resistant lesions, recrossing the CTO with the RA guidewire can become extremely challenging because of the need to exchange the RA guidewire.^{14,15} The seesaw balloon-wire cutting technique is another option for treating balloon-uncrossable lesions and has demonstrated favorable technical success.¹⁶ Apart from efficacy and safety, cost-effectiveness is another factor that needs to be considered when evaluating a new technique. As listed in Table 4, although the BAM technique does not

Table 3. Comparisons between successful and unsuccessful BAM groups.

Variables	Successful BAM (n = 18)	Unsuccessful BAM (n = 6)	P value
Age, years	59.1 ± 9.8	68.2 ± 7.99	0.045
Male	14 (77.8)	2 (33.3)	0.129
Smoking	12 (66.7)	2 (33.3)	0.192
Hypertension	13 (72.2)	4 (66.7)	1.000
Diabetes	7 (38.9)	4 (66.7)	0.357
Prior MI	4 (22.2)	2 (33.3)	0.480
Prior PCI	3 (16.7)	2 (33.3)	0.568
Prior CABG	1 (5.6)	1 (16.7)	0.446
CTO target vessel			0.240
LAD	4 (22.2)	3 (50.0)	/
LCX	5 (27.8)	0 (0.0)	/
RCA	9 (50.0)	3 (50.0)	/
J-CTO score	1.94 ± 1.06	2.00 ± 0.63	0.971
PROGRESS CTO score	1.33 ± 1.03	1.50 ± 0.55	0.598
Calcification			0.041
None/mild	9 (50.0)	0 (0.0)	/
Moderate	7 (29.2)	3 (50.0)	/
Severe	2 (20.8)	3 (50.0)	/
Intravascular ultrasound	5 (27.8)	3 (50.0)	0.302
Size of guiding catheter			1.000
7 French	18 (100)	6 (100)	
6 French	0 (0.0)	0 (0.0)	
Antegrade access			1.000
Radial arteries	11 (61.1)	4 (67.0)	
Femoral arteries	7 (38.9)	2 (33.0)	
Fluoroscopy time, minutes	36.6 ± 17.1	38.0 ± 20.4	0.883
Radiation dose, mGy	1518 ± 941	1763 ± 932	0.507

Data are presented as mean ± standard deviation or n (%).

BAM, balloon-assisted microdissection; MI, myocardial infarction; PCI, percutaneous coronary intervention; CABG, coronary artery bypass grafting; CTO, chronic total occlusion, LAD, left anterior descending artery; LCX, left circumflex artery; RCA, right coronary artery; J-CTO score, Japanese Multicenter CTO Registry score; PROGRESS CTO score, Prospective Global Registry for the Study of Chronic Total Occlusion Intervention score.

provide the highest technical success rate, it is convenient, safe, and economic in treating balloon-uncrossable lesions. Thus, it should be considered as the first-line option when augmentation of guide support fails to facilitate balloon crossing.

The conventional BAM technique uses a balloon ranging in size from 1.2 to 1.5 mm. Although no specific data regarding the required burst pressure for rupturing the

balloon have been reported, it is understood that high pressure is required to induce intentional balloon rupture. Vo et al.⁴ considered the BAM technique to be safe because no complications were noted in 17 balloon-uncrossable CTO lesions. However, unintentional balloon rupture can reportedly lead to coronary dissection, perforation, balloon entrapment, and distal embolization during PCI.^{17,18} We used

Table 4. Comparisons of plaque modification techniques for balloon-uncrossable CTOs.

Techniques	Number of cases	Technical success rate	Coronary perforation	Additional wiring	Additional equipment	Approximate cost (RMB)*
BAM	17	47%	0%	None	None	2600
Seesaw balloon-wire cutting	17	81%	0%	Yes	None	3000
ELCA	58	91%	3.4%	None	Yes	35,000
Rotational atherectomy	45	95%	0%	Yes	Yes	13,000

*Cost in mainland China.

CTO, chronic total occlusion; BAM, balloon-assisted microdissection; ELCA, excimer laser coronary atherectomy.

small balloons in the present study, and most of the balloons ruptured at a relatively low pressure (12–14 atm), providing a safe option for treating balloon-uncrossable lesions.

Our study has several limitations. First, because of the small sample size, it is difficult to identify the predictors of technical success. Second, the Sapphire® II 1.0-mm balloon was not compared with other traditional BAM balloons. Third, IVUS data were available for only one-third of the patients. Finally, this was a retrospective study with small sample size; the conclusion of the study requires confirmation in a large prospective study.

In conclusion, BAM with the Sapphire® II 1.0-mm balloon may be considered effective and safe for patients with balloon-uncrossable CTO lesions. However, further study is required to verify this technique.

Authors' contributions

Conceptualization, Y.Y. and Y.Z.; methodology, Y.Y., X.Z., J.D., and Y.Z.; formal analysis, Y.Y., X.Z., and J.D.; investigation, Y.Y., X.Z., and J.D.; resources, Y.Y., X.Z., and J.D.; data curation, Y.Y., X.Z., and J.D.; writing—original draft preparation, Y.Y.; writing—review and editing, Y.Y., X.Z., J.D., and Y.Z.; supervision, Y.Z.; project administration, Y.Z. All authors have read and agreed to the published version of the manuscript.


Declaration of conflicting interest

The author(s) declared no potential conflicts of interest with respect to the research, authorship, and/or publication of this article.

Funding

The author(s) disclosed receipt of the following financial support for the research, authorship, and/or publication of this article: This research received no specific grant from any funding agency in the public, commercial, or not-for-profit sectors.

ORCID iD

Yong Zeng  <https://orcid.org/0000-0002-7846-963X>

References

1. Tajti P and Brilakis ES. Chronic total occlusion percutaneous coronary intervention: evidence and controversies. *J Am Heart Assoc* 2018; 7: e006732.
2. Dash D. Interventional management of “balloon-uncrossable” coronary chronic total occlusion: is there any way out? *Korean Circ J* 2018; 48: 277–286.
3. Karacsonyi J, Karmaliotis D, Alaswad K, et al. Prevalence, indications and management of balloon uncrossable chronic total occlusions: insights from a contemporary multicenter US registry. *Catheter Cardiovasc Interv* 2017; 90: 12–20.
4. Vo MN, Christopoulos G, Karmaliotis D, et al. Balloon-assisted microdissection

- “BAM” technique for balloon-uncrossable chronic total occlusions. *J Invasive Cardiol* 2016; 28: E37–E41.
5. Genereux P, Madhavan MV, Mintz GS, et al. Ischemic outcomes after coronary intervention of calcified vessels in acute coronary syndromes. Pooled analysis from the HORIZONS-AMI (Harmonizing Outcomes With Revascularization and Stents in Acute Myocardial Infarction) and ACUITY (Acute Catheterization and Urgent Intervention Triage Strategy) trials. *J Am Coll Cardiol* 2014; 63: 1845–1854.
 6. Mintz GS, Popma JJ, Pichard AD, et al. Patterns of calcification in coronary artery disease. A statistical analysis of intravascular ultrasound and coronary angiography in 1155 lesions. *Circulation* 1995; 91: 1959–1965.
 7. Morino Y, Kimura T, Hayashi Y, et al. In-hospital outcomes of contemporary percutaneous coronary intervention in patients with chronic total occlusion insights from the J-CTO Registry (Multicenter CTO Registry in Japan). *JACC Cardiovasc Interv* 2010; 3: 143–151.
 8. Christopoulos G, Kandzari DE, Yeh RW, et al. Development and validation of a novel scoring system for predicting technical success of chronic total occlusion percutaneous coronary interventions: the PROGRESS CTO (Prospective Global Registry for the Study of Chronic Total Occlusion Intervention) score. *JACC Cardiovasc Interv* 2016; 9: 1–9.
 9. Rafie IM, Uddin MM, Ossei-Gerning N, et al. Patients undergoing PCI from the femoral route by default radial operators are at high risk of vascular access-site complications. *EuroIntervention* 2014; 9: 1189–1194.
 10. Kovacic JC, Sharma AB, Roy S, et al. GuideLiner mother-and-child guide catheter extension: a simple adjunctive tool in PCI for balloon uncrossable chronic total occlusions. *J Interv Cardiol* 2013; 26: 343–350.
 11. Ambrosini V, Sorropago G, Laurenzano E, et al. Early outcome of high energy Laser (Excimer) facilitated coronary angioplasty ON hARD and complex calcified and balloOn-resistant coronary lesions: LEONARDO Study. *Cardiovasc Revasc Med* 2015; 16: 141–146.
 12. Fernandez JP, Hobson AR, McKenzie D, et al. Beyond the balloon: excimer coronary laser atherectomy used alone or in combination with rotational atherectomy in the treatment of chronic total occlusions, non-crossable and non-expandable coronary lesions. *EuroIntervention* 2013; 9: 243–250.
 13. Pagnotta P, Briguori C, Mango R, et al. Rotational atherectomy in resistant chronic total occlusions. *Catheter Cardiovasc Interv* 2010; 76: 366–371.
 14. De Belder AJ. Rotational atherectomy: re-emergence of an old technique. *Heart* 2018; 104: 440–448.
 15. Barbato E, Carrie D, Dardas P, et al. European expert consensus on rotational atherectomy. *EuroIntervention* 2015; 11: 30–36.
 16. Li Y, Li J, Sheng L, et al. “Seesaw balloon-wire cutting” technique as a novel approach to “balloon-uncrossable” chronic total occlusions. *J Invasive Cardiol* 2014; 26: 167–170.
 17. Alfonso F, Perez-Vizcayno MJ, Hernandez R, et al. Clinical and angiographic implications of balloon rupture during coronary stenting. *Am J Cardiol* 1997; 80: 1077–1080.
 18. Christopoulos G, Luna M and Brilakis ES. The clinical implications of balloon rupture during cardiovascular interventions. *J Invasive Cardiol* 2015; 27: E45–E50.