



## Case report

# Successful treatment for a patient with chronic thromboembolic pulmonary hypertension comorbid with essential thrombocythemia with the JAK2 V617F mutation by balloon pulmonary angioplasty

Tomohiro Yamaguchi, Yasuhiro Izumiya<sup>\*</sup>, Hiroya Hayashi, Yoshitaka Ichikawa, Hirotoishi Ishikawa, Atsushi Shibata, Takanori Yamazaki, Minoru Yoshiyama

Department of Cardiovascular Medicine, Osaka City University Graduate School of Medicine, Osaka, Japan



## ARTICLE INFO

## Keywords:

Chronic thromboembolic pulmonary hypertension  
Essential thrombocythemia  
Balloon pulmonary angioplasty

## ABSTRACT

A-71-year-old woman was diagnosed as chronic thromboembolic pulmonary hypertension (CTEPH) accompanied by essential thrombocythemia (ET) with JAK2 V617F mutation. Blood test showed remarkable increase of platelet counts ( $132.9 \times 10^4/\mu\text{L}$ ) and elevated plasma BNP level (125.1pg/mL). Right heart catheterization (RHC) revealed remarkably high mean pulmonary arterial pressure (mPAP) of 43 mmHg. We gave her riociguat of 7.5mg, oral anticoagulants, oxygen inhalation for CTEPH, and anagrelide for ET. We performed 4 sessions of balloon pulmonary angioplasty (BPA) in 9 months RHC revealed successful hemodynamic improvement (mPAP = 21 mmHg) after final BPA procedure without riociguat. At six month later after final BPA procedure, RHC showed steadily improvement of mPAP (21 mmHg) without riociguat and oxygen inhalation. She lives well without oxygen inhalation and PH targeted therapy. This is the first report of successful treatment for a patient with CTEPH comorbid with ET with JAK2 V617F mutation by BPA.

## 1. Introduction

Chronic thromboembolic pulmonary hypertension (CTEPH) is classified as Group 4 pulmonary hypertension (PH), and it is induced by multiple organized thrombi in the pulmonary arteries [1]. Pulmonary endarterectomy (PEA) is the gold standard of CTEPH treatment. However, balloon pulmonary angioplasty (BPA), which is the interventional treatment to dilate the stenotic or occlusive lesion comprised of organized thrombi in pulmonary artery by plain balloon catheter, is becoming popular as an effective treatment for CTEPH with thrombi in the distal pulmonary arteries or without eligibility for PEA [2,3].

Essential thrombocythemia (ET), which is caused by genetic mutation of hematopoietic stem cells, results in thrombogenesis and thromboembolic events in the artery and vein [4]. The prognosis of patients with ET and the JAK2 V617F mutation is significantly worse than that with other genetic mutations [5]. Venous thrombotic events appear to be more common in ET with the JAK2 V617F mutation, whereas arterial

thrombotic events are common in the overall ET population [6].

There have been case reports of patients with CTEPH comorbid with ET [7,8], but a specific therapeutic intervention has not been established. Moreover, to the best of our knowledge, there are few reports about the effectiveness of interventional therapies in CTEPH comorbid with ET of particular genetic mutation types.

## 2. Case report

A 71-year-old woman, who was diagnosed with ET and the JAK2 V617 mutation and treated by aspirin, was referred to our institution with dyspnea on exertion. She had a history of cerebral infarction 8 years before admission. Blood pressure was 131/71 mmHg and heart rate was regular at 81 bpm. Although the oxygen saturation was 90% at room air, it decreased to 79% by the 6-min walking test (6MWT). She had jugular vein distention, leg pitting edema, and a parasternal beat. A blood test showed a remarkable increase in platelet count ( $132.9 \times 10^4/$

**Abbreviations:** CTEPH, chronic thromboembolic pulmonary hypertension; ET, essential thrombocythemia; BNP, Brain natriuretic peptide; RHC, right heart catheterization; mPAP, mean pulmonary arterial pressure; BPA, balloon pulmonary angioplasty; PH, pulmonary hypertension; PEA, pulmonary endarterectomy; 6MWT, 6-min walking test.

<sup>\*</sup> Corresponding author. Department of Cardiovascular Medicine, Osaka City University Graduate School of Medicine, 1-4-3 Asahimachi, Abeno-ku, Osaka, 545-8585, Japan.

E-mail address: [izumiya.yasuhiro@med.osaka-cu.ac.jp](mailto:izumiya.yasuhiro@med.osaka-cu.ac.jp) (Y. Izumiya).

<https://doi.org/10.1016/j.rmcr.2020.101235>

Received 4 September 2020; Received in revised form 18 September 2020; Accepted 23 September 2020

Available online 28 September 2020

2213-0071/© 2020 The Authors.

Published by Elsevier Ltd.

This is an open access article under the CC BY-NC-ND license

(<http://creativecommons.org/licenses/by-nc-nd/4.0/>).

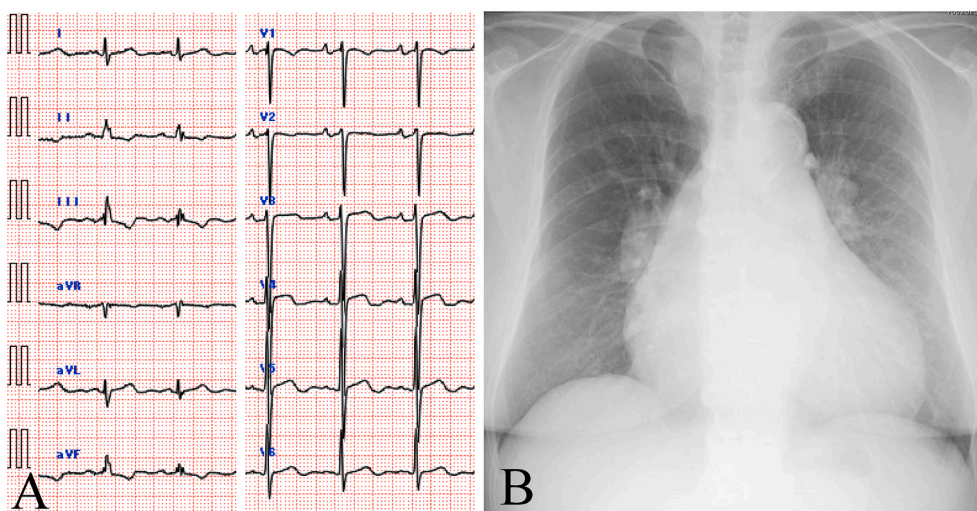


Fig. 1. A 12-lead resting electrocardiogram (A) and chest X-ray (B) on admission.

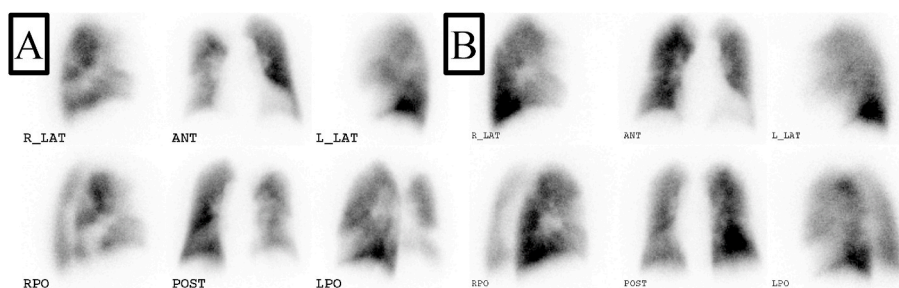


Fig. 2. Pulmonary perfusion scintigraphy on admission (A) and at 6 months after a final balloon pulmonary angioplasty (BPA) session (B).

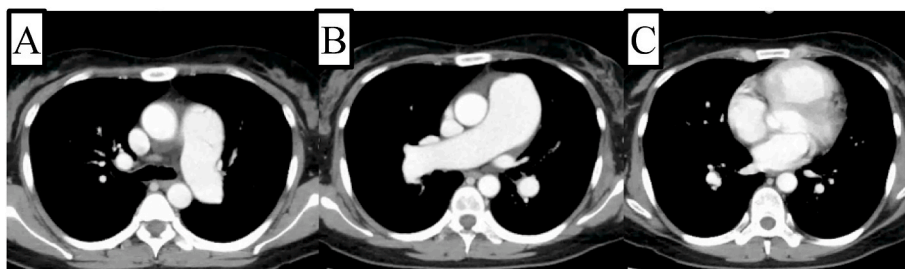


Fig. 3. Contrast enhanced computed tomography images on admission of upper field (A), middle field (B), and lower field (C).

$\mu\text{L}$ ) and an elevated plasma brain natriuretic peptide level (125.1 pg/mL). An electrocardiogram showed an inverted T wave in leads II, III, and aVF. A chest X-ray showed a markedly enlarged cardiac and pulmonary artery silhouette (Fig. 1). Transthoracic echocardiography showed severe PH (88 mmHg) as estimated by the tricuspid systolic pressure gradient, significant right atrial and ventricular dilation, and oppression of the left ventricle by the right ventricle. Pulmonary perfusion scintigraphy showed a severe segmental perfusion defect whereas we could not find the contrast defect suggesting the thrombus in the contrast enhanced computed tomography (Figs. 2 and 3). Right heart catheterization (RHC) showed a remarkably high mean pulmonary arterial pressure (mPAP) of 43 mmHg and high pulmonary vascular resistance of 7.4 WU (Table 1). Pulmonary angiography showed typical findings consistent with CTEPH (Fig. 4). The hematology team diagnosed her with ET because of a bone marrow biopsy and detected the JAK2 V617F mutation in peripheral blood. Her blood tests did not show any other coagulopathy, except for ET, and other types of PH, including

connective tissue disease. The other genetic mutations associated with PH or ET were not investigated. She was finally diagnosed with CTEPH comorbid with ET and prescribed oral anticoagulant (warfarin) and riociguat 7.5 mg/day. Additionally, we administered clopidogrel 75 mg considering the history of cerebral infarction due to ET. For treating ET, anagrelide administration reduced her platelet count to  $40 \times 10^4/\mu\text{L}$ . Although RHC showed slight improvement of mPAP (37 mmHg) after anticoagulation therapy for 3 months (Table 1), she still required oxygen inhalation because of remaining hypoxia. We performed four sessions of BPA in 9 months. The indication of BPA was decided by the heart team comprising interventional cardiologists and cardiovascular surgeons considering the patient's intension. Each BPA sessions were performed for all of the interventional pulmonary arteries of right or left lung alternately (we performed BPA to right A1,3,5,6,8,10 in first session, left 1,2,3,6,8,9 in second session, right A1,8,9,10 in third session, left A1,3,4, 8,9,10 in forth session), which were successfully done without any complications. Any unusual lesion findings including intravascular

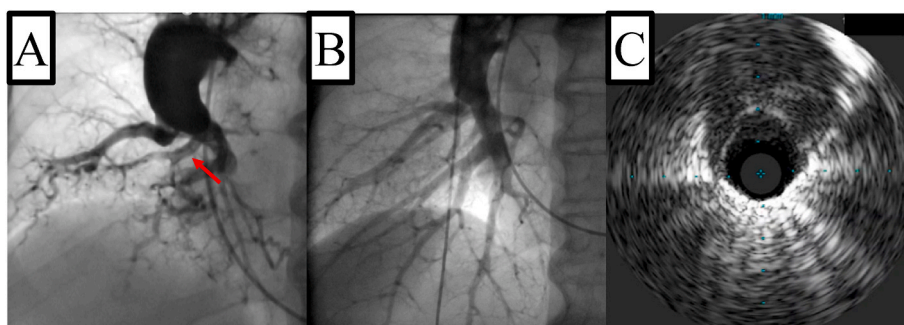
**Table 1**  
Hemodynamic parameters in right heart catheterization (RHC).

Variable	Baseline	Riociguat (7.5mg)	Final BPA <sup>a</sup>	Follow-up <sup>b</sup>
Pulmonary capillary wedge pressure (mmHg)	13	13	10	11
Pulmonary artery pressure (mmHg)	75/23/43	59/23/37	36/11/21	32/14/21
Right ventricular pressure (mmHg)	73/6	60/9	37/6	32/5
Right atrial pressure (mmHg)	1	5	1	2
Cardiac index (L/min/m <sup>2</sup> ) <sup>c</sup>	2.56/2.60	4.17	5.43	2.85
Pulmonary vascular resistance (wood units)	7.4	3.7	3.45	2.24

<sup>a</sup> RHC was performed immediately after final BPA procedure.

<sup>b</sup> At 6 months follow-up after final BPA.

<sup>c</sup> Cardiac index was calculated by thermodilution method.



**Fig. 4.** Pulmonary angiography (PAG) of the right lower lobe on admission (A) and PAG at 6 months of follow-up after the final BPA session (B). Intravascular ultrasounds image at right A9 (red arrow in (A)). (For interpretation of the references to colour in this figure legend, the reader is referred to the Web version of this article.)

ultrasounds images were not observed (Fig. 4). Oxygen inhalation and riociguat were stopped because of improvement of oxygenation on the 6MWT and hemodynamic parameters in RHC (mPAP = 21 mmHg after the final BPA procedure, Table 1). Six months after the final BPA procedure, RHC showed steady improvement of mPAP (21 mmHg) without riociguat and oxygen inhalation (Table 1). Her dyspnea was remarkably improved. She is currently well without oxygen inhalation and PH-targeted therapy, including riociguat.

### 3. Discussion

The prognosis of patients with CTEPH is remarkably improving because of progress in treatment strategies, including PEA, BPA, and PH-targeted medical therapies. While PEA is the gold standard of CTEPH treatment [2], it still has some clinical difficulties in patients with some comorbidities and frailty. Therefore, the treatment strategy is important for the patient's prognosis considering their background.

Although an increased number of PEA and BPA procedures have recently been performed worldwide, little is known about the prognosis after PEA and BPA in patients with CTEPH affected by ET. There is a high thrombotic event risk in patients with ET and the JAK2-V617F mutation [5]. Furthermore, patients affected by ET with the JAK2-V617F mutation have an increased rate of venous thrombosis, which is at an uncommon thrombotic site in patients with chronic myeloproliferative disorders [6]. Therefore, the rate of recurrent thrombotic events or the recurrent worsening rate after invasive CTEPH therapies is probably different in the ET population. A previous genetic study of CTEPH showed the characteristics of a patient accompanied by ET with JAK2 V617F variant who underwent PEA. Although the prognosis of the patient was not described in detail after PEA unfortunately, this description was maybe helpful considering the interventional treatment strategy in this rare situation [8]. Additionally, assessing the pathology of PH in patients with ET is difficult because arterial hypertension without thrombi (group 5) sometimes develops in patients with ET [1, 9]. Therefore, in patients with CTEPH accompanied by ET, there is a concern about the prognosis and careful observation is possibly

necessary after BPA treatment. In our case with the JAK2-V617F mutation, BPA procedures were successfully performed without worsening of PH in a short-term follow-up. Careful long-term follow-up is required in the future.

There have been few reports of invasive therapy, including PEA and BPA, in patients with CTEPH accompanied by ET. This is a novel report of successful treatment of a patient with CTEPH comorbid with ET with the JAK2 V617F mutation by BPA.

### Declaration of competing interest

None.

### Acknowledgments

We thank Dr. Matsubara H for assisting in treatment of this patient in the first and second BPA sessions. We thank Ellen Knapp, PhD, from Edanz Group ([www.edanzediting.com/ac](http://www.edanzediting.com/ac)) for editing a draft of this manuscript.

### References

- [1] G. Simonneau, M.A. Gatzoulis, I. Adatia, D. Celermajer, C. Denton, A. Ghofrani, et al., Updated clinical classification of pulmonary hypertension, *J. Am. Coll. Cardiol.* 62 (2013) D34–D38.
- [2] L. Irene, C.M. Bernhard, T. Ogo, H. Matsubara, K. Marcin, G. Hossein-Ardeschir, et al., Balloon pulmonary angioplasty in chronic thromboembolic pulmonary hypertension, *Eur. Respir. Rev.* 26 (2017) 160119.
- [3] Nazzareno Galiè, Marc Humbert, Jean-Luc Vachiery, Simon Gibbs, Irene Lang, Torbicki Adam, et al., 2015 ESC/ERS guidelines for the diagnosis and treatment of pulmonary hypertension: the joint task force for the diagnosis and treatment of pulmonary hypertension of the European society of cardiology (ESC) and the European respiratory society (ERS); endorsed by: association for European paediatric and congenital cardiology (AEPC), international society for heart and lung transplantation (ISHLT), *Eur. Heart J.* 37 (1) (2016) 67–119.
- [4] Y. Adir, D. Elia, S. Harari, Pulmonary hypertension in patients with chronic myeloproliferative disorders, *Eur. Respir. Rev.* 24 (137) (2015) 400–410.
- [5] T. Klampfl, H. Gisslinger, A.S. Harutyunyan, H. Nivarthi, E. Rumi, J.D. Milosevic, et al., Somatic mutations of calreticulin in myeloproliferative neoplasms, *N. Engl. J. Med.* 369 (25) (2013) 2379–2390.

- [6] P.J. Campbell, L.M. Scott, G. Buck, K. Wheatley, C.L. East, J.T. Marsden, et al., Definition of subtypes of essential thrombocythaemia and relation to polycythaemia vera based on JAK2 V617F mutation status: a prospective study, *Lancet* 366 (2005) 1945–1949.
- [7] N. Shishido, A. Inoue, H. Morishita, M. Kodama, K. Hasegawa, H. Ishihara, et al., A case of chronic thromboembolic pulmonary hypertension based on essential thrombocythemia, *Nihon Kogyoku Gakkai Zasshi* 40 (7) (2002) 574–578 (in Japanese).
- [8] A.E. Christina, V. Jeremias, H. Michael, B. Nicola, F. Christine, M. Eckhard, et al., Myeloproliferative diseases as possible risk factor for development of chronic thromboembolic pulmonary hypertension - a genetic study, *Int. J. Mol. Sci.* 21 (9) (2020) 3339.
- [9] P. Guilpain, D. Montani, G. Damaj, L. Achouh, F. Lefrère, J. Le Pavec, et al., Pulmonary hypertension associated with myeloproliferative disorders: a retrospective study of ten cases, *Respiration* 76 (3) (2008) 295–298.