



## Novel dilation technique and stent selection to reduce periprocedural adverse events in left hepaticogastrostomy

Mark Hanscom, MD, Stephen Anders, MD, Shahrad Hakimian, MD, Anwar Dudekala, MD, Prashanth Rau, MD, Anupam Singh, MD, Jaroslav Zivny, MD, Gustavo Churrango, MD, Kanishka Bhattacharya, MD, Christopher Marshall, MD, Neil B. Marya, MD

A 67-year-old man presented to the emergency department with fatigue and laboratory value abnormalities concerning for biliary obstruction. His medical history was notable for unresectable pancreatic cancer complicated by malignant gastric outlet obstruction requiring a surgical laparoscopic gastrojejunostomy.

In the emergency department, the patient underwent a CT scan of the abdomen and pelvis, which revealed a markedly dilated common bile duct consistent with biliary obstruction (Fig. 1). The CT scan also demonstrated a large pancreatic head mass that was compressing the adjacent duodenum.

The gastroenterology service was consulted for further evaluation, and the patient underwent an upper endoscopy. During the upper endoscopy, extrinsic compression of the duodenum was confirmed, resulting in a complete obstruction through which a duodenoscope could not be passed to reach the ampulla. The decision was made to attempt biliary drainage via a choledochoduodenostomy. However, during the procedure, the common bile duct did not distend enough to facilitate a safe attempt at stent placement. The maximum diameter of the bile duct was measured at 12 to 13 mm during the attempt, whereas we prefer to reach a diameter of 20 mm before attempting choledochoduodenostomy; thus, the procedure was ultimately aborted (Fig. 2). The decision was then made to attempt biliary drainage via a left hepaticogastrostomy, which was thought to be the best next step given the inadequate duct dilation (Video 1, available online at [www.VideoGIE.org](http://www.VideoGIE.org)).

### PROCEDURE

At the start of the procedure, EUS revealed multiple markedly dilated intrahepatic ducts (IHDs). Fine-needle puncture was performed into an accessible left IHD, and contrast was injected to confirm positioning (Fig. 3). With positioning confirmed, a 0.018-inch guidewire (Boston Scientific, Marlborough, Mass, USA) was then passed into the IHD. Over the guidewire, a 3.5-mm angioplasty balloon (Boston Scientific) was advanced into the IHD, and dilation of the IHD was performed. During dilation, an IHD stricture was identified, which was also dilated

(Fig. 4). After dilation, an exchange catheter was used to assist in the exchange of the 0.018-inch guidewire for a 0.035-inch guidewire. With the 0.035-inch guidewire in place, a 4-mm balloon dilator was passed, which was then used to further dilate the hepaticogastrostomy tract to 4 mm (Fig. 5).

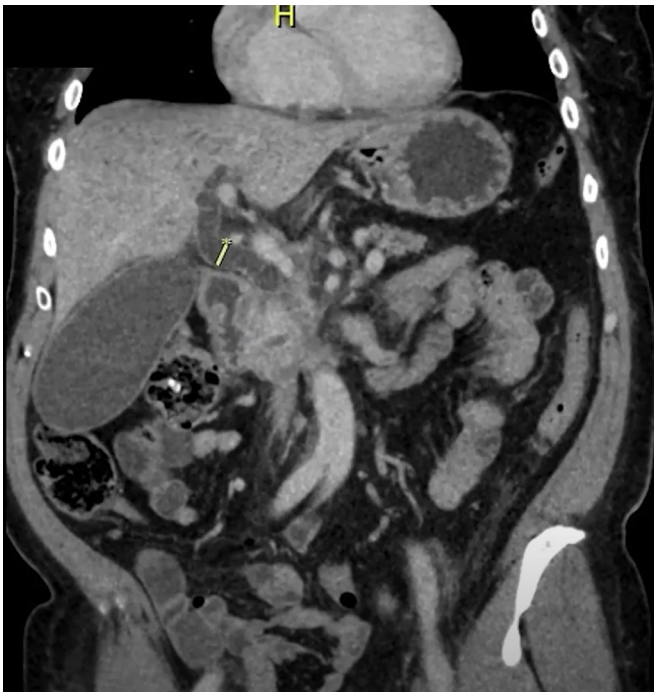
Once dilation was complete, the balloon dilator was removed, and an 8-mm × 6-cm fully covered self-expanding metal stent with 2 transmural drainage holes (Gore, Flagstaff, Ariz, USA) was advanced through the newly created hepaticogastrostomy tract and deployed. Because of concerns that the proximal stent was close against the gastric wall, a second coaxial stent was placed inside the original stent to secure positioning (Fig. 6).

### OUTCOME AND DISCUSSION

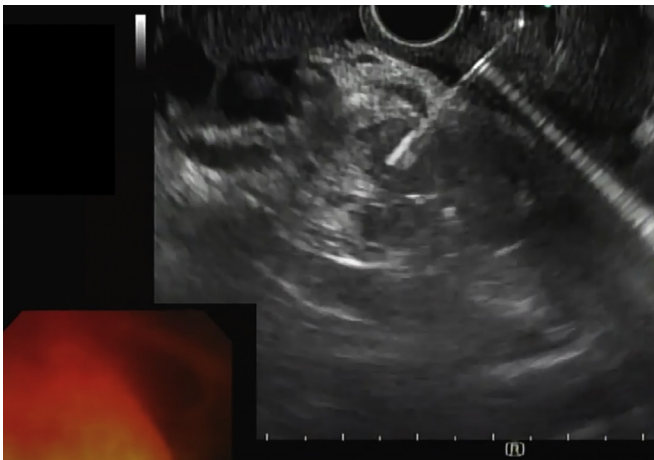
After our procedure, the patient returned to his hospital room for postprocedure care. The patient had a dramatic improvement in his bilirubin levels over the subsequent weeks, with a decrease in bilirubin from a peak of 7 mg/dL to a nadir of less than 1 mg/dL at 1 month postprocedure (Fig. 7). No other adverse events were encountered.

EUS-guided biliary drainage is a recent but evolving technique for bile duct drainage in cases of malignant obstruction that are not amenable to surgical or percutaneous intervention.<sup>1,2</sup> EUS-guided hepaticogastrostomy (EUS-LHG)—a specific technique within EUS-biliary drainage—has demonstrated both high technical and clinical success rates. However, it also involves not insignificant risks. Most of the periprocedural adverse events in EUS-LHG occur during tract predilation and include bile leak, bile peritonitis, and perforation.<sup>2,3</sup> Consequently, techniques and tools to facilitate predilation and successful stent placement are of great interest.

Previous reports have described various predilation techniques, including using graduated dilation catheters and a needle-knife.<sup>3</sup> For this procedure, we decided to adapt the use of an angioplasty balloon to perform the dilation itself and thus avoid the need for predilation altogether. A similar technique was first described by Hayat et al<sup>4</sup> in EUS-guided pancreaticogastrostomy. The tip of the angioplasty balloon is much smaller than

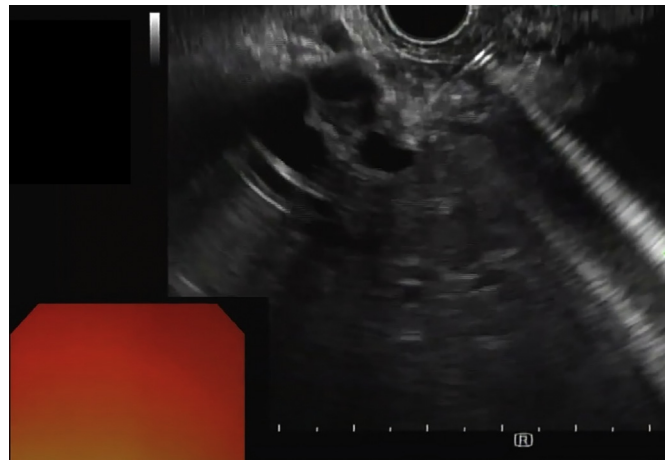


**Figure 1.** CT scan demonstrating marked common bile duct dilation (*arrow*). There is an adjacent pancreatic head mass at the distal end of the common bile duct.

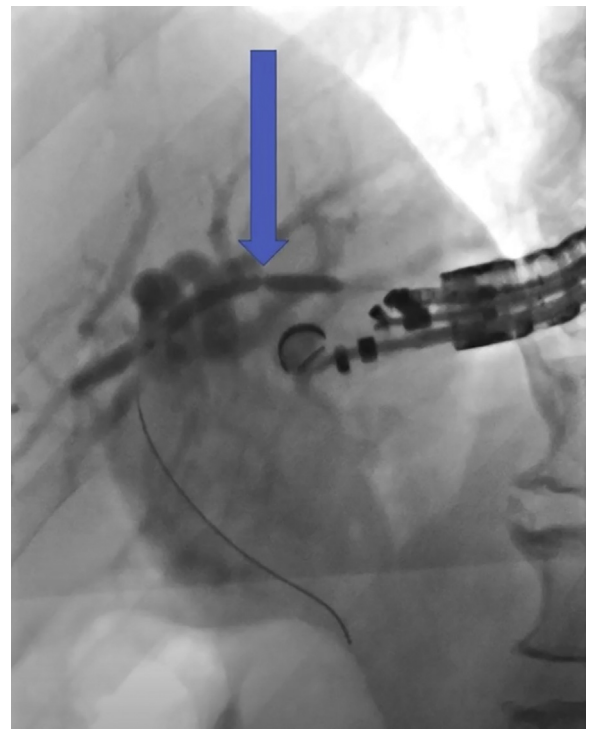


**Figure 2.** EUS image of the common bile duct obtained during an attempt at choledochoduodenostomy. A 19-gauge needle is seen entering and instilling contrast into the common bile duct, which did not distend enough to facilitate stent placement.

traditional balloon dilators, and provided that the caliber of a 19-gauge needle is 0.040 inches, no predilation is required to accommodate an angioplasty balloon. This allows the slim profile of the angioplasty balloon to pass into the IHD, where it can then be used to evaluate for and treat intrahepatic strictures that might complicate future stent placement without the need to first commit to dilation of the hepaticogastrostomy tract itself. There have been some reports of use of the 4-mm standard



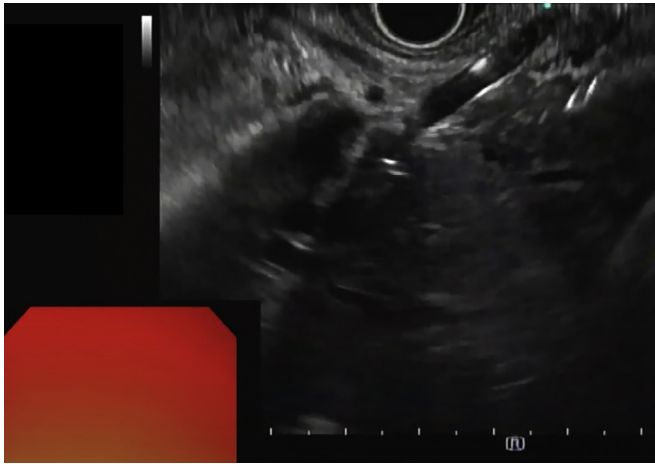
**Figure 3.** EUS image of a markedly dilated intrahepatic duct. A 19-gauge needle is seen entering into the left intrahepatic ducts during fine-needle puncture.



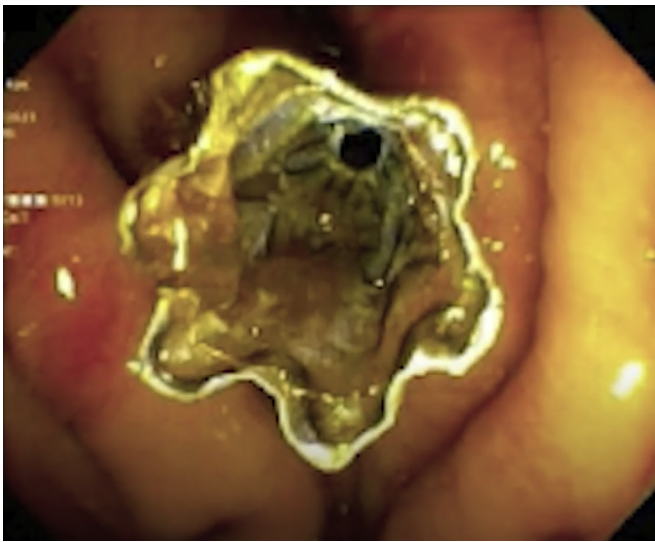
**Figure 4.** Fluoroscopic image of the 3.5-mm angioplasty balloon being used to dilate an intrahepatic duct stricture (*arrow*). The balloon was passed over a 0.018-inch guidewire and allowed for stricture dilation without the need for tract predilation.

balloon dilator without predilation as well; however, in our experience with this technique and with cystgastrostomy, difficulties can arise in attempting to pass the larger profile of a traditional balloon dilator through the gastric wall.

Likewise, stent selection is critical in optimizing against adverse events. For this procedure, we decided to use a fully covered self-expanding metal stent with transmural



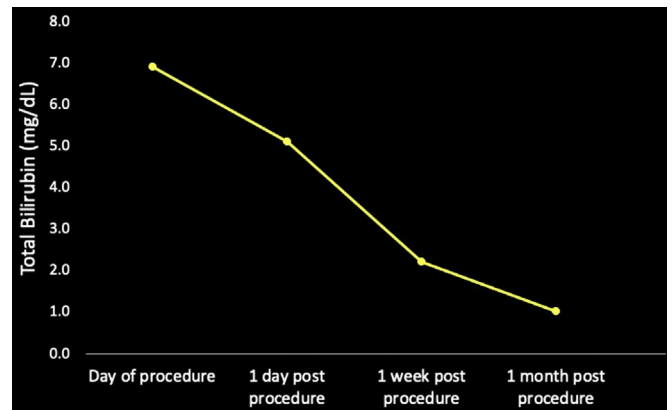
**Figure 5.** EUS image of balloon dilation of the left hepaticogastrostomy tract to 4 mm. Immediately prior, the tract was dilated to 3.5 mm using an adapted angioplasty balloon.




**Figure 6.** Endoscopic image of the covered metal stent with transmurial drainage holes after deployment and creation of the left hepaticogastrostomy.

drainage holes. The stent comprises a covered portion with transmurial drainage holes to facilitate bile drainage and antimigration fins to reduce stent migration, as well as a covered portion to reduce the risk of bile leak and peritonitis (Figs. 8 and 9). Although we deployed an additional coaxial stent to secure positioning, a more distal deployment of the gastric end of the stent would likely also be successful without the need for additional stent placement.

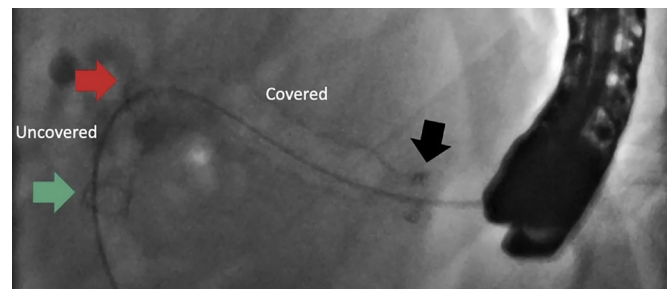
Our case is instructive in demonstrating the utility of small-caliber devices (eg, a 0.018-inch guidewire and angioplasty balloon) for the endoscopic creation of left hepaticogastrostomy. This technique may reduce periprocedural adverse events associated with LHG that often result



**Figure 7.** Bilirubin trend after creation of the EUS-left hepaticogastrostomy.



**Figure 8.** The covered self-expanding metal stent with transmurial drainage holes comprises both a covered portion with drainage holes (right) with antimigration fins, as well as a fully covered portion (left) to reduce bile leak.



**Figure 9.** Fluoroscopic image of the stent in place after successful creation of the EUS-left hepaticogastrostomy. The portion with transmurial drainage holes (left) can be clearly demarcated from the covered portion (right).

from the predilation step, which often requires the use of cautery or a step-up dilator. In addition, the angioplasty balloon was well suited for managing a tight IHD stricture, which otherwise might have disrupted stent placement. The use of a covered metal stent with transmurial drainage holes simultaneously minimizes the risk of bile peritonitis and occlusion of branches of the biliary tree.

## DISCLOSURE

*Dr Marya is a consultant for Boston Scientific. All other authors disclosed no financial relationships.*

Abbreviation: IHD, intrabepatic ducts; LHG, left hepaticogastrostomy.

a novel cross-platform technique with small-caliber devices. *Endosc Int Open* 2020;8:E196-202.

## REFERENCES

1. Ogura T, Higuchi K. Endoscopic ultrasound-guided hepaticogastrostomy: technical review and tips to prevent adverse events. *Gut Liver* 2021;15:196-205.
2. Paik WH, Park DH. Outcomes and limitations: EUS-guided hepaticogastrostomy. *Endosc Ultrasound* 2019;8:S44-9.
3. Park DH, Jang JW, Lee SS, et al. EUS-guided biliary drainage with trans-luminal stenting after failed ERCP: predictors of adverse events and long-term results. *Gastrointest Endosc* 2011;74:1276-84.
4. Hayat U, Freeman ML, Trikudanathan G, et al. Endoscopic ultrasound-guided pancreatic duct intervention and pancreaticogastrostomy using

Division of Gastroenterology, University of Massachusetts Medical School, Worcester, Massachusetts.

If you would like to chat with an author of this article, you may contact Dr. Marya at [neil.marya@umassmed.edu](mailto:neil.marya@umassmed.edu).

Copyright © 2021 American Society for Gastrointestinal Endoscopy. Published by Elsevier Inc. This is an open access article under the CC BY-NC-ND license (<http://creativecommons.org/licenses/by-nc-nd/4.0/>).

<https://doi.org/10.1016/j.vgje.2021.06.010>

### Submit to *VideoGIE*

*VideoGIE* is now indexed in PubMed Central.

*VideoGIE* is an Open Access, online-only journal indexed in PubMed Central. Submit video cases of endoscopic procedures used in the study, diagnosis, and treatment of digestive diseases.

*VideoGIE* publishes the following article types:

- **Case Reports:** Reports of the diagnosis and management of digestive diseases using a single case.
- **Case Series:** Reports of the diagnosis and management of digestive diseases using 3 or more cases.
- **Tools and Techniques:** Educational videos demonstrating the use of a particular endoscopic tool or technique. The goal of this section is to help trainees, endoscopy nurses, and technicians learn how best to use the tools of endoscopy for high-quality care.

All manuscripts must be submitted online at <http://www.editorialmanager.com/vgje>