

Epicardial and Perivascular Adipose Tissues and Their Influence on Cardiovascular Disease: Basic Mechanisms and Clinical Associations

Timothy P. Fitzgibbons, MD, PhD; Michael P. Czech, PhD

It is well established that the cardiovascular (CV) risk of obesity is more strongly associated with visceral rather than subcutaneous adiposity.^{1–3} Anthropometric variables that account for visceral adiposity, such as body mass index (BMI) and waist circumference (WC), have limited sensitivity and specificity. Furthermore, there is increasing recognition of “normal weight obese” persons (ie, those with increased visceral adipose but normal WC) who are prone to the same risk of the metabolic syndrome.⁴ These patients are detected only through abdominal computed tomography (CT) or magnetic resonance imaging (MRI). Rapid advancements in non-invasive cardiac imaging techniques have fostered interest in the imaging of perivascular and epicardial fat as proxy measures of visceral adiposity and, hence, more sensitive and specific indicators of cardiometabolic risk.^{5,6} The idea that these fat depots may not only be representative of abdominal visceral adipose tissue (VAT) but perhaps independently causal of CV disease (CVD) is an attractive one that is rapidly gaining traction. The potential roles of perivascular and epicardial fat in obesity-associated CVD are best understood in the context of the pathophysiology of obesity-induced insulin resistance.

Basic Mechanisms

“Immunometabolism”: Inflammation of VAT and the Development of Insulin Resistance

The idea that obesity is associated with a chronic inflammatory response in visceral fat dates to seminal articles

published almost 20 years ago.^{7–9} These studies showed that tumor necrosis factor (TNF)- α levels were increased in the adipose tissue of obese humans and mice and demonstrated infiltration of macrophages into the VAT of obese mice.^{7–9} Chronic caloric excess in the face of reduced energy expenditure causes increased visceral fat mass, due to hypertrophy of individual adipocytes and hyperplasia of adipocyte precursors. Increased adipocyte size results in the release of chemotactic factors such as monocyte chemoattractant protein-1 (MCP-1), which initiate the migration of monocytes into VAT and promote their differentiation into macrophages.¹⁰ The trigger for the initiation of blood monocyte chemotaxis into VAT is multifactorial; adipocyte apoptosis, increased lipolysis and local free fatty acids, reactive oxygen species (ROS), and/or tissue hypoxia may also play a role.¹¹ The differentiation of infiltrated monocytes into proinflammatory macrophages (M1 or “classically activated”) results in the local production of cytokines such as interleukin (IL)-1 β , TNF- α , and IL-6. TNF- α production by macrophages directly inhibits insulin signaling in adipocytes, causing decreased glucose transport, decreased free fatty acid uptake and reesterification, and increased lipolysis.¹² Based on these considerations, the resultant failure of VAT to store triglyceride could result in the ectopic accumulation of toxic fatty acids species (eg, diacylglycerol, ceramide) in skeletal muscle, liver, pancreas, and myocardium, which contribute to end-organ and ultimately systemic insulin resistance.¹² In particular, the proximity of inflamed VAT to the portal circulation allows released fatty acids and cytokines to directly affect the liver and are thought to contribute to hepatic insulin resistance and hepatic steatosis.¹³ Interestingly, some have suggested that epicardial adipose tissue (EAT) may play a similarly important role in myocardial steatosis, due to its anatomic proximity and absence of a dividing fascial plane.¹⁴

Aspects of this long-standing paradigm, which is the foundation for the burgeoning field of “immunometabolism,” have recently been challenged. First, increased plasma concentrations of free fatty acids do not always result in insulin resistance.¹⁵ Second, in some instances, for example negative caloric balance (ie, fasting), macrophage infiltration

From the Division of Cardiovascular Medicine (T.P.F.) and Program in Molecular Medicine (M.P.C.), University of Massachusetts Medical School, Worcester, MA.

Correspondence to: Timothy P. Fitzgibbons, MD, PhD, Division of Cardiovascular Medicine, University of Massachusetts Medical School, 55 Lake Avenue North, Worcester, MA 01655. E-mail: timothy.fitzgibbons@umassmemorial.org

J Am Heart Assoc. 2014;3:e000582 doi: 10.1161/JAHA.113.000582.

© 2014 The Authors. Published on behalf of the American Heart Association, Inc., by Wiley Blackwell. This is an open access article under the terms of the Creative Commons Attribution-NonCommercial License, which permits use, distribution and reproduction in any medium, provided the original work is properly cited and is not used for commercial purposes.

into VAT is protective.¹⁶ Finally, not only the monocyte/macrophage, but virtually every type of immune cell, has been implicated in the orchestration of a broad inflammatory response in VAT in response to high-fat feeding.^{17–21} However, that activated peripheral blood monocytes play an essential and perhaps primary role is evidenced by the fact that specific depletion of Cd11c⁺ macrophages in a diet-induced obesity model ameliorates insulin resistance.²²

Beneficial Effects of Perivascular Adipose Tissue and EAT

It should be emphasized that perivascular and epicardial fat are normally present in humans and other mammals. However, in obesity, the size of these fat depots is increased, commensurate with increases in visceral fat. Therefore, this is not “ectopic fat” per se but rather hypertrophy of a normal anatomic structure. EAT predominantly functions as perivascular adipose tissue (PVAT) for the coronary arteries, following their course, and being concentrated in the acute marginal, atrio-ventricular, and interventricular sulci²³ (Figure 1). With the exception of the lateral wall of the right and the anterior wall of the left, the walls of the ventricles are free of epicardial fat.²³ EAT displays high rates of both lipogenesis and lipolysis and has been proposed to serve as local fat storage depot, storing excess free fatty acids as triglyceride at times of excess and releasing them to the heart for substrate in times of metabolic stress.³⁴ In addition to surrounding the coronary arteries, PVAT surrounds large (aorta), medium-size (mesenteric), and small arteries (gluteal), and its function likely differs in each of these anatomic contexts (Figure 1). In this review, we use the term “PVAT” broadly, understanding that different functions may be common to different vascular beds.

In lean humans and rodents, PVAT has been shown to express and secrete many putatively beneficial adipokines, of which adiponectin (ADIPOQ) appears to be the most prominent^{32,35–38} (Table 1). In lean humans, PVAT-derived ADIPOQ has vasodilatory properties on small arteries from gluteal fat.³² This anticontractile function is lost in obesity, due to decreased PVAT ADIPOQ and increased TNF- α concentrations.³² After gastric bypass and a mean reduction in BMI from 51.5 to 37.9 kg/m², the anticontractile effect of PVAT was restored, in conjunction with an increase in PVAT ADIPOQ concentrations.³⁵ In both instances, this anticontractile effect was abrogated by preincubation with anti-AdipoR1 antibodies or removal of PVAT.^{32,35} ADIPOQ also modulates endothelium-dependent vasodilation. A recent study using PVAT from human saphenous vein grafts and internal mammary arteries showed that PVAT-derived ADIPOQ stimulates local endothelial nitric oxide synthetase (eNOS/NOS3) function via 2

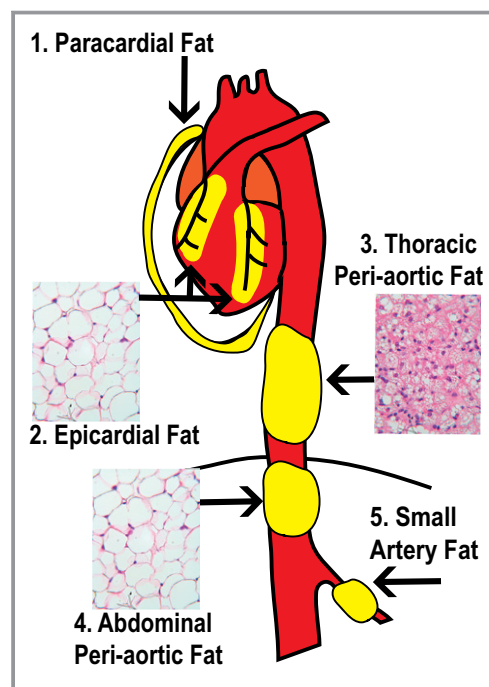


Figure 1. Anatomy and nomenclature of commonly studied perivascular adipose depots. (1) Paracardial adipose tissue (PAT) is the fat that surrounds the parietal pericardium; it is also referred to as “mediastinal fat” or “thoracic” fat. Recent human data suggest that this fat may be “beige” in morphology—that is, having features of both white and brown adipose tissue.²⁴ Measurement of paracardial fat volume is often used in imaging studies and may or may not be specifically differentiated from the underlying epicardial fat. (2) Epicardial adipose tissue (EAT) is encased by the visceral pericardium, lying directly adjacent to the myocardium and surrounding the coronary arteries. Here, it is shown surrounding the right coronary artery (RCA) and left anterior descending coronary artery (LAD). Human EAT is morphologically similar to white adipose tissue.²⁵ Pericardial fat has been defined as the combination of *paracardial* and *epicardial* fat.²⁶ (3) Thoracic periaortic fat surrounds the thoracic aorta in humans and rodents. In rodents, it is morphologically and functionally identical to brown adipose tissue; whether this is the case in humans remains unknown.^{27–30} (4) Abdominal periaortic fat surrounds the abdominal aorta and has features of white adipose tissue in rodents and humans.^{29,31} (5) Small artery fat, or that surrounding the mesenteric arteries and smaller arteries, usually has features of white adipose. Fat surrounding small arteries (ie, resistance vessels) may play a role in regulating vascular tone and flow of metabolites/nutrients, as originally proposed by Yudkin.^{32,33}

mechanisms: stimulation of AKT-dependent phosphorylation and increased tetrahydrobiopterin (BH₄) synthesis³⁸ (Figure 2).

ADIPOQ also has potent anti-inflammatory effects in multiple cell types.⁴⁴ For example, it suppresses adipocyte production of TNF- α and C-reactive protein.⁴⁴ Adipoq^{-/-} mice have increased expression of endothelial cell adhesion molecules and greater inflammation in mesenteric fat.⁴⁵ ADIPOQ suppresses activation of nuclear factor κ -light-chain-enhancer of activated B cells in endothelial cells via both

Table 1. Vasculoprotective Factors Released From EAT and/or PVAT in Human and Animal Studies

Factor	Effects
Adiponectin	<ul style="list-style-type: none"> ● Endothelium-independent vasodilation^{32,35} ● Inhibition of vascular smooth muscle proliferation in vivo and in vitro via an AMPK-dependent pathway³⁶ ● Prevents monocyte adhesion to HAECs³⁷ ● Activation of local eNOS function by stimulatory phosphorylation and increased BH₄ production³⁸
Leptin	<ul style="list-style-type: none"> ● Endothelium-dependent dilation of conduit arteries³⁹
Omentin-1	<ul style="list-style-type: none"> ● EAT and plasma levels of omentin are reduced in diabetic patients⁴⁰ ● Recombinant omentin prevented the inhibitory effects of CM-EAT-DM on contraction of ARVC and insulin-stimulated Akt-Ser473 phosphorylation⁴⁰
Nitric oxide	<ul style="list-style-type: none"> ● Endothelium-dependent vasodilation³²
PAME	<ul style="list-style-type: none"> ● Vasodilation via direct stimulation of VSMC potassium channels⁴¹
PGI ₂	<ul style="list-style-type: none"> ● PVAT-derived prostacyclin may inhibit endothelial dysfunction by impairing acetylcholine-induced vasoconstriction³⁰

EAT indicates epicardial adipose tissue; PVAT, perivascular adipose tissue; AMPK, adenosine monophosphate-activated protein kinase; HAEC, human aortic endothelial cell; eNOS, endothelial nitric oxide synthetase; BH₄, tetrahydrobiopterin; CM-EAT-DM, conditioned media from epicardial adipose of diabetic patients; ARVC, adult rat ventricular cardiomyocyte; PAME, palmitic acid methyl ester; VSMC, vascular smooth muscle cell; PGI₂, prostacyclin.

cyclic AMP-protein kinase A and AMP-regulated protein kinase pathways.⁴⁵ Finally, ADIPOQ suppresses IL-6, TNF- α , and scavenger receptor A expression in macrophages; while increasing expression of the anti-inflammatory cytokine IL-10.⁴⁴ Not only do the specific anti-inflammatory effects of ADIPOQ vary based on the cellular context, but they are also dependent on the concentration and molecular weight of the circulating hexamer (ie, low or high molecular weight).⁴⁵

Additional beneficial paracrine effects of PVAT-derived ADIPOQ in mice have been described.³⁶ In mouse femoral arteries, PVAT-derived ADIPOQ prevents neointimal hyperplasia in response to wire vessel injury.³⁶ This effect was shown to be due to AMP-regulated protein kinase-dependent inhibition of platelet-derived growth factor (PDGF)-stimulated smooth muscle cell growth (Figure 2). Thus, in both lean mice and humans, PVAT secretes ADIPOQ, which has at least 3 beneficial effects on the underlying vasculature: stimulation of endothelium-dependent and -independent vasodilation, inhibition of inflammation, and inhibition of growth factor-stimulated vascular smooth muscle cell (VSMC) growth.^{32,38}

Pathological Effects of Dysregulated Perivascular Adipocytes

Despite these putative beneficial effects, analogous to VAT, EAT is subject to the maladaptive adipocyte biology of

obesity, which is characterized by hypertrophy, failure to store triglyceride, increased lipolysis, and inflammation. In this setting, the beneficial paracrine effects of EAT (ie, ADIPOQ release, fatty acid uptake) are abrogated, and a causative role in local inflammation and CV pathophysiology may be assumed (Figure 2). There appears to be mechanisms in the PVAT of lean mice that restrain inflammation, such as the mammalian target of rapamycin complex 2 (mTORC2)⁴² (Figure 2). Not only does mTORC2 suppress inflammatory cytokine expression, but it also appears to suppress expression of inducible nitric oxide synthetase (iNOS/NOS2) by the adipocyte itself.⁴² Downregulation of mTORC2 signaling causes induction of adipocyte iNOS, leading to unregulated nitric oxide production and generation of ROS such as peroxynitrite (ONOO⁻), which directly cause vasoconstriction of vascular smooth muscle cells (Figure 2). This represents a provocative mechanism via which metabolic stress in adipocytes may simultaneously initiate inflammation and vasoconstriction.

Not only the degree but also the nature of local inflammatory responses influence the biology of EAT. In patients with advanced coronary artery disease (CAD), there is increased staining for CD11c⁺ cells in EAT, a marker of inflammatory (M1 or “classically activated”) macrophages.⁴⁶ In contrast, in patients without CAD, there is increased CD206⁺ staining, which is a marker of anti-inflammatory macrophage (M2 or “alternatively activated”) polarity.⁴⁶ The transition of resident macrophages from a resting anti-inflammatory (M2) state to an activated (M1) state may be a manifestation of lipotoxicity⁴⁷; how this might relate to the development plaque in adjacent coronary arteries is unknown.

In parallel to this inflammatory state in EAT, beneficial adipokine production is decreased in obesity. For example, ADIPOQ secretion from EAT is suppressed in patients with obesity and/or CAD.^{37,48} Interestingly, expression of ADIPOQ in EAT may or may not correlate with plasma concentrations, which are presumably derived from subcutaneous adipose tissue (SAT) and most often decreased in obesity.³⁸

The concept that adventitial inflammation might stimulate disease of the underlying vessel stems from initial studies of human abdominal aortic PVAT and EAT.^{31,49} PVAT from atherosclerotic abdominal aortas was found to secrete MCP-1 and IL-8 in concentrations equivalent to paired subcutaneous fat³¹ (Table 2). The functional significance of these factors was suggested by the ability of both subcutaneous fat and PVAT to stimulate leukocyte chemotaxis in transwell assays and the observation that CD68⁺ and CD3⁺ cells were present in PVAT.³¹ EAT from patients with CAD was found to have higher mRNA and protein levels of inflammatory cytokines (IL-1 β , IL-6, MCP-1, and TNF- α) than paired subcutaneous fat. Expression of these factors was associated with dense inflammatory infiltrates of macrophages,

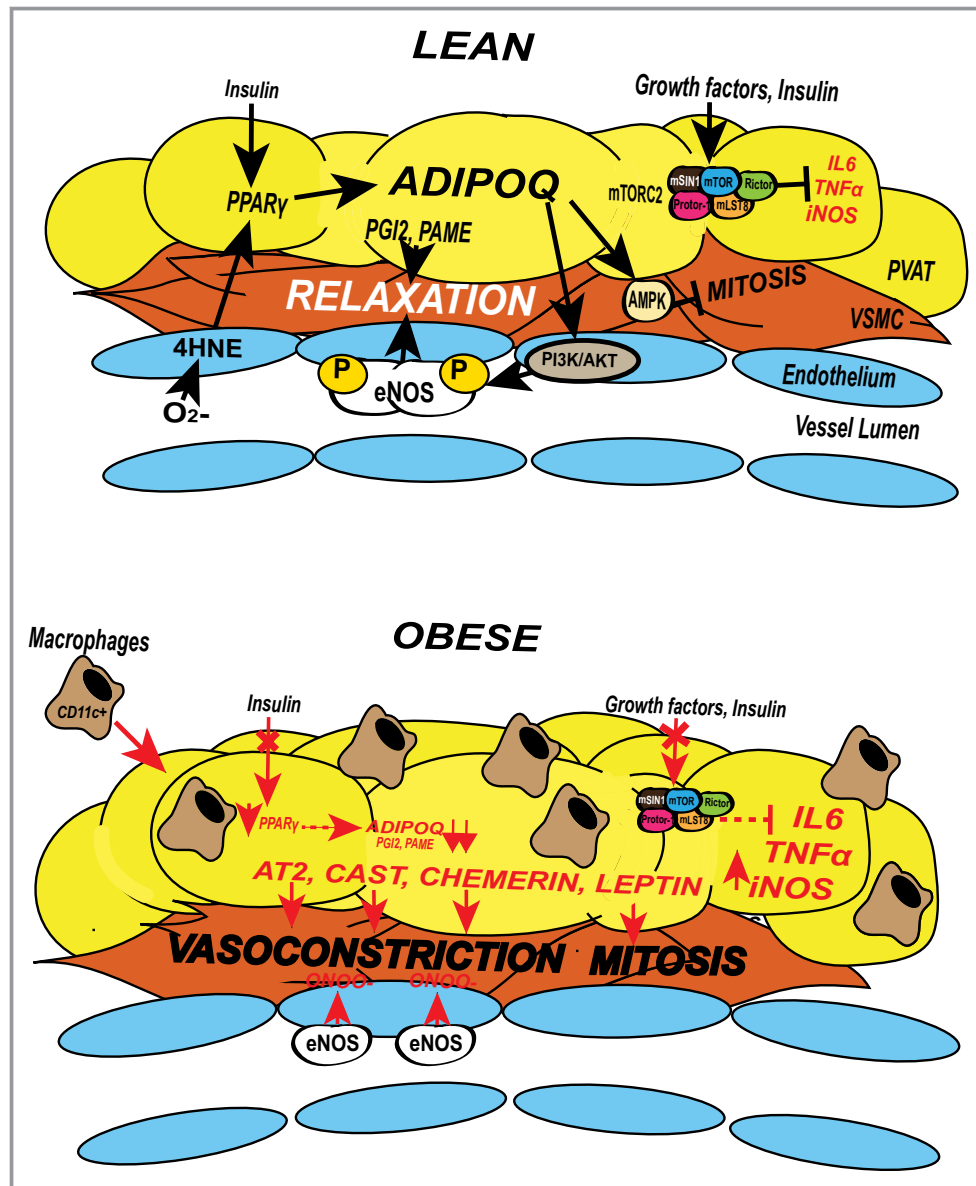


Figure 2. Signaling pathways that mediate the paracrine effects of PVAT. Adiponectin (ADIPOQ) has been shown to mediate many of the beneficial effects of PVAT. ADIPOQ is more highly expressed in lean conditions (top) than in obese conditions (bottom). ADIPOQ causes arterial vasodilation by promoting local eNOS activity in 2 ways: stimulation of AKT-dependent phosphorylation and subsequent increased eNOS coupling, and by increasing BH₄ cofactor availability.³⁸ ROS byproducts generated by dysfunctional endothelium (4HNE) feedback to activate PPAR_γ in adjacent PVAT, thereby stimulating transcription of ADIPOQ and other downstream adipogenic genes. ADIPOQ also promotes endothelium-independent vasodilation by activation of VSMC potassium channels (not shown). ADIPOQ released by healthy PVAT prevents neointimal hyperplasia by suppressing mitosis of VSMCs in an AMPK-dependent mechanism³⁶ (top). Lipids such as palmitic acid methyl ester (PAME) and prostacyclin (PGI₂) have also been shown to stimulate endothelium-independent vasodilation via direct activation of VSMC potassium channels and PGI₂ receptor activation (top).^{30,41} Finally, in PVAT from lean mice, unknown growth factor signals converge on mTORC2, resulting in Akt activation and inhibition of inflammatory cytokine production by adipocytes; loss of mTORC2 signaling in Rictor-deficient mice results in increased inflammation and increased vasoconstriction of underlying VSMC (top).⁴² In obesity, these pathways may be compromised, or new pathological mechanisms may emerge (bottom). Obesity stimulates inflammation and macrophage infiltration, which increases local cytokine and ROS production (bottom). The resultant impairment of insulin signaling contributes to a reduction in beneficial adipokine expression (ADIPOQ, PAME, PGI₂), uncoupling of eNOS, and increased expression of pathological vasoconstricting factors (angiotensin 2 [AT2], chemerin, and calpastatin).⁴³ PVAT from obese patients may also release factors that stimulate mitosis (eg, leptin, PDGF) of VSMCs by overwhelming local beneficial adipokine effects.^{36,41} AMPK indicates adenosine monophosphate kinase; BH₄, tetrahydrobiopterin; eNOS, endothelial nitric oxide synthetase; 4HNE, 4-hydroxynonenal; IL-6, interleukin 6; iNOS, inducible nitric oxide synthetase; mLS18, MTOR associated protein, LST8; mTORC2, mammalian target of rapamycin complex 2; ONOO⁻, peroxynitrite; PDGF, platelet-derived growth factor; PI3K/AKT, Phosphoinositide 3-kinase; PPAR_γ, peroxisome proliferator-activated receptor gamma; PVAT, perivascular adipose tissue; ROS, reactive oxygen species; TNF α , tumor necrosis factor alpha; VSMC, vascular smooth muscle cell.

Table 2. Pathological Factors Released From EAT and/or PVAT in Human and Animal Studies

Factor	Effect
Activin A	<ul style="list-style-type: none"> ● Increased fibrosis of rat atrial myocytes treated with conditioned media in vitro⁵⁰ ● Cardiodepressant effect on ARVCs in vitro by reducing expression of SERCA2a⁵¹
Angiopietin	<ul style="list-style-type: none"> ● Cardiodepressant effect on ARVCs in vitro by reducing expression of SERCA2a⁵¹
Angptl-2	<ul style="list-style-type: none"> ● Promotes adventitial inflammation in vivo⁵²
Angiotensin II	<ul style="list-style-type: none"> ● Increased vasoconstriction of aortic rings, blocked by incubation with ATIIR blocker⁴¹
Calpastatin/CAST	<ul style="list-style-type: none"> ● Protein is a partial agonist for intracellular domains of Ca_v1.2 ● Dose-dependently increases coronary arterial contractions like PVAT⁴³
Chemerin/ <i>RARRES2</i>	<ul style="list-style-type: none"> ● May directly stimulate vasoconstriction by binding to ChemR23, which is found on VSMCs⁵³
Complement component 3	<ul style="list-style-type: none"> ● Stimulates differentiation and migration of adventitial myofibroblasts⁵⁴
Leptin	<ul style="list-style-type: none"> ● Local leptin levels may promote neointima formation independently of obesity or inflammation⁵⁵
IL-6, MCP-1, PAI-1, GRO α , sICAM-1, sIL-6R, RANTES	<ul style="list-style-type: none"> ● Conditioned media from patients with CAD increased THP1 monocyte adhesion and migration in vitro^{31,37}
Resistin	<ul style="list-style-type: none"> ● Stimulates endothelial cell permeability in vitro⁵⁶
Secretory type II phospholipase A2	<ul style="list-style-type: none"> ● Promotes formation of inflammatory lipid mediators in EAT⁵⁷
TNF α	<ul style="list-style-type: none"> ● Loss of vasodilator effect of PVAT; likely due to downregulation of NOS by TNFα³²
VEGF	<ul style="list-style-type: none"> ● VEGF expression was increased in the VAT and EAT of diabetic patients and stimulated greater proliferation of VSMCs in vitro⁵⁸
Visfatin	<ul style="list-style-type: none"> ● Stimulation of vascular smooth muscle proliferation in vitro⁵⁹

EAT indicates epicardial adipose tissue; PVAT, perivascular adipose tissue; ARVC, adult rat ventricular cardiomyocyte; SERCA2, sarcoplasmic reticulum Ca²⁺ ATPase; ATIIR, angiotensin II receptor; CAST, ; ChemR23, Chemerin receptor 23; VSMC, vascular smooth muscle cell; IL-6, interleukin 6; MCP-1, monocyte chemoattractant protein-1; PAI-1, plasminogen activator inhibitor-1; GRO α , growth-regulated oncogene α ; sICAM-1, soluble intercellular adhesion molecule 1; sIL-6R, soluble IL-6 receptor; RANTES, Regulated on Activation, Normal T cell Expressed and Secreted; CAD, coronary artery disease; THP1, Human acute monocytic leukemia cell line; TNF α , tumor necrosis factor α ; NOS, nitric oxide synthase; VEGF, vascular endothelial growth factor; VAT, visceral adipose tissue.

T cells, and mast cells in EAT.⁴⁹ The authors concluded that EAT from patients with CAD is associated with increased inflammatory gene expression, which may affect the development or progression of atherosclerosis. Many subsequent studies have demonstrated increased expression of proinflammatory cytokines in EAT from patients with CAD.^{56,60–62} However, because a normal control group was not present in most studies, the degree to which inflammation was causative or reactive to local atherosclerotic lesions remains unknown.⁴⁹

Finally, it should be emphasized that PVAT is an intimate part of the adventitia that contains many different cell types (eg, adipocytes, endothelial cells, fibroblasts) with interrelated functions. Not only obesity, but other pathological conditions such as hypertension, or balloon inflation during percutaneous intervention, may initiate a response in PVAT. For example, among the most abundant proteins secreted by rodent PVAT is complement component 3 (C3).⁵⁴ C3 from PVAT-conditioned media stimulates adventitial fibroblast migration and differentiation via c-Jun N-terminal kinase activation.⁵⁴ This effect is increased in the deoxycorticosterone acetate–salt hypertensive rat and is thought to contribute to adventitial remodeling and increased vascular stiffness.

Brown Fat–Like Attributes in the Perivascular Niche

Adipose tissue in different anatomic locations, or even within the same depot, may differ with regard to its metabolic function. In general, adipose tissue can be thought of as belonging to 2 broad functional categories. White adipose tissue (WAT) consists of large unilocular adipocytes whose primary function is to store energy in the form of triglyceride. Brown adipose tissue (BAT) contains multilocular adipocytes with large numbers of mitochondria and is most commonly found in young mammals and rodents. Its primary function is to generate heat via uncoupled oxidative phosphorylation. A third type of adipocyte, termed the “brite” or “beige” adipocyte, is a brown adipocyte that arises within white adipose depots and also has thermogenic capacity.^{63,64} There is great interest within the metabolic field in activating the formation of BAT to facilitate expenditure of energy, promote weight loss, and prevent obesity and diabetes. This interest has been sparked by recent data that suggest, contrary to prior thought, that BAT is present in adult humans and correlates with leanness, age, female sex, and insulin sensitivity.^{65,66} These fascinating aspects of BAT are the topic of many recent excellent reviews.^{63,67,68}

Interestingly, mRNA expression of uncoupling protein-1 (UCP-1) is high in EAT in comparison to other fat depots, leading some to speculate that it may function as BAT to generate heat and protect the myocardium from hypothermia.⁶⁹ UCP-1 is also increased at the protein level, and there is increased expression of genes specific for beige adipocytes.²⁵ Despite the presence of UCP-1 protein and beige cell gene expression, histological studies showed that EAT contained unilocular cells, consistent with purely white adipocytes²⁵ (Figure 1). Fat adjacent to the subclavian artery, however, did show morphological features consistent with a beige cell origin (ie, round nuclei, multilocular lipid droplets).²⁵ In short, there is no definitive evidence to date that brown fat exists in the perivascular niche in humans. This may be due to the fact that in most cases, sampling of epicardial and perivascular fat is done when humans are older or already have established vascular disease, two instances in which one might not expect to find BAT.

In contrast, there are abundant data in rodents that demonstrates bona fide brown adipose surrounding the thoracic aorta.^{27–30} There is a dichotomy in the morphology of the aortic PVAT in rodents—that above the diaphragm being brown and that below being white (Figure 1). BAT, unlike WAT, tends to be resistant to high-fat diet-induced inflammation.²⁷ Therefore, the presence of brown PVAT may be protective, whereas WAT surrounding the abdominal aorta may lead to adventitial inflammation and promote abdominal aortic aneurysm formation in obese patients.²⁹

A major limitation to this field is that most studies demonstrate association but not causality. There have been recent elegant attempts to address this problem using removal or transplantation of fat to the perivascular space.^{36,55,70} These studies are prone to some methodological limitations. For example, only vessels that are easily accessed with surgical technique (ie, femoral, carotid) are available to study. Second, transplanted fat is usually VAT or SAT. The small amount of PVAT surrounding native rodent vessels is generally prohibitive to transplantation studies. Finally, the process of transplantation itself causes an inflammatory response in the transplanted fat pad that is artificial and unlikely to represent native physiology.⁷¹ Nonetheless, it does seem to recapitulate the inflammatory response of VAT to a high-fat diet and is, importantly, absent in transplanted SAT.⁷¹ Therefore, transplantation studies do offer important insight into the potential impact of PVAT on vascular physiology and disease.

In 2009, Takaoka et al³⁶ published the first of these studies using the femoral artery wire injury model. They established that normal PVAT has an important effect to prevent neointimal hyperplasia in response to vessel injury; femoral arteries stripped of PVAT had excessive neointimal hyperplasia.³⁶ Transplantation of normal SAT to the femoral

artery rescued this effect, whereas transplantation of VAT from high-fat diet-fed animals exaggerated it. The authors concluded that inhibition of neointimal hyperplasia was dependent on PVAT-derived ADIPOQ activation of AMP kinase in underlying vascular smooth muscle cells.³⁶ Others have used the same model to show that PVAT-derived leptin and angiotensin-related protein 2 (Anptl2), both of which are upregulated with obesity or aging, contribute to excessive neointimal hyperplasia in response to vessel injury.^{52,55} These studies have great clinical relevance for the study of diabetic and obese patients undergoing percutaneous coronary interventions.

Recently, Ohman et al⁷⁰ published a study in which they transplanted VAT to the common carotid artery of apolipoprotein E-deficient (ApoE^{-/-}) mice. This location is generally free of spontaneous atherosclerosis. Therefore, they hypothesized that transplantation of VAT to the carotid artery would incite atherosclerosis. They did indeed see a dramatic increase in complex atherosclerotic plaques in the underlying carotid artery. Before the development of atherosclerosis, they observed decreased vasodilator responses to acetylcholine in the transplanted arteries.⁷⁰ These effects were not observed with the transplantation of SAT and were associated with an increase in circulating MCP-1. Furthermore, they were abrogated in mice with whole body deficiency of P-selectin glycoprotein ligand-1 (Psgl-1) or with treatment with antibodies against Psgl-1.⁷⁰ It is still not understood whether Psgl-1 is acting on the intimal endothelium, or on endothelium within the adventitial vasa vasorum to initiate vascular disease. Limitations aside, these studies provide important proof of concept that PVAT can have both protective and pathological effects, and there is likely to be an increase in the use of these interesting experimental models.

Regarding the primary effect of PVAT on vascular disease, the most definitive study to date was recently published by Chang et al,³⁰ who describe a “PVAT-less” mouse. After generating a conditional knock-out of peroxisome proliferator-activated receptor- γ in vascular smooth muscle cells (SMPG-KO), the authors serendipitously found that these mice lacked PVAT. They went on to cross this mouse with ApoE^{-/-} mice to pose the question: Is PVAT protective against the development of atherosclerosis? In thermo-neutral conditions, there was no difference in aortic atherosclerosis between wild-type and SMPG-KO/ApoE^{-/-} mice.³⁰ However, the authors then exposed each strain of mice to the cold and noted a dramatic effect of cold conditions in limiting the extent of atherosclerosis in ApoE^{-/-} mice. This effect was lost in the mice without PVAT (SMPG-KO/ApoE^{-/-}). Among the putative factors responsible for this effect, the authors showed that PVAT-derived prostacyclin (1) decreased with age and (2) decreased with high-fat diet and atherosclerosis and that (3) blockade of the prostacyclin receptor prevented

PVAT-derived inhibition of acetylcholine-induced vasoconstriction.³⁰ The authors concluded that PVAT-derived prostacyclin prevented acetylcholine-induced endothelial dysfunction, which is a precursor to atherosclerosis (Figure 2). The fact that the production of prostacyclin was increased by active thermogenesis of PVAT suggests that there is an important role for BAT in the perivascular niche and supports the ongoing efforts to discover and promote such a depot in humans.

Summary of Basic Research

There is increasing evidence from studies in animals and humans that PVAT has beneficial effects on the vasculature under normal conditions and pathological effects under obese or diseased conditions (Figure 2). ADIPOQ is primary among the beneficial adipokines released from PVAT, signaling through smooth muscle AMP-regulated protein kinase to prevent proliferation and endothelial Akt to promote eNOS coupling and NOS generation. Beneficial paracrine mediators also include lipid species such as palmitic acid methyl ester and prostacyclin (Table 1). Obesity abrogates beneficial adipokine signaling, likely by stimulating inflammation of PVAT and increasing local cytokine production, thus inducing resistance to Akt and mTOR signaling. Resistance in these pathways results in eNOS uncoupling and increased local ROS production, smooth muscle cell proliferation, and increased smooth muscle cell tone by calcium-dependent mechanisms (Figure 2). This paracrine signaling may also function from the “inside out,” as local ROS may generate ligands (4HNE) for peroxisome proliferator-activated receptor- γ in perivascular adipocytes, which signal the need for increased vasodilatory ADIPOQ production (Figure 2).³⁸ Direct manipulation of these pathways via pharmacological and nonpharmacological methods is likely to be a very effective means to combat CVD associated with obesity and will be an increasingly popular topic of research in the future.

Clinical Studies That Associate PVAT or EAT and CV Risk

Anatomy, Imaging, and Normal Values

There is confusion in the literature in regard to the nomenclature of cardiac fat depots and the methods section of imaging studies should be read carefully to understand what specific depot has been measured.⁷² *Paracardial* fat is found on the external surface of the parietal pericardium and is also known as mediastinal or thoracic fat (Figure 1).⁷³ In contrast, *pericardial* adipose tissue (PAT) has been proposed to include the paracardial and epicardial fat together.²⁶ EAT lies beneath the visceral pericardium directly opposed to the surface of the

heart and encases the epicardial coronary arteries. EAT is the true visceral fat depot for the heart and shares the same developmental origin as mesenteric and omental fat, which are derived from the splanchnopleuric mesoderm.^{74,75} Paracardial fat, however, is derived from the primitive thoracic mesenchyme, which also gives rise to the parietal pericardium.⁷⁴ In keeping with these different developmental origins, EAT is supplied by branches of the coronary arteries, whereas paracardial fat is supplied by the pericardiophrenic artery.⁷⁴

There is growing interest in the imaging of EAT and PAT as a proxy measure of visceral adiposity. A second purpose of imaging EAT and PAT is to provide an incremental risk of incident CVD in addition to other risk factors. The repeated observation that EAT volumes correlate highly and directly with VAT volumes has strengthened interest in imaging for this purpose.^{5,26,76–79} Furthermore, recent data suggest that there are individuals with normal VAT volume but increased PVAT volume; these patients may represent a unique subset of the “normal weight” obese.⁸⁰ Finally, and perhaps the most promising indication, involves imaging of EAT to follow treatment (eg, weight loss intervention studies).⁸¹ Unfortunately, the vast majority of clinical studies are cross-sectional, and basic or translational studies are correlative, providing no information regarding causation. This is due primarily to 3 factors: mice do not have epicardial fat, depot-specific adipose tissue knockouts have only recently been developed, and normal human subjects are usually absent in molecular studies.^{30,82} For purposes of CV risk stratification, measurement of EAT thickness using echocardiography has generally been the study of choice, due to its lesser cost, ease of use, and absence of radiation. CT has the advantage of simultaneous determination of coronary calcium, however, it is difficult to differentiate between epicardial and pericardial fat on CT.⁸³ MRI provides the most specific and precise measurements of epicardial fat volume. Unlike CT and MRI, there is some consensus regarding the method of measurement and normal values by 2-dimensional echocardiography. Epicardial fat thickness on the lateral wall of the right ventricle should be measured in the right parasternal long-axis view, perpendicular to the aortic annulus.⁶ The EAT thickness extends from the outer wall of the right ventricle to the visceral layer of pericardium and is generally echo free. Mindful of the limitations of this measurement, a normal value is <7 mm.^{6,84} Certainly, estimations of EAT volume by using MRI or CT will more accurately and precisely measure total fat mass, as will emerging 3-dimensional echocardiographic techniques. In addition to the quantity of adipose tissue, measurement of CT attenuation allows for the “quality” of fat to be imaged.⁸⁵ Lower CT attenuation (more negative Hounsfield units) is thought to represent increased lipid content and possibly greater metabolic risk. Recent data from the Framingham Heart Study showed that lower CT

attenuation is associated with an increased risk of insulin resistance and metabolic syndrome, after controlling for VAT volume.⁸⁵ In the following sections, we will review the evidence for imaging of EAT and PAT for the estimation of global CV risk and prognosis in CAD and atrial fibrillation (AF).

Global CV Risk and CAD

For the purposes of cardiometabolic risk, there is no question that EAT volume is highly and directly correlated with VAT^{5,26,76–79} (Table 3). As a proxy measurement of VAT, which is not available without using CT or MRI, measurement of EAT thickness has inherent value over imprecise anthropometric estimations such as BMI or WC. However, the evidence to date does not suggest that increased EAT volume imparts additive risk when VAT mass is accounted for.

For example, in a cross-sectional CT study of 1155 Framingham Heart Study patients, PAT was highly correlated with VAT and components of the metabolic syndrome such as high triglyceride, low HDL cholesterol, and hypertension.⁹² Yet, these correlations did not persist after adjustment for VAT, and VAT showed the strongest independent correlation.⁹²

EAT thickness or PAT volume has subsequently been associated with multiple independent cardiac risk factors, such as fasting glucose, C-reactive protein, low HDL, carotid intima-media thickness, and others (Table 3).^{76,86,92} However, when adjusted for VAT, many of these associations are diminished or absent. Perhaps the most definitive study to date was recent prospective study published by the Framingham Heart Study, in which 3000 patients free of CVD had PAT, thoracic aortic PVAT, and VAT measured at baseline and were followed for a median of 5 years to determine incident CV death, cancer, and all-cause mortality.⁹¹ After multivariate adjustment, VAT, but not thoracic PVAT or PAT, was associated with incident CVD and cancer. There was no discriminatory power for all-cause mortality.⁹¹

Interestingly, a consistent finding in many of these studies is the association of coronary artery calcification with PAT volume, even after adjustment for VAT.^{83,93} Therefore, even though many of the systemic determinants of CV risk associated with EAT are actually mediated by VAT, EAT and/or PAT may have local effects that promote vascular calcification or atherosclerosis.^{83,93} One might speculate that alterations in PVAT surrounding the thoracic aorta influence the vascular stiffening or calcification that is associated with aging.

Cross-sectional studies have shown an association between prevalent CAD and PAT volume by CT and/or EAT thickness by using echocardiography^{83,88,92} (Table 4). Fewer studies have correlated EAT with incident CAD. A recent study

compared EAT volume in patients who developed incidental coronary calcium on a subsequent CT within 3 to 5 years.⁹⁰ EAT volume was compared at baseline and follow-up in cases and controls. There was no difference in the change in EAT volume indexed to body surface area between these 2 groups ($4.9 \pm 8.9 \text{ cm}^3$ versus $4.2 \pm 8.0 \text{ cm}^3$, $P=0.67$) at follow-up.⁹⁰ The authors concluded that in low-risk patients (coronary calcium score of 0), EAT volume at baseline and increase over 3 to 5 years was not related to incident CAD.⁹⁰ The same group performed a second study in 375 intermediate-risk patients. Patients were divided into tertiles of coronary calcium progression between the performance of 2 CT scans 3 to 5 years apart, and low progressors were compared with high progressors.⁹⁸ Although there were no differences at baseline, at follow-up, high progressors had a greater volume of EAT than low progressors ($102 \pm 38 \text{ cm}^3$ versus $90 \pm 35 \text{ cm}^3$, $P=0.03$).⁹⁸ In contrast to low-risk patients, EAT may influence the progression of CAD in intermediate-risk patients.⁹⁸ Finally, a recent case-control study reported that increased EAT volume was associated with greater major adverse cardiac events within 4 years.⁸⁷ After having a noncontrast CT scan, 2751 asymptomatic patients without known CAD were followed for 4 years. After adjustment for the Framingham Risk Score, coronary calcium score, and BMI, PAT volume was associated with an OR of 1.74 (95% CI 1.0 to 2.95 for each doubling of PAT) for major adverse cardiac events within 4 years.⁸⁷

Atrial Fibrillation

Although less numerous, the evidence for a local effect of EAT and PAT in the pathogenesis of AF is more compelling (Table 5). It is well known that obesity is a risk factor for new-onset AF.¹⁰³ Considering the increasing incidence of obesity and the aging of the population, prevalent cases of AF are expected to exceed 10 million persons in the United States by 2050.¹⁰⁴ Recent data from the Framingham Heart Study have shown that PAT volume, but not intrathoracic or VAT, is associated with prevalent AF.¹⁰¹ In age- and sex-adjusted models, per 1-SD increase in PAT volume, there was a 30% increased risk of AF (OR 1.30, 95% 1.0 to 1.6, $P<0.02$). This association was not observed for VAT or thoracic fat volume. Furthermore, it remained equally significant in multivariable models, which included measures of visceral adiposity such as BMI.¹⁰¹ This is in contrast to many of the prior studies of CV risk in which the observed associations with PAT volume are negated when the systemic effects of visceral adiposity are accounted for. The authors concluded that PAT likely exerts a local effect on the atria, by secreting cytokines/adipokines that affect atrial mechanical or electrical remodeling; this possibility is supported by the results of translational studies.^{50,101}

Table 3. Studies Examining the Relationship Between EAT and/or PAT and Cardiovascular Risk Factors

Authors	Fat Depot	Imaging Modality	Clinical Variables	Measure of Association	Notes
Iacobellis et al ⁷⁸	EAT	Echo	WC VAT volume	$r=0.845, P<0.01$ $r=0.840, P<0.01$	72 patients with a BMI ranging from 22 to 47 kg/m ² .
Wheeler et al ²⁶	PAT	CT	VAT volume	$r=0.81, P<0.0001$	80 subjects chosen at random from a family study of sibling pairs with type 2 diabetes mellitus.
Iacobellis et al ⁸⁶	EAT	Echo	VAT volume IMT	$r=0.85, P<0.001$ $r=0.78, P<0.001$	60 HIV+ patients with HAART-associated metabolic syndrome. IMT was greater in patients with metabolic syndrome, than those without.
Iacobellis et al ⁷⁷	EAT	Echo	VAT volume Serum AST Serum ALT Serum adiponectin	$r=0.83, P<0.01$ $r=0.56, P<0.01$ $r=0.58, P<0.01$ $r=-0.45, P<0.01$	57 HIV+ patients with HAART-associated metabolic syndrome. EAT thickness was associated with visceral fat volume by MRI and serum markers of hepatic steatosis (AST, ALT).
Wang et al ⁷⁹	EAT (left AV groove)	CT	Resistin hsCRP	$r=0.16, P<0.05$ $r=0.16, P<0.05$	148 consecutive patients undergoing MDCT. Researchers measured thickness of EAT in different areas. EAT thickness in the left AV groove was the only measurement associated with all 3 components of the metabolic syndrome.
Cheng et al ⁸⁷	PAT	CT	MACE	OR 1.7 (95% CI 1.0 to 2.9) per doubling of PAT volume	2751 asymptomatic patients without CAD who had MDCT and were followed for major adverse cardiac events for 4 years. Multivariate analysis was adjusted for BMI, CCS, and Framingham scores.
Dey et al ⁸⁸	PAT	CT	VAT area BMI	$r=0.79, P<0.0001$ $r=0.49, P<0.0001$	201 patients who had CT scans to measure CCS. PAT volume was also associated with coronary calcium (OR 3.1, $P=0.04$).
Tamarappo et al ⁸⁹	PAT	CT SPECT	Ischemia	OR 2.9 (95% CI 1.5 to 5.5), $P<0.001$	1777 consecutive patients without previously known CAD who had CT performed within 6 months of SPECT. Multivariable analysis was adjusted for BMI, CCS, and traditional risk factors but not VAT.
Otaki et al ⁹⁰	EAT	CT	Incident CAD	ND	1248 low-risk patients with CCS of 0 who developed coronary calcium, and 106 controls who did not. There was no difference in the indexed EAT volume in those with and without incident coronary calcium.
Britton et al ⁹¹	VAT PAT Aortic PVAT	CT	Incident CVD Cancer All-cause mortality	HR 1.44 (95% CI 1.08 to 1.97), $P=0.01$ HR 1.42 (95% CI 1.12 to 1.84), $P=0.005$	Prospective study that measured fat depot in 3000 patients without CVD at baseline; median follow-up of 5 years. VAT, but not PAT or PVAT from the thoracic aorta, was associated with an incidence CVD and cancer. None of the fat depots were associated with all-cause mortality.

EAT indicates epicardial adipose tissue; PAT, pericardial adipose tissue; Echo, echocardiography; WC, waist circumference; VAT, visceral adipose tissue; BMI, body mass index; CT, computed tomography; HIV, human immunodeficiency virus; IMT, intima-media thickness; HAART, highly active anti-retroviral therapy; ALT, alanine aminotransferase; AST, aspartate aminotransferase; MRI, magnetic resonance imaging; AV, atrioventricular; hsCRP, high-sensitivity C-reactive protein; MDCT, multidetector computed tomography; MACE, major adverse cardiac events; SPECT, single-photon emission computed tomography; CAD, coronary artery disease; CCS, coronary calcium score; HR, hazard ratio; ND, no difference; PVAT, perivascular adipose tissue.

Table 4. Studies That Examine the Relationship Between Coronary Atherosclerosis and EAT or PAT

Authors	Fat Depot	Imaging Modality	Clinical Variables	Measure of Association	Notes
Ding et al ⁹⁴	PAT	CT	CAC (+/−)	OR 1.92 (95% CI 1.2 to 2.9), <i>P</i> <0.002	162 patients from the Multi-Ethnic Study of Atherosclerosis. Per 1-SD increment in PAT volume, there was a 92% greater risk of the presence of CAC. Model was adjusted for height but not VAT.
Jeong et al ⁹⁵	EAT	Echo	Age CRP BMI WC	<i>r</i> =0.33, <i>P</i> <0.0001 <i>r</i> =0.18, <i>P</i> =0.009 <i>r</i> =0.14, <i>P</i> =0.042 <i>r</i> =0.22, <i>P</i> =0.001	203 consecutive patients who had both echocardiography and diagnostic coronary angiography. Per 1-SD increase in EAT thickness, there was an OR of 10.53 for significant coronary stenosis. Multivariate analysis was not adjusted.
Mahabadi et al ⁹⁶	PAT	CT	Prevalent CVD Prevalent CHD Prevalent MI	OR 1.3 (95% CI 1.0 to 1.5), <i>P</i> <0.006 OR 1.9 (95% CI 1.2 to 3.0), <i>P</i> <0.004 OR 1.3 (95% CI 1.0 to 1.8), <i>P</i> <0.03	1267 participants in the Framingham Offspring Cohort (9.7% prevalent CVD). PAT and VAT volume were associated with prevalent CVD. However, PAT, but not VAT, was also associated with prevalent CHD or MI.
Grief et al ⁹²	PAT	CT	Diseased segments Serum adiponectin Serum HDL Serum hsCRP Serum TNF α	<i>r</i> =0.44, <i>P</i> <0.0001 <i>r</i> =−0.23, <i>P</i> <0.0001 <i>r</i> =−0.25, <i>P</i> <0.0001 <i>r</i> =0.12, <i>P</i> <0.04 <i>r</i> =0.18, <i>P</i> <0.002	286 consecutive patients with intermediate risk of CAD. PAT volume was significantly associated with BMI and the number of diseased segments, independent of BMI. VAT was not measured.
Saam et al ⁹⁷	PAT	FDG PET CT	Target-to-background ratio in LAD	<i>r</i> =0.20, <i>P</i> <0.05	292 cancer patients who had FDG PET and CT scans. Inflammation in the LAD, as measured by FDG uptake, correlated with HTN, BMI, CAD, and PAT volume.
Liu et al ⁸³	PAT	CT	HTN MS CAC	OR 1.3 (95% CI 1.0 to 1.9), <i>P</i> <0.03 OR 1.3 (95% CI 1.0 to 1.6), <i>P</i> <0.006 OR 1.3 (95% CI 1.1 to 1.6), <i>P</i> <0.004	1414 patients enrolled in the Jackson Heart Study. Correlations of PAT volume with cardiac risk factors were diminished after adjustment for VAT volume. However, associations with HTN, MS, and CAC remained significant.
Cheng et al ⁸⁷	PAT	CT	MACE	OR 1.7 (95% CI 1.0 to 2.9) per doubling of PAT volume	2751 asymptomatic patients without CAD who had MDCT and were followed for MACE for 4 years. Multivariate analysis was adjusted for BMI, CCS, and Framingham scores.
Dey et al ⁸⁸	PAT	CT	VAT area BMI	<i>r</i> =0.79, <i>P</i> <0.0001 <i>r</i> =0.49, <i>P</i> <0.0001	201 patients who had CT scans to measure CCS. PAT volume was also associated with coronary calcium (OR 3.1, <i>P</i> =0.04).
Tamarappo et al ⁸⁹	PAT	CT SPECT	Ischemia	OR 2.9 (95% CI 1.5 to 5.5), <i>P</i> <0.001	1777 consecutive patients without previously known CAD who had CT performed within 6 months of SPECT. Multivariate analysis was adjusted for BMI, CCS, and traditional risk factors but not VAT.
Otaki et al ⁹⁰	EAT	CT	Incident CAD	ND	1248 low-risk patients with CCS of 0 who developed coronary calcium, and 106 controls who did not. There was no difference in the indexed EAT volume in those with and without incident coronary calcium.

EAT indicates epicardial adipose tissue; PAT, pericardial adipose tissue; CT, computed tomography; CAC, coronary artery calcium; Echo, echocardiography; VAT, visceral adipose tissue; CRP, C-reactive protein; BMI, body mass index; WC, waist circumference; CVD, cardiovascular disease; CHD, coronary heart disease; MI, myocardial infarction; HDL, high-density lipoprotein; hsCRP, high-sensitivity C-reactive protein; TNF α , tumor necrosis factor α ; FDG, fluorodeoxyglucose; PET, positron emission tomography; LAD, left anterior descending coronary artery; HTN, hypertension; CAD, coronary artery disease; ND, no difference; MS, metabolic syndrome; MACE, major adverse cardiac events; CCS, coronary calcium score; SPECT, single-photon emission computed tomography; MDCT, multidetector computed tomography.

Table 5. Studies That Report an Association Between EAT and/or PAT and AF

Authors	Fat Depot	Imaging Modality	Clinical variables	Measure of Association	Notes
Shin et al ⁹⁹	EAT	CT	LAV Total EAT Periatrial EAT	NA NA NA	40 patients with PAF, 40 with PeAF, and 80 control patients without AF. PAF and PeAF patients had larger LAV, total EAT, and periatrial EAT than controls. PeAF patients had greater LAV, EAT total, and periatrial EAT and lower coronary sinus adiponectin than PAF patients.
Batal et al ¹⁰⁰	EAT	CT	AF burden	OR 5.30 (95% CI 1.3 to 20.2)	169 patients who had CT scans for AF or CAD. EAT thickness directly posterior to the LA was greater in those with PeAF than in those with PAF or without AF. Multivariate analysis controlled for age, BMI, and LA size.
Thanassoulis et al ¹⁰¹	PAT	CT	Prevalent AF	OR 1.28 (95% CI 1.03 to 1.58)	Pericardial fat was associated with AF after adjustment for risk factors, including BMI
Wong et al ¹⁰²	PAT	MRI	Prevalent AF AF symptom burden AF chronicity AF recurrence	$P < 0.05$ for all end points	PAT volumes were significantly associated with all 4 end points, even after adjustment for BMI and BSA. Total pericardial fat volume showed a modest, linear association with LA volume ($r = 0.46$, $P < 0.001$).

EAT indicates epicardial adipose tissue; PAT, pericardial adipose tissue; AF, atrial fibrillation; CT, computed tomography; LAV, left atrial volume; NA, not available; PAF, paroxysmal atrial fibrillation; PeAF, permanent atrial fibrillation; BMI, body mass index; LA, left atrium; MRI, magnetic resonance imaging; BSA, body surface area; CAD, coronary artery disease.

A second study, in which 169 patients who underwent CT scans for AF or CAD were examined, strengthened and refined this conclusion.¹⁰⁰ Thickness of epicardial fat pads around the mid-left atrium (LA) was measured in relation to 3 anatomical landmarks: the esophagus, pulmonary artery, and thoracic aorta. Of these 3 fat pads, mid-LA–esophagus is the most posterior to the LA and directly adjacent to the pulmonary vein ostia. Interestingly, in patients with persistent AF, thickness of the mid-LA–esophagus fat pad was almost twice that of those with paroxysmal or no AF (0.56 cm versus 0.39 cm, $P = 0.011$, and 0.56 cm versus 0.34 cm, $P < 0.015$).¹⁰⁰ In contrast, there was no difference in the thickness of the anterior epicardial fat pads (mid-LA–thoracic aorta, mid-LA–pulmonary artery) between groups. In multivariate analysis, adjusted for age, BMI, and mid-LA area, thickness of the mid-LA–esophagus epicardial fat was a significant predictor of AF burden (OR 5.30, 95% CI 1.39 to 20.24, $P = 0.015$).¹⁰⁰

A recent MRI study confirmed these results by showing that PAT volume is associated not only with prevalent AF and AF burden but also LA remodeling and poorer outcomes after radiofrequency ablation.¹⁰² A total of 110 patients undergoing RF ablation for AF and 20 normal controls underwent MRI to quantify PAT volumes. There was a dose-response of PAT volume for both the presence and the chronicity of AF; those with persistent AF had the highest mean PAT volume and normal controls had the lowest. After adjustment for body weight, total PAT volume was predictive of the presence of AF

(OR 13.28, 95% CI 2.2 to 79, $P = 0.005$) and the presence of nonparoxysmal AF (OR 3.28, 95% CI 1.2 to 8.5, $P = 0.015$), whereas BMI was not.¹⁰² Importantly, PAT volume, but not BMI, was also associated with greater LA volume and predicted of AF recurrence.

Although these studies still demonstrate association and not causation, they do provide compelling evidence that epicardial fat depots may have an adverse effect on the adjacent atrial or pulmonary vein tissue. Furthermore, because many of these studies control for measures of visceral adiposity, they suggest that these effects are specific to EAT/PAT and not systemic inflammation. This is may be analogous to the independent association of EAT/PAT with coronary calcification.^{83,93}

Ventricular Remodeling and Heart Failure

In patients without CVD, EAT thickness measured by using echocardiography has been found to directly correlate with indexed left ventricular (LV) mass ($r = 0.75$, $P = 0.01$).¹⁰⁵ When classified by waist circumference, men and women with abdominal obesity had greater LV mass and EAT thickness than those with truncal obesity. In multivariate analysis, EAT thickness was the strongest determinant of indexed LV mass.¹⁰⁵ In contrast, 2 recent studies have demonstrated that patients with systolic heart failure (HF) have proportional reductions in EAT volume compared with normal controls.^{106,107} In the first study, 381 patients referred for

myocardial perfusion imaging had CT performed. Patients were divided into those with or without a history of LV dysfunction (ejection fraction <55%) on echocardiography. Patients with reduced ejection fraction had lower EAT volumes than control patients ($114.5 \pm 98.5 \text{ cm}^3$ versus $83.5 \pm 98.5 \text{ cm}^3$, $P < 0.05$). In subgroup analysis, patients with a severely reduced ejection fraction (<35%) had EAT volumes that were lower than those with moderate LV dysfunction.¹⁰⁶ These differences in EAT volume persisted when adjusted for BMI. Correlations with LV mass indices were not provided. A second study used MRI to measure EAT volume in 66 patients with cardiomyopathy and 32 healthy controls.¹⁰⁷ Indexed EAT volume showed a direct correlation with indexed LV end-diastolic mass in both normal controls and HF patients. However, on average, HF patients had less indexed EAT mass than normal controls ($22 \pm 5 \text{ g/m}^2$ versus $34 \pm 4 \text{ g/m}^2$, $P < 0.001$).¹⁰⁷ The ratio of EAT mass to LV mass was also significantly reduced in HF patients compared with controls. Post-mortem studies have also shown a significant reduction in EAT in patients with evidence of HF.¹⁰⁸ As the ratio of EAT to myocardium generally remains constant in normal individuals, the authors suggested that there is a “deficit” of epicardial fat in HF patients.¹⁰⁷ As has been shown in obesity or CAD, this may be associated with reductions in local or serum ADIPOQ concentrations, a cardioprotective adipokine that has anti-inflammatory and vasodilatory effects.¹⁰⁷

Summary

Increased EAT thickness measured by using echocardiography or EAT/PAT volume by using CT/MRI correlates well with visceral adiposity and hence is associated with multiple components of the metabolic syndrome. Although increased EAT volume is associated with prevalent CAD, this association is most likely due to the systemic inflammation caused by hypertrophied visceral fat depots. There is no strong evidence to date that EAT or PVAT in humans is independently associated with incident CVD. However, EAT may have local paracrine effects on the heart and circulation, as shown by the independent association of EAT volume with coronary calcification, LA volume, AF presence, and burden. This possibility seems increasingly likely in light of evidence that EAT from patients with CAD has increased inflammatory cytokine expression at the tissue level, without evidence of increased proinflammatory cytokines in serum.⁴⁹ The observation that patients with systolic HF have reduced EAT volume suggests that there may be a beneficial effect of EAT that is lost in systolic dysfunction. Whether this correlates with reduced tissue or plasma levels of cardioprotective adipokines such as ADIPOQ has yet to be demonstrated, and it may also be a manifestation of cardiac cachexia. Certainly, there is ample evidence to suggest that EAT and PAT are potential

therapeutic targets that could be modified to affect health or disease. For example, diet, exercise, and gastric bypass have all been shown to reduce visceral and epicardial fat mass and lower cardiometabolic risk.^{81,109,110} Additional experimental therapeutic strategies may include drugs that inhibit EAT/PAT inflammation, epicardial/pericardial fat removal or transplantation, and stem cell-based protocols in chronic systolic HF.

Acknowledgments

We apologize to those authors whose work we did not cite in the text due to space considerations. We thank Dr John F. Keaney for his helpful comments and suggestions.

Sources of Funding

Dr Fitzgibbons is supported by a Fellow to Faculty Award from the National Affiliate of the American Heart Association (12FTF11260010). Dr Czech is supported by National Institutes of Health grants (DK085753, AI046629, and DK030898) and the International Research Alliance of the Norvo Nordisk Foundation Center for Metabolic Research.

Disclosures

None.

References

1. Fox CS, Massaro JM, Hoffmann U, Pou KM, Maurovich-Horvat P, Liu CY, Vasan RS, Murabito JM, Meigs JB, Cupples LA, D'Agostino RB Sr, O'Donnell CJ. Abdominal visceral and subcutaneous adipose tissue compartments: association with metabolic risk factors in the Framingham Heart Study. *Circulation*. 2007;116:39–48.
2. DeFronzo RA. Insulin resistance, lipotoxicity, type 2 diabetes and atherosclerosis: the missing links. The Claude Bernard Lecture 2009. *Diabetologia*. 2010;53:1270–1287.
3. Van Gaal LF, Mertens IL, De Block CE. Mechanisms linking obesity with cardiovascular disease. *Nature*. 2006;444:875–880.
4. Litwin SE. Normal weight obesity: is bigger really badder? *Circ Cardiovasc Imaging*. 2012;5:286–288.
5. Iacobellis G, Assael F, Ribaudo MC, Zappaterreno A, Alessi G, Di Mario U, Leonetti F. Epicardial fat from echocardiography: a new method for visceral adipose tissue prediction. *Obes Res*. 2003;11:304–310.
6. Iacobellis G, Willens HJ. Echocardiographic epicardial fat: a review of research and clinical applications. *J Am Soc Echocardiogr*. 2009;22:1311–1319.
7. Hotamisligil GS, Arner P, Caro JF, Atkinson RL, Spiegelman BM. Increased adipose tissue expression of tumor necrosis factor- α in human obesity and insulin resistance. *J Clin Invest*. 1995;95:2409–2415.
8. Weisberg SP, McCann D, Desai M, Rosenbaum M, Leibel RL, Ferrante AW Jr. Obesity is associated with macrophage accumulation in adipose tissue. *J Clin Invest*. 2003;112:1796–1808.
9. Xu H, Barnes GT, Yang Q, Tan G, Yang D, Chou CJ, Sole J, Nichols A, Ross JS, Tartaglia LA, Chen H. Chronic inflammation in fat plays a crucial role in the development of obesity-related insulin resistance. *J Clin Invest*. 2003;112:1821–1830.
10. Gustafson B, Hammarstedt A, Andersson CX, Smith U. Inflamed adipose tissue: a culprit underlying the metabolic syndrome and atherosclerosis. *Arterioscler Thromb Vasc Biol*. 2007;27:2276–2283.
11. Sun K, Kusminski CM, Scherer PE. Adipose tissue remodeling and obesity. *J Clin Invest*. 2011;121:2094–2101.

12. Guilherme AVJ, Puri V, Czech MP. Adipocyte dysfunctions linking obesity to insulin resistance and type 2 diabetes. *Nat Rev Cell Biol*. 2008;9:367–377.
13. Rytka JM, Wueest S, Schoenle EJ, Konrad D. The portal theory supported by venous drainage-selective fat transplantation. *Diabetes*. 2011;60:56–63.
14. Harmaney R, Wilson CR, Taegtmeier H. Adaptation and maladaptation of the heart in obesity. *Hypertension*. 2008;52:181–187.
15. Karpe F, Dickmann JR, Frayn KN. Fatty acids, obesity, and insulin resistance: time for a reevaluation. *Diabetes*. 2011;60:2441–2449.
16. Kosteli A, Soguru E, Haemmerle G, Martin JF, Lei J, Zechner R, Ferrante AW Jr. Weight loss and lipolysis promote a dynamic immune response in murine adipose tissue. *J Clin Invest*. 2010;120:3466–3479.
17. Bertola A, Ciucci T, Rousseau D, Bourlier V, Duffaut C, Bonnafous S, Blin-Wakkach C, Anty R, Iannelli A, Gugenheim J, Tran A, Bouloumie A, Gual P, Wakkach A. Identification of adipose tissue dendritic cells correlated with obesity-associated insulin-resistance and inducing Th17 responses in mice and patients. *Diabetes*. 2012;61:2238–2247.
18. DeFuria J, Belkina AC, Jagannathan-Bogdan M, Snyder-Cappione J, Carr JD, Neresosova YR, Markham D, Strissel KJ, Watkins AA, Zhu M, Allen J, Bouchard J, Toraldo G, Jasuja R, Obin MS, McDonnell ME, Apovian C, Denis GV, Nikolajczyk BS. B cells promote inflammation in obesity and type 2 diabetes through regulation of T-cell function and an inflammatory cytokine profile. *Proc Natl Acad Sci USA*. 2013;110:5133–5138.
19. Kintscher U, Hartge M, Hess K, Foryst-Ludwig A, Clemenz M, Wabitsch M, Fischer-Posovszky P, Barth TF, Dragun D, Skurk T, Hauner H, Bluher M, Unger T, Wolf AM, Knippschild U, Hombach V, Marx N. T-lymphocyte infiltration in visceral adipose tissue: a primary event in adipose tissue inflammation and the development of obesity-mediated insulin resistance. *Arterioscler Thromb Vasc Biol*. 2008;28:1304–1310.
20. Talukdar S, da Oh Y, Bandyopadhyay G, Li D, Xu J, McNelis J, Lu M, Li P, Yan Q, Zhu Y, Ofrecio J, Lin M, Brenner MB, Olefsky JM. Neutrophils mediate insulin resistance in mice fed a high-fat diet through secreted elastase. *Nat Med*. 2012;18:1407–1412.
21. Zhang J, Shi GP. Mast cells and metabolic syndrome. *Biochim Biophys Acta*. 2012;1822:14–20.
22. Patsouris D, Li PP, Thapar D, Chapman J, Olefsky JM, Neels JG. Ablation of CD11c-positive cells normalizes insulin sensitivity in obese insulin resistant animals. *Cell Metab*. 2008;8:301–309.
23. Rabkin SW. Epicardial fat: properties, function and relationship to obesity. *Obes Rev*. 2007;8:253–261.
24. Cheung L, Gertow J, Werngren O, Folkersen L, Petrovic N, Nedergaard J, Franco-Cereceda A, Eriksson P, Fisher RM. Human mediastinal adipose tissue displays certain characteristics of brown fat. *Nutr Diabetes*. 2013;3:1–9.
25. Sacks HS, Fain JN, Bahouth SW, Ojha S, Frontini A, Budge H, Cinti S, Symonds ME. Adult epicardial fat exhibits beige features. *J Clin Endocrinol Metab*. 2013;98:E1448–E1455.
26. Wheeler GL, Shi R, Beck SR, Langefeld CD, Lenchik L, Wagenknecht LE, Freedman BI, Rich SS, Bowden DW, Chen MY, Carr JJ. Pericardial and visceral adipose tissues measured volumetrically with computed tomography are highly associated in type 2 diabetic families. *Invest Radiol*. 2005;40:97–101.
27. Fitzgibbons TP, Kogan S, Aouadi M, Hendricks GM, Straubhaar J, Czech MP. Similarity of mouse perivascular and brown adipose tissues and their resistance to diet-induced inflammation. *Am J Physiol Heart Circ Physiol*. 2011;301:1425–1437.
28. Padilla J, Jenkins NT, Vieira-Potter VJ, Laughlin MH. Divergent phenotype of rat thoracic and abdominal perivascular adipose tissues. *Am J Physiol Regul Integr Comp Physiol*. 2013;304:543–552.
29. Police SB, Thatcher SE, Charnigo R, Daugherty A, Cassis LA. Obesity promotes inflammation in periaortic adipose tissue and angiotensin II-induced abdominal aortic aneurysm formation. *Arterioscler Thromb Vasc Biol*. 2009;29:1458–1464.
30. Chang L, Villacorta L, Li R, Hamblin M, Xu W, Dou C, Zhang J, Wu J, Zeng R, Chen YE. Loss of perivascular adipose tissue on peroxisome proliferator-activated receptor-gamma deletion in smooth muscle cells impairs intravascular thermoregulation and enhances atherosclerosis. *Circulation*. 2012;126:1067–1078.
31. Henrichot E, Juge-Aubry CE, Pernin A, Pache JC, Velebit V, Dayer JM, Meda P, Chizzolini C, Meier CA. Production of chemokines by perivascular adipose tissue: a role in the pathogenesis of atherosclerosis? *Arterioscler Thromb Vasc Biol*. 2005;25:2594–2599.
32. Greenstein AS, Khavandi K, Withers SB, Sonoyama K, Clancy O, Jeziorska M, Laing I, Yates AP, Pemberton PW, Malik RA, Heagerty AM. Local inflammation and hypoxia abolish the protective anticontractile properties of perivascular fat in obese patients. *Circulation*. 2009;119:1661–1670.
33. Yudkin JS, Eringa E, Stehouwer CD. “Vasocrine” signalling from perivascular fat: a mechanism linking insulin resistance to vascular disease. *Lancet*. 2005;365:1817–1820.
34. Marchington JM, Pond CM. Site specific properties of pericardial and epicardial adipose tissue: the effects of insulin and high-fat feeding on lipogenesis and the incorporation of fatty acids in vivo. *Int J Obesity*. 1990;14:1013–1022.
35. Aghamohammadzadeh R, Greenstein AS, Yadav R, Jeziorska M, Hama S, Soltani F, Pemberton PW, Ammori B, Malik RA, Soran H, Heagerty AM. Effects of bariatric surgery on human small artery function: evidence for reduction in perivascular adipocyte inflammation, and the restoration of normal anticontractile activity despite persistent obesity. *J Am Coll Cardiol*. 2013;62:128–135.
36. Takaoka M, Nagata D, Kihara S, Shimomura I, Kimura Y, Tabata Y, Saito Y, Nagai R, Sata M. Periadventitial adipose tissue plays a critical role in vascular remodeling. *Circ Res*. 2009;105:906–911.
37. Karastergiou K, Evans I, Ogston N, Miheisi N, Nair D, Kaski JC, Jahangiri M, Mohamed-Ali V. Epicardial adipokines in obesity and coronary artery disease induce atherogenic changes in monocytes and endothelial cells. *Arterioscler Thromb Vasc Biol*. 2010;30:1340–1346.
38. Margaritis M, Antonopoulos AS, Digby J, Lee R, Reilly S, Coutinho P, Shirodaria C, Sayeed R, Petrou M, De Silva R, Jalilzadeh S, Demosthenous M, Bakogiannis C, Tousoulis D, Stefanadis C, Choudhury RP, Casadei B, Channon KM, Antoniades C. Interactions between vascular wall and perivascular adipose tissue reveal novel roles for adiponectin in the regulation of endothelial nitric oxide synthase function in human vessels. *Circulation*. 2013;127:2209–2221.
39. Lembo G, Vecchione C, Fratta L, Marino G, Trimarco V, d’Amati G, Trimarco B. Leptin induces direct vasodilation through distinct endothelial mechanisms. *Diabetes*. 2000;49:293–297.
40. Greulich S, Chen WJ, Maxhera B, Rijzewijk LJ, van der Meer RW, Jonker JT, Mueller H, de Wiza DH, Floerke RR, Smiris K, Lamb HJ, de Roos A, Bax JJ, Romijn JA, Smit JW, Akhyari P, Lichtenberg A, Eckel J, Diamant M, Ouwens DM. Cardioprotective properties of omentin-1 in type 2 diabetes: evidence from clinical and in vitro studies. *PLoS ONE*. 2013;8:e59697.
41. Lee YC, Chang HH, Chiang CL, Liu CH, Yeh JI, Chen MF, Chen PY, Kuo JS, Lee TJ. Role of perivascular adipose tissue-derived methyl palmitate in vascular tone regulation and pathogenesis of hypertension. *Circulation*. 2011;124:1160–1171.
42. Bhattacharya I, Dragert K, Albert V, Contassot E, Damjanovic M, Hagiwara A, Zimmerli L, Humar R, Hall MN, Bategay EJ, Haas E. Rictor in perivascular adipose tissue controls vascular function by regulating inflammatory molecule expression. *Arterioscler Thromb Vasc Biol*. 2013;33:2105–2111.
43. Owen MK, Witzmann FA, McKenney ML, Lai X, Berwick ZC, Moberly SP, Aloosh M, Sturek M, Tune JD. Perivascular adipose tissue potentiates contraction of coronary vascular smooth muscle: influence of obesity. *Circulation*. 2013;128:9–18.
44. Ouchi N, Walsh K. Adiponectin as an anti-inflammatory factor. *Clin Chim Acta*. 2007;380:24–30.
45. Goldstein BJ, Scalia RG, Ma XL. Protective vascular and myocardial effects of adiponectin. *Nat Clin Pract Cardiovasc Med*. 2009;6:27–35.
46. Hirata Y, Tabata M, Kurobe H, Motoki T, Akaike M, Nishio C, Higashida M, Mikasa H, Nakaya Y, Takanashi S, Igarashi T, Kitagawa T, Sata M. Coronary atherosclerosis is associated with macrophage polarization in epicardial adipose tissue. *J Am Coll Cardiol*. 2011;58:248–255.
47. Prieur X, Mok CY, Velagapudi VR, Nunez V, Fuentes L, Montaner D, Ishikawa K, Camacho A, Barbarroja N, O’Rahilly S, Sethi JK, Dopazo J, Oresic M, Ricote M, Vidal-Puig A. Differential lipid partitioning between adipocytes and tissue macrophages modulates macrophage lipotoxicity and M2/M1 polarization in obese mice. *Diabetes*. 2011;60:797–809.
48. Iacobellis G, Pistilli D, Gucciardo M, Leonetti F, Miraldi F, Brancaccio G, Gallo P, di Gioia CR. Adiponectin expression in human epicardial adipose tissue in vivo is lower in patients with coronary artery disease. *Cytokine*. 2005;29:251–255.
49. Mazurek T, Zhang L, Zalweski A, Mannion JD, Diehl JT, Arafat H, Sarov-Blat L, O’Brien S, Keiper EA, Johnson AG, Martin J, Goldstein HJ, Shi Y. Human epicardial adipose tissue is a source of inflammatory mediators. *Circulation*. 2003;108:2460–2466.
50. Venticlef N, Guglielmi V, Balse E, Gaborit B, Cotillard A, Atassi F, Amour J, Leprince P, Dutour A, Clement K, Hatem SN. Human epicardial adipose tissue induces fibrosis of the atrial myocardium through the secretion of adipo-fibrokinases. *Eur Heart J*. 2013; 10.1093/eurheartj/ehd099 [Epub ahead of print].
51. Greulich S, Maxhera B, Vandenplas G, de Wiza DH, Smiris K, Mueller H, Heinrichs J, Blumensatt M, Cuvelier C, Akhyari P, Ruige JB, Ouwens DM, Eckel J. Secretory products from epicardial adipose tissue of patients with

- type 2 diabetes mellitus induce cardiomyocyte dysfunction. *Circulation*. 2012;126:2324–2334.
52. Tian Z, Miyata K, Tazume H, Sakaguchi H, Kadomatsu T, Horio E, Takahashi O, Komohara Y, Araki K, Hirata Y, Tabata M, Takanashi S, Takeya M, Hao H, Shimabukuro M, Sata M, Kawasuji M, Oike Y. Perivascular adipose tissue-secreted angiopoietin-like protein 2 (Angptl2) accelerates neointimal hyperplasia after endovascular injury. *J Mol Cell Cardiol*. 2013;57:1–12.
 53. Watts SW, Dorrance AM, Penfold ME, Rourke JL, Sinal CJ, Seitz B, Sullivan TJ, Charvat TT, Thompson JM, Burnett R, Fink GD. Chemerin connects fat to arterial contraction. *Arterioscler Thromb Vasc Biol*. 2013;33:1320–1328.
 54. Ruan CC, Zhu DL, Chen QZ, Chen J, Guo SJ, Li XD, Gao PJ. Perivascular adipose tissue-derived complement 3 is required for adventitial fibroblast functions and adventitial remodeling in deoxycorticosterone acetate-salt hypertensive rats. *Arterioscler Thromb Vasc Biol*. 2010;30:2568–2574.
 55. Schroeter MR, Leifheit-Nestler M, Hubert A, Schumann B, Gluckerman R, Eschholz N, Kruger N, Lutz S, Hasenfuss G, Konstantinides S, Schafer K. Leptin promotes neointima formation and smooth muscle cell proliferation via NADPH oxidase activation and signalling in caveolin-rich microdomains. *Cardiovasc Res*. 2013;99:555–565.
 56. Langheim S, Dreas L, Veschini L, Maisano F, Foglieni C, Ferrarello S, Sinagra G, Zingone B, Alfieri O, Ferrero E, Maseri A, Ruotolo G. Increased expression and secretion of resistin in epicardial adipose tissue of patients with acute coronary syndrome. *Am J Physiol Heart Circ Physiol*. 2010;298:H746–H753.
 57. Doutour A, Achard V, Sell H, Naour N, Collart F, Gaborit B, Silaghi A, Eckel J, Alessi MC, Henegar C, Clement K. Secretory type II phospholipase A2 is produced and secreted by epicardial adipose tissue and overexpressed in patients with coronary artery disease. *J Clin Endocrinol Metab*. 2010;95:963–967.
 58. Schlich R, Willems M, Greulich S, Ruppe F, Knoefel WT, Ouwens DM, Maxhera B, Lichtenberg A, Eckel J, Sell H. VEGF in the crosstalk between human adipocytes and smooth muscle cells: depot-specific release from visceral and perivascular adipose tissue. *Mediators Inflamm*. 2013;2013:982458.
 59. Wang P, Xu TY, Guan YF, Su DF, Fan GR, Miao CY. Perivascular adipose tissue derived visfatin is a vascular smooth muscle cell growth factor: role of nicotinamide mononucleotide. *Cardiovasc Res*. 2009;81:370–380.
 60. Baker AR, Silva NF, Quinn DW, Harte AL, Pagano D, Bonser RS, Kumar S, McTernan PG. Human epicardial adipose tissue expresses a pathogenic profile of adipocytokines in patients with cardiovascular disease. *Cardiovasc Diabetol*. 2006;5:1.
 61. Baker AR, Harte AL, Howell N, Pritlove DC, Ranasinghe AM, da Silva NF, Yousef EM, Khunti K, Davies MJ, Bonser RS, Kumar S, Pagano D, McTernan PG. Epicardial adipose tissue as a source of nuclear factor-kappaB and c-Jun N-terminal kinase mediated inflammation in patients with coronary artery disease. *J Clin Endocrinol Metab*. 2009;94:261–267.
 62. Kremen J, Dolinkova M, Krajickova J, Blaha J, Anderlova K, Lacinova Z, Haluzikova D, Bosanska L, Vokurka M, Svacina S, Haluzik M. Increased subcutaneous and epicardial adipose tissue production of proinflammatory cytokines in cardiac surgery patients: possible role in postoperative insulin resistance. *J Clin Endocrinol Metab*. 2006;91:4620–4627.
 63. Kiefer FW, Cohen P, Plutzky J. Fifty shades of brown: perivascular fat, thermogenesis, and atherosclerosis. *Circulation*. 2012;126:1012–1015.
 64. Petrovic N, Walden TB, Shabalina IG, Timmons JA, Cannon B, Nedergaard J. Chronic peroxisome proliferator-activated receptor gamma (PPARGamma) activation of epididymally derived white adipocyte cultures reveals a population of thermogenically competent, UCP1-containing adipocytes molecularly distinct from classic brown adipocytes. *J Biol Chem*. 2010;285:7153–7164.
 65. Cypess AM, Lehman S, Williams G, Tal I, Rodman D, Goldfine AB, Kuo FC, Palmer EL, Tseng YH, Doria A, Kolodny GM, Kahn CR. Identification and importance of brown adipose tissue in adult humans. *N Engl J Med*. 2009;360:1509–1517.
 66. van Marken Lichtenbelt WD, Vanhommel JW, Smulders NM, Drossaerts JM, Kemerink GJ, Bouvy ND, Schrauwen P, Teule GJ. Cold-activated brown adipose tissue in healthy men. *N Engl J Med*. 2009;360:1500–1508.
 67. Nedergaard J, Cannon B. The changed metabolic world with human brown adipose tissue: therapeutic visions. *Cell Metab*. 2010;11:268–272.
 68. Tam CS, Lecoultre V, Ravussin E. Brown adipose tissue: mechanisms and potential therapeutic targets. *Circulation*. 2012;125:2782–2791.
 69. Sacks HS, Holman B, Cheema P, Chary A, Parks F, Karas J, Optican R, Bahouth SW, Garrett E, Wolf RY, Carter RA, Robbins T, Wolford D, Samaha J. Uncoupling protein-1 and related messenger ribonucleic acids in human epicardial and other adipose tissues: epicardial fat functioning as brown fat. *J Clin Endocrinol Metab*. 2009;94:3611–3615.
 70. Ohman MK, Luo W, Wang H, Guo C, Abdallah W, Russo HM, Eitzman DT. Perivascular visceral adipose tissue induces atherosclerosis in apolipoprotein E deficient mice. *Atherosclerosis*. 2011;219:33–39.
 71. Ohman MK, Wright AP, Wickenheiser KJ, Luo W, Russo HM, Eitzman DT. Monocyte chemoattractant protein-1 deficiency protects against visceral fat-induced atherosclerosis. *Arterioscler Thromb Vasc Biol*. 2010;30:1151–1158.
 72. Iacobellis G. Epicardial and pericardial fat: close, but very different. *Obesity*. 2009;17:625; author reply 626–627.
 73. Sironi AM, Gastaldelli A, Mari A, Ciociaro D, Positano V, Buzzigoli E, Ghione S, Turchi S, Lombardi M, Ferrannini E. Visceral fat in hypertension: influence on insulin resistance and beta-cell function. *Hypertension*. 2004;44:127–133.
 74. Sacks HS, Fain JN. Human epicardial adipose tissue: a review. *Am Heart J*. 2007;153:907–917.
 75. Ho E, Shimada Y. Formation of the epicardium studied with the scanning electron microscope. *Dev Biol*. 1978;66:579–585.
 76. Iacobellis G, Leonetti F. Epicardial adipose tissue and insulin resistance in obese subjects. *J Clin Endocrinol Metab*. 2005;90:6300–6302.
 77. Iacobellis G, Pellicelli AM, Grisorio B, Barbarini G, Leonetti F, Sharma AM, Barbaro G. Relation of epicardial fat and alanine aminotransferase in subjects with increased visceral fat. *Obesity*. 2008;16:179–183.
 78. Iacobellis G, Ribaudo MC, Assael F, Vecchi E, Tiberti C, Zappaterreno A, Di Mario U, Leonetti F. Echocardiographic epicardial adipose tissue is related to anthropometric and clinical parameters of metabolic syndrome: a new indicator of cardiovascular risk. *J Clin Endocrinol Metab*. 2003;88:5163–5168.
 79. Wang TD, Lee WJ, Shih FY, Huang CH, Chang YC, Chen WJ, Lee YT, Chen MF. Relations of epicardial adipose tissue measured by multidetector computed tomography to components of the metabolic syndrome are region-specific and independent of anthropometric indexes and intraabdominal visceral fat. *J Clin Endocrinol Metab*. 2009;94:662–669.
 80. Britton KA, Pedley A, Massaro JM, Corsini EM, Murabito JM, Hoffmann U, Fox CS. Prevalence, distribution, and risk factor correlates of high thoracic periaortic fat in the Framingham Heart Study. *J Am Heart Assoc*. 2012;1:e004200.
 81. Iacobellis G, Singh N, Wharton S, Sharma AM. Substantial changes in epicardial fat thickness after weight loss in severely obese subjects. *Obesity*. 2008;16:1693–1697.
 82. Iacobellis G, Corradi D, Sharma AM. Epicardial adipose tissue: anatomic, biomolecular and clinical relationships with the heart. *Nat Clin Pract Cardiovasc Med*. 2005;2:536–543.
 83. Liu J, Fox CS, Hickson D, Sarpong D, Ekunwe L, May WD, Hundley GW, Carr JJ, Taylor HA. Pericardial adipose tissue, atherosclerosis, and cardiovascular disease risk factors: the Jackson heart study. *Diabetes Care*. 2010;33:1635–1639.
 84. Natale F, Tedesco MA, Mocerino R, de Simone V, Di Marco GM, Aronne L, Credendino M, Siniscalchi C, Calabro P, Cotrufo M, Calabro R. Visceral adiposity and arterial stiffness: echocardiographic epicardial fat thickness reflects, better than waist circumference, carotid arterial stiffness in a large population of hypertensives. *Eur J Echocardiogr*. 2009;10:549–555.
 85. Rosenquist KJ, Pedley A, Massaro JM, Therklens KE, Murabito JM, Hoffmann U, Fox CS. Visceral and subcutaneous fat quality and cardiometabolic risk. *JACC Cardiovasc Imaging*. 2013;6:762–771.
 86. Iacobellis G, Sharma AM, Pellicelli AM, Grisorio B, Barbarini G, Barbaro G. Epicardial adipose tissue is related to carotid intima-media thickness and visceral adiposity in HIV-infected patients with highly active antiretroviral therapy-associated metabolic syndrome. *Curr HIV Res*. 2007;5:275–279.
 87. Cheng VY, Dey D, Tamarappoo B, Nakazato R, Gransar H, Miranda-Peats R, Ramesh A, Wong ND, Shaw LJ, Slomka PJ, Berman DS. Pericardial fat burden on ECG-gated noncontrast CT in asymptomatic patients who subsequently experience adverse cardiovascular events. *JACC Cardiovasc Imaging*. 2010;3:352–360.
 88. Dey D, Wong ND, Tamarappoo B, Nakazato R, Gransar H, Cheng VY, Ramesh A, Kakadiaris IGG, Slomka PJ, Berman DS. Computer-aided non-contrast CT-based quantification of pericardial and thoracic fat and their associations with coronary calcium and metabolic syndrome. *Atherosclerosis*. 2010;209:136–141.
 89. Tamarappoo B, Dey D, Shmilovich H, Nakazato R, Gransar H, Cheng VY, Friedman JD, Hayes SW, Thomson LE, Slomka PJ, Rozanski A, Berman DS. Increased pericardial fat volume measured from noncontrast CT predicts myocardial ischemia by SPECT. *JACC Cardiovasc Imaging*. 2010;3:1104–1112.
 90. Otaki Y, Ragani RR, Cheng VY, Gransar H, Nakanishi R, Shmilovich H, Nakazato R, Hayes SW, Thomson LE, Friedman JD, Slomka PJ, Wong ND,

- Rozanski A, Shaw L, Budoff M, Berman DS, Dey D. The relationship between epicardial fat volume and incident coronary artery calcium. *J Cardiovasc Comput Tomogr*. 2011;5:310–316.
91. Britton KA, Massaro JM, Murabito JM, Kreger BE, Hoffmann U, Fox CS. Body fat distribution, incident cardiovascular disease, cancer, and all-cause mortality. *J Am Coll Cardiol*. 2013;62:921–925.
 92. Greif M, Becker A, von Ziegler F, Lebherz C, Lehrke M, Broedl UC, Tittus J, Parhofer K, Becker C, Reiser M, Knez A, Leber AW. Pericardial adipose tissue determined by dual source CT is a risk factor for coronary atherosclerosis. *Arterioscler Thromb Vasc Biol*. 2009;29:781–786.
 93. Rosito GA, Massaro JM, Hoffmann U, Ruberg FL, Mahabadi AA, Vasan RS, O'Donnell CJ, Fox CS. Pericardial fat, visceral abdominal fat, cardiovascular disease risk factors, and vascular calcification in a community-based sample: the Framingham Heart Study. *Circulation*. 2008;117:605–613.
 94. Ding J, Kritchevsky SB, Harris TB, Burke GL, Detrano RC, Szklo M, Carr JJ. The association of pericardial fat with calcified coronary plaque. *Obesity*. 2008;16:1914–1919.
 95. Jeong JW, Jeong MH, Yun KH, Oh SK, Park EM, Kim YK, Rhee SJ, Lee EM, Lee J, Yoo NJ, Kim NH, Park JC. Echocardiographic epicardial fat thickness and coronary artery disease. *Circ J*. 2007;71:536–539.
 96. Mahabadi AA, Massaro JM, Rosito GA, Levy D, Murabito JM, Wolf PA, O'Donnell CJ, Fox CS, Hoffmann U. Association of pericardial fat, intrathoracic fat, and visceral abdominal fat with cardiovascular disease burden: the Framingham Heart Study. *Eur Heart J*. 2009;30:850–856.
 97. Saam T, Rominger A, Wolpers S, Nikolaou K, Rist C, Greif M, Cumming P, Becker A, Foerster S, Reiser MF, Bartenstein P, Hacker M. Association of inflammation of the left anterior descending coronary artery with cardiovascular risk factors, plaque burden and pericardial fat volume: a PET/CT study. *Eur J Nucl Med Mol Imaging*. 2010;37:1203–1212.
 98. Nakanishi R, Rajani R, Cheng VY, Gransar H, Nakazato R, Shmilovich H, Otaki Y, Hayes SW, Thomson LE, Friedman JD, Slomka PJ, Berman DS, Dey D. Increase in epicardial fat volume is associated with greater coronary artery calcification progression in subjects at intermediate risk by coronary calcium score: a serial study using non-contrast cardiac CT. *Atherosclerosis*. 2011;218:363–368.
 99. Shin SY, Yong HS, Lim HE, Na JO, Choi CU, Choi JI, Kim SH, Kim JW, Kim EJ, Park SW, Rha SW, Park CG, Seo HS, Oh DJ, Kim YH. Total and interatrial epicardial adipose tissues are independently associated with left atrial remodeling in patients with atrial fibrillation. *J Cardiovasc Electrophysiol*. 2011;22:647–655.
 100. Batal O, Schoenhagen P, Shao M, Ayyad AE, Van Wagoner DR, Halliburton SS, Tchou PJ, Chung MK. Left atrial epicardial adiposity and atrial fibrillation. *Circ Arrhythm Electrophysiol*. 2010;3:230–236.
 101. Thanassoulis G, Massaro JM, O'Donnell CJ, Hoffmann U, Levy D, Ellinor PT, Wang TJ, Schnabel RB, Vasan RS, Fox CS, Benjamin EJ. Pericardial fat is associated with prevalent atrial fibrillation: the Framingham Heart Study. *Circ Arrhythm Electrophysiol*. 2010;3:345–350.
 102. Wong CX, Abed HS, Molaei P, Nelson AJ, Brooks AG, Sharma G, Leong DP, Lau DH, Middeldorp ME, Roberts-Thomson KC, Wittert GA, Abhayaratna WP, Worthley SG, Sanders P. Pericardial fat is associated with atrial fibrillation severity and ablation outcome. *J Am Coll Cardiol*. 2011;57:1745–1751.
 103. Wang TJ, Parise H, Levy D, D'Agostino RB Sr, Wolf PA, Vasan RS, Benjamin EJ. Obesity and the risk of new-onset atrial fibrillation. *JAMA*. 2004;292:2471–2477.
 104. Miyasaka Y, Barnes ME, Gersh BJ, Cha SS, Bailey KR, Abhayaratna WP, Seward JB, Tsang TS. Secular trends in incidence of atrial fibrillation in Olmsted County, Minnesota, 1980 to 2000, and implications on the projections for future prevalence. *Circulation*. 2006;114:119–125.
 105. Iacobellis G, Ribaldo MC, Zappaterreno A, Iannucci CV, Leonetti F. Relation between epicardial adipose tissue and left ventricular mass. *Am J Cardiol*. 2004;94:1084–1087.
 106. Khawaja T, Greer C, Chokshi A, Chavarria N, Thadani S, Jones M, Schaeffle K, Bhatia K, Collado JE, Shimbo D, Einstein AJ, Schulze PC. Epicardial fat volume in patients with left ventricular systolic dysfunction. *Am J Cardiol*. 2011;108:397–401.
 107. Doesch C, Haghi D, Flüchter S, Suselbeck T, Schoenberg SO, Michaely H, Borggreffe M, Papavassiliu T. Epicardial adipose tissue in patients with heart failure. *J Cardiovasc Magn Reson*. 2010;12:40.
 108. Schejbal V. Epicardial fatty tissue of the right ventricle—morphology, morphometry and functional significance. *Pneumologie*. 1989;43:490–499.
 109. Kim MK, Tomita T, Kim MJ, Sasai H, Maeda S, Tanaka K. Aerobic exercise training reduces epicardial fat in obese men. *J Appl Physiol*. 2009;106:5–11.
 110. Willens HJ, Byers P, Chirinos JA, Labrador E, Hare JM, de Marchena E. Effects of weight loss after bariatric surgery on epicardial fat measured using echocardiography. *Am J Cardiol*. 2007;99:1242–1245.

Key Words: adipose • atherosclerosis • epicardial • obesity • perivascular