

Prenatal Diagnosis of Right Dominant Heart in Fetuses: A Tertiary Center Experience over a 7-year Period

Juan Feng, Mei Zhu, Hao Liang, Qiao Li

Department of Ultrasound, Shandong Provincial Hospital Affiliated to Shandong University, Jinan, Shandong 250021, China

Abstract

Background: Right dominant heart (RDH) in fetuses can occur with a number of cardiac as well as noncardiac anomalies. Analysis of the enlargement of the right cardiac chamber in the fetus remains a major challenge for sonographers and echocardiographers. The aim of this study was to report the experience with prenatal diagnosis of RDH in the fetuses over a 7-year period.

Methods: Fetuses with prenatal diagnosis of RDH from July 2009 to July 2016 were evaluated in two different categories: according to the gestational age, Group I ($n = 154$, second trimester) and Group II ($n = 298$, third trimester); and according to the fetal echocardiography diagnosis, Group A ($n = 452$, abnormal cardiac structure) and Group B ($n = 90$, normal cardiac structure). Differences in categorical variables were assessed by Chi-square exact test and continuous variables were evaluated by independent Student's *t*-test or Mann-Whitney *U*-test depending on parametric or nonparametric nature of the data.

Results: Over a 7-year period, 452 fetuses were referred for the assessment of suspected RDH. Left-sided obstructive lesions were observed most frequently in the fetuses with RDH. When comparing Group I with Group II and Group A with Group B, the latter groups exhibited significant differences in the right/left ventricle (RV/LV) ratio (1.435 vs. 1.236, $P = 0.002$; 1.309 vs. 1.168, $P = 0.047$), RV width Z-score (1.626 vs. 1.104, $P < 0.001$; 1.553 vs. 0.814, $P = 0.014$), and above +2 cutoff percentages (14.3% vs. 22.5%; $P = 0.038$; 21.5% vs. 12.2%, $P = 0.046$). Multivariable logistic regression revealed no variables associated with perinatal survival.

Conclusions: The study demonstrates that RDH warrants careful attention to the possible presence of a structural cardiac anomaly, especially left-sided obstructive lesions. A diagnosis of RDH is best supported by a combination of the RV Z-score and RV/LV ratio. Most of the fetuses with RDH and structurally normal hearts had favorable outcomes.

Key words: Fetal Echocardiography; Prenatal Diagnosis; Right Ventricle; Z-score

INTRODUCTION

Congenital heart disease (CHD) is the most frequent congenital disability in China, affecting approximately 7–10 newborns per thousand live births. Fetal echocardiography (FE) is the primary tool for making a detailed diagnosis and evaluating fetal cardiovascular pathology from the late first trimester until term.^[1,2] Since the introduction of FE, the accuracy with which CHD can be diagnosed prenatally has improved. Right dominant heart (RDH) is relatively commonly encountered in antenatal imaging.^[3,4] The right ventricle (RV) is the dominant ventricle during *in utero* life. Ventricular disproportion is subjectively defined as any noticeable difference between the RV and the left ventricle (LV). Typically, the RV is wider than the LV.^[5] RDH can occur with a number of cardiac as well as noncardiac anomalies.

Analysis of the enlargement of the right cardiac chamber in the fetus remains a major challenge for sonographers and echocardiographers.

Traditional RV width or RV/LV ratio nomograms have been compiled in some studies, which have typically focused on normal FE examinations.^[5,6] To the best of our knowledge, there are rare studies on evaluating the usefulness of combining the Z-scores of the RV and the RV/LV ratio in

Address for correspondence: Dr. Hao Liang,

Department of Ultrasound, Shandong Provincial Hospital Affiliated to Shandong University, Jinan, Shandong 250021, China
E-Mail: 740579369@qq.com

This is an open access article distributed under the terms of the Creative Commons Attribution-NonCommercial-ShareAlike 3.0 License, which allows others to remix, tweak, and build upon the work non-commercially, as long as the author is credited and the new creations are licensed under the identical terms.

For reprints contact: reprints@medknow.com

© 2017 Chinese Medical Journal | Produced by Wolters Kluwer - Medknow

Received: 31-10-2016 **Edited by:** Peng Lyu

How to cite this article: Feng J, Zhu M, Liang H, Li Q. Prenatal Diagnosis of Right Dominant Heart in Fetuses: A Tertiary Center Experience over a 7-year Period. Chin Med J 2017;130:574-80.

Access this article online

Quick Response Code:



Website:
www.cmj.org

DOI:
10.4103/0366-6999.200544

fetuses suspected of having RDH. Because the accuracy and prognosis of prenatally diagnosed RDH have been scarcely reported in China, in this retrospective series, we presented information on the components of the prenatal diagnosis, fetal characteristics, clinical associations, and implications for prognosis of consecutively referred cases of fetal RDH over a 7-year period.

METHODS

Study populations

All of the fetuses suspected of RDH, either from local primary hospitals pursuing advanced and confirmatory scans or detected by our department between July 2009 and July 2016, were reviewed retrospectively. At present, Chinese guidelines for FE do not require quantitative evaluation of the RV/LV ratio. Therefore, the diagnosis of RDH was based on subjective assessment of the four-chamber view. However, in clinical practice, the diagnosis depends on the level of experience of an echocardiologist and the extent of their knowledge and familiarity with RDH. Therefore, the investigation is a reflection of RDH diagnoses in actual clinical settings. Fetuses of multiple gestations were excluded. If multiple echocardiographic studies were conducted, then the earliest complete study was used. This study was approved by the Ethics Committee at our hospital.

To explore the relationship between RDH and the gestational period, as well as the association between RDH and cardiac structural or functional anomalies, we evaluated patients in two broad categories: according to the gestational age (GA): Group I ($n = 154$, second trimester) and Group II ($n = 298$, third trimester); and according to the FE diagnoses: Group A ($n = 452$, abnormal cardiac structure: fetuses who demonstrated CHD based on intracardiac structural anomalies; abnormal cardiac hemodynamics [e.g., ductal constriction and restrictive foramen ovale]; and arteriovenous malformations [e.g., Galen malformation] were also included in this group) and Group B ($n = 90$, normal cardiac structure: fetuses with no associated cardiac structural anomaly). RDH without or with mild to moderate tricuspid insufficiency, but without significant evidence of tricuspid valve dysplasia, was defined as isolated RDH and was included in Group B. However, RDH due to severe tricuspid insufficiency, irrespective of evidence of tricuspid valve anomalies, was included in Group A. To determine the attribution of tricuspid valve regurgitation belonging to Group A or Group B, the study followed the practical experience about tricuspid insufficiency: although tricuspid insufficiency might be a sign of increased preload, afterload, or cardiac dysfunction, in most cases, mild-moderate tricuspid insufficiency is an isolated transient finding with little temporal and spatial expansion, and it might be physiological.

Data collection

Subjects were identified using outpatient and echocardiography databases. All patients underwent a

detailed FE examination, which included standard planes with color Doppler assessment and was obtained following the guidelines of the International Society of Ultrasound in Obstetrics and Gynecology and other expert guidelines. We measured the maximum width of RV and LV from endocardium to endocardium immediately inferior to the atrioventricular valve annulus at the end of the diastole. The RV/LV ratio was calculated, and the Z-scores of the RV and LV were calculated for different values of femur length (FL).^[6,7] The number of cases with RV width Z-scores above +2 was calculated for each group.^[6,8] RDH was defined as an RV/LV ratio ≥ 1.12 . GA was determined by the 1st day of the last normal menstrual period and confirmed by either a first- or early second-trimester ultrasound scan performed before the 20th week. Postnatal infant cardiac diagnoses were reviewed when available. Excluding fetuses that were lost to follow-up or terminated, all the other liveborn fetuses were delivered at our hospital. The period of postnatal follow-up ranged from <24 h to >6 years. We examined RDH of the fetuses in Group B to investigate the clinical features of RDH without cardiac structure anomalies.

Statistical analysis

All statistical analyses were performed with SPSS software (version 18.0, SPSS Inc., Chicago, IL, USA). Differences in categorical variables were assessed by the Chi-square exact test or Fisher's exact test. An independent Student's *t*-test or Mann-Whitney *U*-test was chosen to evaluate the continuous variables for parametric or nonparametric nature of the data, respectively. Univariate and multivariable logistic regression was used to evaluate the impact of different binary variables on survival. The odds ratios (ORs) and 95% confidence intervals (CIs) were calculated. All statistical analyses were two-sided and $P < 0.05$ was considered to indicate statistical significance.

RESULTS

Baseline characteristics of the subjects

Echocardiograms were performed in 515 fetuses (762 examinations) suspected of having RDH during the study period. After excluding repeated examinations of single pregnancies (198), incomplete variables (14), RV/LV ratios < 1.12 (23), and multiple gestation (33 fetuses, 75 examinations), a total of 452 FE examinations were used for the final analysis. This represented 1.17% of all fetuses scanned by our department. Figure 1 shows the RV/LV ratio distribution in all 452 scans. Of these, the mean GA was 30.2 ± 3.3 weeks. The mean GA was 23.6 ± 2.8 weeks for Group I ($n = 154$, 34.1%) and 33.6 ± 3.6 weeks ($n = 298$, 65.9%) for Group II. Of the 452 fetuses scanned, 362 (80.1%) comprised Group A, while 90 (19.9%) comprised Group B. In total, 89 (19.7%) fetuses exhibited an RV width Z-score ≥ 2 .

Heart disease distribution

The details of the cardiac diagnoses are shown in Figure 2, and the heart diseases associated with an RV width

Z-score ≥ 2 are shown in Figure 3. Of the enrolled women, the three most common diagnoses on echocardiogram were left-sided obstructive lesions, isolated RDH, and ductal constriction, which accounted for nearly 50% of the diagnoses of RDH typically encountered in our clinical practice. Of the fetuses with an RV Z-score ≥ 2 , the most common abnormality was also left-sided obstructive lesions, followed by ductal constriction and tricuspid insufficiency. These conditions accounted for more than 65% of the diagnoses of RDH in fetuses with RV width Z-scores $>+2$.

Subgroups comparisons

Baseline characteristics of the Z-scores of the RV and LV and the RV/LV ratio in Group I and II are presented in Table 1. Fetuses in Group II exhibited significantly higher RV Z-scores (1.626 [0.450, 3.195] vs. 1.104 [0.004, 2.348],

$P < 0.001$) and RV/LV ratios (1.435 [1.136, 2.893] vs. 1.236 [1.127, 2.339], $P = 0.002$) than those in Group I. However, no significant difference was observed in mean LV Z-scores (0.094 [-0.013, 1.021] vs. 0.078 [-0.005, 0.520], $P = 0.783$) between Group I and Group II. The differences in the ventricular Z-scores and RV/LV ratios between Groups A and B are summarized in Table 2. Fetuses in Group A exhibited significantly higher RV Z-scores (1.553 [0.526, 2.870] vs. 0.814 [0.003, 2.432]) and RV/LV ratios (1.309 [1.137, 2.572] vs. 1.168 [1.324, 2.188]) than those in Group B. No significant difference was found in mean LV Z-scores (0.103 [-0.049, 1.034] vs. 0.082 [-0.093, 1.005]) between Groups A and B. The RV Z-scores that exceeded the +2 cutoff were analyzed, and significant differences were found between Groups I and II as well as between Groups A and B (14.3% vs. 22.5%, $P = 0.038$; 21.5% vs. 12.2%, $P = 0.046$).

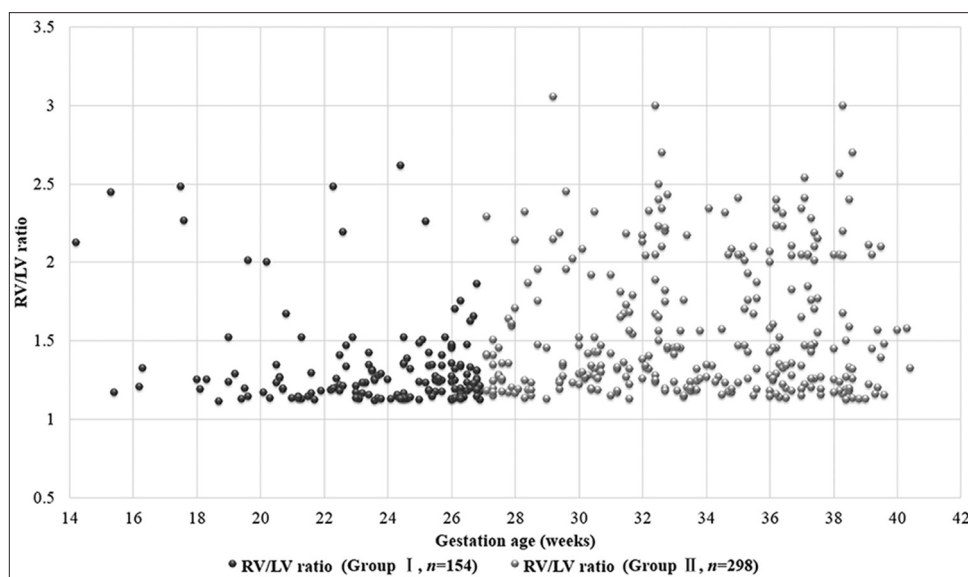


Figure 1: RV/LV ratio measurements and gestational age for Group I (second trimester, black dot) and Group II (third trimester, gray dot) fetuses. RV: Right ventricle; LV: Left ventricle.

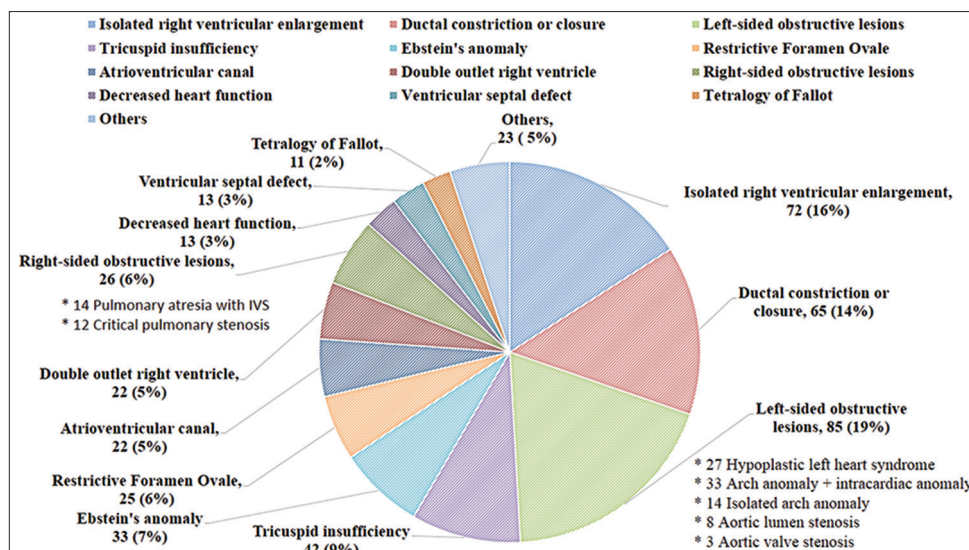


Figure 2: Breakdown of types of RDH diagnoses seen in the study subjects ($n = 452$). RDH: Right dominant heart.

Perinatal follow-up

Fifty-five (12.2%) of the 452 fetuses were lost to follow-up, and 149 (33.0%) terminations of pregnancy occurred. The perinatal outcomes according to diagnoses are presented in Figure 4. The highest termination rate occurred with left-sided obstructive lesions (64/84, 76.2%). Excluding pregnancies that were lost to follow-up or terminated, 50 (20.2%) perinatal mortalities occurred, and 198 (79.8%) fetuses survived. The highest perinatal mortality rate occurred in cases of reduced heart function (4/6), and the lowest perinatal mortality rate occurred in cases with ventricular septal defects (0/11). Follow-up data were obtained in 328 of the 452 fetuses (55 lost to follow-up and 69 rejected autopsies) through postnatal echocardiograms, magnetic resonance imaging findings, surgical reports, or autopsies. The antenatal echocardiogram was accurate in 319 fetuses (97.3%) during the study (the most important anomaly diagnosed was compared). The missed diagnoses included four ventricular septal defects (three perimembranous and

one muscular), one total anomalous pulmonary venous drainage, and one coarctation of the aorta. Two false positive diagnoses involved fetuses with a structurally normal heart that were suspected of having coarctation of the aorta. Two discrepant diagnoses included one pulmonary atresia that was interpreted as truncus arteriosus communis and one critical pulmonary stenosis diagnosed as pulmonary atresia.

A total of 248 fetuses were included in the analysis of perinatal survival. Univariate logistic regression analyses were used to determine the effect on survival of the following parameters: indications for diagnosis before the third trimester, an RV Z-score $\geq +2$, and abnormal cardiac structure. Variables with a value of $P < 0.05$ (RV Z-score $\geq +2$ and abnormal cardiac structure) were considered for inclusion in a forward stepwise multivariable logistic regression model. These parameters were not significantly associated with perinatal survival (adjusted ORs of 0.76 [95% CI, 0.54–1.12] and 0.97 [95% CI, 0.89–1.37], respectively).

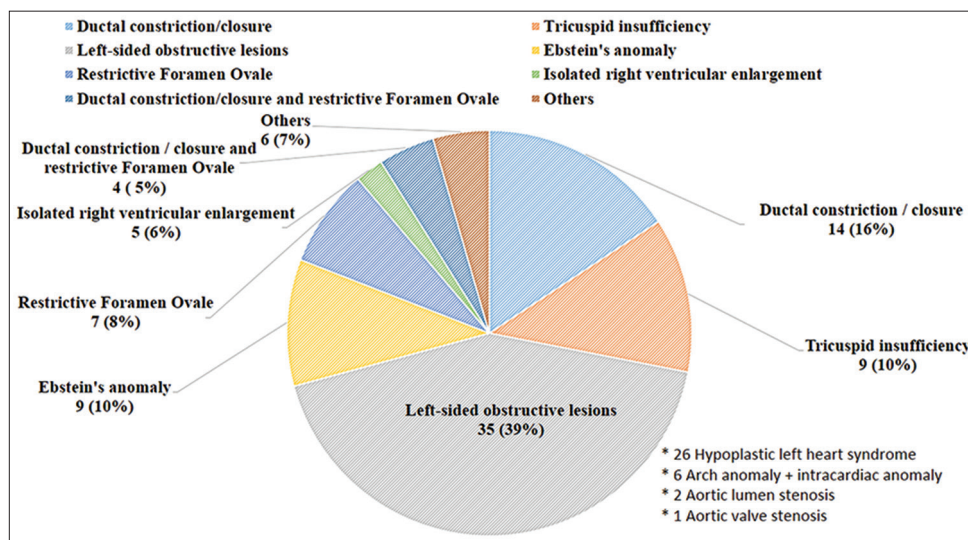


Figure 3: Breakdown of types of RDH diagnoses in the fetuses with RV Z-score ≥ 2 ($n = 89$). RDH: Right dominant heart; RV: Right ventricle.

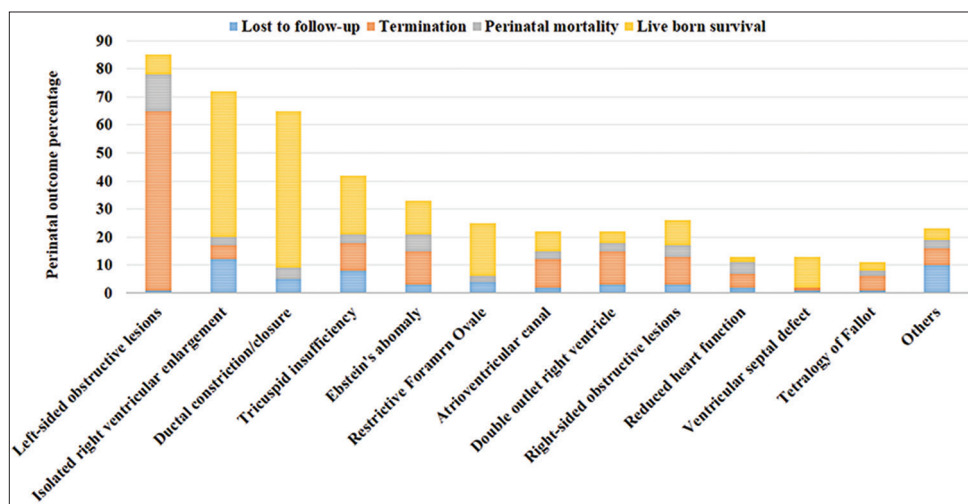


Figure 4: Perinatal outcome according to disease distribution at diagnosis.

Postnatal follow-up of Group B

The clinical features of Group B are presented in Table 3. Isolated RDH constituted the most important component of Group B (72/90, 80.0%). However, the proportion of RV Z-scores that exceeded the +2 cutoff was small (5/72, 6.9%). Late 1-month follow-up showed that 52 perinatal survivors had RV Z-scores <2, except for four infants with neonatal persistent pulmonary hypertension (NPPH). At the 1-year follow-up, 51 infants were alive and one baby had died at 2 months secondary to NPPH.

DISCUSSION

In recent years, enlargement of the right cardiac chambers has drawn attention from sonographers and echocardiologists in the field of fetal cardiology. Although previously published studies^[3,8] have concluded that cardiac asymmetry with right dominance is an important indirect sign of the presence of left heart obstruction, the phenomenon of RDH might also be observed with other cardiac abnormalities or might be found in a structurally normal heart. Currently, Chinese medicine is receiving international attention due to the fragile doctor–patient relationship. Violence against medical staff has reportedly increased in recent years.^[9] For this reason, sonographers in China are under tremendous pressure

not to miss a diagnosis. It is increasingly common to find diagnostic terms such as “right-to-left disproportion” or “asymmetry phenomenon” in ultrasound reports. Although some fetuses exhibited an RV/LV ratio <1.12 ($n = 23$), nearly 70% of the 452 fetuses with RDH were initially identified by community obstetric ultrasonographers. This occurred because FE is performed in primary hospitals in Shandong province, and our center serves as a major referral facility for FE in our area.

To evaluate RDH, we should not only focus on the RV width or length but also focus on the growth of the RV and LV change with GA. Use of the RV/LV ratio might be more advantageous because it is independent of fetal size. However, the RV/LV ratio might amplify the ventricular discrepancy compared to the individual fetal cardiac chamber Z-score. Therefore, it is more useful to combine the RV Z-score and RV/LV ratio to confirm the presence of right ventricular asymmetry. It is widely accepted that the Z-score increases the accuracy of echocardiographic assessments of fetal cardiomegaly. A Z-score of +2 was chosen because it corresponds to a measurement that is 2 standard deviations above the mean (corresponding to the 97.7 and 2.3 percentiles). Furthermore, we calculated the Z-score using normative data adjusted to the FL from

Table 1: Gestational age, RV/LV ratio, RV width Z-score, and LV width Z-score of Group I and Group II

Items	Group I ($n = 154$)	Group II ($n = 298$)	Statistical values	P
Gestational age (weeks)	23.6 ± 2.8	33.6 ± 3.6	2.84*	0.005
RV/LV ratio	1.236 (1.127, 2.339)	1.435 (1.136, 2.893)	-2.81†	0.002
RV width Z-score	1.104 (0.004, 2.348)	1.626 (0.450, 3.195)	-16.45†	<0.001
LV width Z-score	0.078 (-0.005, 0.520)	0.094 (-0.013, 1.021)	-0.22†	0.783

Data are shown as mean ± SD or median (P_{25} , P_{75}). *Independent Student's *t*-test, †Mann-Whitney *U*-test. RV: Right ventricle; LV: Left ventricle; SD: Standard deviation.

Table 2: Gestational age, RV/LV ratio, RV width Z-score, and LV width Z-score of Group A and Group B

Items	Group A ($n = 362$)	Group B ($n = 90$)	Statistical values	P
Gestational age (weeks)	25.7 ± 4.3	24.4 ± 3.1	0.56*	0.293
RV/LV ratio	1.309 (1.137, 2.572)	1.168 (1.324, 2.188)	-2.08†	0.047
RV width Z-score	1.553 (0.526, 2.870)	0.814 (0.003, 2.432)	-2.63†	0.014
LV width Z-score	0.103 (-0.049, 1.034)	0.082 (-0.093, 1.005)	-0.65†	0.674

Data are shown as mean ± SD or median (P_{25} , P_{75}). *Independent Student's *t*-test, †Mann-Whitney *U*-test. RV: Right ventricle; LV: Left ventricle; SD: Standard deviation.

Table 3: Clinical features and outcomes of fetuses in Group B

Items	RV Z-score RV/LV ratio	Lost to follow-up	Termination	Perinatal mortality	IUGR	RV Z-score ≥ 2		
						Fetuses	1-month	1-year
Isolated RDH ($n = 72$)	1.332 (-0.006–2.256)	12 (16.7)	5 (6.9)	3 (5.5)	12 (16.7)	5 (6.9)	4 (7.7)*	None; A/W ($n = 51$) One death†
	1.584 (1.130–2.368)							
Reduced heart function ($n = 13$)	1.670 (1.215–2.751)	2 (15.4)	5 (38.5)	4 (66.7)	1 (7.7)	4 (3.1)	1 (16.7)‡	None; A/W ($n = 1$) One death§
	1.653 (1.127–2.247)							
Arrhythmia ($n = 5$)	1.475 (-0.002–2.007)	None	None	None	None	2 (40.0)	1 (20.0)	None; A/W ($n = 5$)
	1.194 (1.121–1.337)							

*Four babies all with NPPH; †Died at 2 months secondary to NPPH; ‡One baby with persistent ductus arteriosus; §Died at 4 months due to heart failure. Data are shown as median (range) or n (%). Group B: Fetuses with no associated abnormal cardiac structure. RDH: Right dominant heart; RV: Right ventricle; LV: Left ventricle; IUGR: Intrauterine growth restriction; A/W: Alive and well; NPPH: Neonatal persistent pulmonary hypertension.

a Chinese population for two reasons. First, FL has been reported to provide the highest correlation coefficient with the most cardiovascular dimensions, and second, ethnic differences are associated with different intrauterine growth rates.^[6,10,11] In some previous studies that have quantitatively assessed the RV/LV ratio,^[12,13] investigators chose an RV/LV ratio of 1.2 as the cutoff for RDH. However, there were studies reported an average upper limit of the RV/LV ratio of other different data.^[14,15] We defined RDH as an RV/LV ratio of 1.12 or greater for three reasons. First, we aimed to avoid missing mild ventricular asymmetry. Second, we chose the value based on clinical parameters in the Chinese population to eliminate the effect of ethnic differences. Third, we aimed to report the actual spectrum of RDH in our daily work in a comprehensive manner.^[16,17]

In the study, an analysis was performed on the relationship between the diagnosis of RDH and the distribution of heart disease. We also analyzed RDH according to the GA at diagnosis and the parameters used. Approximately, one-third of our RDH cases were diagnosed during the second trimester. Most of the women received confirmatory scans during their third trimester. These same proportions were reported by Peng *et al.*^[12] and Jung *et al.*^[18] Moreover, the RV width Z-score and RV/LV ratio in the third-trimester group were significantly different from those in the second-trimester group. The RV/LV ratio has been most commonly noted in association with gestation age, it decreases initially, and, starting at 24 gestational weeks, it continuously increased up to 38 weeks. All changes were minimal and clinically nonsignificant.^[5]

The obvious difference between Group I and Group II might have occurred because ductal constriction/closure and restrictive foramen ovale were detected primarily in the third trimester and attributed to almost one-fifth of the diagnoses of RDH. With the exception of fetuses with ductal constriction/closure and restrictive foramen ovale in Group II, no obvious differences were observed in the RV Z-score and RV/LV ratio between Groups I and II. Consistent with the results reported by Jung *et al.*^[18] and Wei *et al.*,^[19] left-sided obstructive lesions were most frequently observed in fetuses with RDH and also comprised the largest percentage of fetuses with RV Z-scores ≥ 2 . Group B comprised fetuses with RDH without associated structural anomalies, such as isolated RDH, cardiomyopathy, reduced heart function secondary to arrhythmia, or anomalies of unknown etiology. When we compared the RV/LV ratio and RV Z-scores between Groups A and B, it was obvious that the RV Z-scores exhibited greater differences. Thus, notable ventricular asymmetry should prompt careful consideration of the possibility of a cardiac structural anomaly. Of the 90 fetuses in Group B, most exhibited isolated RDH (72/90), with 12 fetuses also showing evidence of intrauterine growth restriction (IUGR). It is widely accepted that a strong link exists between chromosomal abnormalities and IUGR and that IUGR is a potential cause of RDH.^[20,21]

The greatest challenge following a diagnosis of RDH with a structurally normal heart is counseling parents;

this process is more straightforward when clear cardiac structural anomalies are present. Of the fetuses with isolated RDH, five had an RV Z-score ≥ 2 . At the 1-month follow-up examinations, four newborns had an RV Z-score ≥ 2 , all of whom exhibited NPPH. Interestingly, three of the four infants with NPPH were from the group of five fetuses, with an RV Z-score ≥ 2 . This finding indicates a possible correlation between the presence of isolated fetal RDH and abnormal pulmonary vascular resistance, which should be further investigated. Thus, we propose that the presence of clearly defined isolated RDH should alert the clinician to the possibility of NPPH and IUGR. Although the highest perinatal mortality rate occurred in fetuses with reduced heart function (4/6), overall most of the fetuses in Group B had a favorable outcome.

It should be noted that in the study, many patients were lost to follow-up, and nearly one-third underwent terminations. Due to the China's national conditions, inadequacy of the social security system, availability of legal termination at any time during gestation, and poor medical compliance of patients in our developing country, large numbers of patients are lost to follow-up. Furthermore, terminations are inevitable when perinatal clinical research diagnoses indicate fetal abnormalities. At the beginning of this study, we did not exclude the fetuses lost to follow-up or who were terminated to more accurately present the 7-year experience of our center.

The study had several limitations. First, we cannot exclude the limitations of the retrospective design, which resulted in an unequal spread of data across GAs due to the spectrum of RDH diagnoses, with a larger representation of records from third rather than from second-trimester measurements. Second, the Z-scores of the RV and LV were correlated with FL irrespective of the GA or biparietal diameter measurements. This factor could have generated some bias, especially during the third trimester, when the variance between fetuses increases.

In conclusion, the results demonstrate that the presence of RDH warrants careful consideration of the possibility of a cardiac structural anomaly, particularly coexistent left-sided obstructive lesions. The RV Z-score and RV/LV ratio should be combined to support the presence of right ventricular asymmetry. Even though no obvious independent predictors of poor perinatal survival were found in fetuses with RDH and most of the fetuses with RDH and structurally normal hearts had favorable outcomes, a fetus with clearly defined RDH in the absence of cardiac structural anomalies should not be neglected.

Acknowledgments

We gratefully acknowledge all the members involved in the work. We would also like to thank Jie Sun for his statistic evaluation help.

Financial support and sponsorship

Nil.

Conflicts of interest

There are no conflicts of interest.

REFERENCES

1. Nayak K, Chandra GS, Shetty R, Narayan PK. Evaluation of fetal echocardiography as a routine antenatal screening tool for detection of congenital heart disease. *Cardiovasc Diagn Ther* 2016;6:44-9. doi: 10.3978/j.issn.2223-3652.2015.12.01.
2. Yang L, Pei QY, Li YT, Yang ZJ. The application of an anatomical database for fetal congenital heart disease. *Chin Med J* 2015;128:2583-7. doi: 10.4103/0366-6999.166045.
3. Bravo C, Gámez F, Pérez R, Álvarez T, De León-Luis J. Fetal aortic arch anomalies: Key sonographic views for their differential diagnosis and clinical implications using the cardiovascular system sonographic evaluation protocol. *J Ultrasound Med* 2016;35:237-51. doi: 10.7863/ultra.15.02063.
4. Lopes LM, Carrilho MC, Francisco RP, Lopes MA, Krebs VL, Zugaib M. Fetal ductus arteriosus constriction and closure: Analysis of the causes and perinatal outcome related to 45 consecutive cases. *J Matern Fetal Neonatal Med* 2016;29:638-45. doi: 10.3109/14767058.2015.1015413.
5. Gabbay-Benziv R, Turan OM, Harman C, Turan S. Nomograms for fetal cardiac ventricular width and right-to-left ventricular ratio. *J Ultrasound Med* 2015;34:2049-55. doi: 10.7863/ultra.14.10022.
6. Wu LH, Wang N, Xie HN, Du L, Peng R. Cardiovascular Z-scores in fetuses with tetralogy of Fallot. *Ultrasound Obstet Gynecol* 2014;44:674-81. doi: 10.1002/uog.13419.
7. Lee W, Riggs T, Amula V, Tsimis M, Cutler N, Bronsteen R, *et al.* Fetal echocardiography: Z-score reference ranges for a large patient population. *Ultrasound Obstet Gynecol* 2010;35:28-34. doi: 10.1002/uog.7483.
8. Marginean C, Marginean CO, Muntean I, Toganel R, Voidazan S, Gozar L. The role of ventricular disproportion, aortic, and ductal isthmus ultrasound measurements for the diagnosis of fetal aortic coarctation, in the third trimester of pregnancy. *Med Ultrason* 2015;17:475-81. doi: 10.11152/mu.2013.2066.174.rvd.
9. Fayyaz A, Ahmed W. Congenital heart disease screening: Which referral factors are most important? *J Coll Physicians Surg Pak* 2013;23:543-7. doi: 10.29307/JCPSP.543547.
10. Schneider C, McCrindle BW, Carvalho JS, Hornberger LK, McCarthy KP, Daubeney PE. Development of Z-scores for fetal cardiac dimensions from echocardiography. *Ultrasound Obstet Gynecol* 2005;26:599-605. doi: 10.1002/uog.2597.
11. Matthiesen NB, Henriksen TB, Gaynor JW, Agergaard P, Bach CC, Hjortdal VE, *et al.* Congenital heart defects and indices of fetal cerebral growth in a nationwide cohort of 924422 liveborn infants. *Circulation* 2016;133:566-75. doi:10.1161/CIRCULATIONAHA.116.021793.
12. Peng R, Xie HN, Zhu YX, Li LJ, Du L, Zheng J. Prenatal diagnosis of prevalence of the right heart: Associated anomalies and outcome predictors. *J Ultrasound Med* 2014;33:1155-61. doi: 10.7863/ultra.33.7.1155.
13. Zhang D, Zhang Y, Ren W, Sun F, Guo Y, Sun W, *et al.* Prenatal diagnosis of fetal interrupted aortic arch type A by two-dimensional echocardiography and four-dimensional echocardiography with B-Flow imaging and spatiotemporal image correlation. *Echocardiography* 2016;33:90-8. doi: 10.1111/echo.12996.
14. DeVore GR. The prenatal diagnosis of congenital heart disease--a practical approach for the fetal sonographer. *J Clin Ultrasound* 1985; 13: 229-45. doi: 10.1002/jcu.1870130403.
15. Sahn DJ, Lange LW, Allen HD, Goldberg SJ, Anderson C, Giles H, *et al.* Quantitative real-time cross-sectional echocardiography in the developing normal human fetus and newborn. *Circulation* 1980;62: 588-97. doi: 10.1161/01.CIR.62.3.588.
16. Zhang YF, Zeng XL, Zhao EF, Lu HW. Diagnostic Value of fetal echocardiography for congenital heart disease: A systematic review and meta-analysis. *Medicine (Baltimore)* 2015;94:e1759. doi: 10.1097/MD.0000000000001759.
17. Gao JX, Pei QY, Li YT, Yang ZJ. Establishment of a database of fetal congenital heart malformations and preliminary investigation of its clinical application. *Taiwan J Obstet Gynecol* 2015;54:284-9. doi: 10.1016/j.tjog.2015.01.002.
18. Jung E, Won HS, Lee PR, Kim A, Park IS. Clinical implication of isolated right dominant heart in the fetus. *Prenat Diagn* 2007;27:695-8. doi: 10.1002/pd.1756.
19. Wei YJ, Liu BM, Zhou YH, Jia XH, Mu SG, Gao XR, *et al.* Spectrum and features of congenital heart disease in Xi'an, China as detected using fetal echocardiography. *Genet Mol Res* 2014;13:9412-20. doi: 10.4238/2014.November.11.6.
20. Cruz-Lemini M, Crispi F, Valenzuela-Alcaraz B, Figueras F, Sitges M, Bijnens B, *et al.* Fetal cardiovascular remodeling persists at 6 months in infants with intrauterine growth restriction. *Ultrasound Obstet Gynecol* 2016;48:349-56. doi: 10.1002/uog.15767.
21. Akazawa Y, Hachiya A, Yamazaki S, Kawasaki Y, Nakamura C, Takeuchi Y, *et al.* Cardiovascular remodeling and dysfunction across a range of growth restriction severity in small for gestational age infants - Implications for fetal programming. *Circ J* 2016;80:2212-20. doi: 10.1253/circj.CJ-16-0352.