

Research Article



Effect of post space preparation drills on the incidence of root dentin defects

Tháise Ayres Bezerra Zuli ,¹ Orlando Aguirre Guedes ,²
Gislaine Figueiredo Zarza Arguello Gonçalves ,¹ Aurélio Rosa da Silva Júnior ,¹
Álvaro Henrique Borges ,¹ Andreza Maria Fábio Aranha

¹Department of Oral Sciences, School of Dentistry, University of Cuiabá - UNIC, Cuiabá, MT, Brazil

²Department of Endodontics, School of Dentistry, Centro Universitário de Anápolis - UniEvangélica, Anápolis, GO, Brazil



Received: Feb 21, 2020

Revised: May 3, 2020

Accepted: Jun 2, 2020

Zuli TAB, Guedes OA, Gonçalves GFZA,
da Silva Júnior AR, Borges AH, Aranha AMF

*Correspondence to

Andreza Maria Fábio Aranha, DDS, MS, PhD

Associate Professor, Department of Oral
Sciences, School of Dentistry, University of
Cuiabá - UNIC, Av. Manoel José de Arruda,
3100, Bairro Jardim Europa, Cuiabá, MT,
78015-000, Brazil.

E-mail: andreza.aranha@gmail.com

Copyright © 2020. The Korean Academy of
Conservative Dentistry

This is an Open Access article distributed
under the terms of the Creative Commons
Attribution Non-Commercial License ([https://
creativecommons.org/licenses/by-nc/4.0/](https://creativecommons.org/licenses/by-nc/4.0/))
which permits unrestricted non-commercial
use, distribution, and reproduction in any
medium, provided the original work is properly
cited.

Conflict of Interest

No potential conflict of interest relevant to this
article was reported.

Author Contributions

Conceptualization: Aranha AMF, Zuli TAB; Data
curation: Gonçalves GFZA, da Silva Júnior AR,
Borges AH; Formal analysis: da Silva Júnior
AR; Investigation: Zuli TAB; Methodology: Zuli
TAB, Gonçalves GFZA; Project administration:
Aranha AMF; Resources: Aranha AMF;
Supervision: Aranha AMF, Guedes OA; Writing
- original draft: Zuli TAB; Writing - review &
editing: Aranha AMF, Guedes OA.

ABSTRACT

Objectives: This study investigated the incidence of root dentin defects after the use of different post space preparation (PSP) drills.

Materials and Methods: Seventy-two bovine incisors were selected and obtained 14-mm-long root sections. Twelve roots served as controls with no intervention (G1). The 60 root canals remaining were instrumented using the crown-down technique with the ProTaper Next system and obturated using the lateral condensation technique. Specimens were randomly distributed into 5 groups ($n = 12$) according to the operative steps performed: G2, root canal instrumentation and filling (I+F); G3, I+F and PSP with Gates-Glidden drills; G4, I+F and PSP with Largo-Peeso reamers; G5, I+F and PSP with Exacto drill; and G6, I+F and PSP with WhitePost drill. Roots were sectioned at 3, 6, 9, and 12 mm from the apex, and digital images were captured. The presence of root dentin defects was recorded. Data were analyzed by the χ^2 test, with $p < 0.05$ considered to indicate statistical significance.

Results: Root dentin defects were observed in 39.6% of the root sections. No defects were observed in G1. G5 had significantly more cracks and craze lines than G1, G2, and G3 ($p < 0.05$), and more fractures than G1, G2, G3, and G4 ($p < 0.05$). When all root sections were analyzed together, significantly more defects were observed at the 12-mm level than at the 3-mm level ($p < 0.05$).


Conclusions: PSP drills caused defects in the root dentin. Gates-Glidden drills caused fewer root defects than Largo-Peeso reamers and Exacto drills.


Keywords: Cracks; Dentin defects; Post space preparation; Root canal therapy; Vertical root fracture


INTRODUCTION


Severely damaged crowns are often observed in endodontically treated teeth, requiring preparation of the root canal to receive a post in order to promote retention of the crown restoration while maintaining the integrity of the canal walls [1]. Numerous recommendations have been made about the characteristics of post space preparation, including specific techniques for the removal of filling material and root canal enlargement [1,2]. Increased diameters [3] and longer post lengths [2] have been shown not to increase post retention or

ORCID iDs


Thaise Ayres Bezerra Zuli 
<https://orcid.org/0000-0002-2987-0339>

Orlando Aguirre Guedes 
<https://orcid.org/0000-0003-1664-329X>

Gislaine Figueiredo Zarza Arguello Gonçalves 
<https://orcid.org/0000-0002-9195-0268>

Aurélio Rosa da Silva Júnior 
<https://orcid.org/0000-0001-8944-0747>

Álvaro Henrique Borges 
<https://orcid.org/0000-0001-9510-6542>

Andreza Maria Fábio Aranha 
<https://orcid.org/0000-0003-0014-7937>

fracture resistance. In fact, the post space diameter should not exceed one-third of the root diameter [3], and the remaining dentin thickness should not be less than 1 mm [4].

Different techniques have been proposed to remove preexisting root canal filling material in order to create a post space, including the use of chemical solvent, heated instruments, and Largo-Peeso reamers, Gates-Glidden burs, or other types of rotary instruments [5]. Mechanical removal of gutta-percha is efficient and probably the most commonly used technique, but it can result in excessive wear of the root canal walls [1,2,6]. In addition, numerous momentary stress concentrations in dentin may be created during root canal enlargement because of the contact between the instrument and dentin walls [7]. The use of larger [1,8] or stiffer [7] instruments results in more contact with the wall and, therefore, more friction and stress concentration, which is transmitted through the root and may damage the dentin, leading to incomplete cracks or craze lines that may develop into vertical root fractures (VRFs), a clinical complication that may affect long-term tooth survival [9].

Despite the high rates of VRFs in teeth with intraradicular posts [10], little attention has been paid to the effect of post space preparation on the development of dentin defects. In fact, only 1 study [6] has focused on the effect of post space preparation on the formation of root defects. In that study, post space preparation with drills of the Rebuilda post system (VOCO, Cuxhaven, Germany) had a significant impact on crack propagation [6]. As far as we know, no studies have evaluated the effect of other post space preparation drills on the occurrence of root dentin defects. Therefore, the aim of this study was to investigate the incidence of root dentin defects after the use of Gates-Glidden, Largo-Peeso, Exacto, and WhitePost drills for post space preparation. The null hypothesis tested was that the development of root dentin defects would not be affected by 1) the post space preparation drill or 2) the root canal level.

MATERIALS AND METHODS

Sample selection and preparation

A total of 120 freshly extracted bovine mandibular incisors with fully formed roots, which were morphologically similar in size and shape, and single straight root canals with comparable widths, about 9 mm from the apex (measured on radiographs taken from the buccolingual and mesiodistal views) and with a cervical diameter of approximately 1 mm, were selected for this study and stored in distilled water until use. Teeth with calcified or flared canals and anatomic irregularities were discarded. A total of 96 teeth were decoronated with a double-faced diamond disc (KG Sorensen, Barueri, SP, Brazil) operated perpendicular to the longitudinal axis of the teeth, leaving standardized root sections of 14 mm in length. All roots were examined for the presence of preexisting external defects at $\times 20$ magnification (Expert DN; Müller Optronic, Erfurt, Germany), and those presenting any cracks, fractures, or craze lines were excluded and replaced by similar teeth. To simulate the periodontal ligament [11], the roots were covered with a silicone impression material (Aquasil; Dentsply Maillefer, Ballaigues, Switzerland). Specimens were then placed in a polyvinyl chloride pipe (14 \times 20 mm) and embedded in acrylic resin blocks.

Root canal instrumentation and filling

Twelve roots served as controls with no intervention. The 84 root canals remaining were selected for the intracanal interventions. They were explored with sizes 10 and 15 K-files (Dentsply Maillefer), which were inserted passively until their tips became visible at the apical

foramen. A total of 24 roots that showed patency larger than an ISO size 15 file was discarded. The remaining 60 roots were randomly divided into 5 groups, according to the endodontic procedures (instrumentation, filling, and post space preparation) ($n = 12$ per group).

For root canal instrumentation, the cervical and middle thirds of each specimen were prepared sequentially with Gates-Glidden (Dentsply Maillefer) sizes 1 (0.50 mm) and 2 (0.70 mm) until resistance was found on the canal walls. The apical thirds were instrumented to a working length of 13 mm using a crown-down technique with ProTaper Next rotary instruments (Dentsply Maillefer), with a sequence of X1 (size 0.17/0.04), X2 (size 0.25/0.06), X3 (size 0.30/0.07), and X4 (size 0.40/0.06). Each instrument was used for the instrumentation of 3 root canals and operated at a rotational speed of 300 rpm and 2.9 Ncm torque with an endodontic electric motor (X-Smart Plus; Dentsply Maillefer).

At each instrument change, the root canals were irrigated with 3 mL of 1.0% sodium hypochlorite (NaOCl; Pharm, Phloraceae, Cuiabá, MT, Brazil) by using a syringe and a 31-gauge needle (NaviTip; Ultradent, South Jordan, UT, USA). Final irrigation was performed with 3 mL of 17% ethylenediaminetetraacetic acid (EDTA; Biodinâmica, Ibioporã, PR, Brazil) for 3 minutes, with the final 2 minutes under active agitation with an endodontic file, followed by 3 mL of 1.0% NaOCl. The roots were then dried with sterilized paper points (Dentsply Maillefer) and filled with gutta-percha points (Dentsply Maillefer) and AH Plus (Dentsply Maillefer), which was mixed according to the manufacturer's instructions using the lateral condensation technique. Excess gutta-percha and sealer were removed with heated condensers (Paiva; SS White, Rio de Janeiro, RJ, Brazil), and the root canal openings were sealed with temporary cement (White Cimpat; Septodont, São Paulo, SP, Brazil). The specimens were stored at 37°C and 100% humidity for 1 week.

Post space preparation

After the storage period, of the 60 roots that were endodontically treated, 48 were divided into 4 groups (G3–G6; $n = 12$ each), according to the post space preparation protocol.

The temporary restorative material was removed, and heated condensers (Paiva; SS White) were used to remove the initial root canal filling. The post spaces were prepared sequentially until a standardized depth of 9 mm was achieved, leaving 4 mm of gutta-percha in the apical third, according to the manufacturer's instructions. Post space preparation drills of each group were selected, aiming to standardize the apical diameter at about 1.1 mm. The drills were used in a low-speed handpiece (Kavo Ind. Com. Ltda., Joinville, SC, Brazil) at 15,000 to 20,000 rpm. The root canals were irrigated with 1.0% NaOCl after each drill change and dried with sterilized paper points (Dentsply Maillefer).

A single endodontist with 10 years of experience performed all clinical procedures. All roots were stored in distilled water during the experimental procedures in order to avoid dehydration.

The investigated groups, the operative steps, and the post space preparation protocols are presented in **Table 1**. The PSP protocols for the G5 and G6 groups were performed as recommended by the respective manufacturers.

Table 1. Operative steps of the control and experimental groups ($n = 12$) and the post space preparation protocols

Groups ($n = 12$ /each)	Operative steps	Post space preparation protocols (9 mm)	
		Filling removal	Root canal preparation
G1 (Control)	Roots without any intervention.	-	-
G2	Roots subjected to instrumentation and root canal filling.	-	-
G3	Roots subjected to instrumentation, root canal filling, and post space preparation with Gates-Glidden drills (Dentsply/Maillefer, Ballaigues, Switzerland).	Gates-Glidden drill #1 (0.50)*	Gates-Glidden drills #1 (0.50)*, #2 (0.70)*, #3 (0.90)*, #4 (1.10)*
G4	Roots subjected to instrumentation, root canal filling, and post space preparation with Largo Peeso drills (Dentsply/Maillefer, Ballaigues, Switzerland).	Largo Peeso reamer #1 (0.70)*	Largo Peeso reamers #1 (0.70)*, #2 (0.90)*, #3 (1.10)*
G5	Roots subjected to instrumentation, root canal filling, and post space preparation with Exacto drills (Ángelus, Londrina, PR, Brazil).	Heated Paiva condenser #2 (1.20)*	Exacto system: Blue drill #3 (1.10)*
G6	Roots subjected to instrumentation, root canal filling, and post space preparation with WhitePost drills (FGM Produtos Odontológicos, Joinvile, SC, Brazil).	Largo Peeso reamer #2 (0.90)*	WhitePost system: Drill #2 (1.05)*

*Values referring to the diameter of the drill tip in millimeters.

Sectioning and root dentin analysis

The roots were removed from the resin blocks and horizontally sectioned at 3, 6, 9, and 12 mm from the apex with a double-faced diamond disc (4-inch diameter \times 0.012-inch thickness \times 1/2 inch; Arbor, Extec, Enfield, CT, USA) and a low-speed saw under water cooling (Isomet 1000; Buehler, Lake Bluff, IL, USA). The slices were analyzed under a stereomicroscope (Expert DN; Müller Optronic, Erfurt, Germany) at $\times 25$ magnification, and digital images of each section were captured. The occurrence of defects was recorded as “no defect,” “fracture,” and “other defects” [12].

“No defect” was defined as the absence of any type of line in the outer surface of the root and on the inner wall of the root canal. “Fracture” was defined as a line that extended from the root canal space to the outer surface of the root. “Other defects” were defined as all other observed lines that did not extend from the root canal to the external surface of the root, including craze lines (lines extending from the outer surface into the dentin that did not reach the canal lumen), and partial cracks (lines that extended from the canal wall into the dentin without reaching the outer surface of the root) (Figure 1). A total of 48 images were examined in each group. A blinded, previously calibrated examiner analyzed all images. The same examiner read the images twice, with an interval of 1 week between readings. The study design is presented in Figure 2.

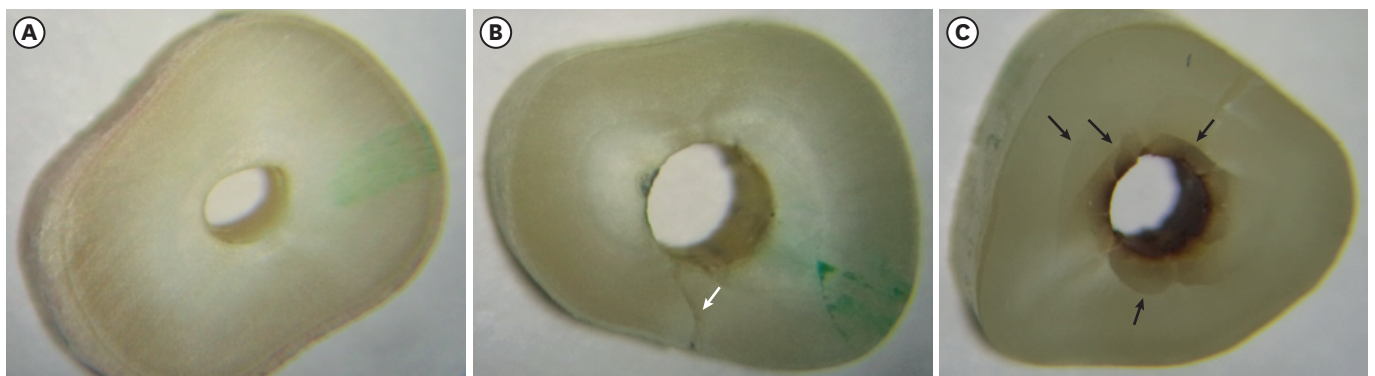


Figure 1. Representative images of root cross-sectional slices and dentin defects: (A) No dentin defects; (B) fracture (white arrow); (C) other defects (black arrows).

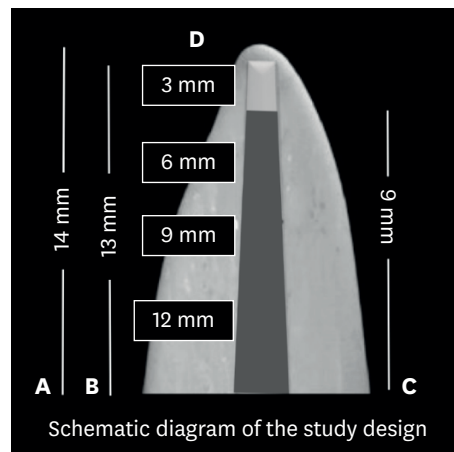


Figure 2. Schematic illustration of the study design: (A) root canal length; (B) working length; (C) post space depth; (D) root cross-sections.

Statistical analysis

The results were expressed as the number and percentage of roots with defects in each group. The χ^2 test was used to compare the presence of defective roots between the control and experimental groups using Minitab, version 17.0 (Minitab Inc., State College, PA, USA). The level of significance was set at $p < 0.05$. Intraexaminer agreement in the reading of images was evaluated by the kappa coefficient in 10% of the sample.

RESULTS

The kappa value was 0.83. Of the 288 slices that were analyzed, 114 (39.6%) had root dentin defects (other defects and fractures). No defects were observed in G1 (root canals without any intervention). When considering the formation of other defects, G5 had significantly more cracks and craze lines than G1, G2, and G3 ($p < 0.05$), but not significantly more than G4 and G6 ($p > 0.05$) (Table 2). When considering fracture formation, G5 had significantly more defects than G1, G2, G3, and G4 ($p < 0.05$), but not significantly more than G6 ($p > 0.05$) (Table 3).

When all groups and all defects were considered, significantly more defects were observed at the 12-mm level than at the 3-mm level ($p < 0.05$) (Table 2). Regarding root fractures, no significant difference was observed between root canal levels ($p > 0.05$) (Table 3).

Table 2. Number and percentage of other defects in the different cross-section slices.

Groups*	Root levels				Total
	3 mm	6 mm	9 mm	12 mm	
G1	0 (0%) ^{A,a}	0 (0%) ^{A,a}	0 (0%) ^{A,a}	0 (0%) ^{A,a}	0 (0%) ^A
G2	0 (0%) ^{A,a}	1 (8.33%) ^{A,a}	2 (16.67%) ^{AC,a}	3 (25%) ^{AB,a}	6 (1.25%) ^{AB}
G3	2 (16.67%) ^{A,a}	3 (25%) ^{AB,a}	4 (33.33%) ^{AC,a}	5 (41.67%) ^{B,a}	14 (29.1%) ^{BC}
G4	9 (75%) ^{B,a}	7 (58.33%) ^{B,a}	8 (66.67%) ^{BCD,a}	8 (66.67%) ^{BC,a}	32 (66.6%) ^D
G5	3 (25%) ^{AB,a}	7 (58.33%) ^{B,ab}	12 (100%) ^{D,c}	11 (91.67%) ^{C,bc}	33 (68.7%) ^D
G6	4 (33.33%) ^{AB,a}	4 (33.33%) ^{AB,a}	6 (50%) ^{BC,a}	9 (75%) ^{BC,a}	23 (47.9%) ^{CD}
Total	18 (25%) ^a	22 (30.56%) ^{ab}	32 (44.44%) ^{ab}	36 (50%) ^b	108 (37.5%)
<i>p</i> -value [†]	< 0.001	0.004	< 0.001	< 0.001	< 0.001

*G1, control; G2, root canal instrumentation and filling; G3, post preparation with Gates-Glidden drills; G4, post preparation with Largo Peeso reamers; G5, post preparation with Exacto drill; G6, post preparation with WhitePost drill. [†]Capital letters compare groups in vertical columns and lowercase letters compare groups in horizontal rows.

Table 3. Number and percentage of root fractures in the different cross-sectional slices.

Groups*	Root levels				Total	p-value†
	3 mm	6 mm	9 mm	12 mm		
G1	0 (0%) ^{A,a}	0 (0%) ^{A,a}	0 (0%) ^{A,a}	0 (0%) ^{A,a}	0 (0%) ^A	1.000
G2	0 (0%) ^{A,a}	0 (0%) ^{A,a}	0 (0%) ^{A,a}	0 (0%) ^{A,a}	0 (0%) ^A	1.000
G3	0 (0%) ^{A,a}	0 (0%) ^{A,a}	0 (0%) ^{A,a}	0 (0%) ^{A,a}	0 (0%) ^A	1.000
G4	0 (0%) ^{A,a}	0 (0%) ^{A,a}	0 (0%) ^{A,a}	0 (0%) ^{A,a}	0 (0%) ^A	1.000
G5	0 (0%) ^{A,a}	0 (0%) ^{A,a}	2 (16.67%) ^{A,a}	2 (16.67%) ^{A,a}	4 (8.33%) ^B	1.000
G6	0 (0%) ^{A,a}	0 (0%) ^{A,a}	1 (8.33%) ^{A,a}	1 (8.33%) ^{A,a}	2 (4.17%) ^B	0.225
Total	0 (0%) ^a	0 (0%) ^a	3 (4.17%) ^a	3 (4.17%) ^a	6 (2.10%)	0.225
p-value†	1.000	1.000	0.199	0.199	0.014	

*G1, control; G2, root canal instrumentation and filling; G3, post preparation with Gates-Glidden drills; G4, post preparation with Largo Peeso reamers; G5, post preparation with Exacto drill; G6, post preparation with WhitePost drill. †Capital letters compare groups in vertical columns and lowercase letters compare groups in horizontal rows.

DISCUSSION

This study aimed to investigate whether the occurrence of root dentin defects is influenced by the type of drill used for post space preparation. To the authors' knowledge, no other study has focused on the formation of root dentin defects after PSP with Largo-Peeso reamers and Gates-Glidden, Exacto, and WhitePost drills. The results showed that both the post space preparation protocol and root canal level influenced the development of root dentin defects. Therefore, the null hypotheses were rejected.

Although various methods have been proposed to investigate the effect of intracanal procedures on the formation of dentin defects, such as thermography, optical coherence tomography, and scanning electron microscopy [13], much of the knowledge of this topic is derived from investigations using micro-computed tomography (micro-CT) [14-18] and/or root-sectioning methods [11,12,19-21]. Micro-CT is an accurate, non-destructive 3-dimensional method [17] that allows quantitative and qualitative volumetric assessments of specimens before and after any intracanal procedure [16,22]. With this method, each tooth may serve as its own control [17]. In addition, hundreds of dentin slices can be analyzed per specimen, thereby enabling the full extension of the defects to be tracked [13,14]. However, it is expensive, time-consuming, and often unavailable to the general research community [24]. Furthermore, Pedullà *et al.* [21] suggested that the increase in temperature from the use of high-resolution micro-CT scans may provoke dehydration and subsequently an increase in existing defects, which may affect the results of the study. Lim *et al.* [23], however, observed that the resolution and contrast of micro-CT are not always enough to identify all root defects because of the restricted signal-to-noise ratio. Root-sectioning methods allow direct inspection by optical microscopy of defects in slices proceeding from several levels of the canal [12,15]. Swift results are provided without the need for post-processing and much smaller datasets are required, making it possible to screen many samples in a short time [24]. This simplifies tracking the appearance and evolution of cracks involving sample motion, which is not possible with micro-CT [24]. However, sectioning methods have some limitations, such as their destructive nature [21,22] and 2-dimensional, single-moment observations of only a few slices per tooth, which may result in the chance of missing some previous defects along the root [15]. Furthermore, it is not possible to assess the precise moment at which the defect is developed [14]. Unfortunately, an ideal experimental model to evaluate the presence of dentin defects has not yet been established [18,22]. Therefore, more attention should be drawn to the development of new methods to understand the phenomenon of dentin defect formation better.

An understanding of the cause-and-effect relationship between endodontic procedures and dentin defect formation has been obtained from studies using teeth with several root and root canal morphologies, such as lower incisors [16], premolars [12,18,24] and molars [11,15,25], and upper premolars [26] and incisors [27]. This fact makes it difficult to compare the results [21,27], since there is wide variation in tooth anatomy, such as canal length, width, and shape; dentin hardness; calcification; size and location of the apical constriction and angle; radius length; and the location of curvatures [28]. Another aspect that deserves attention is that previous publications examining root defects have not provided appropriate data on the hydration conditions of the teeth (storage conditions and time), tooth condition before extraction, trauma, age and sex of the donors, and variables related to the lifetime of the tooth *in vivo* (masticatory function, excursive interferences, or any parafunctions) [13,17,29].

In this study, we used bovine teeth since human teeth are difficult to obtain for academic dental investigation [29]. Bovine teeth are easier to handle due to their dimensions, enable better uniformity in terms of age and root canal space, and decrease the possibility of transmitting diseases [30]. It is worth noting that the use of bovine teeth makes it possible to unify different features and to use a lower number of animals, reducing confounding factors related to dentin [30]. Previous investigations have also demonstrated that human and bovine teeth have similar biological, chemical, and physical properties [31], which could make bovine teeth possible substitutes for human teeth in root dentin defect evaluations. In the current study, bovine incisors with straight canals were chosen to permit the use of tapered post space preparation drills, as the effect of these drills on the development of root dentin defects has been inadequately investigated [6]. When choosing bovine teeth, older teeth were desirable due to the possibility of a greater morphologic resemblance to human teeth [31].

For all teeth included in this study, the outer surface of the roots was inspected preoperatively with an operative microscope to assess the presence of cracks and/or fractures. One could argue that some defects might have been internal and not visible externally. However, no defects were noticed in the teeth with no intervention (control group), which is consistent with several studies that used a similar method [19,27,32]. Therefore, it is reasonable to interpret all root dentin defects observed in the present study as having resulted from the intracanal procedures, rather than from the sectioning method [12]. It is important to consider that no auxiliary tools were used to improve the visualization of defects. Recent studies have demonstrated that illumination conditions may influence the capacity to detect root dentin defects [18,21,22]. Coelho *et al.* [22] observed that the use of light-emitting diode (LED) transillumination enhances the visualization of dentin defects, especially in control groups (uninstrumented roots). This is one of the limitations of the present study, and further sectioning studies should be performed with the aid of LED transillumination to reassess the potential of dentin defect formation resulting from different intracanal procedures.

It has been demonstrated that specimen storage conditions may affect the biomechanical properties of root dentin [14,15,22,24]. Therefore, in the present study, all specimens were kept in distilled water throughout the entire experiment [15,24,27]. In addition, to reproduce periodontal ligament and bone and consequently stress absorption [12], the roots used in the experiment were covered with a silicone impression material and embedded in acrylic resin blocks [11,21,33]. Although it is very difficult to imitate the complexity of the anatomic and biologic aspects of the periodontal ligament, and no artificial material can accurately reproduce its viscoelastic properties [12], periodontal ligament reproduction is important since it may influence the results of studies investigating the effects of intracanal forces on

the formation of root dentin defects [33]. Additionally, in the present study, the specimens were equally allocated among the groups according to their root canal widths at the 9-mm level [21,33]. A disparity in dentin thickness would cause important variations in strength, and hence in response to stress distribution, during intracanal procedures [26]. Moreover, uniformity was obtained in the groups by including only teeth with a canal width near the apex consistent with a size 15 K-file and leaving roots of about 14 mm in length [21].

Previous studies have shown a clear correlation between root canal instrumentation and the development of root dentin defects [7,11,12,15,17,19-22,27], attributing the harmful effects to the instrument's cross-sectional geometry, alloy, heat treatment, cutting efficiency, size, tip configuration, variable pitch and taper, flute form, number of instruments used, and kinematics [7,14,17,21,25]. In this study, root canal instrumentation was performed using the ProTaper Next system, which works in continuous rotation and consists of 5 files [25]. ProTaper Next instruments are made of the M-Wire alloy, which is produced by a pioneering thermal treatment protocol and has the advantage of instrument flexibility and enhanced resistance to cyclic fatigue [25]. Its off-centered rectangular projection creates a swaggering movement, which reduces the screw effect and unsafe taper lock by reducing contact between the instrument and root canal wall [14]. These instrument characteristics may result in less stress generation inside the root canal, and hence less damage to root dentin [34].

The irrigants used during root canal preparation can also induce root dentin defects [32]. There is evidence that high concentrations of NaOCl can alter the elastic modulus and flexural strength of root canal dentin [26,35]. Ari *et al.* [35] observed reduced root dentin microhardness after contact with NaOCl at concentrations of 2.5% and 5.25%, but not at low concentrations. In this study, 1.0% NaOCl solution was employed for irrigation to reduce the possible alterations to the mechanical characteristics of dentin during intracanal procedures [20].

Despite the extensive investigations on the impact of root canal filling procedures on defect formation [12,15,19], contradictory findings have been reported on the influence of the lateral compaction technique [12,15,19,26]. Shemesh *et al.* [12] assessed the occurrence of dentin defects after root filling with lateral compaction or passive compaction techniques and reported a higher incidence of dentin defects in teeth filled by lateral compaction. Adorno *et al.* [26] evaluated the effects of instrumentation and filling (lateral compaction associated or not with vertical compaction) on crack initiation and propagation in apical dentin and reported a significant effect of root canal filling only on crack propagation, with no significant difference between the 2 techniques in crack propagation. Shemesh *et al.* [19] compared the incidence of dentin defects after root canal instrumentation, lateral compaction, and continuous wave compaction of gutta-percha, and no difference was observed in the occurrence of defects between the 2 filling procedures. De-Deus *et al.* [15] reported that the cold lateral compaction technique was not linked to the development of new root defects. In this study, the lateral condensation technique was the method of choice for root canal obturation, since it is broadly used to fill the root canal system, does not necessitate an exceptional or expensive apparatus, and is considered safe in controlling the apical extension of the filling [12,19]. The results of the present study showed a lower incidence of defects (12.5%) than those of previous studies, which demonstrated an occurrence of defects after root canal instrumentation and filling ranging from 15.99% to 30.00% [15,19], which may be explained by the difference among studies in the methods used [13].

Different drills have been developed and suggested for post space preparation [6,36]. In the present study, Gates-Glidden #1, #2, #3, and #4 drills and Largo-Peeso #1, #2, and #3 reamers were compared with Exacto #3 and WhitePost #2 drills. Only drills that act in the straight portion of the canal were selected. Gates-Glidden drills and Largo-Peeso reamers were chosen because they are widely used in preflaring and post space preparation [8,36], while Exacto and WhitePost drills were chosen because of their use during the placement of a fiber post inside the root canal, and because no studies have investigated the effects of these burs on dentin defect formation. According to their manufacturers, Exacto and WhitePost drills consist of stainless-steel drills, with a conical shape and inactive tips. The main differences between these drills are related to their cervical and tip diameters. The Exacto drill has a tip diameter of 1.10 mm and a cervical diameter of 1.60 mm, whereas the WhitePost drill has diameters of 1.05 mm and 1.80, respectively. The results revealed that Exacto drill and Largo-Peeso reamers promoted significantly more “other” types of defects than Gates-Glidden drills, while no significant differences were noted among the Largo-Peeso reamers, Exacto drill, and WhitePost drill (**Table 2**). Furthermore, teeth instrumented with the Exacto and WhitePost drills were the only ones in which root fractures were observed (**Table 3**). These results may be credited to the highly-tapered design of Exacto and WhitePost drills, to the stiffness of the larger instruments [6,7], and to unnecessary dentin removal [36]. It has been demonstrated that fiber post space preparation drills are more aggressive than other instruments [6]. It is also noteworthy that the recommendations for Exacto post space preparation involve the use of heated devices to remove part of the root canal filling. The use of these instruments, even with light pressure, can promote higher coronal stress concentration, which could lead to a higher risk of dentin defect development [26,37]. It will be useful to evaluate whether comparable root dentin defects will be present after post space preparation with drills having different features. Moreover, professionals must be conscious of the possibilities of harm during post space preparation with Exacto drill.

Although dentin defects were observed at all 4 levels of the root canal, a higher number of root fractures and other defects occurred coronally than apically. This is consistent with the results of previous studies [24,27,37] and may be attributed to the increase in tensile stress and in the regions of stress concentration associated with post space preparation. It is important to highlight that PSP may cause root dentin defects, which can remain confined inside to the root canal walls. Unfortunately, the root-sectioning method used in the present study does not provide information about the root canal lumen [13]. Even though this *ex vivo* study did not reflect clinical situations, the results may explain some failures observed in endodontically treated teeth with intraradicular posts. Nevertheless, further studies using rapid, reliable, and accurate experimental methods are essential to obtain a better knowledge of the influence of different PSP protocols on the formation of root dentin defects.

CONCLUSIONS

Post space preparation with Largo-Peeso reamers and Gates-Glidden, Exacto, and WhitePost drills induced damage to the root dentin. However, Gates-Glidden drills tended to cause fewer root dentin defects than other drills. A higher number of root dentin defects occurred coronally than apically.

REFERENCES

1. Ghoddusi J, Bagherpour A, Mahmudabadi F, Forghani M, Sarmad M. Residual dentin thickness of bifurcated maxillary premolars following two post space preparation methods. *Iran Endod J* 2013;8:94-98.
[PUBMED](#)
2. Cecchin D, Farina AP, Guerreiro CA, Carlini-Júnior B. Fracture resistance of roots prosthetically restored with intra-radicular posts of different lengths. *J Oral Rehabil* 2010;37:116-122.
[PUBMED](#) | [CROSSREF](#)
3. Nergiz I, Schmage P, Ozcan M, Platzer U. Effect of length and diameter of tapered posts on the retention. *J Oral Rehabil* 2002;29:28-34.
[PUBMED](#) | [CROSSREF](#)
4. Caputo AA, Standlee JP. Pins and posts--why, when and how. *Dent Clin North Am* 1976;20:299-311.
[PUBMED](#)
5. Alberto Rubino G, de Miranda Candeiro GT, Gonzales Freire L, Faga Iglecias E, de Mello Lemos É, Luiz Caldeira C, Gavini G. Micro-CT evaluation of gutta-percha removal by two retreatment systems. *Iran Endod J* 2018;13:221-227.
[PUBMED](#) | [CROSSREF](#)
6. Çapar ID, Uysal B, Ok E, Arslan H. Effect of the size of the apical enlargement with rotary instruments, single-cone filling, post space preparation with drills, fiber post removal, and root canal filling removal on apical crack initiation and propagation. *J Endod* 2015;41:253-256.
[PUBMED](#) | [CROSSREF](#)
7. Kim HC, Lee MH, Yum J, Versluis A, Lee CJ, Kim BM. Potential relationship between design of nickel-titanium rotary instruments and vertical root fracture. *J Endod* 2010;36:1195-1199.
[PUBMED](#) | [CROSSREF](#)
8. Arslan H, Karataş E, Çapar ID, Ozsu D, Doğanay E. Effect of ProTaper Universal, Endoflare, Revo-S, HyFlex coronal flaring instruments, and Gates Glidden drills on crack formation. *J Endod* 2014;40:1681-1683.
[PUBMED](#) | [CROSSREF](#)
9. Chai H, Tamse A. Fracture mechanics analysis of vertical root fracture from condensation of gutta-percha. *J Biomech* 2012;45:1673-1678.
[PUBMED](#) | [CROSSREF](#)
10. Maddalone M, Gagliani M, Citterio CL, Karanxha L, Pellegatta A, Del Fabbro M. Prevalence of vertical root fractures in teeth planned for apical surgery. A retrospective cohort study. *Int Endod J* 2018;51:969-974.
[PUBMED](#) | [CROSSREF](#)
11. Ashwinkumar V, Krithikadatta J, Surendran S, Velmurugan N. Effect of reciprocating file motion on microcrack formation in root canals: an SEM study. *Int Endod J* 2014;47:622-627.
[PUBMED](#) | [CROSSREF](#)
12. Shemesh H, Bier CA, Wu MK, Tanomaru-Filho M, Wesselink PR. The effects of canal preparation and filling on the incidence of dentinal defects. *Int Endod J* 2009;42:208-213.
[PUBMED](#) | [CROSSREF](#)
13. Versiani MA, Souza E, De-Deus G. Critical appraisal of studies on dentinal radicular microcracks in endodontics: methodological issues, contemporary concepts, and future perspectives. *Endod Topics* 2015;33:87-156.
[CROSSREF](#)
14. De-Deus G, Belladonna FG, Souza EM, Silva EJ, Neves AA, Alves H, Lopes RT, Versiani MA. Micro-computed tomographic assessment on the effect of ProTaper Next and Twisted file adaptive systems on dentinal cracks. *J Endod* 2015;41:1116-1119.
[PUBMED](#) | [CROSSREF](#)
15. De-Deus G, Belladonna FG, Silva EJ, Souza EM, Carvalho JC, Perez R, Lopes RT, Versiani MA. Micro-CT assessment of dentinal micro-cracks after root canal filling procedures. *Int Endod J* 2017;50:895-901.
[PUBMED](#) | [CROSSREF](#)
16. About LR, Santos BC, Lopes RT, Viana LA, Scelza MF. Effect of aging on dentinal crack formation after treatment and retreatment procedures: a micro-CT study. *Braz Dent J* 2018;29:530-535.
[PUBMED](#) | [CROSSREF](#)
17. Aksoy Ç, Keriş EY, Yaman SD, Ocak M, Geneci F, Çelik HH. Evaluation of XP-endo Shaper, Reciproc Blue, and ProTaper Universal systems on dentinal microcrack formation using micro-computed tomography. *J Endod* 2019;45:338-342.
[PUBMED](#) | [CROSSREF](#)
18. Shantiaee Y, Dianat O, Mosayebi G, Namdari M, Tordik P. Effect of root canal preparation techniques on crack formation in root dentin. *J Endod* 2019;45:447-452.
[PUBMED](#) | [CROSSREF](#)

19. Shemesh H, Wesselink PR, Wu MK. Incidence of dentinal defects after root canal filling procedures. *Int Endod J* 2010;43:995-1000.
[PUBMED](#) | [CROSSREF](#)
20. Topçuoğlu HS, Demirbuga S, Tuncay Ö, Pala K, Arslan H, Karataş E. The effects of Mtwo, R-Endo, and D-RaCe retreatment instruments on the incidence of dentinal defects during the removal of root canal filling material. *J Endod* 2014;40:266-270.
[PUBMED](#) | [CROSSREF](#)
21. Pedullà E, Genovesi F, Rapisarda S, La Rosa GR, Grande NM, Plotino G, Adorno CG. Effects of 6 single-file systems on dentinal crack formation. *J Endod* 2017;43:456-461.
[PUBMED](#) | [CROSSREF](#)
22. Coelho MS, Card SJ, Tawil PZ. Visualization enhancement of dentinal defects by using light-emitting diode transillumination. *J Endod* 2016;42:1110-1113.
[PUBMED](#) | [CROSSREF](#)
23. Lim H, Li FC, Friedman S, Kishen A. Residual microstrain in root dentin after canal instrumentation measured with digital moiré interferometry. *J Endod* 2016;42:1397-1402.
[PUBMED](#) | [CROSSREF](#)
24. Shemesh H, Lindtner T, Portoles CA, Zaslansky P. Dehydration induces cracking in root dentin irrespective of instrumentation: a two-dimensional and three-dimensional study. *J Endod* 2018;44:120-125.
[PUBMED](#) | [CROSSREF](#)
25. Çiçek E, Koçak MM, Sağlam BC, Koçak S. Evaluation of microcrack formation in root canals after instrumentation with different NiTi rotary file systems: a scanning electron microscopy study. *Scanning* 2015;37:49-53.
[PUBMED](#) | [CROSSREF](#)
26. Adorno CG, Yoshioka T, Jindan P, Kobayashi C, Suda H. The effect of endodontic procedures on apical crack initiation and propagation *ex vivo*. *Int Endod J* 2013;46:763-768.
[PUBMED](#) | [CROSSREF](#)
27. Borges ÁH, Damião MS, Pereira TM, Filho GS, Miranda-Pedro FL, Luiz de Oliveira da Rosa W, Piva E, Guedes OA. Influence of cervical preflaring on the incidence of root dentin defects. *J Endod* 2018;44:286-291.
[PUBMED](#) | [CROSSREF](#)
28. De Bruyne MA, De Moor RJ. SEM analysis of the integrity of resected root apices of cadaver and extracted teeth after ultrasonic root-end preparation at different intensities. *Int Endod J* 2005;38:310-319.
[PUBMED](#) | [CROSSREF](#)
29. Rose E, Svec T. An evaluation of apical cracks in teeth undergoing orthograde root canal instrumentation. *J Endod* 2015;41:2021-2024.
[PUBMED](#) | [CROSSREF](#)
30. Silva EJ, Carvalho NK, Prado MC, Senna PM, Souza EM, De-Deus G. Bovine teeth can reliably substitute human dentine in an intra-tooth push-out bond strength model? *Int Endod J* 2019;52:1063-1069.
[PUBMED](#) | [CROSSREF](#)
31. Fonseca RB, Haiter-Neto F, Carlo HL, Soares CJ, Sinhoreti MA, Puppini-Rontani RM, Correr-Sobrinho L. Radiodensity and hardness of enamel and dentin of human and bovine teeth, varying bovine teeth age. *Arch Oral Biol* 2008;53:1023-1029.
[PUBMED](#) | [CROSSREF](#)
32. Adl A, Sedigh-Shams M, Majd M. The effect of using RC prep during root canal preparation on the incidence of dentinal defects. *J Endod* 2015;41:376-379.
[PUBMED](#) | [CROSSREF](#)
33. Kansal R, Rajput A, Talwar S, Roongta R, Verma M. Assessment of dentinal damage during canal preparation using reciprocating and rotary files. *J Endod* 2014;40:1443-1446.
[PUBMED](#) | [CROSSREF](#)
34. Shori DD, Shenoi PR, Baig AR, Kubde R, Makade C, Pandey S. Stereomicroscopic evaluation of dentinal defects induced by new rotary system: "ProTaper NEXT". *J Conserv Dent* 2015;18:210-213.
[PUBMED](#) | [CROSSREF](#)
35. Ari H, Erdemir A, Belli S. Evaluation of the effect of endodontic irrigation solutions on the microhardness and the roughness of root canal dentin. *J Endod* 2004;30:792-795.
[PUBMED](#) | [CROSSREF](#)
36. Souza EM, Bretas RT, Cenci MS, Maia-Filho EM, Bonetti-Filho I. Periapical radiographs overestimate root canal wall thickness during post space preparation. *Int Endod J* 2008;41:658-663.
[PUBMED](#) | [CROSSREF](#)
37. Capar ID, Saygili G, Ergun H, Gok T, Arslan H, Ertas H. Effects of root canal preparation, various filling techniques and retreatment after filling on vertical root fracture and crack formation. *Dent Traumatol* 2015;31:302-307.
[PUBMED](#) | [CROSSREF](#)