




Arab Journal of Urology
(Official Journal of the Arab Association of Urology)

www.sciencedirect.com



POINT OF TECHNIQUE

Minimal surgical management of penile paraffinoma after subcutaneous penile paraffin injection



Athanasios E. Dellis^{a,b,*}, Konstantinos Nastos^a, Demetrios Mastorakos^a,
Dionysios Dellaportas^a, Athanasios Papatsoris^c, Panagiotis T. Arkoumanis^a

^a Second Department of Surgery, Aretaieion Academic Hospital, Medical School, National and Kapodistrian University of Athens, Athens, Greece

^b First Department of Urology, Laikon General Hospital, Medical School, National and Kapodistrian University of Athens, Athens, Greece

^c Second Department of Urology, Sismanogleion General Hospital, Medical School, National and Kapodistrian University of Athens, Athens, Greece

Received 13 June 2017, Received in revised form 9 August 2017, Accepted 17 August 2017

Available online 18 September 2017

KEYWORDS

Paraffinoma;
Penile augmentation;
Penile injection;
Penile reconstruction

ABBREVIATION

IIEF-5, five-item version of the International Index of Erectile Function

Abstract Objectives: To describe our reconstructive technique, without flap or graft use, after penile self-augmentation with injected substances, such as paraffin, which are still performed with unfortunate consequences.

Patient and methods: Successful single-stage minimal surgical management of an already twice unsuccessfully managed ulcerative penile paraffinoma in a 38-year-old Greek man.

Results: The patient was discharged with no postoperative complications, with a five-item version of the International Index of Erectile Function score of 23/25 (i.e. normal erectile function) and flaccid penile length of 5 cm.

Conclusions: Penile paraffinoma is a serious complication that can be successfully managed with a single-stage minimal surgical procedure, with normal aesthetic and functional results.

© 2017 Production and hosting by Elsevier B.V. on behalf of Arab Association of Urology. This is an open access article under the CC BY-NC-ND license (<http://creativecommons.org/licenses/by-nc-nd/4.0/>).

* Corresponding author at: Second Department of Surgery, Aretaieion Academic Hospital, Medical School, National and Kapodistrian University of Athens, 76, Vas. Sofias Ave., 11528 Athens, Greece.

E-mail address: aedellis@gmail.com (A.E. Dellis).

Peer review under responsibility of Arab Association of Urology.



Production and hosting by Elsevier

Introduction

The first documented paraffin injection in the literature was reported by Gersuny in 1899 [1]. He described a case of paraffin injection in the scrotum of a boy who had undergone bilateral orchidectomy for genital tuberculosis. However, due to serious complications of this practice, such as infection, ulceration and fistulation [2], the method was abandoned. Penile augmentation with injected substances is still performed in many Asian countries, mainly by the patients themselves or by non-professionals [3,4] with disastrous consequences. In the present study, we describe our technique performed in the first reported case of a successfully managed paraffinoma caused by paraffin injection in the penile corpus, without flap or graft use.

Case description

A 38-year-old Greek man presented in the outpatient clinic with penile pain, painful imperfect erections, and penile shaft circumferential ulceration. He reported a total of six paraffin self-injections in the penile shaft (four around coronal sulcus and two bilateral injections approximately at the penile base). He reported using 3 mL of paraffin oil about 5 years previously, in an attempt of penile augmentation. The initial 4 years were uneventful, but during the fifth year he noticed skin ulceration with necrosis. The patient had undergone a surgical exploration elsewhere 8 months previously, with surgical removal of ulcerative and fibrotic tissue, as well as circumcision. He underwent a re-operation after 2 months due to incomplete resection of the ulcerated skin. As a result of these two procedures the penile shaft skin was scirrhous and fibrotic, with the ulcer causing

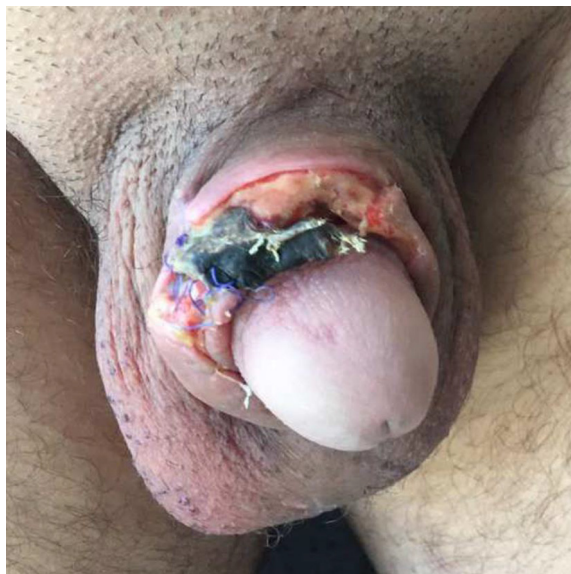


Fig. 1 Penile deformity preoperatively.

further deformity (Fig. 1). As the patient was not referred to our department but presented in the outpatient department as an emergency case, we were not able to access any precise information regarding previous procedures. He reported no history of tuberculosis or penile trauma. Physical examination revealed a painful ulcerated lesion with necrotic areas over the penile shaft skin, whilst the scrotum which initially seemed normal, after careful examination revealed a 5-cm fibrotic scirrhous mass in the mid-scrotal area with several diffuse satellite fibrotic lesions bilaterally. There were no palpable regional lymph nodes. The routine laboratory tests revealed a slightly elevated glucose level and the patient reported a history of poorly controlled diabetes mellitus. Erectile function was assessed using the five-item version of the International Index of Erectile Function (IIEF-5) questionnaire, where he scored 7/25, i.e. severe erectile dysfunction.

Surgical technique

A circumferential sub-coronal and 0.5-cm medial-to-the-lesion penile shaft incision was made. The whole fibrotic and ulcerated tissue between the dartos and Buck's fascia was excised, after it was longitudinally cut. Our deepest limit was Buck's fascia. We tried not to use electrocautery to avoid damage to the neurovascular bundles, as the extent of the fibrotic tissue due to the paraffin injections and past history of circumcision had completely altered the normal subcutaneous anatomy. Furthermore, electrocautery use coagulates small vessels and potentially impedes proper blood supply, and thus optimum healing. Our main goal was to completely eradicate the lesion; because if even small amounts of paraffin are still present the lesions relapse. The penile deficit was rehabilitated using a medial prepuce-suprapubic advancement flap that covered the whole stripped penile shaft like a glove. We considered that it was not safe to use scrotal flaps, due to several satellite lesions in both semi-scrotal areas and the scirrhous mid-scrotal lesion; moreover the patient had a history of diabetes mellitus. A pubic liposuction was performed to prevent buried-penis effect, whilst an Alexandrite laser was used to eradicate hair follicles. Finally, we removed all palpable scrotal masses in a one-by-one fashion, in an attempt to destroy the least possible scrotal tissue, given the extent of the paraffin spread. The patient was discharged 24 h later and there were no postoperative complications (Fig. 2). At 7 weeks after surgery the patient's erectile function was re-assessed using the IIEF-5, he scored 23/25, i.e. normal erectile function, and his flaccid penile length was 5 cm. The aesthetic result was remarkable considering its initial presentation. The patient further returned for follow-up at 6 months after our surgical attempt in a stable and according to him 'excellent' condition (Fig. 3).

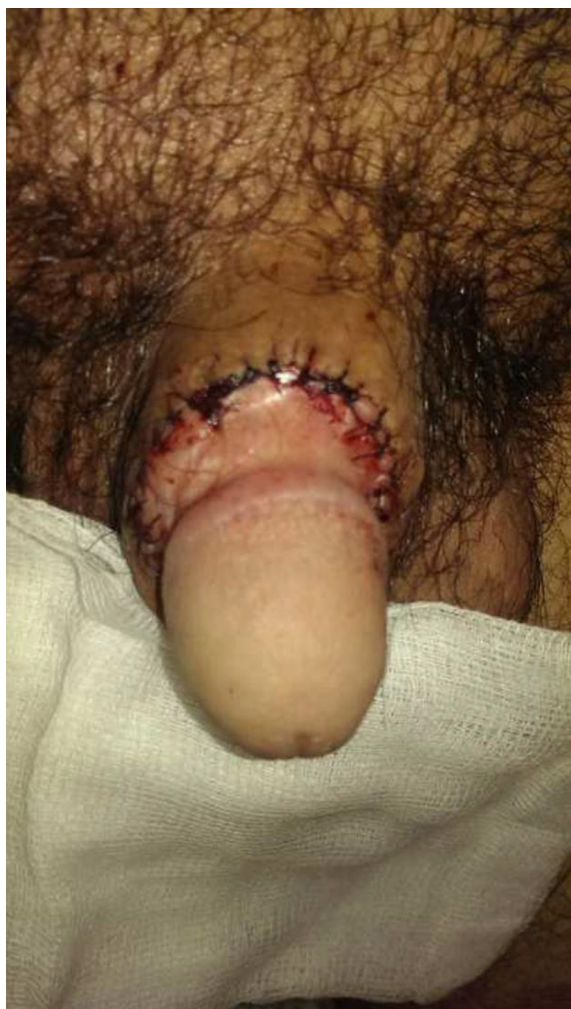

Fig. 2 Penis on first postoperative day.

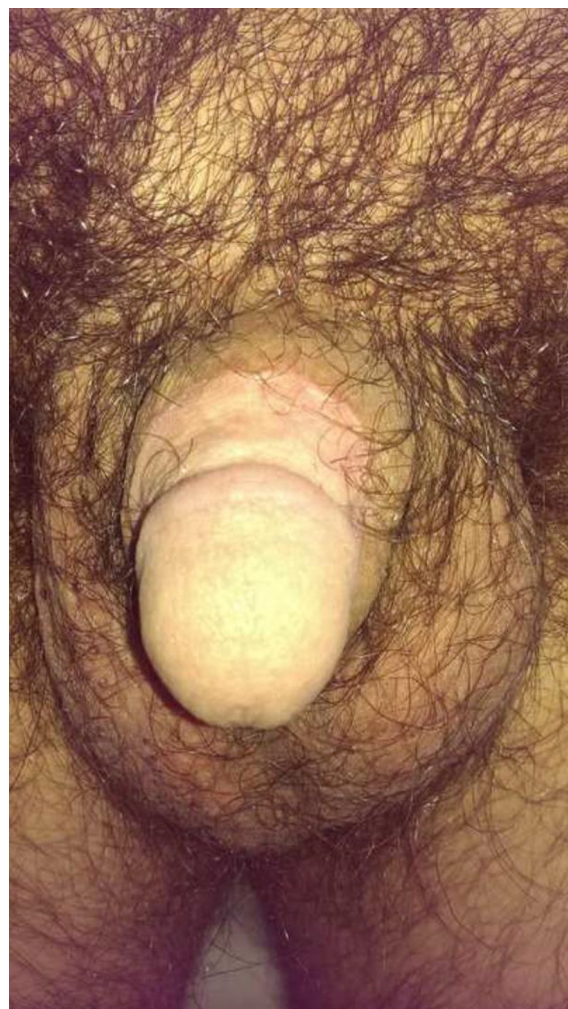

Fig. 3 Penis at 6-months postoperatively.

Discussion

The demand for genital corrective surgery is largely commercialised and increasing in Western societies, mainly as a result of patients' attempts to solve dysmorphism issues. Penile dysmorphism includes either aesthetic (a patient whose penis is normal but who is dissatisfied with its dimensions in the flaccid state) or functional issues (a patient with a normal penis who is dissatisfied with its size when erect) [5]. However, there is no published indication or published guidelines in the relevant literature [6], although a decade ago a simple but well-designed questionnaire was proposed to distinguish suitable patients for penile augmentation procedures [7]. Such patients have in many cases a borderline psychological profile; surgery expectations are unrealistic; thus, there are serious contraindications for such procedures [5]. Additionally, in most cases surgery is not objectively necessary but may be decided upon to satisfy the patient. The aforementioned, along with the possible fear of the surgery per se and the marked

financial recession have led to 'cheaper' self-administered solutions, such as substance injections.

Usually a desired girth can be achieved either with invasive and expensive techniques [8,9] or by less invasive and certainly less costly procedures such as injecting various substances. Injecting filling substances is usually performed in the penile skin as well as in the dartos fascia, which can cause a foreign body reaction, as the human body lacks the enzymes to metabolize interstitial exogenous oils. As a result, a number of unwanted side-effects such as penile scarring, deformity, abscess formation, ulceration, erectile dysfunction, and even Fournier gangrene may occur [2,10]. The clinical manifestation after injection of such substances takes from weeks to several years to occur [10] and the definitive treatment is radical surgical excision of granulomatous tissue together with surgical reconstructive operations. However, radical excision is difficult, as paraffin infiltrates fasciae making its eradication a real challenge. In this case, incomplete resection is more than likely to result in fibrotic tissue formation due to paraffin persistence

and poor healing or even ulceration. To our knowledge this is the first documented case of incomplete resection of paraffinoma treated without the use of free or pedunculated skin flaps. Although in our case it was a pure necessity as there was no healthy tissue in the prepuce or the scrotal area and an unfortunate circumcision had been performed leading to loss of useful tissue for reconstruction, the idea of prepuce and suprapubic skin as an advancement flap proved to be safe and effective. Compared to suggested procedures by Shin et al. [9] the 'T-style anastomosis' technique is characterised by delayed wound healing and infection and the 'inverted V-shape anastomosis' technique needs extended scrotal flaps, which in our case was impossible, as the scrotum was infiltrated by paraffin in both hemi-scrotal areas. For the 'bipedicled scrotal flap with Y-V incision' technique suggested by Kim et al. [8], extended scrotal flaps are needed as well. Penile reconstruction in cases of failed self-augmentation procedures with injected substances should be performed with the use of healthy and well blood-supplied tissues. In our case, the previous multiple failed surgical procedures added morbidity in an already fibrotic and ulcerated area with poor healing potential rather than removing the source of the problem.

Conclusion

Penile paraffinoma is a serious complication resulting from paraffin injection in the penile shaft. Successful surgical management is of utmost importance to restore an aesthetically normal and functional penis, and we show that it can be achieved with a single-stage minimal surgical procedure with no flap or graft use. The latter should be carefully considered given that such patients are aware of their penis appearance and sexual performance, which is probably the initial trigger for substance

Conflict of interest

All authors have nothing to disclose.

Source of funding

None.

References

- [1] Gersuny R. Harte und weiche Paraffinprothesen. *Zentralbl Chir* 1903;**30**:1.
- [2] Bjurlin MA, Carlsen J, Grevious M, Jordan MD, Taylor A, Divakaruni N, et al. Mineral oil-induced sclerosing lipogranuloma of the penis. *J Clin Aesthet Dermatol* 2010;**3**:41–4.
- [3] Bayraktar N, Başar I. Penile paraffinoma. *Case Rep Urol* 2012;**2012**:202840.
- [4] Picozzi SC, Carmignani L. Paraffinoma of the penis. *Int J Emerg Med* 2010;**3**:507–8.
- [5] Austoni E, Guarneri A, Cazzaniga A. A new technique for augmentation phalloplasty: albugineal surgery with bilateral saphenous grafts – three years of experience. *Eur Urol* 2002;**42**:245–53.
- [6] Wessells H, Lue TF, McAninch JW. Penile length in the flaccid and erect state: guidelines for penile augmentation. *J Urol* 1996;**156**:995–7.
- [7] Spyropoulos E, Galanakis I, Dellis A. Augmentation phalloplasty patient selection and satisfaction inventory: a novel questionnaire to evaluate patients considered for augmentation phalloplasty surgery because of penile dysmorphism. *Urology* 2007;**70**:221–6.
- [8] Kim SW, Yoon BI, Ha US, Kim SW, Cho YH, Sohn DW. Treatment of paraffin-induced lipogranuloma of the penis by bipedicled scrotal flap with Y-V incision. *Ann Plast Surg* 2014;**73**:692–5.
- [9] Shin YS, Zhao C, Park JK. New reconstructive surgery for penile paraffinoma to prevent necrosis of ventral skin. *Urology* 2013;**81**:437–41.
- [10] Akkus E, Iscimen A, Tasli L, Hattat H. Paraffinoma and ulcer of the external genitalia after self-injection of vaseline. *J Sex Med* 2006;**3**:170–2.