

Immune thrombocytopenia and autoimmune thyroid disease: a controversial overlap

Guilherme Nader Marta^a, Fernando Peixoto Ferraz de Campos^b

Marta GN, Campos FPF. Immune thrombocytopenia and autoimmune thyroid disease: a controversial overlap. *Autopsy Case Rep* [Internet]. 2015; 5(2):45-48. <http://dx.doi.org/10.4322/acr.2015.002>

ABSTRACT

Immune thrombocytopenia (ITP) is an entity characterized by a platelet count of less than $100 \times 10^9/L$ in the absence of other causes of thrombocytopenia, such as viral infections, rheumatic diseases, or drugs. Grave's disease is also an autoimmune condition in which thrombocytopenia is often observed. Moreover, in the literature, many reports show a marked interference of the thyroid dysfunction (mainly hyperthyroidism) in the control of thrombocytopenia. Although this issue still remains debatable, the authors report the case of a young woman with a previous diagnosis of ITP with a brilliant initial response to corticotherapy. Some years after this diagnosis, the patient presented thyrotoxicosis due to Grave's disease and the thrombocytopenia relapsed, but this time there was no response to the glucocorticoids. Only after the radioiodine I-131 thyroid ablation the control of thrombocytopenia was achieved. The authors call attention to this overlap and for testing thyroid function in every patient with an unexpected negative response to corticotherapy.

Keywords

Hyperthyroidism; Grave's Disease; Purpura, Thrombocytopenic, Idiopathic; Therapeutics.

CASE REPORT

A 31-year-old Caucasian and previously healthy female patient sought medical care complaining of petechiae throughout the body associated with epistaxis, and bleeding gums after teeth brushing. The peripheral blood count revealed thrombocytopenia ($5 \times 10^9/L$) with normal red and white blood cells count. The patient was prescribed prednisone with the diagnostic hypothesis of immune thrombocytopenia (ITP) after a laboratory work-up, comprising antinuclear antibodies (ANA), human immunodeficiency virus (HIV) antibody, and hepatitis B and C serologies, which ruled out secondary causes of thrombocytopenia.

Therapeutic response was achieved 5 days after prednisone prescription.

Four years after the ITP diagnosis, thrombocytopenia relapsed and the patient returned to the emergency department because of abnormal genital bleeding, with a platelet count of $8 \times 10^9/L$. After ruling out gynecological abnormalities, the patient was, once again, hospitalized for corticotherapy. On this occasion, the patient presented tachycardia, insomnia, tremors, exophthalmia, and a diffuse goiter. Laboratory determinations confirmed the diagnosis of Grave's disease by the determination of thyroid stimulating hormone (TSH) = $0.02 \mu IU/mL$ (reference value [RV]:

^a Internal Medicine Department - Hospital das Clínicas - Faculdade de Medicina - Universidade de São Paulo, São Paulo/SP - Brazil.

^b Internal Medicine Department - Hospital Universitário - Universidade de São Paulo, São Paulo/SP - Brazil.



0.55–4.78 $\mu\text{IU/mL}$; free T4 = 2.79 ng/dL (RV: 0.89–1.76 ng/dL); anti-thyroperoxidase (anti-TPO) = 179 IU/mL (RV: < 34 IU/mL) and anti-thyroglobulin (anti-TG) > 500 IU/mL (RV: < 60 IU/mL), and anti-TSHR Ab = 22.53 IU/L (RV: < 1.75 IU/L). Consequently, propylthiouracil was prescribed. During the following months the platelet count reached $363 \times 10^9/L$. The patient did not attend medical follow-up and therefore the euthyroidism could not be assured in the meantime.

Three years later, the patient returned to the emergency department complaining of easy bruising, petechiae, epistaxis, and bleeding gums. The platelet count was $6 \times 10^9/L$, even though she had been taking corticosteroids. The TSH determination was < 0.01 mIU/mL (RV: 0.55–4.78 mIU/mL) and free T4 was 6.23 ng/dL (RV: 0.89–1.76 ng/dL). During this hospitalization, resistance to the corticotherapy was observed since the platelet count remained low after more than 4 weeks of 1.5 mg/kg/day of prednisone. Since the patient's adherence to the treatment was doubtful and the anti-thyroid drugs could be myelotoxic, radioiodine I-131 thyroid ablation treatment was recommended and undertaken after the patient's agreement. After the control of the hyperthyroidism (free T4 = 0.91 ng/dL [RV: 0.89–1.76 ng/dL]) the platelet count increased markedly in the presence of the tapering dose of the corticotherapy (Figure 1).

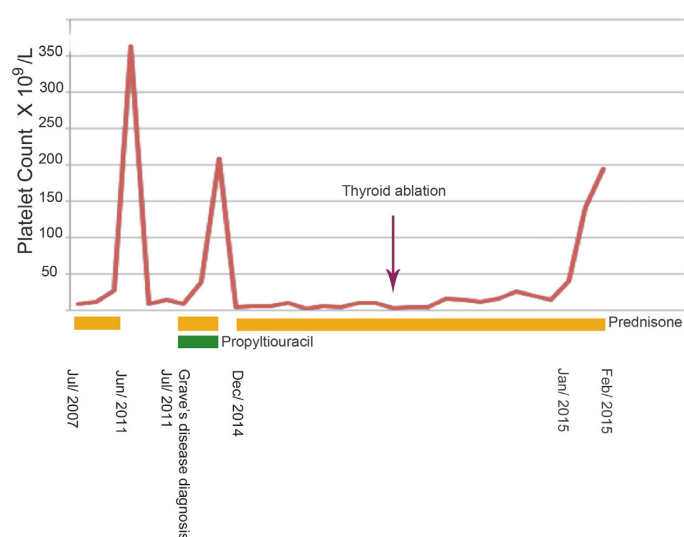


Figure 1. Platelet count during treatment with corticoid and propylthiouracil, and after thyroid ablation.

DISCUSSION

ITP is one of the most common causes of thrombocytopenia in otherwise asymptomatic adults. ITP is an acquired thrombocytopenia caused by autoantibodies against platelet antigens. This entity is characterized by persistent thrombocytopenia, which is defined by a platelet count of $< 100 \times 10^9/L$ (RV: 150–450 $\times 10^9/L$), with neither abnormalities in the white or red blood cells, nor on the peripheral blood smear. The diagnosis of ITP is achieved after ruling out other potential causes of thrombocytopenia including infections by HIV, hepatitis-C virus, hepatitis-B virus, drugs, or rheumatologic diseases, such as systemic lupus erythematosus and antiphospholipid syndrome.¹ The destruction of the platelet–antibody complex by the reticuloendothelial system in a rate superior to the marrow's replacement capacity explains the physiopathology of thrombocytopenia in ITP.¹ In the past few years, new evidence suggests that the platelet production may also be impaired in patients with ITP.²

Quite frequently, patients with Grave's disease present mild thrombocytopenia, but generally the platelet count, in these cases, is $> 100 \times 10^9/L$.^{3,4} In 1931, Jackson⁵ first described the association between hyperthyroidism and thrombocytopenia. Although rare, this association (especially with Grave's disease and Hashimoto's thyroiditis) has been demonstrated in several studies.^{6,7} When associated, ITP and autoimmune thyroid diseases may present simultaneously, although the time between the onset of both diseases may vary widely from months to years.^{3,8} Cordiano et al.⁹ showed that autoimmune thrombocytopenia, in the course of thyroid disease, is far more prevalent than vice versa. In a longitudinal study, 8–14% of patients with ITP developed hyperthyroidism¹⁰, leading to speculation on the physiopathology of this phenomenon. Two mechanisms have been proposed to explain this association: a) activation of the reticuloendothelial system by the thyroid hormones; and b) the presence of an autoimmune mechanism able to trigger both conditions.^{11–13} Platelet-associated immunoglobulin G and specific platelet antibody were detected in 83% and 86% of patients with ITP with and without thyroid autoimmune disease, respectively, while anti-thyroid antibodies were found in 89% of patients with ITP.⁹ An experimental study evaluated the platelet's life span in a group of rats in which hyperthyroidism had been

induced by 3,5,3'-triiodothyronine (T3) administration and a control group.¹² The animals treated with T3 presented a reduced platelet count due to early platelet destruction. When the platelets of animals treated with T3 were infused in the animals of the control group, the platelet life span returned to normal; however, when the platelets of the control group were infused in the T3-treated animals the mean platelet survival time decreased.¹⁴ These results point to the possibility that, in Graves disease, thyroid hormones might increase the phagocytic activity of the reticuloendothelial system, leading to thrombocytopenia.^{3,12} Genetic predisposition for the development of both diseases, associated with HLA B8, has also been reported.^{14,15}

However, other studies and case series could not show such a parallelism between the clinical courses of ITP and thyroid disease, such that, in many cases, no improvement in the platelet count was observed after the thyroid function control.^{16,17} The thrombocytopenia induced by the reticuloendothelial hyper activation is, in general, mild to moderate,¹² suggesting that this may not be the single mechanism involved in the pathogenesis of the marked thrombocytopenia observed in ITP.¹¹ Altintas et al.¹⁸ found the presence of anti-thyroglobulin (anti-TG) in 39% of the patients with ITP without evidence of thyroid disease, while this finding was positive in only 10% of the control group. In this study, many of the patients with ITP and positive anti-TG also had positive tests for anti-endomysium, and anti-gliadin, which may suggest a substantial defect in the immune self-tolerance in this group of patients.^{3,18}

Another theory proposes a cross reaction between the antibodies anti-thyroid receptors and the platelets epitopes, which could explain the association of both conditions.¹⁷ This hypothesis was strengthened by the structural similarity of the platelet membrane glycoprotein GPIIb/IIIa and the TABP (truncated actin binding protein), which is the protein to which the anti-thyroid antibodies bind.¹⁹ This suggests that the same anti-thyroid antibodies may react with platelet receptors by providing their early destruction.

Nonetheless, the effect of the thyroid disease and its treatment on the clinical course of ITP remains controversial.³ Differently from the hypothyroidism, the majority of case reports of hyperthyroidism and ITP show complete remission of the thrombocytopenia or a better control with the usual therapeutic modalities.³ Sugimoto et al.¹¹ report the case of a patient with a

10-year history of Grave's disease taking methimazole, which showed a parallelism between the platelet count and the TSH values. In that report, the ITP response could be attributed to the treatment of Grave's disease, since no corticosteroid or other immunosuppressor was used.¹¹ An interesting case was reported by Jung et al.²⁰, which showed the reversal of thrombocytopenia after I-131 thyroid ablation, in a patient with the diagnosis of ITP and Grave's disease. In a review of cases on hyperthyroidism associated with ITP, it was estimated that 7% of the cases of ITP would respond to the treatment of the thyrotoxicosis, and that in many cases the thrombocytopenia would be resistant to other therapies.^{3,21}

The International Consensus Report on the investigation and management of primary immune thrombocytopenia, published in 2010,²² classifies the thyroid function evaluation and the thyroid antibodies research as a test of potential utility in the management of ITP, although this recommendation does not take into account the basic investigation for patients with the suspicion of ITP.

The observation of this case points positively to the interference of thyroid function in the response to corticotherapy for the control of thrombocytopenia in cases of ITP. We suggest, therefore, that the thyroid function should always be evaluated in cases presenting resistance to the usual ITP treatment protocols.

REFERENCES

1. Neunert C, Lim W, Crowther M, Cohen A, Solberg L Jr, Crowther MA. The American Society of Hematology 2011 evidence-based practice guideline for immune thrombocytopenia. *Blood*. 2011;117(16):4190-207. <http://dx.doi.org/10.1182/blood-2010-08-302984>. PMID:21325604.
2. Bromberg ME. Immune thrombocytopenic purpura—the changing therapeutic landscape. *N Engl J Med*. 2006;355(16):1643-5. <http://dx.doi.org/10.1056/NEJMp068169>. PMID:17050888.
3. Cheung E, Liebman HA. Thyroid disease in patients with immune thrombocytopenia. *Hematol Oncol Clin North Am*. 2009;23(6):1251-60. <http://dx.doi.org/10.1016/j.hoc.2009.08.003>. PMID:19932432.
4. Brent GA. Clinical practice. Graves' disease. *N Engl J Med*. 2008;358(24):2594-605. <http://dx.doi.org/10.1056/NEJMc0801880>. PMID:18550875.
5. Jackson AS. Acute hemorrhagic purpura associated with exophthalmic goiter. *JAMA*. 1931;113:2386-93.

6. Marshall JS, Weisberger AS, Levy RP, Breckenridge RT. Coexistent Idiopathic Thrombocytopenic Purpura and Hyperthyroidism. *Ann Intern Med.* 1967;67(2):411-4. <http://dx.doi.org/10.7326/0003-4819-67-2-411>.
7. Gill H, Hwang YY, Tse E. Primary immune thrombocytopenia responding to antithyroid treatment in a patient with Graves' disease. *Ann Hematol.* 2011;90(2):223-4. <http://dx.doi.org/10.1007/s00277-010-0983-4>. PMID:20467745.
8. Pavithran K, Sreekumar A, Krishnamohan VE. Idiopathic thrombocytopenic purpura associated with Graves' disease--case report. *Indian J Med Sci.* 1996;50(2):43-6. PMID:8979632.
9. Cordiano I, Betterle C, Spadaccino CA, Soini B, Girolami A, Fabris F. Autoimmune thrombocytopenia (AITP) and thyroid autoimmune disease (TAD): overlapping syndromes? *Clin Exp Immunol.* 1998;113(3):373-8. <http://dx.doi.org/10.1046/j.1365-2249.1998.00677.x>. PMID:9737665.
10. Liebman H. Other immune thrombocytopenias. *Semin Hematol.* 2007;44(4, Suppl 5):S24-34. <http://dx.doi.org/10.1053/j.seminhematol.2007.11.004>. PMID:18096469.
11. Sugimoto K, Sasaki M, Isobe Y, Tamayose K, Hieda M, Oshimi K. Improvement of idiopathic thrombocytopenic purpura by antithyroid therapy. *Eur J Haematol.* 2005;74(1):73-4. <http://dx.doi.org/10.1111/j.1600-0609.2004.00341.x>. PMID:15613111.
12. Kurata Y, Nishioeda Y, Tsubasio T, Kitanin T. Thrombocytopenia in Grave's disease: effect of T3 on platelet kinetics. *Acta Hematol.* 1980;63:185-90. <http://dx.doi.org/10.1159/000207396>.
13. Hofbauer LC, Spitzweg C, Schmauss S, Heufelder AE. Graves disease associated with autoimmune thrombocytopenic purpura. *Arch Intern Med.* 1997;157(9):1033-6. <http://dx.doi.org/10.1001/archinte.1997.00440300155015>. PMID:9140276.
14. Bizzaro N. Familial association of autoimmune thrombocytopenia and hyperthyroidism. *Am J Hematol.* 1992;39(4):294-8. <http://dx.doi.org/10.1002/ajh.2830390411>. PMID:1348160.
15. Grumet FC, Payne RO, Konishi J, Kriss JP. HL-A antigens as markers for disease susceptibility and autoimmunity in Graves' disease. *J Clin Endocrinol Metab.* 1974;39(6):1115-9. <http://dx.doi.org/10.1210/jcem-39-6-1115>. PMID:4479624.
16. Vergès B, Giroud-Baleyrier F, Olsson O, Vaillant G, Brun JM, Putelat R. [Association of Basedow's disease and autoimmune thrombopenic purpura. No effect of hyperthyroidism on antiplatelet autoimmunity]. *Rev Med Interne.* 1989;10(6):565-9. PMID:2488511.
17. Cohen Aubart F, Jublanc C, Bruckert E. [Graves' disease and autoimmune thrombocytopenic purpura: distinct outcomes of the two diseases]. *Ann Endocrinol.* 2007;68(1):55-7. <http://dx.doi.org/10.1016/j.ando.2006.12.001>. PMID:17292844.
18. Altintas A, Pasa S, Cil T, Bayan K, Gokalp D, Ayyildiz O. Thyroid and celiac diseases autoantibodies in patients with adult chronic idiopathic thrombocytopenic purpura. *Platelets.* 2008;19(4):252-7. <http://dx.doi.org/10.1080/09537100801894651>. PMID:18569860.
19. Leedman PJ, Faulkner-Jones B, Cram DS, et al. Cloning from the thyroid of a protein related to actin binding protein that is recognized by Graves disease immunoglobulins. *Proc Natl Acad Sci USA.* 1993;90(13):5994-8. <http://dx.doi.org/10.1073/pnas.90.13.5994>. PMID:8327473.
20. Jung RS, Parghane RV, Sood A, Bhattacharya A, Mittal BR. Primary autoimmune thrombocytopenia and co-existing Graves' disease: Role of radioiodine-131. *Indian J Nucl Med.* 2014;29(3):195-6. <http://dx.doi.org/10.4103/0972-3919.136602>. PMID:25210295.
21. Herman J, Resnitzky P, Fink A. Association between thyrotoxicosis and thrombocytopenia. A case report and review of the literature. *Isr J Med Sci.* 1978;14(4):469-75. PMID:566733.
22. Provan D, Stasi R, Newland AC, et al. International consensus report on the investigation and management of primary immune thrombocytopenia. *Blood.* 2010;115(2):168-86. <http://dx.doi.org/10.1182/blood-2009-06-225565>. PMID:19846889.

Conflict of interest: None

Submitted on: February 25, 2015

Accepted on: April 12, 2015

Correspondence

Guilherme Nader Marta

Internal Medicine Department

Hospital das Clínicas

Faculdade de Medicina da Universidade de São Paulo

Av. Dr. Enéas de Carvalho Aguiar, 255 – Pinheiros – São Paulo/SP – Brazil

CEP: 05403-900

Phone: +55 (11) 2661-7690 | +55 (11) 2661-6746

E-mail: gnmarta2@gmail.com