

# Surgical treatment for type II macular hole retinal detachment in pathologic myopia

Wenjian Xin, MS, Xuehong Cai, BS, Yun Xiao, BS\*, Leibing Ji, MS, Yongxin Gu, MS, Wenjuan Lv, MS, Jize Jiang, BS

## Abstract

To observe the effectiveness and complications of inverted internal limiting membrane insertion through 25-G minimally invasive vitrectomy assisted with autologous blood adhesion fixation and combined with gas tamponade type-II macular hole retinal detachment in pathologic myopia.

This was a retrospective study. The best-corrected visual acuity, intraocular pressure, macular hole closure, retinal reattachment, and systemic and ocular adverse events were observed.

Twenty-three eyes were operated. Best-corrected visual acuity before surgery and at 3 and 6 months were  $2.25 \pm 0.47$ ,  $1.85 \pm 0.32$ , and  $1.32 \pm 0.36$  LogMAR ( $P < .001$ ). On days 2 to 5, all the retinas reattached, and the macular holes closed. On days 5 to 9, 5 eyes showed increased intraocular pressure. At 2 and 4 months, 2 eyes showed retinal detachment recurrence. No serious systemic or ocular adverse events were observed.

This surgical technique showed clinical benefits and no significant complications. Clinical trials are necessary to confirm efficacy and safety.

**Abbreviations:** BCVA = best-corrected visual acuity, ICG = indocyanine green, IOP = intraocular pressure, MHRD = macular hole retinal detachment.

**Keywords:** blood, degenerative, myopia, retinal detachment, surgery

## 1. Introduction

In China, the prevalence of myopia is particularly high, reaching 88% among high school students in some areas.<sup>[1,2]</sup> Severe myopia is associated with an increased risk of retinal detachment, cataracts, and glaucoma.<sup>[3,4]</sup> With the progressive extension of the ocular axis, eyes with pathologic myopia show a series of pathological changes,<sup>[5,6]</sup> among which macular hole retinal detachment (MHRD) is one of the common complications and eventually seriously impairs the visual function,<sup>[4]</sup> especially in Asians.<sup>[7,8]</sup>

The treatment and management of MHRD is controversial.<sup>[9,10]</sup> The traditional treatment of MHRD was vitrectomy combined with silicone oil tamponade, which not only increases

the economic burden and the times of hospitalization of patients but also seriously affects the physical and mental health of patients due to long-term prone position.<sup>[11]</sup> In recent years, various surgical methods have been developed for the treatment of MHRD,<sup>[10-15]</sup> but no surgical methods can solve all the problems related to MHRD.<sup>[10]</sup>

Based on the relevant literature<sup>[16]</sup> and combining with clinical experience, our center developed a surgical technique based on vitrectomy assisted with internal limiting membrane (ILM) repositioning and combined with gas tamponade for the treatment of type I MHRD.<sup>[16,17]</sup> Because of the wider range and higher degree of detachment, type II MHRD was tentatively treated with an adapted technique. Therefore, the aim of the present study was to report the effectiveness and complications of inverted ILM insertion through 25-G minimally invasive vitrectomy assisted with autologous blood adhesion fixation and combined with gas tamponade type-II MHRD in pathologic myopia.

## 2. Methods

### 2.1. Patients

This was a retrospective case series. This study was approved by the Ethics Committee of Xinjiang Military Region General Hospital of the People's Liberation Army. Informed consent was waived by the committee because of the retrospective nature of the study.

The patients diagnosed with type II MHRD due to pathological myopia at the Ophthalmology center, Xinjiang Military Region General Hospital of the People's Liberation Army from January 2016 to June 2018 were included in this study.

Editor: Undurti N. Das.

The authors have no conflicts of interest to disclose.

Department of Ophthalmology, Military Ophthalmological Center, General Hospital of Xinjiang Military Region, Urumqi, Xinjiang, China.

\* Correspondence: Yun Xiao, Department of Ophthalmology, Military Ophthalmological Center, General Hospital of Xinjiang Military Region, Urumqi, Xinjiang, China (e-mail: yunxiao2688@126.com).

Copyright © 2020 the Author(s). Published by Wolters Kluwer Health, Inc. This is an open access article distributed under the terms of the Creative Commons Attribution-Non Commercial License 4.0 (CCBY-NC), where it is permissible to download, share, remix, transform, and buildup the work provided it is properly cited. The work cannot be used commercially without permission from the journal.

How to cite this article: Xin W, Cai X, Xiao Y, Ji L, Gu Y, Lv W, Jiang J. Surgical treatment for type II macular hole retinal detachment in pathologic myopia. *Medicine* 2020;99:17(e19531).

Received: 12 August 2019 / Received in final form: 15 January 2020 / Accepted: 12 February 2020

<http://dx.doi.org/10.1097/MD.00000000000019531>

The inclusion criteria were:

- (1) <80 years of age;
- (2) disease duration of <6 months;
- (3) axial length >26.5 mm and <32 mm;
- (4) with light perception;
- (5) with documented type II MHRD<sup>[16]</sup>; and
- (6) received the study surgery and regular follow-up.

The exclusion criteria were:

- (1) proliferative vitreoretinopathy;
- (2) history of chronic eye inflammation, eye traumas, other eye surgery, or intravitreal drug therapy; or
- (3) severe dysfunction of the heart, lung, liver, or kidney.

## 2.2. Data collection

Age, sex, and disease duration were collected from the medical records. All patients underwent intraocular pressure (IOP) examination, slit-lamp examination, indirect ophthalmoscope examination, fundus photography, optical coherence tomography (OCT), and ocular ultrasound before surgery. Preoperative IOP, axial length, lens status, the minimum diameter of the macular hole, and the presence of macular retinoschisis and posterior scleral staphyloma were recorded. Best-corrected visual acuity (BCVA) was measured via the international standard visual chart, and its Snellen value was converted to the logarithm of the minimum angle of resolution (logMAR). A BCVA of hand movement and counting fingers were defined as 3.0 and 2.0 logMAR, respectively.

## 2.3. Surgical procedures

All patients underwent standard 3-channel 25-G pars plana vitrectomy, performed by the same experienced ophthalmologist. The vitreous body on the central axis was excised, posterior, and lateral vitreous detachment in the area of retinal detachment was performed cautiously till the ambitus were excised completely, and the surrounding vitreous body was excised as far as possible. After dyeing with 20% diluted triamcinolone acetonide (40 mg/mL; Kunming Jida Co., Ltd., Yunnan, China), the posterior vitreous cortex membrane was removed with a flute needle and membrane tweezers, followed by fluid-gas exchange. The peripheral retina was checked after the retina, and the macular hole fit properly. Photocoagulation was given according to the situation of the retina, and ILM in the macular area was dyed with diluted 0.1% indocyanine green (ICG, 25 mg/10 mL; Dandong Yichuang Pharmaceuticals Co., Ltd., Liaoning, China), where the macular hole was avoided as much as possible. The excessive ICG was removed with a flute needle, and the flaps were made in the upper and lower vascular arches with the membrane tweezers, which peeled the ILM along the direction of the macular hole. An area of 1.5 PD of ILM around the macular hole was retained to be peeled, inverted, and inserted in the macular hole. About 1 mL of venous blood was collected from the median cubital vein of the patient; about 0.05 mL was extracted with a flute needle and then dripped at the macular hole to form a thrombus. After the gas-fluid exchange, 15% C<sub>3</sub>F<sub>8</sub> was injected. The phacoemulsification cataract excision combined with intraocular lens implantation was performed if the patient's fundus surgery was affected by lens opacity. The patients were instructed to keep the prone position for 1 to 2 weeks after surgery.

## 2.4. Outcomes

Follow-up was performed for at least 6 months in all patients. BCVA was examined at 3 and 6 months after surgery. OCT (CIRRUS OCT5000; Carl Zeiss, Jena, Germany) was used to determine the closure of the macular hole and retinal reattachment. The connection of the histological components in the macular hole was considered closed. Tissue defect is seen in the macular hole, and whole layer loss of the neural epithelium was considered not closed. Retinal reattachment was defined as the neural epithelium and pigment epithelium fitting in the macular area; otherwise, retinal reattachment was considered as failed. Intraoperative and postoperative ocular and systemic adverse events were observed during the study period. Serious adverse events included anesthesia accident, apnea, cardiovascular and cerebrovascular accidents, fulminant intraocular hemorrhage, and intraocular infection.

## 2.5. Statistical analysis

Statistical analysis was carried out using SPSS 19.0 (IBM, Armonk, NY). Continuous variables are expressed as means ± standard deviation or median (range), and categorical variables are represented as frequencies (percentage). The comparison of BCVA measured before operation and at 3 and 6 months after surgery was performed with repeated measures analysis of variance. The differences were considered statistically significant when  $P < .05$ .

## 3. Results

### 3.1. Characteristics of the patients

Twenty-three patients were included in this study, all of whom underwent monocular surgery (Table 1).

### 3.2. Surgical outcomes

All 23 patients (23 eyes) underwent surgery successfully (Table 2). Five eyes underwent phacoemulsification cataract excision combined with intraocular lens implantation due to the severe opacity of the lens. On days 2 to 5 after surgery, the retinas of all operated eyes gradually reattached, and the macular holes closed, with the front lenses and observation through the gas (Fig. 1).

The BCVA before surgery and at 3 and 6 months after surgery were  $2.25 \pm 0.47$ ,  $1.85 \pm 0.32$ , and  $1.32 \pm 0.36$  logMAR, respectively ( $P < .001$ ). Five eyes showed increased IOP on days 5 to 9. Examination showed a small number of blood cells floating in the vitreous body cavity and anterior chamber. IOP recovered to normal after 1 week of betaxolol plus brinzolamide eye drops.

At 2 and 4 months, 2 patients (2 eyes) showed recurrence and were treated with scleral buckling surgery. After surgery, the retinas reattached, and the macular holes closed. Both patients showed the macular hole appearing on the edge of the neurodeatrophia lesion on the bitemporal distal periphery. It was speculated that the macular hole was formed on the retina due to the contraction of the vitreous base and traction due to the choroidal atrophy in the process of ocular axis extension. No macular hole was found in the preoperative mydriasis examination, but a macular hole was found using indirect ophthalmoscopy combined with a sclerotic compression examination. The macular hole closed after scleral buckling surgery, but the retinal reattached occurred at 3 months after operation when the persistent subretinal effusion was finally absorbed completely.

**Table 1**  
**Characteristics of the patients.**

| Variable                                     | Patients (n = 23) |
|--|-------------------|
| Sex, n (%)                                   |                   |
| Male   | 6 (26.1)          |
| Female                                       | 17 (73.9)         |
| Age (yr), mean ± SD                          | 58.3 ± 9.5        |
| Duration of disease (mo), median (range)     | 1.6 (0.25–4)      |
| Side, n (%)                                  |                   |
| Right  | 11 (47.8)         |
| Left   | 12 (52.2)         |
| BCVA (logMAR), mean ± SD                     | 2.25 ± 0.47       |
| Intraocular pressure (mm Hg), mean ± SD      | 9.85 ± 2.24       |
| Axial length (mm), mean ± SD                 | 28.13 ± 2.45      |
| Macular retinoschisis, n (%)                 | 9 (39.1)          |
| Posterior scleral staphyloma, n (%)          | 23 (100)          |
| Lens status, n (%)                           |                   |
| Phakic                                       | 17 (73.9)         |
| Pseudophakic                                 | 6 (26.1)          |
| Minimum diameter of macular hole (μm), n (%) |                   |
| <400   | 9 (39.1)          |
| 400–600                                      | 11 (47.8)         |
| >600   | 3 (13.1)          |

BCVA = best corrected visual acuity, logMAR = logarithm of the minimum angle of resolution, SD = standard deviation.

### 3.3. Adverse events

No serious ocular or systemic adverse events were observed in all patients. The macular holes closed, and the retina reattached in all affected eyes at the last follow-up visit.

## 4. Discussion

In 2010, Michalewska et al<sup>[18,19]</sup> took the lead in using the inverted ILM flap technique to treat huge idiopathic macular holes, finding that this technique could increase the closure rate of macular holes with a diameter of >400 μm. Thereafter, Kuriyama et al<sup>[20]</sup> found that the inverted ILM flap technique could also be used for increasing the macular hole closure rate in high myopia patients with or without retinal detachment. With the increasing application of the inverted ILM flap technique, the effect of pars plana vitrectomy combined with ILM peeling has been generally recognized for the treatment of MHRD.<sup>[21]</sup>

This technique is still very controversial regarding ILM peeling or retaining. Numerous studies have confirmed that the ILM, as

**Table 2**  
**Postoperative outcomes.**

| Variable                         | Patients (n = 23) |
|----------------------------------|-------------------|
| Operation success, n (%)         | 23 (100)          |
| Combined cataract surgery, n (%) | 5 (21.7)          |
| Operative time (min), mean ± SD  | 48 ± 8.3          |
| Length of stay (d), mean ± SD    | 10 ± 1.6          |
| Closure of macular hole, n (%)   | 23 (100)          |
| Retinal reattachment, n (%)      | 23 (100)          |
| BCVA (logMAR), mean ± SD         |                   |
| Baseline                         | 2.25 ± 0.47       |
| 3 mo                             | 1.85 ± 0.32       |
| 6 mo                             | 1.32 ± 0.36       |
| P                                | <.001             |

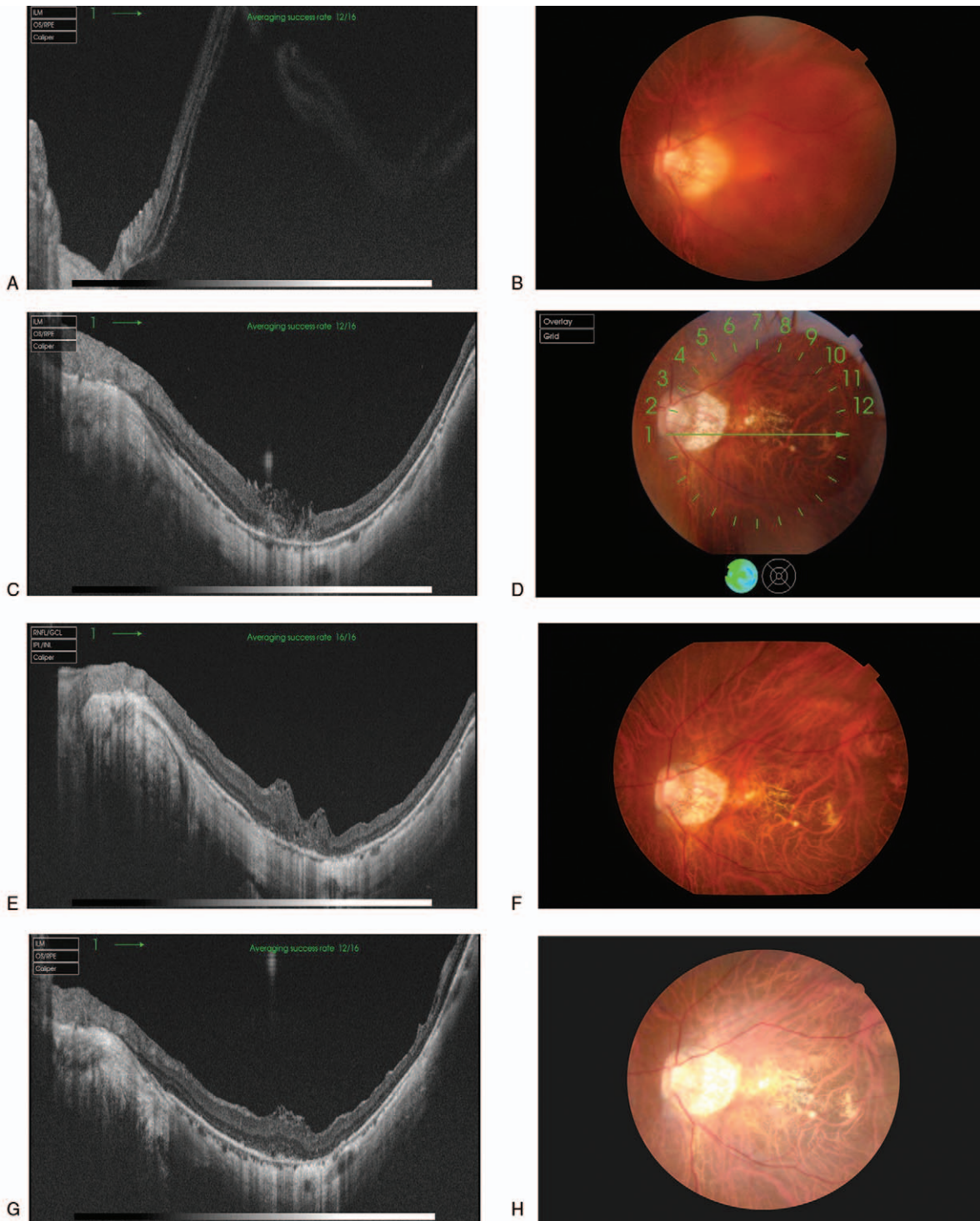
BCVA = best corrected visual acuity, logMAR = logarithm of the minimum angle of resolution, SD = standard deviation.

the basement membrane of the Müller cells, plays a role in protecting and nourishing the retina.<sup>[22–24]</sup> Terasaki et al<sup>[25]</sup> found that ILM peeling can delay the recovery of the β waves in ERG within the range of 15° of the macular area or make it incomplete. Other studies have reported that uneven reflection points and radial corrugations along the nerve fiber layer were seen through C-Scan image obtained with the frequency domain OCT after the ILM was peeled.<sup>[26–28]</sup> We advocate to preserve the ILM in the central concave area and to peel the ILM outside of the central concave area to the vascular arch, so as to remove the force in the tangent direction and facilitate the recovery of the macular functions after surgery.

With regard to patients with type II MHRD, the intraoperative retinal detachment had a large range and a high degree, so ILM peeling was very difficult, and the inserted ILM was also easy to drift apart, which would not be encountered in the case of type I MHRD. Autologous whole blood was instilled at the same time to fill in the ILM at the position of the macular hole, so as to form a “macular thrombus” that could close the hole, thus achieving the effect of retinal reattachment, as if the intraoperative closure was the key to scleral buckling surgery, an external-route surgery. As for type I MHRD, we tried to adopt the inverted ILM flap combined with gas injection in the vitreous cavity since the retinal detachment range is limited within the vascular arch, and the height of detachment is lower. No inverted ILM fixed with autologous blood was adopted in the process of surgery, and good postoperative outcomes were also obtained.<sup>[16]</sup>

Due to the fragile eyes of patients with type II MHRD in pathological myopia, long AL, thin sclera wall, poor elasticity of collagen fiber of the sclera, and decreased closing force, we adopted the 25-G 3-way surgery with smaller incision and rapid and high cutting efficiency. Flute needles were used for careful blowing-suction for the posterior vitreous cortex detachment in the macular area, to avoid the enlargement of the hole. The peripheral vitreous body was incised with low negative pressure and high cutting speed technique for the bitemporal retinal detachment reaching the equator or even the peripheral region, so as to avoid the enlargement of retinal detachment scope due to human factors. In the process of ICG dyeing, the ILM in the area far away from the macular hole under gas was dyed slowly to prevent the stain from penetrating the retina. The flute needles were used to remove the excess stain, thus further reducing the toxicity to the retina and protecting the function of the vision cells in the macular area. Considering the retinal atrophy of the affected eyes with pathologic myopia, crisp and thin ILM, and floating and unfixed retina detached, ILM peeling was certainly difficult. The flute needles were used first to remove the excessive sub-retinal fluid to reduce the detachment height, and then the ILM could be peeled. The trophic and growth factors possibly in autologous blood can facilitate the proliferation of glial cells and fibroblasts with the help of the “bridge-like” connection of ILM, so as to achieve the closure of the hole, which was beneficial to the migration of photoreceptor cells and the reconstruction of visual function.<sup>[29,30]</sup>

At 6 months after surgery, the BCVA was improved compared with the preoperative result, although the improvement of vision was limited. It is well known that patients with pathologic myopia have poor visual function from the start, which is closely associated with degenerative fundus changes and a series of complications, especially for patients with an overlong ocular axis and higher age, for whom it is particularly important to improve their vision by surgery. Five eyes showed elevated IOP



**Figure 1.** Optical coherence tomography (OCT) and fundus photograph of a 61-yr old male patient with binocular pathologic myopia and cataract. Type II macular hole retinal detachment and posterior scleral staphyloma occurred in the left eye, without macular retinoschisis. Preoperative best-corrected visual acuity (BCVA) was 3.0 logMAR (hand movement). This patient underwent cataract phacoemulsification, intraocular lens implantation, and inverted internal limiting membrane flap technique through 25-G minimally-invasive vitrectomy assisted with autologous blood adhesion fixation and combined with intravitreal gas injection. Postoperative BCVA at 3 and 6 mo was 0.02 and 0.04 logMAR, respectively. (A) Preoperative OCT. (B) Preoperative fundus photograph. (C) Postoperative OCT at mo 1. (D) Postoperative fundus photograph at 1 mo. (E) Postoperative OCT at 3 mo. (F) Postoperative fundus photograph at 3 mo. (G) Postoperative OCT at 6 mo. (H) Postoperative fundus photograph at 6 mo.

on days 5 to 9 after operation, and a small number of blood cells were found floating in their vitreous cavity and anterior chamber. It was speculated that there might be invisible relaxation or

missing of the suspensory ligament and trabecular meshwork degeneration in pathologic myopia, which may lead to increased IOP caused by aqueous humor outflow. The IOP dropped to a

normal level after decompression with drugs. IOP fluctuation caused by this surgical method is often transient when compared with the sustained high IOP, which is also difficult to control, caused by the previous vitrectomy combined with silicone oil tamponade.<sup>[31]</sup>

This study also has many limitations. This retrospective study had no control group, a small number of cases, and a short follow-up. The toxicity on the pigment epithelium caused by more ICG retained in the macular hole because of more ILM insertion in the macular hole cannot be ignored. Nevertheless, even if no such toxicity was observed in the present study, physicians must be aware of this possibility. In addition, the toxicity of the hemosiderin on the neural epithelium caused by red blood cell lysis is also worthy of attention, which is one of the possible reasons why autologous blood adhesion and fixation was not recommended for patients with type I MHRD in this study. Finally, as all patients in the present study had type II macular hole retinal detachment, there was a hole at the macular fovea. Due to the severe retinal detachment (large gap between the retinal neuroepithelium layer and pigment epithelium layer, with large range), central retinal thickness could not be measured accurately at baseline. Some patients even could not be measured at all. Many questions remain to be verified with a larger sample size and a longer follow-up visit.

In conclusion, the treatment of type II MHRD in pathological myopia with inverted ILM insertion through 25-G minimally invasive vitrectomy assisted with autologous blood adhesion fixation and combined with gas tamponade showed clinical benefits and no significant complications. Clinical trials are necessary to confirm the efficacy and safety of this operation.

## Author contributions

**Conceptualization:** Wenjian Xin, Yun Xiao.

**Data curation:** Wenjian Xin, Xuehong Cai, Leibing Ji, Yongxin Gu, Wenjuan Lv, Jize Jiang.

**Formal analysis:** Wenjian Xin, Xuehong Cai, Yun Xiao, Leibing Ji, Yongxin Gu, Wenjuan Lv, Jize Jiang.

**Investigation:** Wenjian Xin, Xuehong Cai.

**Methodology:** Wenjian Xin, Xuehong Cai.

**Project administration:** Yun Xiao.

**Writing – original draft:** Wenjian Xin.

**Writing – review and editing:** Xuehong Cai, Yun Xiao, Leibing Ji, Yongxin Gu, Wenjuan Lv, Jize Jiang.

## References

- Chen M, Wu A, Zhang L, et al. The increasing prevalence of myopia and high myopia among high school students in Fenghua city, eastern China: a 15-year population-based survey. *BMC Ophthalmol* 2018;18:159.
- Li Y, Liu J, Qi P. The increasing prevalence of myopia in junior high school students in the Haidian District of Beijing, China: a 10-year population-based survey. *BMC Ophthalmol* 2017;17:88.
- Foster PJ, Jiang Y. Epidemiology of myopia. *Eye (Lond)* 2014;28:202–8.
- Lens A, Nemeth SC, Ledford JK. *Ocular Anatomy and Physiology*. Thorofare: SLACK Inc; 2008.
- Steidl SM, Pruett RC. Macular complications associated with posterior staphyloma. *Am J Ophthalmol* 1997;123:181–7.
- Takano M, Kishi S. Foveal retinoschisis and retinal detachment in severely myopic eyes with posterior staphyloma. *Am J Ophthalmol* 1999;128:472–6.
- Wong TY, Ferreira A, Hughes R, et al. Epidemiology and disease burden of pathologic myopia and myopic choroidal neovascularization: an evidence-based systematic review. *Am J Ophthalmol* 2014;157:9–25.e12.
- Kempner JH, Mitchell P, Lee KE, et al. The prevalence of refractive errors among adults in the United States, Western Europe, and Australia. *Arch Ophthalmol* 2004;122:495–505.
- Ortisi E, Avitabile T, Bonfiglio V. Surgical management of retinal detachment because of macular hole in highly myopic eyes. *Retina* 2012;32:1704–18.
- Laviers H, Li JO, Grabowska A, et al. The management of macular hole retinal detachment and macular retinoschisis in pathological myopia; a UK collaborative study. *Eye (Lond)* 2018;32:1743–51.
- Laviers H, Zambarakji H. Management of macular hole retinal detachment and macular retinoschisis secondary to pathological myopia: a national survey of UK practice patterns. *Eye (Lond)* 2013;27:1324.
- Li X, Wang W, Tang S, et al. Gas injection versus vitrectomy with gas for treating retinal detachment owing to macular hole in high myopes. *Ophthalmology* 2009;116:1182–7.e1.
- Yu J, Wang F, Cao H, et al. Combination of internal limiting membrane peeling and endophotocoagulation for retinal detachment related to high myopia in patients with macular hole. *Ophthalmic Surg Lasers Imaging* 2010;41:215–21.
- Chen SN, Yang CM. Inverted internal limiting membrane insertion for macular hole-associated retinal detachment in high myopia. *Am J Ophthalmol* 2016;162:99–106.e1.
- Chen SN, Yang CM. Lens capsular flap transplantation in the management of refractory macular hole from multiple etiologies. *Retina* 2016;36:163–70.
- Lai CC, Chen YP, Wang NK, et al. Vitrectomy with internal limiting membrane repositioning and autologous blood for macular hole retinal detachment in highly myopic eyes. *Ophthalmology* 2015;122:1889–98.
- Lai CC, Wang NK, Chuang LH, et al. Blood clump-assisted vitrectomy and internal limiting membrane peeling for macular hole repair. *Retina* 2011;31:2014–20.
- Michalewska Z, Michalewski J, Adelman RA, et al. Inverted internal limiting membrane flap technique for large macular holes. *Ophthalmology* 2010;117:2018–25.
- Michalewska Z, Michalewski J, Dulczewska-Cichecka K, et al. Inverted internal limiting membrane flap technique for surgical repair of myopic macular holes. *Retina* 2014;34:664–9.
- Kuriyama S, Hayashi H, Jingami Y, et al. Efficacy of inverted internal limiting membrane flap technique for the treatment of macular hole in high myopia. *Am J Ophthalmol* 2013;156:125–31.e1.
- Mancino R, Ciuffoletti E, Martucci A, et al. Anatomical and functional results of macular hole retinal detachment surgery in patients with high myopia and posterior staphyloma treated with perfluoropropane gas or silicone oil. *Retina* 2013;33:586–92.
- Caicedo A, Espinosa-Heidmann DG, Pina Y, et al. Blood-derived macrophages infiltrate the retina and activate Muller glial cells under experimental choroidal neovascularization. *Exp Eye Res* 2005;81:38–47.
- Winkler J, Hagelstein S, Rohde M, et al. Cellular and cytoskeletal dynamics within organ cultures of porcine neuroretina. *Exp Eye Res* 2002;74:777–88.
- Martin F, Pastor JC, De La Rua ER, et al. Proliferative vitreoretinopathy: cytologic findings in vitreous samples. *Ophthalmic Res* 2003;35:232–8.
- Terasaki H, Miyake Y, Nomura R, et al. Focal macular ERGs in eyes after removal of macular ILM during macular hole surgery. *Invest Ophthalmol Vis Sci* 2001;42:229–34.
- Rosen RB, Hathaway M, Rogers J, et al. Multidimensional en-face OCT imaging of the retina. *Opt Express* 2009;17:4112–33.
- Forte R, Cennamo G, Pascotto F, et al. En face optical coherence tomography of the posterior pole in high myopia. *Am J Ophthalmol* 2008;145:281–8.
- Tammewar AM, Bartsch DU, Kozak I, et al. Imaging vitreomacular interface abnormalities in the coronal plane by simultaneous combined scanning laser and optical coherence tomography. *Br J Ophthalmol* 2009;93:366–72.
- Liggett PE, Skolik DS, Horio B, et al. Human autologous serum for the treatment of full-thickness macular holes. A preliminary study. *Ophthalmology* 1995;102:1071–6.
- Christmas NJ, Skolik SA, Howard MA, et al. Treatment of retinal breaks with autologous serum in an experimental model. *Ophthalmology* 1995;102:263–71.
- Nishimura A, Kimura M, Saito Y, et al. Efficacy of primary silicone oil tamponade for the treatment of retinal detachment caused by macular hole in high myopia. *Am J Ophthalmol* 2011;151:148–55.