

Descemet's tear due to injector cartridge tip deformity

*Partha Biswas, Subhrangshu Sengupta, Ajoy Paul,
Lav Kochgaway, Sayantan Biswas¹*

Foldable intraocular lens (IOL) implantation using an injector

B B Eye Foundation, 2/5, Sarat Bose Road, Kolkata, ¹Elite School of Optometry, Chennai, Tamil Nadu, India

Correspondence to: Dr. Partha Biswas, Cluster 7, House Number 4, Purbachal, Salt Lake, Kolkata - 700 097, India.
E-mail: drpartha_biswas07@yahoo.co.in

Manuscript received: 03.04.11; Revision accepted: 21.09.11

system through 2.8-mm clear corneal incision following phacoemulsification provides excellent speedy postoperative recovery. In our reported case, a Sensar AR40e IOL (Abbott Medical Optics, USA) was loaded into Emerald C cartridge, outside the view of the operating microscope, by the first assistant. The surgeon proceeded with the IOL injection through a 2.8-mm clear corneal incision after uneventful phacoemulsification, immediately following which he noted a Descemet's tear with a rolled out flap of about 2 mm near the incision site. Gross downward beaking of the bevelled anterior end of the cartridge was subsequently noticed upon examination under the microscope. We suggest careful preoperative microscopic inspection of all instruments and devices entering the patient's eyes to ensure maximum safety to the patient.

Key words: Cartridge tip, descemet's tear, intraocular Lens, phacoemulsification

Cite this article as: Biswas P, Sengupta S, Paul A, Kochgaway L, Biswas S. Descemet's tear due to injector cartridge tip deformity. *Indian J Ophthalmol* 2012;60:218-20.

Access this article online

Quick Response Code:	Website: www.ijo.in
	DOI: 10.4103/0301-4738.95877

Phacoemulsification (PE) with posterior chamber intraocular lens (PC IOL) implantation has emerged as the preferred technique for surgical correction of cataract.^[1] One of the most popular ways to implant a foldable intraocular lens (IOL) through a small incision is by using an injector system. These systems usually consist of two parts: the injector and the cartridge.^[2] There have been several reports of damage occurring to IOLs while implantation using injector systems.^[2]

Our case report describes gross deformity of cartridge tips of the injector system of a particular make, resulting in inadvertent trauma to the main incision port and localized damage to the Descemet's membrane of the eye during IOL implantation.

Case Report

A 56-year-old female presented with best corrected visual acuity (BCVA) of 20/120 and nuclear sclerosis (nuclear opacity 3, nuclear color 2 using Lens Opacification Classification System III)^[3] in the left eye (LE). She was posted for PE with foldable PC IOL implantation (LE). Preoperative endothelial cell count was 2653/mm².

The surgery was performed using proparacaine drops (Paracain Ophthalmic Solution 0.5%, Sunways Pvt. Ltd., Mumbai, India) through a 2.8-mm temporal clear corneal incision. All surgical steps including PE were uneventful. A foldable IOL of +22.5 D of the Sensar AR40e variety [Abbott Medical Optics Inc (AMO), 1700 E. St. Andrew Place, Santa Ana, CA 92705 USA] was loaded into the Emerald C Cartridge (Lot CH00841 of AMO Inc., USA) by the first assistant outside the field of the operating microscope to save the surgical time. The cartridge was inserted in the injector and the loaded injector was handed to the surgeon. The tip of the cartridge was just inserted snugly by slight rotatory motion into the anterior chamber through the 2.8-mm incision. However, while removing the injector system, it was noticed that there was a gross downward beaking of the bevelled anterior end of the cartridge [Fig. 1] which had earlier passed unnoticed. Immediately, the incision site was inspected under the operating microscope and a Descemet's tear was detected with a rolled out flap of about 2 mm in length. The viscoelastic was meticulously washed out and the main incision wound and the two side port entries were carefully hydrated and an air bubble was injected into the anterior chamber.

On the first postoperative day, the patient's LE had an uncorrected VA of 20/60 with a small rolled out Descemet's flap and adjacent Descemet's striae at the site of the main clear corneal incision (temporally) [Fig. 2] with mild corneal edema. The edema persisted at 7 days post-op with mild resolution.

However, the rolled out flap was not evident any more. A corneal opacity remained at the deeper corneal layers with mild surrounding edema, even at the time of last check-up at 4 weeks post-op, with a BCVA of 20/30 [Fig. 3]. The corneal endothelial cell count 4 weeks after surgery was 2332/mm².



Figure 1: Downward beaking of the beveled anterior end of the Emerald C Cartridge (Lot CH00841 of Advanced Medical Optics, Inc., USA)

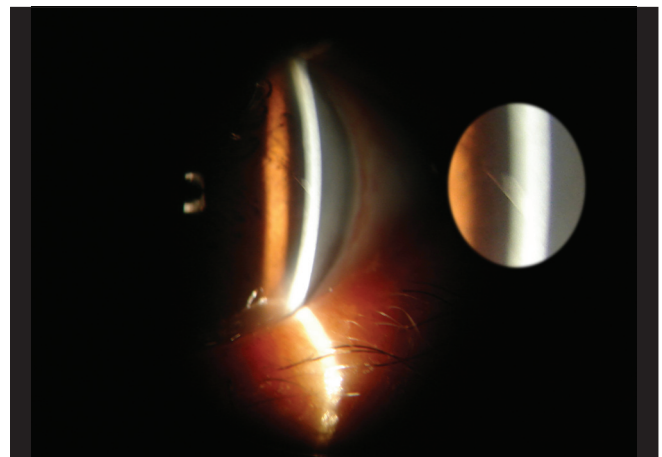


Figure 2: A small rolled out Descemet's flap and adjacent Descemet's striae (left eye of the reported case on the first postoperative day)

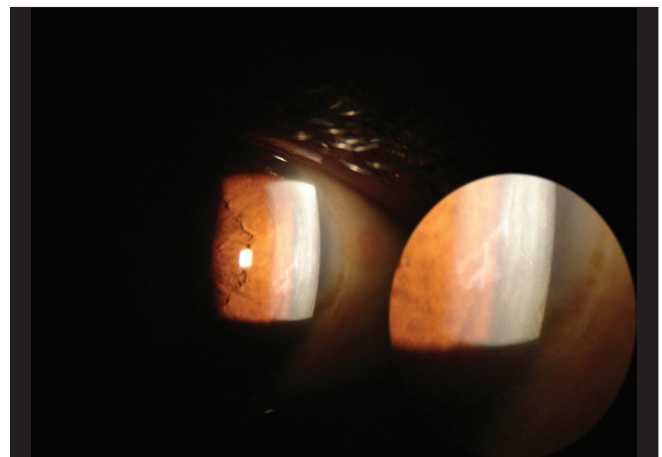


Figure 3: Corneal opacity at the deeper corneal layers with mild surrounding edema (left eye of the reported case at 4 weeks post-op)

Discussion

Damage to IOLs as a consequence of passage through various injector systems includes marks or scratches,^[4] stress fractures, cracks and tear lines.^[5]

Damage to Descemet's membrane can occur due to various factors during cataract surgery, including engaging of Descemet's membrane by the leading haptic during IOL implantation^[6] or with the irrigation/aspiration device (when mistaken as an anterior capsular remnant)^[7] or due to inadvertent injection of viscoelastic between Descemet's membrane and corneal stroma.^[8] Repair techniques include manual repositioning,^[9] repositioning with viscoelastic^[9] or air,^[9] suturing of Descemet's membrane to the peripheral cornea^[9] or use of SF₆^[8] or C₃F₈.

Our case report describes injury to the corneal endothelium and Descemet's membrane intraoperatively due to frayed and beaked tip of the AMO Emerald C cartridge. Such occurrences have not yet been reported, to the best of our knowledge. The case has been followed up for a period of about 4 weeks as on the day of reporting, and as the visual axis was not completely involved, the vision is maintained, although the Descemet's stria and mild surrounding edema remains. We have reported only a single case; however, a damaged AMO Emerald C cartridge has been found in a few subsequent cases in our institute. In cases where a back-up cartridge was not available, the size of the clear corneal incision was increased to 3.2 mm at least to protect the entry wound architecture and the corneal endothelium, while injecting the IOL using the damaged cartridge. Postoperative recovery was uneventful in such cases.

The cause of the damaged nature of the AMO Emerald C cartridges appears to be a manufacturer's oversight which has been duly informed to the concerned authorities, who have assured speedy correction of the defect.

These cartridges are delivered in sterile transparent cases and the tip can be easily examined under the slit lamp beforehand without opening the casing. This should be made a routine practice as this will allow any damaged cartridge to be replaced before starting the surgery by ordering a fresh one from the manufacturer.

We suggest loading of the foldable IOL should be done

by the surgeon himself under the operating microscope. The speed of the surgery should never compromise the quality of the surgery and/or the final visual outcome. With the advent of newer techniques like the microincision cataract surgery (MICS), surgeons also cannot compromise on the incision size or wound integrity and architecture. The onus is on the various manufacturing companies to provide surgeons with precision instruments that are both safe and durable for the patient's eyes. And more importantly, every instrument entering the patient's eye should undergo careful preoperative microscopic inspection by the operating surgeon himself so that a microscopic manufacturing defect can be identified and immediate rectification of the situation can be done.

References

1. Buehl W, Findl O. Effect of intraocular lens design on posterior capsule opacification. *J Cataract Refract Surg* 2008;34:1976-85.
2. Kleinmann G, Apple DJ. Evaluation of a new soft tipped injector for the implantation of foldable intraocular lenses. *Br J Ophthalmol* 2007;91:1070-2.
3. Chylack LT Jr, Wolfe JK, Singer DM, Leske MC, Bullimore MA, Bailey IL, *et al.* The Lens Opacities Classification System III. The Longitudinal Study of Cataract Study Group. *Arch Ophthalmol* 1993;111:831-6.
4. Milazzo S, Turut P, Blin H. Alterations to the AcrySof intraocular lens during folding. *J Cataract Refract Surg* 1996;22:1351-4.
5. Kohnen T, Magdowski G, Koch DD. Scanning electron microscopic analysis of foldable acrylic and hydrogel intraocular lenses. *J Cataract Refract Surg* 1996;22:1342-50.
6. Mannan R, Pruthi A, Om Parkash R, Jhanji V. Descemet membrane detachment during foldable intraocular lens implantation. *Eye Contact Lens* 2011;37:106-8.
7. Marcon AS, Rapuano CJ, Jones MR, Laibson PR, Cohen EJ. Descemet's membrane detachment after cataract surgery: management and outcome. *Ophthalmology* 2002;109:2325-30.
8. Walland MJ, Stevens JD, Steele AD. Repair of Descemet's membrane detachment after intraocular surgery. *J Cataract Refract Surg* 1995;21:250-3.
9. Zeiter HJ, Zeiter JT. Descemet's membrane separation during five hundred forty-four intraocular lens implantations. 1975 - 1982. *J Am Intraocul Implant Soc* 1983;9:36-9.