



ORIGINAL ARTICLE

# Alveolar bone plate measurements of maxillary anterior teeth: A retrospective Cone Beam Computed Tomography study, AlMadianh, Saudi Arabia



Hamsah Sheerah <sup>a</sup>, Badr Othman <sup>b</sup>, Arwa Jaafar <sup>c</sup>, Alla Alsharif <sup>b,\*</sup>

<sup>a</sup> Taibah University Dental College, Almadinah, Saudi Arabia

<sup>b</sup> Preventive Dental Science, Taibah University Dental College & Hospital, Almadinah, Saudi Arabia

<sup>c</sup> Oral and Maxillofacial Surgery, Taibah University Dental College & Hospital, Almadinah, Saudi Arabia

Received 12 December 2018; revised 5 April 2019; accepted 9 April 2019

Available online 13 April 2019

## KEYWORDS

Alveolar ridge;  
Computer-assisted image  
analysis;  
Maxilla;  
Teeth

**Abstract** *Purpose:* To study bone profile (facial bone thickness and height of alveolar bone crest) of anterior maxillary teeth in the aesthetic area among Saudi dentulous adults.

*Methods:* This retrospective study was conducted at Taibah University College of Dentistry and Hospital, AlMadinah; Saudi Arabia. The analysis included 490 adult patients' Cone Beam Computed Tomography (CBCT) retrieved from Kodak Carestream-R4 database. Alveolar bone thickness and crest bone-height for maxillary anterior teeth were measured directly on CBCT images using built-in digital caliper. Descriptive statistics and comparative analysis were performed.

*Results:* Of the 490 CBCTs 186 were found useable for the study purpose. The mean age of the patients was  $34.65 \pm 11.57$  and 109 (59%) were males. Statistically significant ( $P < 0.001$ ) differences were found between the mean  $\pm$  SD facial plate thickness of the central incisors, lateral incisors, and canines ( $1.12 \pm 0.28$  mm,  $1.14 \pm 0.31$  mm, and  $1.03 \pm 0.24$  mm, respectively). In addition, facial plate height increased statistically significantly positively with age for the central incisors, lateral incisors, and canines ( $r = 0.543$ ,  $n = 186$ ,  $p = 0.001$ ;  $r = 0.515$ ,  $n = 186$ ,  $p = 0.001$ ;  $r = 0.474$ ,  $n = 186$ ,  $p = 0.001$ , respectively). Genderwise, males had statistically significantly ( $P < 0.00$ ) higher facial bone thickness e.g. in central incisor (males  $1.20 \pm 0.29$  VS females

\* Corresponding author at: Preventive Dental Science, Taibah University Dental College & Hospital, Prince, Naif Ibn Abdulaziz, Al-Madinah Al-Munawwrah 42353, Saudi Arabia.

E-mail address: [dr-alsharif@hotmail.com](mailto:dr-alsharif@hotmail.com) (A. Alsharif).

Peer review under responsibility of King Saud University.



$1.04 \pm 0.25$ ,  $p = 0.001$ ) and increased bone height (Males  $2.62 \pm 0.77$  VS females  $2.09 \pm 0.66$ ,  $p = 0.001$ ) compared to females.

**Conclusion:** In this study, the significant differences in bone thickness and crest height between anterior maxillary teeth in the aesthetic area was highlighted. Notably, increases in facial plate crest height was linked to age and male and female differed on both facial bone thickness and bone height.

© 2019 The Authors. Production and hosting by Elsevier B.V. on behalf of King Saud University. This is an open access article under the CC BY-NC-ND license (<http://creativecommons.org/licenses/by-nc-nd/4.0/>).

## 1. Introduction

Radiography is a vital diagnostic tool used in clinical dental practices (Author et al., 2006). Cone beam computed tomography (CBCT), an emerging digital imaging technique, enables investigators to assess various conditions of tissue and craniofacial hard tissues via multiplanar visualization (Author et al., 2006; Kumar et al., 2015). CBCT imaging can provide high-quality images with one tenth decrease in radiation below that of more conventional CT scanning approaches (Kumar et al., 2015). Because of its high degree of accuracy and precision, CBCT imaging is widely used in various aspects of dental care and especially in tooth implant procedures (Kumar et al., 2015).

Implant dentistry has gained widespread attention in recent years, especially for use in cases requiring anterior tooth replacement (Zhou et al., 2014). Several studies have described reliable and accurate results using a CBCT-based approach to case selection, assessment of bone quality and quantity, and implant placement guidance (Kumar et al., 2015). Facial plate bone thickness and crest height in aesthetic regions of the anterior maxilla are critical factors in the selection of treatment approaches, especially when planning for immediate implant placement.

After tooth extraction, inevitable changes tend to occur, including alveolar bone resorption and remodeling, especially in the area of the facial plate (Caiazzo et al., 2013). This is an important factor to consider, as it affects the success of implant placement, which in turn affects aesthetic outcomes. Therefore, the assessment of the alveolar bone (using CBCT imaging) aids in the determination of correct implant position; this is key for successful treatment with an optimum aesthetic result (Zhou et al., 2014). CBCT aids in the determination of alveolar bone thickness and serves as a prognostic tool for the prediction of pre- and post-surgical implant placement complications (Zhang et al., 2015).

Several studies have described different factors and conditions that may underlie alveolar bone thickness differences among patients. Gracco et al. (2009) investigated the relationship between alveolar bone thickness and upper jaw morphology, position of the upper incisors, and facial type. They found that the type of face (e.g. shorter face type individuals have greater alveolar bone thickness compared to long face individuals), inclination of the incisors, and degree of jaw protrusion all correlated with alveolar bone thickness in the maxillary incisor region (Gracco et al., 2009). Morad et al. (2014) further measured facial bone thickness near the maxillary and anterior mandibular teeth, as well as the vertical distance from the cemento-enamel junction to the bone crest (Morad et al., 2014). These authors reported mean thicknesses of 1–1.2 mm and 0.5–0.8 mm in the maxillary and mandibular anterior

tooth regions, respectively. Jin et al. (2012) similarly investigated buccal and palatal bone thicknesses near the maxillary canines and premolars, with a particular focus on the side of the tooth and gender differences (Jin et al., 2012). They reported a thickness  $< 2$  mm in the canine area and one of  $> 2$  mm in the premolar area.

Several studies involving different patient samples have similarly demonstrated subtle differences between various ethnic populations (Morad et al., 2014; Zhou et al., 2014). Factors such as population characteristics, gender, side of the tooth, face type, and soft tissue type may influence the thickness and height of the facial plate of the alveolar bone. However, age- and gender-based studies of alveolar bone thickness in Saudi populations have not yet been performed. Therefore, the present study used CBCT images to measure alveolar bone thickness and crest height in the aesthetic zone of the maxillary anterior teeth in a population of adult Saudi patients, with a particular focus on the role of gender and age.

## 2. Material and methods

### 2.1. Study design and setting

This study had a retrospective cross-sectional design and used CBCT imaging to measure alveolar bone thickness and crest bone height in the aesthetic zone of the maxillary anterior teeth. CBCT scans of 490 adult patients were obtained from Taibah University College of Dentistry and Hospital (TUCDH) database, AlMadinah, Saudi Arabia. All scans were obtained previously for various clinical reasons (e.g., removal of impacted teeth). The present study was conducted between March and April 2017.

This study was reviewed and approved by Taibah University College of Dentistry Research Ethics Committee (Reference No.: TUCDREC20170211Sheerah).

### 2.2. Sample size

Sample size was calculated using Epi Info StatCal software version 7 (Centers for Disease Control and Prevention, USA), with a 95% confidence level and an expected frequency of 50% to indicate a significant difference and effect within the representative population.

### 2.3. Inclusion and exclusion criteria

The sample included 186 CBCT scans of bilateral permanent maxillary anterior teeth in individuals aged 18–65 years. Individuals who met the previous criteria were included in the analyses. Images in which one or more anterior teeth were missing,

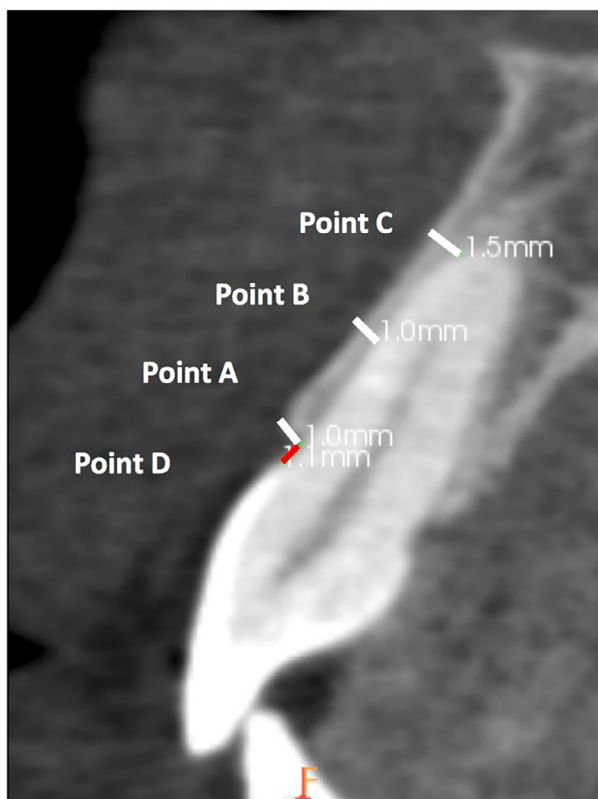
images with implants in the anterior teeth area, and images with distortions or poor-quality images were excluded. Images from patients with systemic or pathological dento-alveolar conditions (e.g. cyst) that might cause abnormal bone remodeling were also excluded.

#### 2.4. Scan measurements

Measurements on CBCT scans were analyzed by two independently trained dentists. The bilateral upper canines (UC), upper lateral incisors (UL), and upper central incisors (UCI) were included in analyses. Repeated measures reliability between investigators was assessed to measure their degree of agreement. Intraclass correlation coefficients (ICCs) were calculated to assess outcome reproducibility and consistency between all repeated measures.

#### 2.5. Radiographic assessments

At each tooth, the facial plate thickness of the alveolar bone was measured from a sagittal CBCT image view of the tooth root (Fig. 1). The sagittal section was made at the middle of



**Fig. 1** Measurements of the facial plate of bone thickness in an axial view from the facial aspect of the tooth root in the CBCT. Point A: Thickness measurement from the facial plate at the level of bone crest to the coronal root third. Point B: Thickness measurement from the facial plate to the mid root surface. Point C: Thickness measurement from the facial plate to the apical root third. Point D: Distance from the cemento-enamel junction (CEJ) to the alveolar crest.

each tooth by applying the cursor in the midline that bisecting the tooth into equal halves. Reference points were used to measure alveolar bone thicknesses at three locations using a digital caliper: point A from the facial plate at the level of bone crest to the coronal root third, point B to the mid root surface, and point C to the apical third. All measurements were taken in millimeters (mm). To set fixed reference points for each tooth in the sagittal view, the cursor was placed at the tooth's midline and in the sagittal view, the tooth root was divided equally into cervical, middle, and apical thirds. Reference points were set at the mid-point of each third, while the cemento-enamel junction (CEJ) was set as a fixed reference point for measuring crest height.

Crest-height (point D) was measured as the distance from the CEJ to the alveolar bone crest. This was performed using the same sagittal view as that used for measuring thicknesses and the same digital caliper as mentioned above. All measurements were in millimeters (mm). The built-in digital caliper was also used for direct bone measurements on CBCT images. All images were viewed on the same monitor and under the same lighting conditions.

#### 2.6. Statistical analyses

Data analyses were conducted using SPSS software (IBM, Armonk, NY). Descriptive and comparative analyses were performed on all quantitative data. Independent-sample t-tests and Pearson correlation tests were used to analyze the data. ANOVA Test followed by Tukey post hoc analysis was performed. Intra-rater and inter-rater measurements were measured using ICC testing. The significance level was set at 95%, with P-values <0.05 considered significant.

This study was conducted in compliance with all STROBE guidelines.

### 3. Results

#### 3.1. Sample characteristics and reliability testing

A total of 186 cases (109 males and 77 females) were included in the present study with a mean age of  $34.65 \pm 11.57$  years. One thousand and sixteen teeth were measured. Of these, 372 of the teeth imaged were central incisors, 372 were lateral incisors, and 372 were canines. ICC testing was performed on a random subset using SPSS (40% of the total cases) to measure intra-rater reproducibility, as well as to assess the validity of the collected data. A high degree of reliability was found between repeated measurements of the facial plate thickness of the alveolar bone. An average ICC of 0.994 with a 95% confidence interval from 0.992 to 0.995 ( $P = 0.001$ ) was found. A high degree of reliability was also found with repeated measurements of the facial plate thickness of the alveolar bone. The average ICC from this measure was 0.994, with a 95% confidence interval from 0.992 to 0.995 ( $P = 0.001$ ). A high degree of reliability was found between the repeated measurements of the facial plate height. The average ICC for this measure was 0.999, with a 95% confidence interval from 0.998 to 0.999 ( $P = 0.001$ ). The intra-rater reliability values for each examiner were greater than 0.9 which indicate good reliability.

3.2. Facial bone thickness

Table 1 shows the percentages of teeth with various facial alveolar bone thicknesses. With regard to central incisors, nearly 89% exhibited average facial alveolar bone thicknesses of < 1.5 mm, 11% exhibited facial bone thicknesses between 1.5 and 2 mm, and only 0.5% exhibited thicknesses of > 2 mm. With regard to lateral incisors, 83% exhibited average facial bone thicknesses of < 1.5 mm, while 15% and 1% exhibited thicknesses of 1.5–2 mm and > 2 mm, respectively. Among the canines, 95% showed average facial bone thicknesses of < 1.5 mm, while 5% exhibited thicknesses between 1.5 and 2 mm.

The mean facial plate thicknesses of the alveolar bone for the upper anterior teeth across measurement points are summarized in Table 2. The average facial plate thicknesses for the central incisors, lateral incisors, and canines were 1.12 ± 0.28 mm, 1.14 ± 0.31 mm, and 1.03 ± 0.24 mm, respectively. The ANOVA Test followed by post hoc analysis showed there was statistically significant (p = 0.0005) difference between groups.

Mean bilateral differences in facial plate thicknesses at the upper anterior teeth are presented in Table 3. The smallest mean facial bone thickness (0.83 mm) was detected at point B of the left canine, while the highest mean value (1.58 mm) was determined at point C of the lateral incisors. An unpaired

*t*-test revealed no significant differences between the right and left sides of the canines, lateral incisors, and central incisors in terms of facial plate bone thickness of the upper anterior teeth (Table 3).

An independent-samples *t*-test was used to compare the right and left sides of the anterior teeth across genders (Table 4). The facial bone thickness at the anterior teeth was significantly greater in males than in females (Table 4). Facial plate thicknesses in the upper anterior teeth across participant ages were compared via a Pearson correlation coefficient; no correlation was observed between facial bone thicknesses and age (Table 5).

3.3. Facial crest bone height

Mean alveolar bone height of the maxillary anterior teeth did not differ significantly (Table 6). An independent *t*-test comparing bone ridge height differences in the maxillary anterior teeth between genders (Table 6) revealed significant differences in bone ridge height, with males exhibiting greater facial bone heights than those of females (P < 0.001; Table 6). An unpaired *t*-test was used to assess differences in facial plate height between the right and left sides (Table 6), and no significant differences were observed. Scatterplots and correlation analyses revealed a significant positive relationship between age and facial plate height for the upper central incisors, upper lateral incisors, and upper canines (r = 0.543, n = 186, p = 0.001; r = 0.515, n = 186, p = 0.001; and r = 0.474, n = 186, p = 0.001, respectively) (Fig. 2A–C). Overall, there was a moderate, positive correlation between age and facial plate height, suggesting that older individuals were more likely to exhibit greater facial plate heights compared with younger individuals.

4. Discussion

Dental implant placement following extraction is a common dental procedure. Satisfactory results and long-term stability

**Table 1** Frequency and percentages of the facial plate thickness of alveolar bone within each category.

| Categories of facial plate thickness (mm)* | Central incisor n (%) | Lateral incisor n (%) | Canine n (%) |
|--|-----------------------|-----------------------|--------------|
| < 1.5                                      | 165(88.7)             | 155(83.3)             | 177 (95.2)   |
| 1.5– 2                                     | 20(11)                | 28(15.1)              | 9(4.8)       |
| > 2  | 1(0.5)                | 2(1.1)                | 0(0.0)       |

\* < 1.5: less than required thickness, 1.5–2: minimally required thickness and > 2: preferable required thickness.

**Table 2** The means thicknesses of the facial plate of the alveolar bone of the upper anterior teeth (N = 186).

| Distance (mm)     | Central incisor Mean ± Std. | P- value* | Lateral incisor Mean ± Std. | P- value* | Canine Mean ± Std. | P- value* |
|-------------------|-----------------------------|-----------|-----------------------------|-----------|--------------------|-----------|
| Point A           | 1.21 ± 0.35                 | 0.001     | 0.93 ± 0.47                 | 0.001     | 0.88 ± 0.33        | 0.001     |
| Point B           | 0.96 ± 0.35                 |           | 0.92 ± 0.39                 |           | 0.84 ± 0.31        |           |
| Point C           | 1.51 ± 0.53                 |           | 1.58 ± 0.62                 |           | 1.38 ± 0.52        |           |
| Average thickness | 1.12 ± 0.28                 |           | 1.14 ± 0.31                 |           | 1.03 ± 0.24        |           |

\* One-way analysis of variance (ANOVA).

**Table 3** The means differences of the facial plate thicknesses of the alveolar bone in the upper anterior teeth per side (N = 186).

| Distance (mm)     | Central incisor (N = 372) |             | Lateral incisor (N = 372) |             | Canine (N = 372) |             |
|-------------------|---------------------------|-------------|---------------------------|-------------|------------------|-------------|
|                   | Right                     | Left        | Right                     | Left        | Right            | Left        |
| Point A           | 0.91 ± 0.42               | 0.92 ± 0.46 | 0.94 ± 0.55               | 0.92 ± 0.45 | 0.85 ± 0.27      | 0.92 ± 0.55 |
| Point B           | 0.99 ± 0.52               | 0.94 ± 0.32 | 0.91 ± 0.46               | 0.94 ± 0.48 | 0.84 ± 0.43      | 0.83 ± 0.32 |
| Point C           | 1.41 ± 0.58               | 1.36 ± 0.62 | 1.58 ± 0.74               | 1.58 ± 0.65 | 1.41 ± 0.58      | 1.36 ± 0.63 |
| Average thickness | 1.13 ± 0.34               | 1.13 ± 0.30 | 1.15 ± 0.37               | 1.15 ± 0.35 | 1.04 ± 0.29      | 1.04 ± 0.30 |

For all comparisons p > 0.05.

**Table 4** Comparison of means facial plate thicknesses of the alveolar bone of the upper anterior teeth based on gender (N = 186).

| Tooth           | Point measured*   | Gender (Mean ± SD) |             | P-value** |
|-----------------|-------------------|--------------------|-------------|-----------|
|                 |                   | Females            | Males       |           |
| Central incisor | POINT A           | 1.0 ± 0.30         | 1.28 ± 0.38 | 0.001     |
|                 | POINT B           | 0.89 ± 0.30        | 1.01 ± 0.38 | 0.01      |
|                 | POINT C           | 1.38 ± 0.52        | 1.58 ± 0.53 | 0.01      |
|                 | Average thickness | 1.04 ± 0.25        | 1.20 ± 0.29 | 0.001     |
| Lateral incisor | POINT A           | 0.8 ± 0.22         | 1.02 ± 0.58 | 0.002     |
|                 | POINT B           | 0.88 ± 0.47        | 0.96 ± 0.33 | 0.202     |
|                 | POINT C           | 1.47 ± 0.57        | 1.66 ± 0.66 | 0.054     |
|                 | Average thickness | 1.05 ± 0.3         | 1.2 ± 0.3   | 0.001     |
| Canine          | POINT A           | 0.83 ± 0.24        | 0.92 ± 0.38 | 0.062     |
|                 | POINT B           | 0.80 ± 0.36        | 0.87 ± 0.25 | 0.131     |
|                 | POINT C           | 1.26 ± 0.51        | 1.48 ± 0.53 | 0.005     |
|                 | Average thickness | 0.96 ± 0.24        | 1.09 ± 0.24 | 0.001     |

\* Measures were in millimeters.

\*\* Independent *t*-test.**Table 5** Correlation coefficients between age and the facial plate thickness of the alveolar bone measurement points in the maxillary anterior teeth.

| Facial plate thickness of the alveolar bone per tooth |                   | AGE    |         |
|---|-------------------|--------|---------|
|   |                   | r      | P-value |
| Central incisor                                       | POINT A           | -0.59  | 0.427   |
|   | POINT B           | -0.022 | 0.77    |
|   | POINT C           | -0.095 | 0.198   |
|   | Average thickness | -0.35  | 0.637   |
| Lateral incisor                                       | POINT A           | 0.037  | 0.62    |
|   | POINT B           | 0.023  | 0.76    |
|   | POINT C*          | -0.201 | 0.006   |
|   | Average thickness | -0.11  | 0.15    |
| Canine  | POINT A           | -0.036 | 0.63    |
|   | POINT B           | -0.096 | 0.19    |
|   | POINT C           | -0.101 | 0.17    |
|   | Average thickness | -0.128 | 0.08    |

\* Pearson correlation is significant at 0.01 level.

with implant treatment depend on the presence of a facial plate of sufficient height and thickness. Furthermore, the maxillary anterior region presents considerable challenges because

changes in it are often aesthetically notable to patients. Simultaneously, several local risk factors can compromise the quality of implant outcomes (Zhang et al., 2015). Examining facial plate thickness at the location of each tooth to be extracted and replaced with an implant is thus crucial for selection of the appropriate treatment for the anterior maxillary region (Zhang et al., 2015). Therefore, the present study aimed to use CBCT images to measure the facial thickness and height of the alveolar bone in relation to the maxillary anterior teeth.

Ideally, the facial bone wall should be at least 1.5–2 mm thick to avoid facial plate resorption immediately following dental implantation and to ensure proper soft tissue support. If this requirement is not met and an excessively thin facial bone is used, fenestration, dehiscence, and recession are possible, which may further result in poor aesthetics (Cha et al., 2016). Moreover, there is a bidirectional relationship between buccal bone thickness and crestal labial soft tissue. As a soft tissue profile is highly influenced by bone thickness, a role of thick soft tissue in protecting against crestal bone loss. Given this, thick tissue biotypes are associated with higher crestal bone levels, less gingival recession, and better aesthetic results than are thinner biotypes (Le and Borzabadi-Farahani, 2012). In the present study, the apical third of the facial bone appeared to have the most favorable thickness. These results

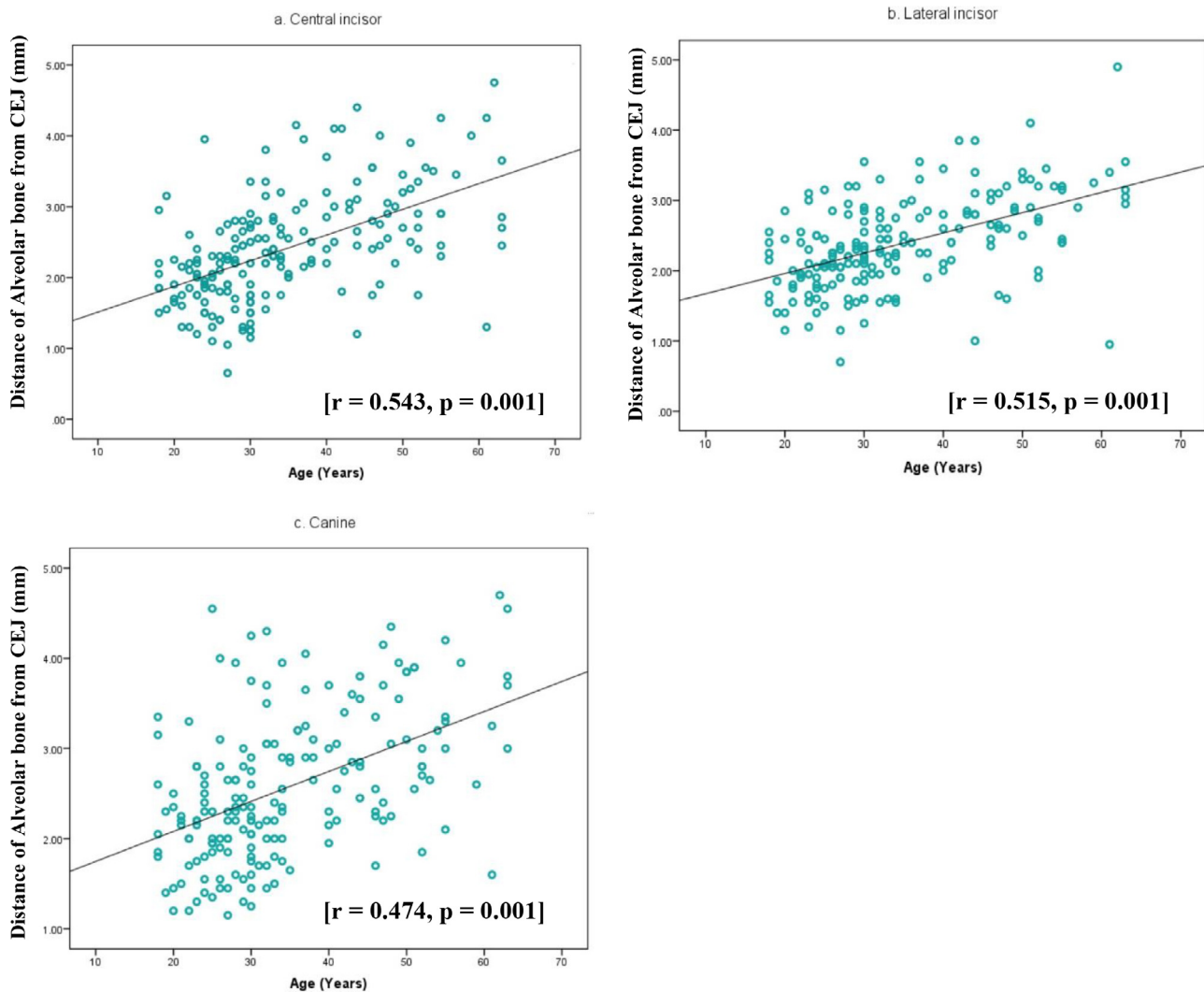
**Table 6** Comparison of the means facial bone height (in mm) of each upper anterior tooth based on gender and side of the tooth (N = 186).

| Distance point D* |         | Central incisor Mean ± Std. | Lateral incisor Mean ± Std. | Canine mean ± Std. |
|-------------------|---------|-----------------------------|-----------------------------|--------------------|
| All**             |         | 2.40 ± 0.77                 | 2.38 ± 0.64                 | 2.56 ± 0.81        |
| Gender‡           | Males   | 2.62 ± 0.77                 | 2.51 ± 0.70                 | 2.74 ± 0.81        |
|                   | Females | 2.09 ± 0.66                 | 2.20 ± 0.52                 | 2.31 ± 0.74        |
| Side              | Right   | 2.34 ± 0.77                 | 2.33 ± 0.73                 | 2.55 ± 0.96        |
|                   | Left    | 2.47 ± 0.88                 | 2.43 ± 0.73                 | 2.58 ± 0.83        |

\* Measures were in millimeters.

\*\* ANOVA is significant at 0.03 level.

‡ Independent *t*-test is significant at 0.001 level.



**Fig. 2** Scatter plot showing the relationship between age (year) and the distance of alveolar bone from CEJ (mm) in the maxillary anterior teeth. (a) Central incisor, (b) Lateral incisor and (c) Canine.

are of particular significance because they demonstrate that even a slightly deeper placement of an immediate implant might allow for increased stability and thus the desired emergence profile.

The present analyses indicate that canines have the least bone thickness while lateral incisors have the greatest bone thickness among the maxillary anterior teeth. These results are consistent with those of previous clinical studies (Ghassemian et al., 2012; Han and Jung, 2011). However, others with smaller sample sizes have reported that the canines have the greatest facial plate thickness among the anterior teeth (Fuentes et al., 2015; Lee et al., 2010). A thick facial bone wall (mean thickness of  $> 2$  mm) was detected in only 0.5% and 1.6% of the total central and lateral incisors cases assessed in this study, respectively. This outcome is similar to that of other studies of smaller samples (Huynh-Ba et al., 2010; Januário et al., 2011; Nowzari et al., 2012). In contrast, others (Fuentes et al., 2015; Ghassemian et al., 2012) have reported a higher prevalence of thick facial plates in the anterior maxillary region than that reported in our study. These disparities

between studies may be attributed to a number of factors, including sampling variability and population distributions. It must be acknowledged, therefore, that different samples or datasets may lead to over- and underestimations of bone measurements.

We found that one-third of all incisors and nearly half of all canine teeth exhibited thin bone walls (mean thickness of  $< 1$  mm) in the present study. From a clinical perspective, the alveolar bone ridge undergoes a well-documented, substantial resorption within the first 4–8 weeks following a tooth extraction, leading to significant ridge alterations (Buser et al., 2009; Tomasi et al., 2010). Thus, to achieve a successful aesthetic outcome, a bone augmentation procedure with a flap approach is indicated in immediate or early implant placement cases. Generally, bone augmentation is needed to achieve adequate ridge width or height that was lost due to factors including extraction, trauma, periodontal disease, sinus pneumatization, or extended use of removable dentures (Deshmukh et al., 2014). Some studies have, however, suggested bone augmentation even in the absence of bone fenestration.

tration or dehiscence for better aesthetic results (Cha et al., 2016).

The relative impact of socio-demographic characteristics on facial plate thickness in the region of anterior maxillary teeth has been previously investigated. Similar to the findings presented here, studies by Nowzari et al. (2012) and Januário et al. (2011) revealed no correlation between age and facial plate thickness (Januário et al., 2011; Nowzari et al., 2012). When Fuentes et al. investigated the impact of age on facial plate thickness, a pattern different from that described above was observed (Fuentes et al., 2015). These results further indicate a significant trend towards decreased facial plate thickness with increasing age. These differences between studies may be attributed to a number of limitations, such as a small sample size, which may limit the generalizability of conclusions that can be drawn from Fuentes study. Significant differences were also observed between genders in our study, suggesting that males exhibit a greater facial plate thickness than do females. This is inconsistent with the findings of previous studies (Ghassemian et al., 2012; Nowzari et al., 2012; Zekry et al., 2014). Conflicting results can be attributed to the differences in the sample variability and population of interest.

As noted previously, significant buccolingual and apico-coronal dimension reductions in the alveolar ridge are frequently observed following tooth extraction (Van Der Weijden et al., 2009). Some have argued that < 1 mm of mean vertical bone resorption in the maxillary anterior region occurs approximately 1 year after single immediate implant loading (Slagter et al., 2014; Tsuda et al., 2011). Typically and in optimal conditions, the alveolar crest is positioned 2 mm apical to the CEJ (Newman et al., 2015). In the present study, the distance between the facial alveolar bone crest and the CEJ of the anterior teeth ranged from 1.74 to 3.37 mm. Accordingly, in cases with limited or reduced alveolar bone crest height, short implants are a preferable treatment option (Karthikeyan et al., 2012). Insufficient crest height may also influence the interproximal papilla level, which may compromise aesthetic outcomes (Roopak and David, 2015).

Studies investigating the relationship between various socio-demographic factors and their correlations with alveolar bone crest height have revealed age and gender to be significant factors (Boskey and Coleman, 2010; Kelly et al., 1990). The present study revealed a gender difference in bone crest position, with females exhibiting smaller facial bone ridge heights compared with their male counterparts. These results indicate that gender differences must be considered when planning immediate implant placements.

Furthermore, we found no significant differences in ridge height between the right and left facial plates in the present study. When assessing for a correlation with age, the anterior facial alveolar bone crest height was found to positively increase with increased age. This may be explained by changes in bone due to the nature of the aging process (Boskey and Coleman, 2010). However, time-related changes in bone height may also be triggered by subjected load, poor nutrition, changing oral hygiene habits, and hormonal changes, all of which also vary with age (Boskey and Coleman, 2010). In addition, studies have also reported that bone formation is decreased with age (Boskey and Coleman, 2010).

The present study was the first to address this particular topic in Saudi Arabia. In addition, our sample size is large in

comparison to similar prior studies. The present findings may thus be of potentially significant relevance to future work related to implant placement in the study area. However, limitations of the present study should also be noted, such as our use of a hospital-based study population and available medical records data. Further, the study population was of diverse ethnic origins, and this heterogeneity may have influenced our results.

In conclusion, significant differences in bone thickness and crest height between anterior maxillary teeth in the aesthetic area was highlighted. Notably, increases in crest height distance was linked to age and male and female differed on both facial bone thickness and bone height. The study is the first step towards enhancing our understanding of the alveolar bone thickness and crest height in relation to age and gender that were never-before-seen insight to this community. However, we found no significant differences with age or gender. Facial plate bone thickness and crest height in aesthetically relevant anterior maxillary regions can drive the selection of an appropriate treatment approach, especially when immediate implant placement is required. Therefore, the use of CBCT is recommended in the presurgical imaging of these cases, as it reveals critical facial alveolar bone dimensions in relation to the tooth to be extracted. Future experimental studies are recommended to assess facial alveolar bone thickness and height after extraction and immediately following implant placement.

#### Conflict of interest

The authors have stated explicitly that there are no conflicts of interest in connection with this article.

#### Author contributions

B.O. and H.S. conceived the ideas; A.J. and H.S. collected the data; A.A, H.S and A.J analysed the data; all authors led the writing.

#### References

- Author, C., Scarfe, W.C., Farman, A.G., Sukovic, P., 2006. Clinical applications of cone-beam computed tomography in dental practice. *J. Can. Dental Association*, 72.
- Boskey, A.L., Coleman, R., 2010. Critical reviews in oral biology & medicine: aging and bone. *J. Dent. Res.* 89, 1333–1348. <https://doi.org/10.1177/0022034510377791>.
- Buser, D., Halbritter, S., Hart, C., Bornstein, M.M., Grütter, L., Chappuis, V., Belser, U.C., 2009. Early implant placement with simultaneous guided bone regeneration following single-tooth extraction in the esthetic zone: 12-month results of a prospective study with 20 consecutive patients. *J. Periodontol.* 80, 152–162. <https://doi.org/10.1902/jop.2009.080360>.
- Caiazzo, A., Brugnami, F., Mehra, P., 2013. Buccal plate preservation with immediate post-extraction implant placement and provisionalization: preliminary results of a new technique. *Int. J. Oral Maxillofac. Surg.* 42, 666–670. <https://doi.org/10.1016/j.ijom.2012.11.009>.
- Cha, H.-S., Kim, J.-W., Hwang, J.-H., Ahn, K.-M., 2016. Frequency of bone graft in implant surgery. *Maxillofac. Plast. Reconstr. Surg.* 38, 19. <https://doi.org/10.1186/s40902-016-0064-2>.
- Deshmukh, J., Deshpande, S., Khatri, R., Deshpande, S., Deshpande, S., 2014. Vertical and horizontal ridge augmentation in anterior maxilla using autograft, xenograft and titanium mesh with simul-

- taneous placement of endosseous implants. *J. Indian Soc. Periodontol.* 18, 661. <https://doi.org/10.4103/0972-124X.142469>.
- Fuentes, R., Flores, T., Navarro, P., Salamanca, C., Beltrán, V., Borie, E., 2015. Assessment of buccal bone thickness of aesthetic maxillary region: a cone-beam computed tomography study. *J. Periodontal Implant Sci.* 45, 162–168. <https://doi.org/10.5051/jpis.2015.45.5.162>.
- Ghasseman, M., Nowzari, H., Lajolo, C., Verdugo, F., Pirronti, T., D'Addona, A., 2012. The thickness of facial alveolar bone overlying healthy maxillary anterior teeth. *J. Periodontol.* 83, 187–197. <https://doi.org/10.1902/jop.2011.110172>.
- Gracco, A., Lombardo, L., Mancuso, G., Gravina, V., Siciliani, G., 2009. Upper incisor position and bony support in untreated patients as seen on CBCT. *Angle Orthod.* 79, 692–702. <https://doi.org/10.2319/081908-437.1>.
- Han, J.Y., Jung, G.U., 2011. Labial and lingual/palatal bone thickness of maxillary and mandibular anteriors in human cadavers in koreans. *J. Periodontal Implant Sci.* 41, 60–66. <https://doi.org/10.5051/jpis.2011.41.2.60>.
- Huynh-Ba, G., Pjetursson, B.E., Sanz, M., Cecchinato, D., Ferrus, J., Lindhe, J., Lang, N.P., 2010. Analysis of the socket bone wall dimensions in the upper maxilla in relation to immediate implant placement. *Clin. Oral Implants Res.* 21, 37–42. <https://doi.org/10.1111/j.1600-0501.2009.01870.x>.
- Januário, A.L., Duarte, W.R., Barriviera, M., Mesti, J.C., Araújo, M. G., Lindhe, J., 2011. Dimension of the facial bone wall in the anterior maxilla: a cone-beam computed tomography study. *Clin. Oral Implants Res.* 22, 1168–1171. <https://doi.org/10.1111/j.1600-0501.2010.02086.x>.
- Jin, S.H. et al, 2012. The thickness of alveolar bone at the maxillary canine and premolar teeth in normal occlusion. *J. Periodontal Implant Sci.* 42, 173–178.
- Karthikeyan, I., Desai, S., Singh, R., 2012. Short implants: a systematic review. *J. Indian Soc. Periodontol.* 16, 302. <https://doi.org/10.4103/0972-124X.100901>.
- Kelly, P.J., Twomey, L., Sambrook, P.N., Eisman, J.A., 1990. Sex differences in peak adult bone mineral density. *J. Bone Miner. Res.* 5, 1169–1175. <https://doi.org/10.1002/jbmr.5650051112>.
- Kumar, M., Shanavas, M., Sidappa, A., Kiran, M., 2015. Cone beam computed tomography - know its secrets. *J. Int. oral Heal. JIOH* 7, 64–68.
- Le, B.T., Borzabadi-Farahani, A., 2012. Labial bone thickness in area of anterior maxillary implants associated with crestal labial soft tissue thickness. *Implant Dent.* <https://doi.org/10.1097/ID.0b013e31826371b5>.
- Lee, S.-L., Kim, H.-J., Son, M.-K., Chung, C.-H., 2010. Anthropometric analysis of maxillary anterior buccal bone of korean adults using cone-beam CT. *J. Adv. Prosthodont.* 2, 92–96. <https://doi.org/10.4047/jap.2010.2.3.92>.
- Morad, G., Behnia, H., Motamedian, S.R., Shahab, S., Gholamin, P., Khosraviani, K., Nowzari, H., Khojasteh, A., 2014. Thickness of labial alveolar bone overlying healthy maxillary and mandibular anterior teeth. *J. Craniofac. Surg.* 25, 1985–1991. <https://doi.org/10.1097/SCS.0000000000001022>.
- Newman, Michael G; Takei, Henry H; Klokkevold, Perry R; Carranza, F.A., 2015. Clinical Periodontology, in: Carranza's Clinical Periodontology. p. 1776. [http://doi.org/10.1016/0030-4220\(53\)90174-1](http://doi.org/10.1016/0030-4220(53)90174-1)
- Nowzari, H., Molayem, S., Chiu, C.H.K., Rich, S.K., 2012. Cone beam computed tomographic measurement of maxillary central incisors to determine prevalence of facial alveolar bone width ??? 2mm. *Clin. Implant Dent. Relat. Res.* 14, 595–602. <https://doi.org/10.1111/j.1708-8208.2010.00287.x>.
- Roopak, B., David, R.M., 2015. Interdental bone and papilla, hold it to preserve it : a case report. *Int. J. Prev. Clin. Dent. Res.* 2, 73–75.
- Slagter, K.W., den Hartog, L., Bakker, N.A., Vissink, A., Meijer, H.J. A., Raghoobar, G.M., 2014. Immediate placement of dental implants in the esthetic zone: a systematic review and pooled analysis. *J. Periodontol.* 85, e241–e250. <https://doi.org/10.1902/jop.2014.130632>.
- Tomasi, C., Sanz, M., Cecchinato, D., Pjetursson, B., Ferrus, J., Lang, N.P., Lindhe, J., 2010. Bone dimensional variations at implants placed in fresh extraction sockets: a multilevel multivariate analysis. *Clin. Oral Implants Res.* 21, 30–36. <https://doi.org/10.1111/j.1600-0501.2009.01848.x>.
- Tsuda, H., Rungcharassaeng, K., Kan, J.Y.K., Roe, P., Lozada, J.L., Zimmerman, G., 2011. Peri-implant tissue response following connective tissue and bone grafting in conjunction with immediate single-tooth replacement in the esthetic zone: a case series. *Int. J. Oral Maxillofac. Implants* 26, 427–436.
- Van Der Weijden, F., Dell'Acqua, F., Slot, D.E., 2009. Alveolar bone dimensional changes of post-extraction sockets in humans: a systematic review. *J. Clin. Periodontol.* 36, 1048–1058. <https://doi.org/10.1111/j.1600-051X.2009.01482.x>.
- Zekry, A., Wang, R., Chau, A.C.M., Lang, N.P., 2014. Facial alveolar bone wall width - a cone-beam computed tomography study in asians. *Clin. Oral Implants Res.* 25, 194–206. <https://doi.org/10.1111/clr.12096>.
- Zhang, W., Skrypczak, A., Weltman, R., 2015. Anterior maxilla alveolar ridge dimension and morphology measurement by Cone Beam Computerized Tomography (CBCT) for immediate implant treatment planning. *BMC Oral Health* 15, 65. <https://doi.org/10.1186/s12903-015-0055-1>.
- Zhou, Z., Chen, W., Shen, M., Sun, C., Li, J., Chen, N., 2014. Cone beam computed tomographic analyses of alveolar bone anatomy at the maxillary anterior region in chinese adults. *J. Biomed. Res.* 28, 498–505. <https://doi.org/10.7555/JBR.27.20130002>.