

Available online at www.sciencedirect.com

ScienceDirect

journal homepage: www.elsevier.com/locate/radcr

Case Report

Unusual chondroblastoma of the hand with large extraosseous soft tissue component[☆]

Justin Choi, B.A.^a, Morgan A. Darrow, M.D.^b, Lauren Zeitlinger, D.O.^c,
Steven W. Thorpe, M.D.^c, Jasjeet Bindra, M.D.^{d,*}

^a University of California Davis School of Medicine, 4610 X St. Sacramento, CA 95817, USA

^b Department of Pathology and Laboratory Medicine, University of California Davis School of Medicine, 4400 V St. Sacramento, CA 95817, USA

^c Department of Orthopaedic Surgery, University of California Davis School of Medicine, 4860 Y St. Suite 3800 Sacramento, CA 95817, USA

^d Department of Radiology, University of California Davis School of Medicine, 4860 Y St. Suite 3100 Sacramento, CA 95817, USA

ARTICLE INFO

Article history:

Received 13 May 2022

Revised 6 June 2022

Accepted 8 June 2022

Keywords:

Chondroblastoma

Soft tissue

Hamate

Magnetic resonance imaging

ABSTRACT

Chondroblastoma is a rare, benign primary cartilaginous bone tumor that typically arises in the epiphyses of the long bones. Radiologically, a well-defined lytic lesion with thin sclerotic margins is commonly found. The tumor is characterized histologically as an admixture of chondroblasts and multinucleated giant cells with chondroid matrix and pericellular calcifications. We present a case of a chondroblastoma of the hand with an unusual large extraosseous soft tissue component. The mass demonstrated diffuse calcifications and radiolucent lesions in the dorsal aspect of the hamate and metacarpals. Differential diagnoses included synovial chondromatosis, soft tissue chondroma, and tenosynovial giant cell tumor. The patient underwent open biopsy of the mass with plans for excision. Final histopathologic diagnosis was of chondroblastoma of the hamate with a large soft tissue component. A marginal excision of the lesion with curettage and cementation was performed.

© 2022 The Authors. Published by Elsevier Inc. on behalf of University of Washington.

This is an open access article under the CC BY-NC-ND license

(<http://creativecommons.org/licenses/by-nc-nd/4.0/>)

Introduction

In this report, we present an unusual case of a chondroblastoma of the hamate and multiple metacarpal bases with a large soft tissue component. Chondroblastoma is a

rare, benign primary cartilaginous bone tumor that accounts for about 1% of all primary bone tumors [2]. Most commonly found in the epiphyses of the proximal tibia, proximal humerus, and femur, chondroblastomas are rarely seen in the hands [1–6]. One study reported just 6 cases of carpal chondroblastomas out of 26,800 primary bone neoplasms with

[☆] Competing Interests: All authors declare no conflict of interest.

* Corresponding author.

E-mail address: jbindra@ucdavis.edu (J. Bindra).

<https://doi.org/10.1016/j.radcr.2022.06.024>

1930-0433/© 2022 The Authors. Published by Elsevier Inc. on behalf of University of Washington. This is an open access article under the CC BY-NC-ND license (<http://creativecommons.org/licenses/by-nc-nd/4.0/>)

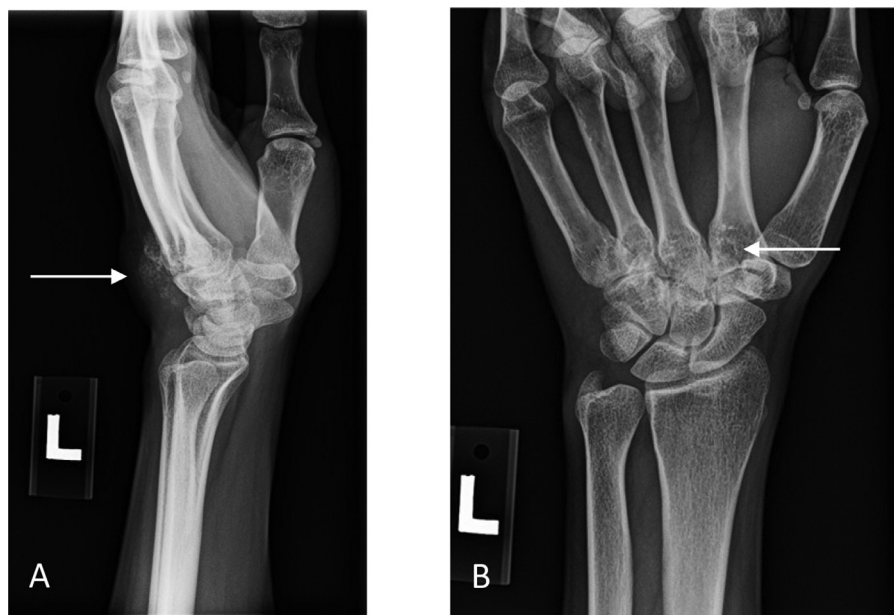

Fig. 1 (A) – Lateral radiograph of the left hand showing a focal lesion (white arrow) at the dorsal aspect of carpometacarpal level with mineralizations in it. **(B)** PA view of the left wrist displaying lucent lesions (white arrow) in the second to fourth metacarpals and hamate. The calcified mass is difficult to see on this radiograph.

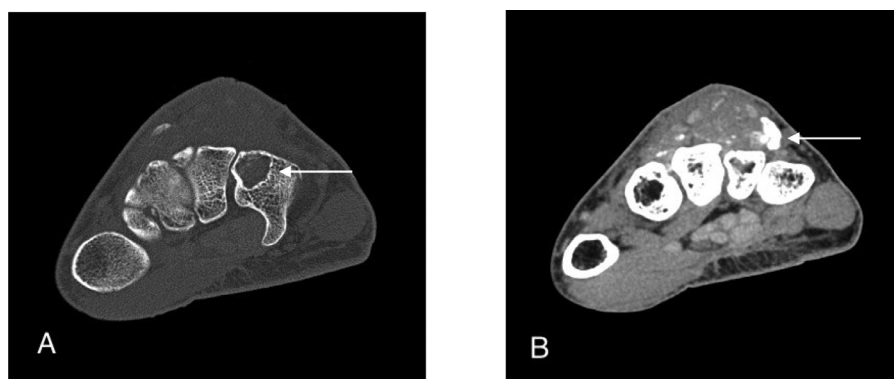


Fig. 2. (A) – Noncontrast axial CT image of the wrist shows a lucent lesion (white arrow) within the dorsal aspect of the hamate with a dorsal soft tissue mass. **(B)** Axial CT image of the wrist slightly distal to the level of A in soft tissue window demonstrates the mass (white arrow) to a better advantage with visualization of internal calcifications.

none involving the hamate (3 in the scaphoid and 3 in the capitate) [9]. There are only 2 other cases of chondroblastomas involving the hamate that have been reported [7,8]. The mean age at presentation is 15 years with a male to female ratio of 2:1 [1]. Clinical findings consist of pain, restricted range of motion, and local swelling. Radiographs classically display a circumscribed lytic lesion with a well-defined sclerotic rim [1–3]. Histologically, chondroblastomas typically consist of an admixture of chondroblasts and multinucleated giant cells with chondroid matrix [10]. Characteristic “chicken-wire” or “lace-like” pericellular calcifications are often seen [11]. Treatment usually consists of surgery with curettage and bone grafting or cementation [3]. Local recurrence rates are reported to be about 10–30% [2]. Three cases of extraosseous chondroblastomas have been reported; however, these cases may have been miscategorized and, based on their clinical and

histologic features, are more likely to be chondroblastoma-like chondromas (CLC) instead [11–14]. CLC is a minority of soft tissue chondromas that closely resemble chondroblastomas histologically [11]. While most chondromas are exclusively composed of mature hyaline cartilage, CLC contain regions of hypercellularity and display chondroblastoma-like areas [11,15]. Therefore, extraosseous involvement by chondroblastomas is exceptionally rare (Figs. 1–6).

Case report

A 31-year-old woman was referred to the orthopedic oncology clinic with a progressively growing mass on the dorsal aspect of her left hand which she first noticed 3–4 years ago. She also

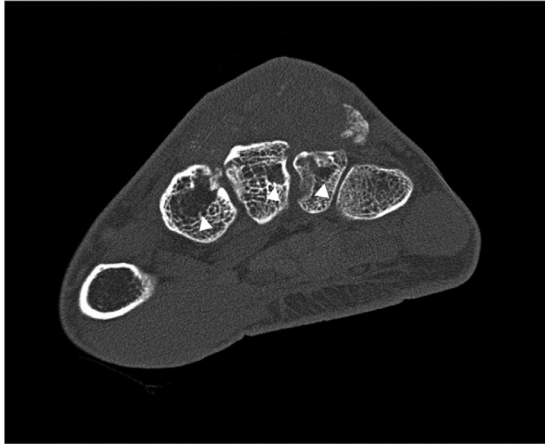


Fig. 3 – Noncontrast axial CT image shows small lucent lesions (white arrowheads) at the bases of the second, third, and fourth metacarpal bases.

reported periodic night sweats and pain in her left metacarpophalangeal (MCP) joints, but not over the mass. Physical examination revealed a firm, non-mobile mass measuring approximately 2 × 2 cm on the dorsal carpus with 3 lobulated palpable masses adjacent to it. The masses were non-tender and without erythema. A 5-10 degree reduction in left wrist extension was noted compared to the contralateral side. There were no deficiencies in finger range of motion, motor function, and sensation.

Imaging

Plain radiographs of the left wrist showed a dorsal soft tissue mass with multiple calcifications at the level of the base of the metacarpals. A noncontrast CT scan of the hand showed a lobulated mass along the dorsum of the wrist and proximal hand measuring 1.5 cm and 3.4 cm in craniocaudal and transverse dimensions, respectively. The mass demonstrated dif-

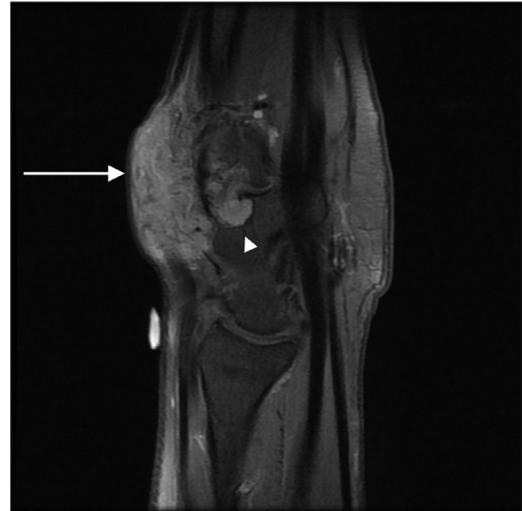

Fig. 5 – Sagittal T1-weighted fat-saturated postcontrast MR image of the wrist showing enhancing soft tissue mass (white arrow) of the dorsal aspect with small areas of involvement (white arrowhead) of the hamate and base of the fourth metacarpal.

fuse calcifications within it and appeared to encompass the extensor tendons of the second, third, and fourth fingers. Bone windows revealed radiolucent lesions in the dorsal aspect of the hamate and second through fourth metacarpal bases. Contrast-enhanced MRI of the left hand exhibited marked enhancement of the mass and further involvement of the hamate and bases of the second, third, and fourth metacarpals. The differential diagnoses at this time included synovial chondromatosis, soft tissue chondroma, and tenosynovial giant cell tumor. With multiple calcifications in close association with the tendon sheaths and carpometacarpal joints, synovial chondromatosis was the primary consideration. Soft tissue chondroma was included in the differential as they mostly occur in the soft tissue of the hands and feet and show patterns of calcification that can be associated with bone ero-

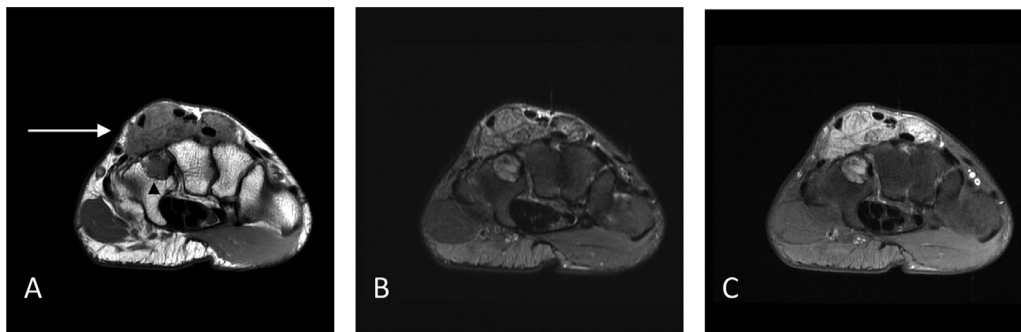


Fig. 4. (A) – Axial T1-weighted nonfat-suppressed MRI of the hand demonstrating a lobulated mass (white arrow) of intermediate signal intensity at the dorsal aspect of the distal carpus with close association of the extensor tendons and abnormal focal signal (black arrowhead) in the dorsal aspect of the hamate. (B) Axial T2-weighted fat saturated MR image at the same level shows the lesion to be mixed signal but primarily hyperintense. (C) Axial T1-weighted fat-saturated postcontrast image shows considerable enhancement of the mass.

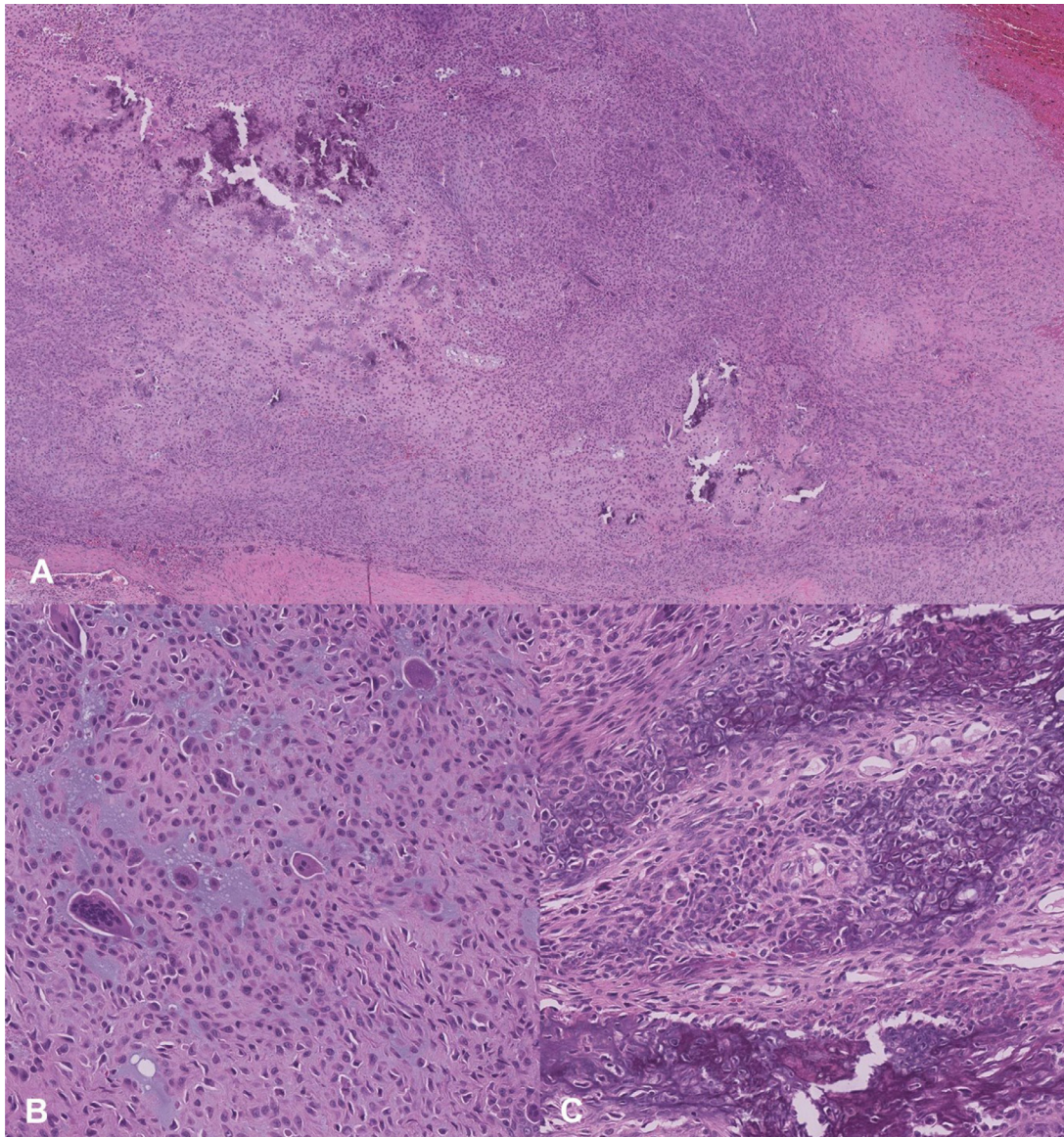


Fig. 6 – Photomicrographs. (A) Sheets of chondroblasts in pale chondroid matrix with areas of mineralization. No mature hyaline cartilage is present (H&E, 40x). (B) Multinucleated osteoclast-like giant cells and mononuclear cells with typical chondroblast cytology – eosinophilic cytoplasm and round nuclei with nuclear grooves (H&E, 200x). (C) Chondroblasts with characteristic pericellular “chicken-wire” calcifications (H&E, 200x).

sions. Tenosynovial giant cell tumor was lower on the differential due to the numerous calcifications within the lesion.

Treatment and follow-up

The patient underwent open biopsy of the lesion with intraoperative frozen assessment and plans for excision. Due to the cartilage features and atypical imaging appearances, definitive surgical treatment was deferred until final pathology resulted. Once the final pathology resulted as chondroblastoma, the patient underwent a marginal excision of the mass with curettage of the hamate, metacarpals and cementation of the hamate lesion. The patient did not report functional limitations at the 3-month follow-up.

Discussion

Chondroblastomas are rare, cartilaginous bone tumors that are not commonly found in the hands and even less so in soft tissue [1,11]. Originally described by Ewing as a “calcifying giant cell tumor,” chondroblastomas characteristically consist histologically of chondroblasts and multinucleated giant cells in a chondroid matrix with scattered calcifications [10,16]. Radiographs typically show a well-defined lytic lesion with thin sclerotic margins. Central calcifications are common and radio densities vary depending on the severity of mineralization [10]. MRI studies on T1- and T2-weighted images show mixed signal intensity, most likely related to the variable com-

ponents of the lesion [10]. Clinical presentation consists of pain, joint effusion, and limited range of motion. A multicenter analysis of 199 patients with chondroblastoma found that pain was the primary presenting symptom at 73.4% with joint effusion and limited movement at 33% and 23%, respectively [1].

The patient's presentation of pain and a palpable mass along the extensor tendons in addition to radiographs with calcifications adjacent to articular spaces made a strong case for synovial chondromatosis after imaging was obtained. The prevalence of synovial chondromatosis in the hands is also rare with 90% of reported cases located in the knee or hip [18]. T1-weighted MRI imaging showed intermediate signal intensity and T2-weighted MRI showed mixed, primarily hyperintensity in the lesion which can be consistent with synovial chondromatosis [17]. Although chronic and progressive synovial chondromatosis may cause cartilaginous erosions around the joints, cortical and subcortical abnormalities as seen on this patient's CT images are not found [17,19]. In contrast to our case, the microscopic appearance of synovial chondromatosis typically consists of nodules composed of hyaline cartilage.

Extrasosseous chondroblastoma is exceptionally rare [14]. Chondroblastoma-like chondromas histologically resemble chondroblastomas, making it difficult to differentiate between these 2 benign cartilage-forming tumors [11]. Both demonstrate proliferation of round cells and scattered multinucleated giant cells with variable "chicken-wire" calcifications [10,11].

Chondroblasts characteristically have round nuclei with longitudinal nuclear grooves while CLC have been described to have ovoid, eccentric nuclei [10,11]. CLCs are found loosely in the soft tissue adjacent to tendons or within tenosynovial sheaths and are often surgically treated with complete excision of loose cartilaginous fragments [15].

Acknowledgment

We would like to thank the Departments of Radiology, Orthopaedic Surgery, and Pathology for their collaborative efforts in this case.

Patient consent

Written, informed consent for publication of the case report titled "Unusual Chondroblastoma of the Hand with Large Extrasosseous Soft Tissue Component" was obtained from the patient.

REFERENCES

- [1] Xu H, Nugent D, Monforte HL, et al. Chondroblastoma of bone in the extremities: a multicenter retrospective study. *J Bone Joint Surg Am* 2015;97(11):925–31.
- [2] Ebeid WA, Hasan BZ, Badr IT, Mesregah MK. Functional and oncological outcome after treatment of chondroblastoma with intralesional curettage. *J Pediatr Orthop* 2019;39(4):e312–17.
- [3] Izadpanah A, Zreik RT, Shives T, Kakar S. Capitate chondroblastoma: a case report and review of the literature. *Hand (N Y)* 2017;12(2) NP14–NP18.
- [4] Davila JA, Amrami KK, Sundaram M, Adkins MC, Unni KK. Chondroblastoma of the hands and feet. *Skelet Radiol* 2004;33(10):582–7.
- [5] Brien EW, Mirra JM, Kerr R. Benign and malignant cartilage tumors of bone and joint: their anatomic and theoretical basis with an emphasis on radiology, pathology and clinical biology. I. The intramedullary cartilage tumors. *Skelet Radiol* 1997;26(6):325–53.
- [6] Wu CT, Chen AC, Wang CJ, Wang CW, Fu CJ, Wong YC. Chondroblastoma of the triquetrum. *Pediatr Neonatol* 2013;54(4):278–80.
- [7] Rhee PC, Novais EN, Shives TC, Shin AY. Chondroblastoma with secondary aneurysmal bone cyst of the hamate: case report. *J Hand Surg Am* 2012;37(3):538–42.
- [8] Daly KE, Chow JW, Vickers RH. Excision of the hamate for an unusual hand tumour. *J Hand Surg Br* 1993;18(5):606–8.
- [9] Murray PM, Berger RA, Inwards CY. Primary neoplasms of the carpal bones. *J Hand Surg Am* 1999;24(5):1008–13.
- [10] Chen W, DiFrancesco LM. Chondroblastoma: an update. *Arch Pathol Lab Med* 2017;141(6):867–71.
- [11] Cates JM, Rosenberg AE, O'Connell JX, Nielsen GP. Chondroblastoma-like chondroma of soft tissue: an underrecognized variant and its differential diagnosis. *Am J Surg Pathol* 2001;25(5):661–6.
- [12] Weinrauch L, Katz M, Pizov G. Primary benign chondroblastoma cutis: extraskeletal manifestation without bone involvement. *Arch Dermatol* 1987;123(1):24–6.
- [13] Kingsley TC, Markel SF. Extraskeletal chondroblastoma. A report of the first recorded case. *Cancer* 1971;27(1):203–6.
- [14] Abdul-Karim FW, Ayala AG, Spjut HJ. Case report 321. Extrasosseous chondroblastoma in the subcutaneous tissues of the right shoulder. *Skelet Radiol* 1985;14(1):73–5.
- [15] Raparia K, Lin JW, Donovan D, et al. Chondroblastoma-like chondroma of soft tissue: report of the first case in the base of skull. *Ann Diagn Pathol* 2013;17(3):298–301.
- [16] Ewing J. A treatise on tumors. Philadelphia, PA: WB Saunders; 1928. p. 293.
- [17] Lee SK, Choy WS, Lee KW, Bae KJ. Synovial chondromatosis of the radiocarpal joint. *Orthopedics* 2008;31(8):811.
- [18] Neumann JA, Garrigues GE, Brigman BE, Eward WC. Synovial chondromatosis. *JBJS Rev* 2016;4(5) e2.
- [19] Rogachefsky RA, Zlatkin MB, Greene TL. Synovial chondromatosis of the distal radioulnar joint: a case report. *J Hand Surg Am* 1997;22(6):1093–7.