



Case Report

Hepatitis A virus infection is complicated by both pancytopenia and autoimmune hemolytic anemia (AIHA)

Omar Al jandale^{a,*}, Heba Jumah^{a,b}, Hasan Jamil^c^a Department of Internal Medicine, Damascus University Hospital, Damascus, Syria^b Department of Hematological Diseases, Damascus University Hospital, Damascus, Syria^c Graduate School of Public Health, St. Luke International University, Tokyo, 104-0044, Japan

ARTICLE INFO

Keywords:

Hepatitis A virus

Pancytopenia

Autoimmune hemolytic anemia

ABSTRACT

Introduction: Hepatitis A infection affects liver tissue primarily and might have some extrahepatic manifestations. Hematologically, the extrahepatic manifestations include aplastic anemia, red cell aplasia, and thrombocytopenia. There were reports about pancytopenia among patients with Hepatitis A infections, however, its association with autoimmune hemolytic anemia is rare as in our case.

Case presentation: A 30-year-old male visited the emergency room with tiredness, unmeasured fever, and jaundice. He also mentioned that recently he had anorexia and weight loss without night sweating. Initial laboratory findings showed pancytopenia and marked elevation of AST and ALT. Direct Coombs and IgM anti-Hepatitis A virus were positive. Consequently, he was diagnosed with HAV complicated by both pancytopenia and AIHA and treated with prednisone (1 mg/kg) leading to significant improvement in his anemia.

Discussion: This report describes a case of acute viral hepatitis A complicated with severe autoimmune hemolytic anemia and pancytopenia, which was successfully treated by high dose (1 mg/kg/day) prednisolone therapy.

Conclusion: This case represents a rare case in the literature review that can increase the awareness of the wide range of complications of HAV and its association with pancytopenia and AIHA.

1. Introduction

The infection of the hepatitis A virus might manifest as an asymptomatic infection or mild one to severe, acute, or even fulminant hepatitis [1].

The clinical course of Hepatitis A infection doesn't complicate with a chronic phase or the development of cirrhosis. Moreover, its hematologic extrahepatic complications are rare, including hemolytic anemia, aplastic anemia, red cell aplasia, etc. [2–4]. In particular, pancytopenia related to hepatitis is a rare hematologic complication, and HAV has the lowest association with pancytopenia compared to other hepatitis viruses [5].

We experienced a case of HAV complicated by both pancytopenia and AIHA which was unreported previously in the literature.

HAV: hepatitis A virus, AIHA: autoimmune hemolytic anemia.

2. Presentation of case

A 30-year-old male visited the emergency room on October 28, 2021 with tiredness and fatigue for 20 days. The complaint was associated with yellowing of the skin and darkening of the urine and unmeasured fever. He also mentioned that recently he had anorexia and weight loss without night sweating. He denies any hemorrhage or bruises. His other symptoms include headache, tinnitus, palpitations, and grade 3 (NYHA) exertional dyspnea. His past medical history is unremarkable except for the transfusion of 2 PRBCs two days before this visit. Also, he is a heavy smoker (20 cigarettes for 15 years).

Physical examination showed a pulse of 110/m and a temperature of 38 °C. Head and neck examination revealed the presence of pallor, jaundice, and jugular veins congestion without lymphadenopathy.

The heart examination was normal except for a systolic murmur grade 3/6. Abdominal examination shows hepatomegaly (liver span 16.5cm) without shifting dullness or splenomegaly. Additional findings

Abbreviations: HBV, hepatitis B virus; HCV, hepatitis C virus; HIV, human immunodeficiency virus; TTP, thrombotic thrombocytopenic purpura; DIC, disseminated intravascular coagulation.

* Corresponding author. Al Mouwasat Hospital, Omar Bin Abdulaziz, Damascus, Syria.

E-mail address: Omarjandali19@gmail.com (O. Al jandale).

<https://doi.org/10.1016/j.amsu.2022.103765>

Received 12 April 2022; Received in revised form 6 May 2022; Accepted 8 May 2022

Available online 11 May 2022

2049-0801/© 2022 The Authors. Published by Elsevier Ltd on behalf of IJS Publishing Group Ltd. This is an open access article under the CC BY-NC-ND license (<http://creativecommons.org/licenses/by-nc-nd/4.0/>).

include bilateral pitting edema in the lower limbs.

Neurological examination was within normal limits.

Initial laboratory findings showed pancytopenia (hemoglobin (Hb) 2.8 g/dL, white blood cell (WBC) 1400/ μ L, platelet 11×10^3 / μ L). LDH 4019 IU/L, serum aspartate aminotransferase (AST) 342 IU/L, alanine aminotransferase (ALT) 670 IU/L, total bilirubin (TB) 2.1 mg/dL, direct bilirubin (DB) 0.8 mg/dl. Urea, Prothrombin Time 16s Partial Thromboplastin Time 32s, creatinine, and electrolytes were within normal limits. Direct Coombs was positive (+++) and indirect Coombs was negative.

Hepatitis B virus surface antigen, IgM anti-HBc, hepatitis C virus (HCV) RNA, Western blot for HIV, and anti-HCV were all negative. IgM anti-Hepatitis A virus was positive.

Chest X-ray and CT scan of the abdomen and chest showed no remarkable findings except for hepatomegaly and a small amount of free fluid around the liver.

Peripheral smear showed anisocytosis, macroovalocyte, hypochromic microcytes, and spherocytes Fig. 1.

Bone marrow aspiration showed normocellular marrow. It revealed increased activity of the red chain with maturity (myeloid: erythroid = 1:3). Granulocyte's chain was in good differentiation with a little proportion of metamyelocytes Fig. 2.

Based on clinical and laboratory findings, we excluded the other possible diagnoses like coagulopathy, malignancies, and hypoproliferative disorders, the patient was diagnosed with Acute Hepatitis A with autoimmune hemolytic anemia. The patient completely accepted the management plan after explaining the benefits and harms of the transfusion therapy and corticosteroids, and excluding the contraindications of the given treatment, such as uncontrolled bleeding and active bleeding gastric ulcer. He was given 5 units of platelets, 5 units of PRBCs, supportive care, and oral prednisolone (1 mg/kg/day) for 7 days. The patient was treated in the hematology ward and his treatment adherence was ensured by ward nurses and he the treatment was well tolerated without any complications. His symptoms and laboratory results were gradually improved during hospitalization as shown in Table 1. The follow-up after three months revealed complete clinical recovery with the absence of the previous findings including pallor,

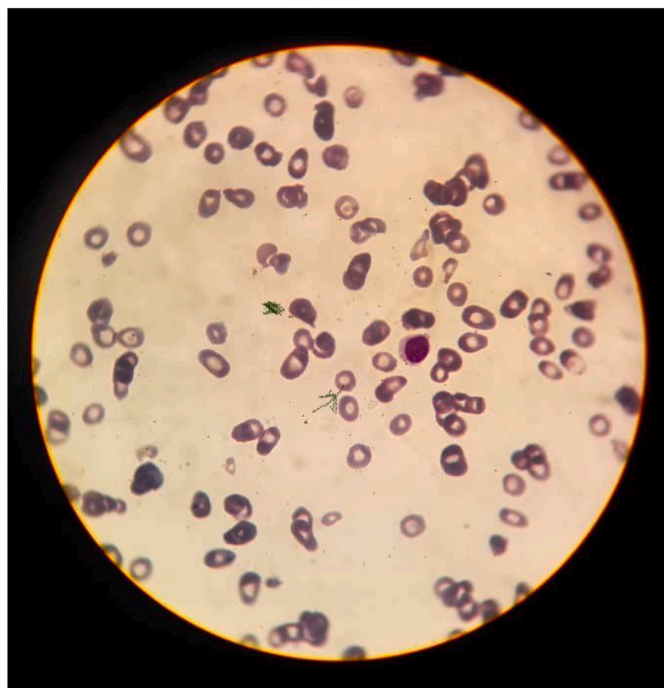


Fig. 1. Microscopic Image of Peripheral Smear showing Anisocytosis, Macroovalocyte, Hypochromic Microcytes (a0072row), and Spherocytes (arrowhead).

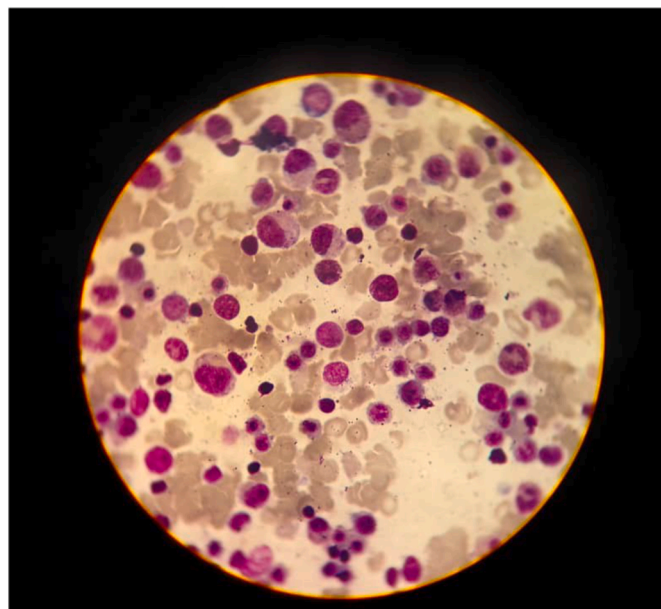


Fig. 2. Microscopic Image of Bone Marrow Aspiration Showing Normocellular Marrow. Revealing Increased Activity of the Red Chain with Maturity (myeloid: erythroid = 1:3). Granulocyte's Chain has Good Differentiation with a little Proportion of Metamyelocytes. (For interpretation of the references to colour in this figure legend, the reader is referred to the Web version of this article.)

Table 1

Hematological and biochemical findings of the case.

	October 28, 2021 ^a	November 1, 2021	November 4, 2021 ^b
WBC	1.4	2.76	3.81
Hb, mg/dl	2.8	7.1	8
Total bilirubin, mg/ dl	2.18	0.9	0.6
AST, IU/L	342	256	130
ALT, IU/L	670	233	86

AST, aspartate aminotransferase; ALT, alanine aminotransferase.

^a Prednisolone 60 mg/day was started one day after this finding.

^b Discharge day on prednisolone 60 mg per day administration.

Jaundice and the systolic murmur, however he denied to do the laboratory tests again.

3. Discussion

This report describes a case of acute viral hepatitis A complicated with severe autoimmune hemolytic anemia and pancytopenia, which was successfully treated by high dose (1 mg/kg/day) prednisolone therapy.

There have been a few reports of severe Coombs positive AIHA complicating acute viral hepatitis [6]. However, the infection of HAV complicated with severe AIHA with pancytopenia has not been reported.

One of the main challenges to diagnosing such a case is the unavailability of laboratory testing for viruses that might cause such type of Coombs positive hemolytic anemia (e.g., parvovirus) which leaves the place for uncertainty about the casual relationship. Moreover, the lack of scientific literature regarding this type of association formed a challenge in the work-up and identifying the prognosis.

P. Valent et al. explained the concept of pancytopenia as a decrease in all peripheral bloodlines and can be associated with a wide range of life-threatening cases. For a definition, the cutoff values are Hemoglobin <12g/dl for non-pregnant women and <13 for men. Absolute neutrophil count <1800/ μ L. Platelet <150,000/ μ L. Adding that these cutoffs

depend on several factors like sex, age, sea level, and race [7].

According to them, the three main mechanisms of pancytopenia include: bone marrow infiltration disorders such as hematologic malignancies and myelofibrosis, or blood cell destruction as in DIC, TTP, and hypersplenism, or bone marrow aplasia such as nutritional disorders and infectious diseases (miliary tuberculosis, fungal infection), and the treatment should be considered according to the possible cause [7].

Another study by M. Michel et al. defined AIHA as a rare autoimmune condition in which autoantibodies directed toward RBC antigens lead to their accelerated destruction. The diagnosis of AIHA is usually based on the identification of anti-RBC autoantibodies using the direct antiglobulin test, and in most cases, reticulocytosis is accompanied. Corticosteroids are the cornerstone of the treatment, and splenectomy and rituximab are second lines. Rapid transfusion has a positive role in severe cases of anemia despite the risk of alloimmunization [8].

Other possible causes of pancytopenia include coagulopathy, malignancies, and hypoproliferative disorders. The absence of schistocytes and the normal values of prothrombin time (PT) and thromboplastin time (PTT) make coagulopathy unlikely [9]. The absence of abnormal cells on blood smear and the confirmation of this by bone marrow aspiration helped us to exclude hematologic malignancies [10]. Hypoproliferative conditions including those caused by medications and deficiencies of minerals and vitamins are diagnosed by bone marrow aspiration and biopsy and are associated with reticulocytopenia as opposed to our case [11].

4. Conclusion

We experienced an HAV case in a patient: who was previously healthy with no drug history, negative serology for HBV, HCV, HIV, which was complicated by both AIHA and pancytopenia, who was successfully treated with corticosteroid and initial transfusion. This should increase awareness about the association between different viral infections and AIHA.

5. Methods

The work has been reported in line with the SCARE 2020 criteria [12].

Sources of funding

This research did not receive any specific grant from funding agencies in the public, commercial, or not-for-profit sectors.

Ethical approval

This case report didn't require review by ethics committee, al Assad university hospital, Damascus university, damascus-Syria.

Registration of research studies

N/A.

Consent of patient

Written informed consent was obtained from the patient of this case report and accompanying images. A copy of the written consent is available for review by the Editor-in-Chief of this journal on request.

Guarantor

Omar al jandale.

Provenance and peer review

Not commissioned, externally peer-reviewed.

Author contribution

All authors have participated in writing and reviewing the manuscript.

Registration of research studies

N/A.

Annals of medicine and surgery

The following information is required for submission. Please note that failure to respond to these questions/statements will mean your submission will be returned. If you have nothing to declare in any of these categories then this should be stated.

Declaration of competing interest

The authors have no Conflicts of Interest to declare.

Acknowledgments

N/A.

References

- [1] J.E. Bennett, R. Dolin, M.J. Blaser (Eds.), *Mandell, Douglas, and Bennett's Principles and Practice of Infectious Diseases, ninth ed.*, Elsevier, Philadelphia, PA, 2020.
- [2] Y.J. Jung, W. Kim, J.B. Jeong, B.G. Kim, K.L. Lee, K.-H. Oh, J.-H. Yoon, H.-S. Lee, Y. J. Kim, Clinical features of acute renal failure associated with hepatitis A virus infection, *J. Viral Hepat.* (2009), <https://doi.org/10.1111/j.1365-2893.2009.01216.x>.
- [3] E.R. Schiff, Atypical clinical manifestations of hepatitis A, *Vaccine* 10 (1992) S18–S20, [https://doi.org/10.1016/0264-410X\(92\)90534-Q](https://doi.org/10.1016/0264-410X(92)90534-Q).
- [4] H.J. Chang, D.H. Sinn, S.G. Cho, T.H. Oh, T.J. Jeon, W.C. Shin, W.C. Choi, Pure red-cell aplasia and autoimmune hemolytic anemia in a patient with acute hepatitis A, *Clin. Mol. Hepatol.* 20 (2014) 204, <https://doi.org/10.3350/cmh.2014.20.2.204>.
- [5] M. Naderi, I. Shahramian, A. Bazi, M. Delaramnasab, G. Kalvandi, Hepatitis A infection presented with pancytopenia, a case series in children, *Int. J. Infect.* (2019), <https://doi.org/10.5812/iji.87332>. In Press.
- [6] A. Chehal, A.I. Sharara, H.A. Haidar, J. Haidar, A. Bazarbachi, Acute viral hepatitis A and parvovirus B19 infections complicated by pure red cell aplasia and autoimmune hemolytic anemia, *J. Hepatol.* 37 (2002) 163–165, [https://doi.org/10.1016/S0168-8278\(02\)00090-9](https://doi.org/10.1016/S0168-8278(02)00090-9).
- [7] P. Valent, Low blood counts: immune mediated, idiopathic, or myelodysplasia, *Hematology Am Soc Hematol Educ Program* (2012) 485–491, <https://doi.org/10.1182/asheducation-2012.1.485>.
- [8] M. Michel, Classification and therapeutic approaches in autoimmune hemolytic anemia: an update, *Expet Rev. Hematol.* 4 (2011) 607–618, <https://doi.org/10.1586/ehm.11.60>.
- [9] J.N. George, C.M. Nester, Syndromes of thrombotic microangiopathy, *N. Engl. J. Med.* 371 (2014) 654–666, <https://doi.org/10.1056/NEJMra1312353>.
- [10] E.P. Weinzierl, D.A. Arber, Bone marrow evaluation in new-onset pancytopenia, *Hum. Pathol.* 44 (2013) 1154–1164, <https://doi.org/10.1016/j.humpath.2012.10.006>.
- [11] A.A. Gabreyes, H.N. Abbasi, K.P. Forbes, G. McQuaker, A. Duncan, I. Morrison, Hypocupremia associated cytopenia and myelopathy: a national retrospective review, *Eur. J. Haematol.* 90 (2013) 1–9, <https://doi.org/10.1111/ejh.12020>.
- [12] R.A. Agha, T. Franchi, C. Sohrabi, G. Mathew, for the SCARE Group, The SCARE 2020 guideline: updating consensus surgical CASE REport (SCARE) guidelines, *Int. J. Surg.* 84 (2020) 226–230.