

## Comorbidity of chronic fatigue syndrome, postural tachycardia syndrome, and narcolepsy with 5,10-methylenetetrahydrofolate reductase (*MTHFR*) mutation in an adolescent: a case report

Ying Liao, Jian-Guang Qi, Hui Yan, Qing-You Zhang, Tao-Yun Ji, Xing-Zhi Chang, Hai-Po Yang, Hong-Fang Jin, Jun-Bao Du

Department of Pediatrics, Peking University First Hospital, Beijing 100034, China.

A 16-year-old male adolescent was hospitalized complaining of intermittent dizziness, drowsiness, and fatigue for approximately 2 years. The patient had an episode of fever and pharyngalgia lasting nearly 2 weeks and had undergone appendectomy because of acute appendicitis before the presentation of the above symptoms. He suffered from severe dizziness mostly after switching from a supine to an upright posture when he was getting up in the morning. The symptom of dizziness usually persisted for minutes to hours and could be partially alleviated by recumbency. In addition, he felt drowsy and fatigued all day despite a total sleep duration of 14 to 15 h per day. All the symptoms could be partially mitigated by complete bed rest for 1 or 2 weeks, but he relapsed after taking part in normal school life again. Additionally, the feeling of fatigue was obviously aggravated after exertion or infection. He was unable to focus on his studies and had to withdraw from school for a long time. As a result, there was a decline in academic performance after the onset of illness. He used to benefit from taking carnitine and folate; however, the improvement was limited in enabling him to take part in normal social and school life. He was physically and mentally healthy before the presentation and did not feel disgusted with learning in the past. No family history of cardiovascular or nervous system disease was evident. The study was approved by the Ethics Committee of Peking University First Hospital (No. 2020-415).

His physical examination showed no significant abnormalities except for a body mass index of 25.6 kg/m<sup>2</sup> indicating overweight and a surgical scar on the right lower abdomen. Investigations in the form of a routine complete blood count, a liver and renal function test, serum electrolytes, cortisol circadian rhythm, and thyroid

function were normal. Meanwhile, his serum homocysteine concentration markedly increased to a maximum value of 86.14 μmol/L during the course and decreased to 31.28 μmol/L after the treatment mentioned above. Relevant investigations, including serum folate and vitamin B<sub>12</sub>, blood amino acid, and urinary organic acid analyses, were normal. Family wide exome sequencing showed complex heterozygous mutations in the 5,10-Methylenetetrahydrofolate reductase (*MTHFR* gene) [Figure 1]. A serum immunoglobulin (Ig) assay revealed significantly elevated titers of Epstein-Barr virus (EBV) capsid antigen IgG (>750 U/mL, reference range: <20 U/mL) and nuclear antigen IgG (>600 U/mL, reference range: <5 U/mL). However, the serum EBV capsid antigen IgM (<10 U/mL, reference range: <40 U/mL) and EBV nucleic acid determination (reference range: <500 copies/mL) were normal. Investigations of immune function revealed normal results. No abnormal results were reported in his examinations of Holter monitoring, echocardiography, and ambulatory blood pressure monitoring. A standing test showed that his heart rate increased from 61 beats per min (bpm) when supine up to 118 bpm during upright as he complained of lightheadedness, which was similar to the way he felt in his daily life, which suggested a diagnosis of postural tachycardia syndrome (POTS). His 24-h urine sodium concentration and flow-mediated vasodilation (FMD) reaction were examined to search for pathogenic factors of POTS, and intensive FMD was confirmed. Repeated magnetic resonance imaging (MRI) of the brain and routine electroencephalogram showed no abnormalities. However, the multiple sleep latency test showed that his sleep latency was from 56 s to 3 min plus 45 s, and three sleep-onset rapid eye movement periods were determined in five naps [Supplemental Figure 1, <http://links.lww.com/CM9/A464>] and his Epworth Sleepiness Scale score added up to 19, which indicated an evident sleep disorder. No

### Access this article online

Quick Response Code:



Website:  
[www.cmj.org](http://www.cmj.org)

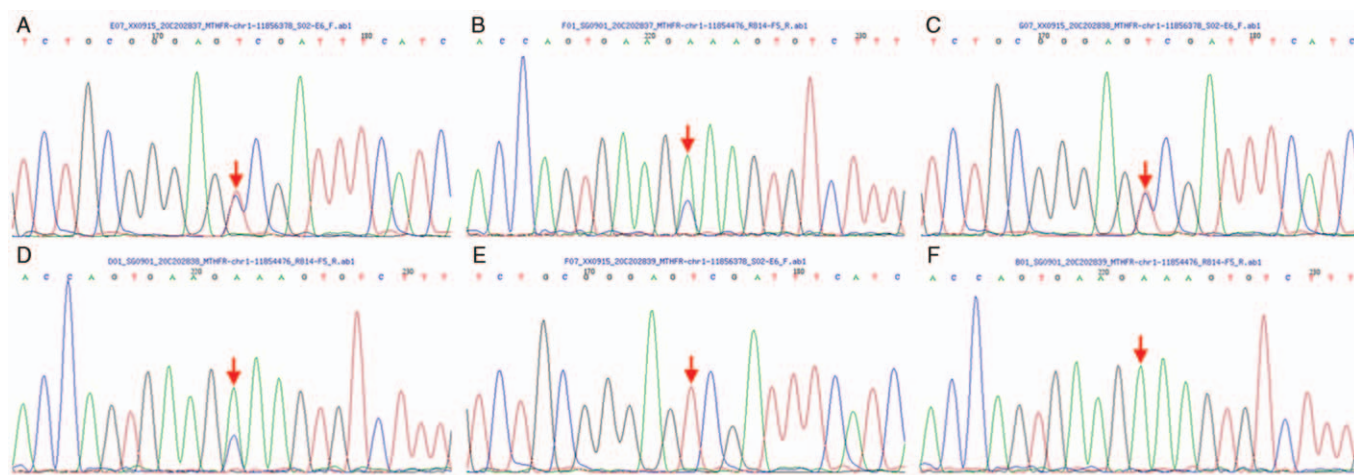
DOI:  
10.1097/CM9.0000000000001387

**Correspondence to:** Prof. Jun-Bao Du, Department of Pediatrics, Peking University First Hospital, Beijing 100034, China  
E-Mail: [junbaodu1@126.com](mailto:junbaodu1@126.com)

Copyright © 2021 The Chinese Medical Association, produced by Wolters Kluwer, Inc. under the CC-BY-NC-ND license. This is an open access article distributed under the terms of the Creative Commons Attribution-Non Commercial-No Derivatives License 4.0 (CCBY-NC-ND), where it is permissible to download and share the work provided it is properly cited. The work cannot be changed in any way or used commercially without permission from the journal.

Chinese Medical Journal 2021;134(12)

Received: 28-12-2020 Edited by: Jing Ni



**Figure 1:** Partial sequencing results of the *MTHFR* gene in this case (A, B) and his parents (the father: C, D; the mother: E, F). The red arrows indicate the mutation site in the *MTHFR* gene. (A) The heterozygous mutation in which C at position 677 of the *MTHFR* gene is replaced with T leads for the replacement of the amino acid alanine at position 222 with valine (p.Ala222Val). (B) The heterozygous mutation in which A at position 1298 of the *MTHFR* gene is replaced with C leads to the replacement of the amino acid glutamic acid at position 429 with alanine (p.Glu429Ala). (C, D) The gene sequence at these two positions of the patient's father is the same with the patient. (E) The patient's mother shows C > T homozygous mutation at position 677 of the *MTHFR* gene. (F) The gene sequence at position 1298 of the mother is normal. As a result, the patient's compound heterozygous mutation at position 677 and 1298 of the *MTHFR* respectively originated from his mother and father. *MTHFR*: 5,10-Methylenetetrahydrofolate reductase.

abnormalities were found in otorhinolaryngologic and ophthalmic examinations.

A multidisciplinary consultation including a pediatric cardiologist and a neurologist was conducted. According to the patient's history and examinations, diagnoses of chronic fatigue syndrome (CFS) and narcolepsy were considered, combined with POTS and hyperhomocysteinemia (*MTHFR* gene mutation). Considering his hyperhomocysteinemia, a combined therapy consisting of oral folate (5 mg/day), vitamin B<sub>6</sub> (10 mg/day), vitamin B<sub>12</sub> (0.5 mg/day), and L-carnitine (1 g/day) was continuously prescribed. In addition, oral midodrine hydrochloride (7.5 mg/day) was used to target excessive vasodilation, which may account for POTS. After 1 month of therapy, the symptom of dizziness was relieved to a certain extent, but his feeling of drowsiness and fatigue barely improved. According to the expertise of pediatric neurology, methylphenidate hydrochloride tablets (18 mg/day) were added to his treatment to ameliorate the narcoleptiform sleep disorder. After another month, the patient felt much less drowsy during the daytime, and his total sleep duration shortened to 9 to 10 h/day. Therefore, he began to gradually resume his school life and has maintained a normal sleep rhythm since then.

CFS, also known as myalgic encephalomyelitis (ME) or ME/CFS, can occur at all ages, but the diagnosis of CFS is most often made in school-age and adolescent children, peaking at the ages of 11 to 18 years during childhood.<sup>[1]</sup> The prominent clinical manifestations are significant fatigue, and other problems include sleep disorders, cognitive disorders, pain, and so on, which may deteriorate by physical or mental activity and cannot be effectively improved even after full rest and sufficient sleep for a short period of time, leading to impairment of physical and mental health and eventually disrupting the patient's social and school life to varying degrees. Although pediatric

patients with CFS appear to have many psychological abnormalities, it is believed that CFS is a physical disease in nature caused by multiple complex mechanisms that are not fully understood. As mentioned above, the patient in this case had a history of fever and an experience of surgical operation before the presence of disease. We speculated that he had an EBV infection previously in view of the long-term fever with pharyngalgia, and sustained increased EBV IgG levels, which is considered to be associated with the etiology of CFS.

The patient showed typical manifestations of orthostatic intolerance and was diagnosed with POTS. It has been reported that nearly 11% of adult CFS patients are diagnosed with POTS. The incidence of POTS is higher in pediatric CFS patients than in adult CFS patients.<sup>[2]</sup> The enhanced FMD in this patient suggested impaired endothelial function and abnormal vasoconstriction, which is believed to be one of the important pathogenesises of POTS.<sup>[3]</sup>

We considered the possibility of narcolepsy because of the patient's excessive sleepiness, especially during the daytime. As expected, he fulfilled the diagnostic criteria of narcolepsy during childhood.<sup>[4]</sup> Narcolepsy is a group of neurological disorders characterized by excessive sleepiness during the daytime, markedly shortened sleep latency (presents as falling asleep abruptly or cataplexy), sleep paralysis, and interruption in nocturnal sleep. As summarized in published reviews, narcolepsy is not an independent presentation apart from CFS but a relatively common complication in CFS. A retrospective study revealed that the degree of fatigue can be obviously relieved by a strategy of treating narcolepsy in 75% of those patients.<sup>[5]</sup>

Hyperhomocysteinemia is another marked characteristic of this case. The metabolic pathway of homocysteine involves the remethylation pathway and the transsulfura-

tion pathway [Supplemental Figure 2, <http://links.lww.com/CM9/A464>]. MTHFR deficiency is now the most common cause of hyperhomocysteinemia. In this case, compound heterozygous mutations in the *MTHFR* gene were determined by family wide exome sequencing. It has been reported that individuals with compound heterozygous mutations of c.1298A>C and c.677C>T in the *MTHFR* gene have similar clinical manifestations as c.677C>T homozygous carriers.<sup>[6]</sup> Therefore, it is reasonable to conclude that hyperhomocysteinemia is attributed to the patient's *MTHFR* gene mutations. No specific pathogenic gene has been defined as the main cause of CFS. In recent years, the relationships between *MTHFR* gene polymorphisms and CSF have begun to attract researchers' attention, but only a few studies have been reported. In a recent cross-sectional study, Regland *et al*<sup>[7]</sup> reported that CFS patients who received more frequent vitamin B<sub>12</sub> injections and higher doses of oral folate showed a better therapeutic response and needed fewer other adjuvant treatments (such as psychiatric drugs). Furthermore, the therapeutic response and oral doses of folate are correlated with the single-nucleotide polymorphisms of c.1298A>C and c.677C>T in the *MTHFR* gene.<sup>[7]</sup> Therefore, disorders of homocysteine metabolic pathways should be taken into account cautiously while treating patients. The mechanisms by which the gene polymorphism of *MTHFR* plays a role in CFS still need to be studied.

Multiple aspects should be taken into account while treating patients with CFS regarding the complex etiology. Symptoms caused by its comorbidities should be controlled comprehensively. In this case, his narcoleptic symptoms were controlled by methylphenidate hydrochloride. According to former researches, methylphenidate may be effective for certain groups of CFS patients, *e.g.*, patients with attention deficit hyperactivity disorder or narcolepsy.<sup>[8]</sup>

Here, we have reported an adolescent case of CFS accompanied by hyperhomocysteinemia associated with heterozygous mutation of the *MTHFR* gene, POTS, and narcolepsy. His symptoms improved after the combined therapy of vitamin B<sub>12</sub>, folate, midodrine, and methylphenidate. We believe that much attention should be paid to CSF in childhood to increase the diagnostic rate and

provide a more comprehensive and effective treatment for pediatric patients.

### Funding

This study was supported by a grant from the Peking University Clinical Scientist Program (No. BMU2019LCKXJ001).

### Conflicts of interest

None.

### References

- Norris T, Collin SM, Tilling K, Nuevo R, Stansfeld SA, Sterne JA, *et al*. Natural course of chronic fatigue syndrome/myalgic encephalomyelitis in adolescents. *Arch Dis Child* 2017;102:522–528. doi: 10.1136/archdischild-2016-311198.
- Blitshteyn S, Chopra P. Chronic fatigue syndrome: from chronic fatigue to more specific syndromes. *Eur Neurol* 2018;80:73–77. doi: 10.1159/000493531.
- Scherbakov N, Szklarski M, Hartwig J, Sotzny F, Lorenz S, Meyer A, *et al*. Peripheral endothelial dysfunction in myalgic encephalomyelitis/chronic fatigue syndrome. *ESC Heart Fail* 2020;7:1064–1071. doi: 10.1002/ehf2.12633.
- Babiker MO, Prasad M. Narcolepsy in children: a diagnostic and management approach. *Pediatr Neurol* 2015;52:557–565. doi: 10.1016/j.pediatrneurol.2015.02.020.
- Spitzer AR, Broadman M. Treatment of the narcoleptiform sleep disorder in chronic fatigue syndrome and fibromyalgia with sodium oxybate. *Pain Pract* 2010;10:54–59. doi: 10.1111/j.1533-2500.2009.00334.x.
- Liew SC, Gupta ED. Methylenetetrahydrofolate reductase (*MTHFR*) C677T polymorphism: epidemiology, metabolism and the associated diseases. *Eur J Med Genet* 2015;58:1–10. doi: 10.1016/j.ejmg.2014.10.004.
- Regland B, Forsmark S, Halaouate L, Matousek M, Peilot B, Zachrisson O, *et al*. Response to vitamin B12 and folic acid in myalgic encephalomyelitis and fibromyalgia. *PLoS One* 2015;10:e0124648. doi: 10.1371/journal.pone.0124648.
- Blockmans D, Persoons P. Long-term methylphenidate intake in chronic fatigue syndrome. *Acta Clin Belg* 2016;71:407–414. doi: 10.1080/17843286.2016.1200816.

**How to cite this article:** Liao Y, Qi JG, Yan H, Zhang QY, Ji TY, Chang XZ, Yang HP, Jin HF, Du JB. Comorbidity of chronic fatigue syndrome, postural tachycardia syndrome, and narcolepsy with 5,10-methylenetetrahydrofolate reductase (*MTHFR*) mutation in an adolescent: a case report. *Chin Med J* 2021;134:1495–1497. doi: 10.1097/CM9.0000000000001387