Squamous cell carcinoma of the uterine cervix extending to the corpus in superficial spreading manner and causing hematometra

Dear Editor,

A fifty year old lady presented with pain in abdomen and thick whitish discharge per vaginum of 3 months duration. She had attained menopause ten years back before which she had normal regular cycles of 4-5/28 days. She had four full term vaginal deliveries which were uneventful. She had no other significant past or family history. On examination she was well oriented and afebrile with a pulse rate of 78/minute and a blood pressure of 128/80 mm Hg. Other systemic examination was unremarkable. Per-vaginal examination revealed a bulky uterus with free vaginal fornices. Per-speculum examination showed a growth on cervix measuring 2.0 × 1.0 × 0.5 cm at 3o' clock position. Biopsy taken from the growth showed an invasive moderately differentiated large cell non-keratinizing squamous cell carcinoma. Subsequent imaging studies were done to know the extent of the disease. Magnetic resonance imaging (MRI) revealed a 5.0 × 4.0 × 3.5 cm enhancing T2 hyper-intense and T1 iso-intense mass lesion in the region of cervix which extended to involve 1 cm of posterior vaginal wall. Apart from this the uterus showed a fluid collection of 5.0 × 5.0 × 4.0 cm [Figure 1]. With a pre-operative diagnosis of carcinoma of the uterine cervix stage IIA, the patient was taken up for radical hysterectomy with bilateral salpingo-oophrectomy. We received the radical hysterectomy specimen measuring 10.0 × 10.0 × 5.0 cm along with bilateral common iliac and deep obturator lymph nodes. The uterine cavity on cutting open showed hemorrhagic fluid in the cavity and the lining was replaced by an irregular shaggy growth along the whole extent [Figure 2]. An infiltrative, gray white, friable growth measuring 2.5 × 2.0 × 1.0 cm was seen in the cervix extending from 2 o'clock to 4 o'clock position. Microscopic examination of the cervix revealed features typical of an invasive moderately differentiated large cell non-keratinizing squamous cell carcinoma. The endometrial lining was completely replaced by superficial spreading squamous cell carcinoma (SSSCC). There was no evidence of invasion of endometrial stroma or myometrium [Figure 3]. The carcinoma was seen to involve posterior part of vaginal wall and extended up to 1 cm. However, the vaginal cut margin and the bilateral parametrial tissue margins were free. All the eleven lymph nodes dissected from bilateral iliac and obturator nodes were also free from tumor. Since all the lymph nodes and margins were negative, no adjuvant radiotherapy or chemotherapy was advised. After 6 month follow-up the patient was disease free.

Squamous cell carcinoma of cervix is one of the most common gynaecological malignancies.[1] Carcinoma of cervix can involve the uterine corpus by direct extension or through parametrium by lymphatic invasion to the uterine wall.[1,2] However, upward extension in a superficial spreading manner replacing the surface epithelium and not invading the underlying endometrial stroma/myometrium is extremely rare and to the best of our knowledge, less than 30 cases have been reported in literature so far.[1] Although initial studies cited the role of radiation in pathogenesis; more recent studies have found the same cell clone in the tissue from cervix as in the endometrium suggesting that these tumors spread from the cervix *per se*.[1] Our case had no previous history of radiation exposure and we could demonstrate physical continuity of cephalic spread the tumor, hence we favour the latter view. Most of the reported cases of SSSCC present with postmenopausal bleeding.[1,2] However,

Figure 1: (a) Photograph showing the MRI image with a 5.0 × 4.0 × 3.5 cm enhancing T2 hyper-intense and T1 iso-intense mass lesion in the region of cervix. (b) Apart from this the uterus showed a fluid collection which is enhancing with the contrast

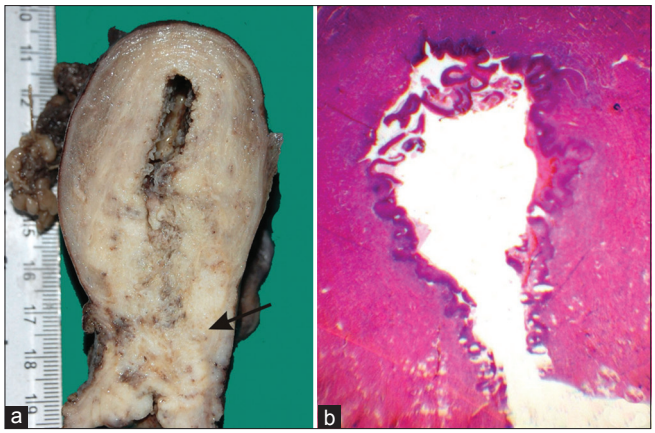

Figure 2: (a) Gross photograph showing cut surface of uterus with uterine cavity lining being replaced by an irregular shaggy growth along the whole extent. Also noted is a cervical growth measuring 2.5 × 20 × 1.5 cm (arrow). (b) Panoramic view of a part of the uterine cavity showing replacement of the entire lining of the uterine cavity with squamous epithelium without invasion of the underlying tissue (H and E, panoramic view)

only one case has presented with hematometra before ours.[1,3] MRI findings can be misleading and can be misinterpreted as endometrial carcinoma especially if the cervical component is small.[4] The histological diagnosis of the primary cervical component has ranged from squamous cell carcinoma *in situ*, microinvasive squamous cell carcinoma, invasive squamous cell carcinoma to adenosquamous carcinoma.[1,2,5,6] Although in most cases, the spread is restricted to endometrium, four cases of spread to fallopian tube as well as ovaries in addition to endometrium have been reported.[1] Moreover, the pattern of spread within the endometrium has been either *in situ* alone like in our case or with an invasive component as well.[1,6] We feel the latter cases must be excluded as they may represent extension to uterine corpus by direct extension or through parametrium.

Since this pattern is unusual, the prognostic significance and management guidelines are lacking.[1,2] Most of the reported cases have presented in an early stage of disease probably due to early endometrial involvement.[1,2] Moreover, these cases did not seem to do any differently from the stage matched cases. International Federation of Gynecology and Obstetrics (FIGO) system of staging has also ignored this unusual mode of spread of carcinoma cervix.[1,2,7] Our patient was also treated in the usual manner and did not show any recurrence 6 months after therapy. We hypothesize that this phenomenon is akin to Paget's disease of nipple and hence no change in staging is recommended. Further studies on a larger scale are essential to elaborate more on the prognostic significance as well as management guidelines.

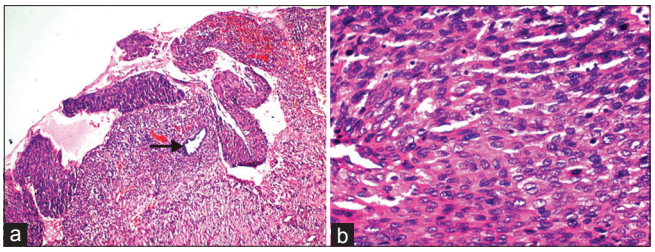

Figure 3: (a) Low power view showing squamous epithelium replacing the endometrial lining. Also seen is one underlying endometrial gland (arrow) (H and E, ×100). (b) High power view showing atypical squamous cells (H and E, ×400)

Harveen Kaur Gulati, Mani Anand, Sanjay D. Deshmukh

Department of Pathology, Smt. Kashibai Navale Medical College and General Hospital, Narhe, Off Pune-Mumbai Bypass, Pune, Maharashtra, India
E-mail: harveengulati78@gmail.com

REFERENCES

1. Gungor T, Altinkaya SO, Ozat M, Akbay S, Mollamahmutoglu L. Unusual form of superficial spreading squamous cell carcinoma of cervix involving the endometrium, bilateral tubes and ovaries: A case report with literature review. Arch Gynecol Obstet 2011;283:323-7.
2. Agashe SR, Kulkarni MP, Momin YA, Sulhyan KR. Superficial extension of squamous cell carcinoma *in situ* of cervix involving endometrium, bilateral fallopian tubes and ovaries: A case report. Indian J Pathol Microbiol 2007;50:375-7.
3. Kushima M, Fujii H, Murakami K, Ota H, Matsumoto T, Motoyama T, *et al.* Simultaneous squamous cell carcinomas of the uterine cervix and upper genital tract: Loss of heterozygosity analysis demonstrates clonal neoplasms of cervical origin. Int J Gynecol Pathol 2001;20:353-8.
4. Adler F, Rabban JT, Yeh BM, Qayyum A, Chen LM, Coakley FV. Superficial endometrial spread of squamous cell cervical carcinoma: A diagnostic challenge at magnetic resonance imaging. J Comput Assist Tomogr 2007;31:247-50.
5. Tan GC, Isa MR, Ng SP, Jamil YM. Unusual form of superficial spreading microinvasive squamous cell carcinoma of uterine cervix involving the endometrium of uterus. J Obstet Gynaecol Res 2004;30:363-7.
6. Lim C, Leecy T, McKenzie P, Pather S, Carter J, Russell P. Two cases of adenosquamous carcinoma of cervix with extensive *in situ* and invasive endometrial extention. Int J Gynaecol Pathol 2011;30:193-7.
7. Edge SB, Byrd DR, Compton CC, Fritz AG, Greene FL, Trotti A. AJCC Cancer Staging Manual, 7th ed. New York: Springer-Verlag; 2010. Available from: http://www.cancerstaging.net.[Last accessed on 2012 Aug 8].

Access this article online

Quick Response Code:

Website: www.jmidlifehealth.org

DOI: 10.4103/0976-7800.109644