

Case report on pediatric septic arthritis of the hip

Shireen Prince¹, Rao Tulasi²

¹ Department of Pharmacy Practice, Malla Reddy Pharmacy College, Dhullapally, Secunderabad, Telangana, India

² Department of Paediatrics, Malla Reddy Institute of Medical Sciences, Secunderabad, Telangana, India

ARTICLE INFO

Corresponding author:

Shireen Prince
Department of Pharmacy Practice
Malla Reddy Pharmacy College
Dhullapally, Secunderabad-500100
Telangana
India
E-mail: shireenprince@gmail.com

Key words:

septic arthritis, pain, fever,
staphylococcus aureus and arthrotomy

ABSTRACT

Septic arthritis is a condition from the presence of microbial agents in a joint space.

A 9 year old boy presented with pain in right hip joint which was tender on palpation, associated with fever (38.3°C). Blood tests showed elevated levels of C reactive protein and erythrocyte sedimentation rate. No pathological findings were found in X-ray of the hip and ultrasound of right hip joint showed mild increase in joint space. Pus culture and sensitivity yielded plenty pus cells in pairs of chains and Methicillin sensitive Staphylococcus aureus was isolated. Treatment with antibiotics was started and right hip arthrotomy and debridement was done followed with skin traction. Follow up was done and the boy had regained his full range of motion with no sign of complications.

INTRODUCTION

Septic arthritis (SA) of the hip is a true orthopedic emergency; delay in diagnosis or treatment may result in irreversible damage to the joint.¹ Staphylococcus aureus is the usual offending microorganism, present in 50% of cases.^{2,3,4} Early diagnosis and accurate treatment is key in avoiding complications such as joint destruction, ankylosis, growth arrest or spread of infection leading to osteomyelitis or nerve lesions.^{5,6} SA is a challenging clinical problem because (1) signs and symptoms may be subtle and overlap with those found in other conditions, (2) screening laboratory studies and synovial fluid cultures are relatively insensitive, and (3) optimal management, including duration of antibiotics and surgical approach, is not evidence based.¹

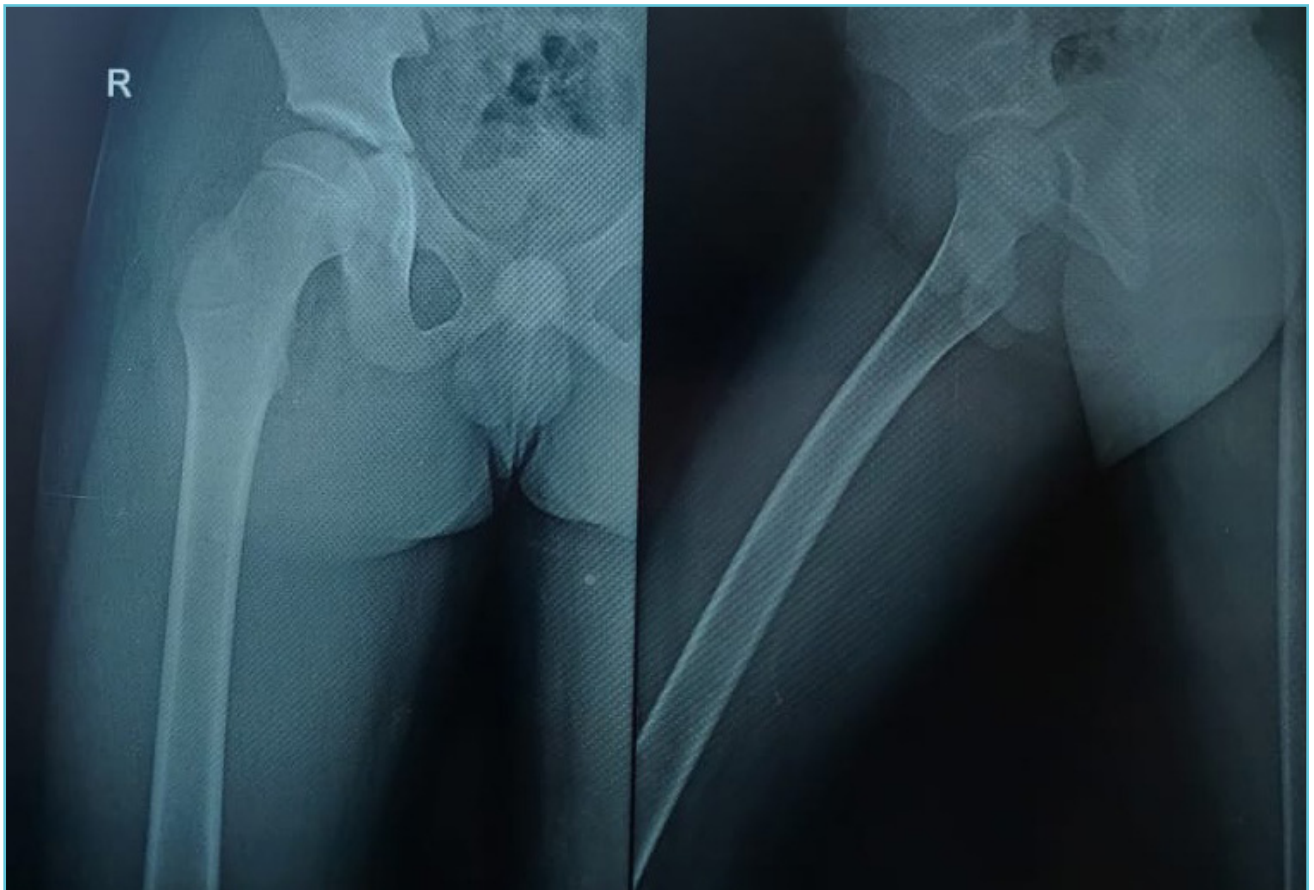
CASE PRESENTATION

A 9 year old boy weighing 30 kg presented with fever (38.3°C) and pain in his upper right thigh, having begun one day prior; and which had increased on the day of his presentation. Parents also reported the pain was sudden in onset and there was restriction in movement. Birth history was normal and uneventful. There was no history of trauma.

Physical examination revealed right anterior superior iliac spine (ASIS) at lower level; flexion abduction altitude; anterior joint line tenderness over right thigh; painful extension of hip and flexion with painful external rotation and internal rotation.

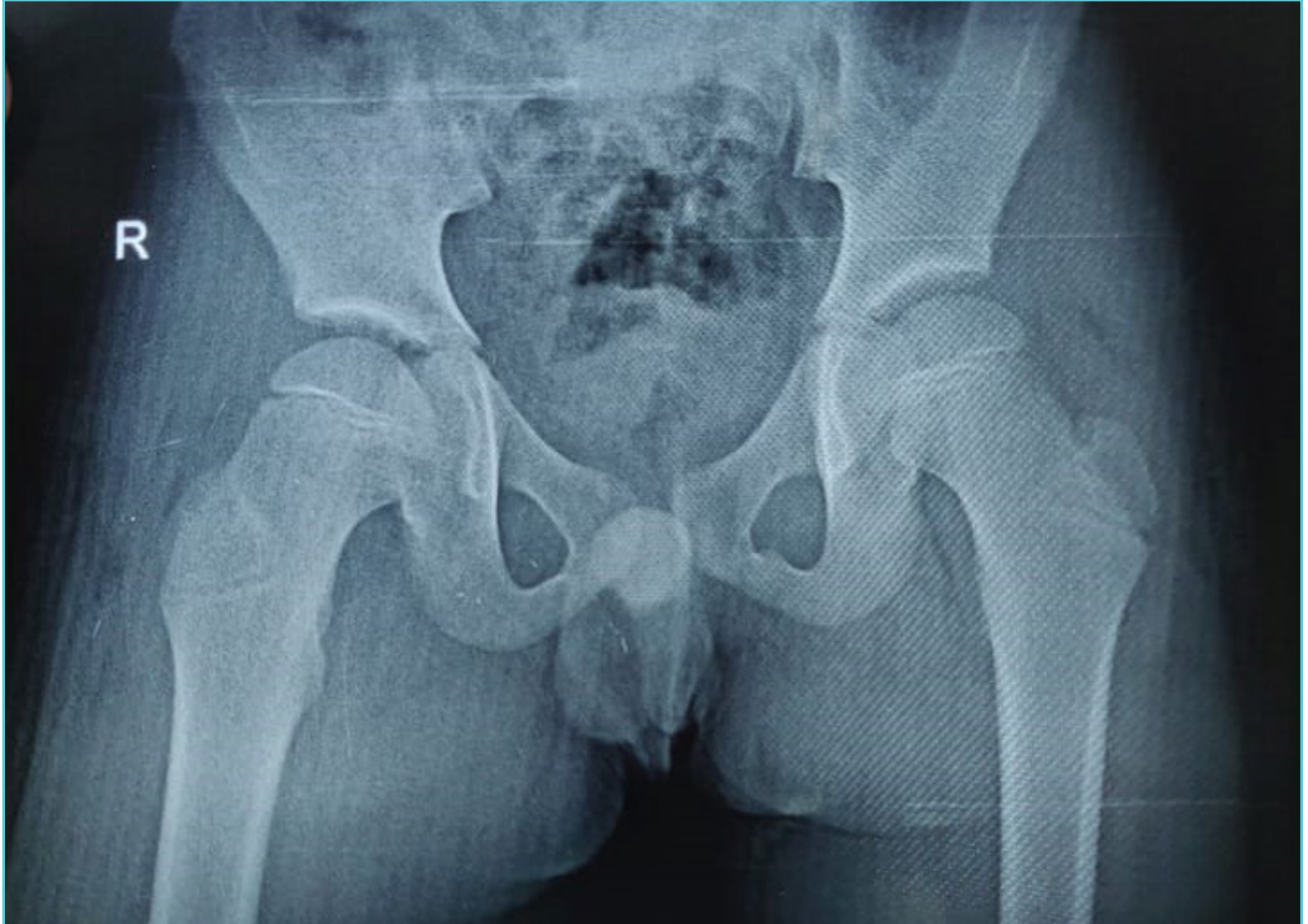
No distal neurovascular deficit was reported.

Figure 1A Plain radiograph of the right hip, showing no pathological findings



To exclude bony lesions X-rays in anterioposterior and lateral view were performed.

Figure 1B Plain radiograph of pelvis with both hip joints, showing no pathological findings



LABORATORY INVESTIGATIONS

Blood tests revealed an elevated level of C reactive protein of 4.8 mg/dL. Erythrocytes sedimentation rate was 80 mm/1 hr. Blood cell count showed 16.8×10^9 leucocytes/L with a differential of 87% neutrophils and 18% lymphocytes. Haemoglobin was 99 g/L and mean cell volume was 72 fL, revealing a microcytic anaemia with neutrophilia.

X-rays of the pelvis with both hips and of right hip with thigh revealed no abnormality. The ultrasound of the right hip joint showed mild increase in joint space of right hip joint as compared to the left hip joint, which indicated signs of inflammation.

Plain radiograph of the right hip showing no pathological findings. To exclude bony lesions X-rays in anteroposterior and lateral view were performed (Fig. 1A, 1B).

TREATMENT

Due to functional limitation, pain, and elevated CRP and leucocytes the decision was taken for arthrotomy & debridement of the right hip. The hip was aspirated with 16 G needle; pus was confirmed. An incision of 10cm posterior and lateral tip of greater trochanter and about 5cm upto proximal femur was done. The pus welled out into the wound which was sucked and drained. The capsule is retracted and thorough irrigation

Table 1 Laboratory parameters

Parameter	Result	Reference
C Reactive Protein	4.8mg/dL	<0.6mg/dL
Erythrocyte Sedimentation Rate	80mm/1hr	0-15mm/1hr
Haemoglobin	99g/L	138 -172g/L
Mean Cell Volume	72fL	80-96fL
Leucocytes	16.8x10 ⁹ cells/L	4.3-10.8x10 ⁹ cells/L
• Neutrophils	87%	40-60%
• Lymphocytes	8%	20-38%
• Eosinophils	1%	2-7%
• Monocytes	5%	4-7%
• Basophils	0 %	<1-2%

with copious amount of saline was done. A piece of synovium was taken for biopsy. Post operated limb was given skin traction to prevent flexion and internal rotation. Abduction pillow was also used.

Pus for gram stain revealed plenty of pus cells gram positive cocci in pairs and chains (Acid Fast Bacillus negative). Methicillin sensitive staphylococcus aureus was isolated from pus culture and sensitivity. Post operative treatment included intravenous Ceftriaxone, Amikacin, Diclofenac sodium, Pantoprazole. Oral medications include tablet Chymoral forte and Limcee.

The patient's condition remained stable after surgery. The CRP and white cell count (WCC) dropped on sequential postoperative testing. After 10 days the boy started to mobilise his leg spontaneously. No further surgical intervention was required and intravenous antibiotic treatment was continued for 14 days. At 2 weeks the

patient was discharged following normal clinical and laboratory findings. The parents were instructed to continue the child on oral antibiotic treatment for 4 weeks. Follow-up examination of 2 years revealed a healthy boy with a full range of motion and no sign of complications.

DISCUSSION

Septic arthritis in children is one of the few true orthopaedic emergencies. It is very important to make the diagnosis as early as possible to avoid sequelae such as cartilage destruction, osteomyelitis, ankylosis, growth aberration due to physical damage, joint instability and restriction of movement.^{7,9}

Early diagnosis in young children can be particularly challenging. In addition, clinical symptoms in these young patients can range from subtle signs, such as restlessness and poor appetite without fever, to the more common diagnostic

criteria of inflammation such as swelling, erythema, warmth, functional limitation and location specific pain.^{3,7} The medical history is, as always, crucial to diagnosis, in particular other foci of infection such as the respiratory tract.⁸

In contrast to children with septic arthritis (SA), children with transient synovitis appear well and are usually afebrile with just a mild limp.⁹ Differentiating septic arthritis from transient synovitis of the hip is particularly important given the need for urgent surgical intervention for the former condition.

The radiological investigations in this case did not reveal much important findings. X-ray findings are often unremarkable, as was the situation here, except in cases that have proceeded to chronic infection.¹⁰ Ultrasonography has a greater sensitivity than plain radiography and is becoming the modality of choice to reveal hip effusions.¹¹ When septic arthritis (SA) is suspected, synovial fluid should be obtained for a complete blood count (CBC), glucose, Gram stain, and culture. The C-reactive protein (CRP) is a more sensitive marker for septic arthritis than is the peripheral WBC count.¹¹ In one study, a CRP of more than 2 mg/dL was found to be a strong independent risk factor for SA of the hip among children presenting with hip pain.¹²

Septic arthritis of the hip requires emergent irrigation and drainage to minimize risk of aseptic necrosis of the femoral head. The optimal duration of antibiotic therapy is not defined, and recommendations vary from 1-6 weeks.

CONCLUSION

We presented a case where immediate surgical intervention and follow up helped in recovery of the patient. Our case uniquely demonstrates that a minimally invasive arthroscopic irrigation of the hip was adequate, and resulted in an excellent clinical outcome.

TAKE HOME MESSAGES/ LEARNING POINTS

- Time to diagnosis is the most important prognosticating factor in septic arthritis. Early institution of therapy helps to prevent degenerative arthritis.
- If lower extremity joints are involved, parents often report that children cannot bear weight and that they resist all efforts to move the involved joint.
- The presence or absence of fever may be helpful in distinguishing septic arthritis from transient synovitis of the hip.
- The C-reactive protein (CRP) is a more sensitive marker for septic arthritis than is the peripheral WBC count.
- Hospitalize all children presumed to have septic arthritis (SA) for empiric intravenous antibiotic therapy.
- Post operative skin traction is beneficial to prevent flexion.



Authors' contributions

Shireen conceived the idea and wrote and edited the manuscript.

Dr. Tulasi was the paediatrician managing the patient and contributed to the manuscript.



REFERENCES

1. Pediatric Septic Arthritis: Practice Essentials, Background, Pathophysiology. Available at: <https://emedicine.medscape.com/article/970365-overview>.
2. Hefti F, Freuler F, Hinchcliffe R, et al. Pediatric orthopedics in practice. Springer, 2007.
3. Al Saadi MM, Al Zamil FA, Bokhary NA, et al. Acute septic arthritis in children. *Pediatr Int* 2009;51:377–80.
4. Akinyoola AL, Obiajunwa PO, Oginni LM. Septic arthritis in children. *West Afr J Med* 2006;25:119–23.

5. Kariminasab MH, Shayesteh Azar M, Sajjadi Saravi M. Surgical intervention for treatment of septic arthritis in infancy and childhood; a retrospective study. *Arch Iran Med* 2009;12:409–11.
6. Michelotti F, Camathias C, Gaston M, et al. Severe septic arthritis of the shoulder with an axillary nerve lesion in a 4-year-old child. *J Orthop Sci* 2011;16:821–4.
7. Kariminasab MH, Shayesteh Azar M, Sajjadi Saravi M. Surgical intervention for treatment of septic arthritis in infancy and childhood; a retrospective study. *Arch Iran Med* 2009;12:409–11.
8. Michelotti F, Camathias C, Gaston M, et al. Severe septic arthritis of the shoulder with an axillary nerve lesion in a 4-year-old child. *J Orthop Sci* 2011;16:821–4.
9. Taekema HC, Landham PR, Maconochie I. Towards evidence based medicine for paediatricians. Distinguishing between transient synovitis and septic arthritis in the limping child: how useful are clinical prediction tools?. *Arch Dis Child*. 2009 Feb. 94(2):167-8. [Medline].
10. Tabea Haas, Mark S Gaston, Erich Rutz, Carlo Camathias. Septic arthritis of the elbow with *Streptococcus pneumoniae* in a 9-month-old girl. *BMJ case reports* 2014;9-12.
11. Pediatric Septic Arthritis: Practice Essentials, Background, Pathophysiology. Available at: <https://emedicine.medscape.com/article/970365-workup>.
12. Caird MS, Flynn JM, Leung YL, et al. Factors distinguishing septic arthritis from transient synovitis of the hip in children. A prospective study. *J Bone Joint Surg Am*. 2006 Jun. 88(6):1251-7. [Medline].