

Article

Functional Staging of Corneal Neovascularization Using Fluorescein and Indocyanine Green Angiography

Christoph Palme¹, Vito Romano², Matthias Brunner², Riccardo Vinciguerra², Stephen B. Kaye^{2,3}, and Bernhard Steger¹

¹ Department of Ophthalmology, Medical University of Innsbruck, Innsbruck, Austria

² Department of Corneal and External Eye Diseases, St. Paul's Eye Unit, Royal Liverpool, University Hospital, Liverpool, UK

³ Department of Eye and Vision Science, University of Liverpool, Liverpool, UK

Correspondence: Bernhard Steger, Department of Ophthalmology, Medical University of Innsbruck, Anichstrasse 35, Innsbruck 6020, Austria. e-mail: Bernhard.steger@i-med.ac.at

Received: 1 October 2017

Accepted: 7 August 2018

Published: 1 October 2018

Keywords: corneal neovascularization; angiography; fluorescein; indocyanine green angiography; staging

Citation: Palme C, Romano V, Brunner M, Vinciguerra R, Kaye SB, Steger B. Functional staging of corneal neovascularization using fluorescein and indocyanine green angiography. *Trans Vis Sci Tech.* 2018;7(5):15. <https://doi.org/10.1167/tvst.7.5.15> Copyright 2018 The Authors

Purpose: Corneal neovascularization (CoNV) is a major risk factor for corneal graft rejection and other corneal conditions. The maturity of CoNV is important to guide treatment. This study investigated associations between clinical and angiographic characteristics of CoNV.

Methods: In a prospective cross-sectional study patients with CoNV of variable but known duration and etiology were included. All cases were clinically staged according to a simplified three-grade scale as active, inactive, and regressed and assessed using color photography, anterior-segment optical coherence tomography, and fluorescein and indocyanine green (ICG) angiography. Outcome parameters included age and depth of CoNV, perfusion times and time to leakage of fluorescein and ICG.

Results: Forty eyes of 39 patients with CoNV were included, active (14), inactive (22), and regressed CoNV (4). There were significant associations between the time to fluorescein or ICG leakage and clinical staging of CoNV ($R^2 = 0.24$; $P = 0.0011$, and $R^2 = 0.3$; $P = 0.0001$). In addition, there was a significant association between the time to fluorescein leakage and the age of CoNV ($R^2 = 0.32$; $P = 0.0002$). ICG leakage within 10 minutes was observed significantly more frequently in active than the inactive group and was not observed in regressed cases ($P < 0.0001$).

Conclusions: Simplification of the staging of CoNV to active, inactive, and regressed to is significantly associated with the time to extravascular leakage of fluorescein and indocyanine and may be useful to guide the selection of appropriate treatments.

Translational Relevance: The association between clinical and angiographic characteristics of CoNV may provide guidance to the treatment approaches.

Introduction

Corneal transplantation is one of the most successful and commonly performed types of transplants.^{1,2} Despite its success, there are a number of important risk factors associated with reduced graft survival. These include ocular inflammation, glaucoma, sex mismatch, timing of bilateral transplants, and corneal neovascularization (CoNV).^{3–5} It has been shown, that the risk of graft rejection and failure increases with the number of corneal quadrants affected by CoNV.³ In order to reduce the risk of graft failure and improve long-term graft survival,

patients with CoNV undergoing corneal transplantation are subjected to preconditioning treatment (PT) of the recipient stromal bed, which aims at a significant reduction of the area CoNV.⁶

Several medical and surgical treatment approaches for the management of CoNV have been investigated.⁷ In the treatment of mature CoNV, surgical interventions, such as fine needle diathermy (FND), are recommended, but potential adverse effects need to be considered, including damage to peripheral corneal endothelium and limbal epithelial stem cell niche.^{8,9} We have shown, that angiography-guided selective application of FND limited to afferent vascular branches of CoNV is an effective method

to reduce mature CoNV while carrying less potential to damage to the limbal epithelial stem cell niche and the peripheral corneal stroma.^{10,11}

Selective inhibitors of vascular endothelial growth factor (VEGF) and steroid eye drops are used successfully to reduce young active CoNV, targeting predominantly immature vessels.¹² In an attempt to estimate the activity and maturity of CoNV, a five-stage clinical grading system has been proposed.^{13,14} It is, however, extremely difficult if not impossible to reliably assess these parameters based solely on the biomicroscopic appearance of CoNV. Additionally, not all of the CoNV is clinically evident, especially in the presence of stromal scarring.¹⁵ Consequently, color photographic assessment may underestimate the area of CoNV (AOC) and relative risk to a planned corneal transplant. As shown by our group, the combined use of fluorescein and indocyanine green angiography (FA/ICGA) has demonstrated better vessel delineation than that obtained with color images alone, particularly for blood vessels located in deeper layers of the cornea, beneath areas of corneal scarring and for inactive vessels with decreased or absent red blood cell traffic.^{16,17} We have also shown, that ICGA in conjunction with objective computer-assisted image analysis provides a reliable method for assessing quantitative changes of CoNV by measuring the vessel diameter, distribution of vessel diameters, origin, and vessel tortuosity.^{18,19} We provided preliminary evidence, that the time and extent of leakage of fluorescein dye may reflect the activity of CoNV, and therefore offer the potential to functionally stage CoNV.^{16,17} This study was performed in order to test for an association between angiographic features of perfusion and leakage with the clinical stage of CoNV. The aim of this study was to determine objective parameters of vessel maturity, which may be useful to guide the selection of the most appropriate type of treatment of CoNV.

Methods

This investigation was designed as a prospective cross-sectional observational study, including patients between 18 and 85 years of age with clinically visible CoNV of variable but specified etiology and duration, extending at least 3 mm onto the cornea on slit-lamp biomicroscopy. Consecutive patients were recruited, who presented for specialist assessment at the cornea clinic at the Department of Ophthalmology of the Medical University of Innsbruck (MUI), Austria. All patients with CoNV of documented onset and age

and who were fit to have FA/ICGA were invited to join the study.

Exclusion criteria included an undocumented age and onset of CoNV, recurrent episode(s) of inflammation after the documented onset of CoNV, a history of allergy to fluorescein, iodides, and shellfish, or the inability to fixate a target.

After inclusion, an ophthalmic history was collected in each patient on a standardized data collection form. This included best-corrected visual acuity (BCVA) recorded on a decimal scale with visual acuities of counting finger, hand movements, and projection of light converted according to a validated scale,²⁰ patient demographics (age, sex), diagnosis, duration of symptoms, previous treatment (medical and surgical), BCVA, and history of allergies. A clinical examination using slit-lamp biomicroscopy was undertaken and a diagram of CoNV and opacification was recorded. Particular note was made of any conjunctival, limbal, or corneal abnormalities. For each case, clinical staging was initially attempted according to a biomicroscopic five-point scale for CoNV, briefly defined as follows¹³:

Stage 1. Active young vessels: newly formed and progressing vessels with bright-red appearance and a well-defined fine capillary network. Signs of leakage and edema in the surrounding corneal stroma.

Stage 2. Active old vessels: less bright vessels that reach the offending lesion, not progressing.

Stage 3. Partially regressed vessels: vessels with slow blood circulation and reduced visibility. Abated corneal pathology and edema in response to treatment.

Stage 4. Mature vessels: relatively large vessels, with minimal arborization and regressed or absent capillary networks, persisting in scar tissue or in the corneal stroma, with maintained red blood cell perfusion.

Stage 5. Regressed (ghost vessels): fine white lines mirroring the morphology of the original vessels without visible red blood cell circulation.

It was found, however, that the differentiation between stages 1 and 2, as well as between stages 3 and 4 according to the published criteria, was unreliable and too subjective, as also acknowledged by the authors.¹³ Therefore, for the no distinction was made between stages 1 and 2, and between 3 and 4. Three subgroups of clinical stages of CoNV were therefore formed, 'Active CoNV' (stages 1 or 2),

'Inactive CoNV' (stages 3 or 4), and 'Regressed CoNV' (ghost vessels, stage 5).

The presence of corneal scarring, corneal edema, exudative keratopathy, corneal ulceration, and relative depth of corneal melting was assessed using slit-lamp biomicroscopy.

Additional assessment included color, red-free and autofluorescence photography, anterior-segment optical coherence tomography (AS-OCT), and FA/ICGA of the AOC and adjacent limbus and conjunctiva, which is the region of interest (ROI). The limbus and adjacent conjunctiva are imaged to identify the main afferent and efferent vessels of the CoNV, which are situated in the limbus and adjacent conjunctiva. The depth of CoNV and minimal corneal thickness in the AOC was calculated from AS-OCT sections.

Informed consent was obtained and the study was conducted according to the tenets of the Declaration of Helsinki. The Ethics committee of MUI, carrying the identification number AN2015 0287 356/4.8, approved this study. The occurrence of adverse events and reactions (anaphylaxis, microbial keratitis, uveitis, loss of 2 or more lines of visual acuity) was documented on a designated and approved adverse events and reactions form.

Color Photography

Color photographs of the cornea were recorded using a slit-lamp mounted digital system (SL-D Digital Slit Lamp; Topcon, Tokyo, Japan). The entire cornea was imaged from limbus to limbus using 10-fold magnification of the ROI. Illumination was from a 45° angled beam on slit-lamp biomicroscopy with a diffuser filter and a variable flash intensity. An anterior-posterior image with diffuse beam and no filter was also obtained. Images with green filter and open beam at magnifications of 10-fold were recorded. A total of 18 color images were obtained for each patient.

Fluorescein and Indocyanine Green Angiography (ICGA/FA)

Both ICGA and FA were acquired using a scanning laser ophthalmoscope (HRA2; Heidelberg Engineering, Heidelberg, Germany). Five milliliters of 5 mg/mL indocyanine green dye (Pulsion Medical Systems, Munich, Germany) were injected into a peripheral arm followed immediately by videography for 20 seconds. Single-frame ICGA photographs of the whole cornea capturing corneal blood vessel

fluorescence every 5 seconds were taken for 3 minutes in high-resolution mode incorporating automatic real-time (ART) software. This was followed by an intravenous injection of 3 mL of 10% sodium fluorescein (Martindale Pharmaceuticals, Essex, UK). The photographs were taken up to 3 minutes, similar to ICGA. Late ICGA and FA images were taken every minute between 5 and 10 minutes.

Anterior Segment Optical Coherence Tomography (AS-OCT)

Using the Heidelberg Spectralis HRA-OCT scanning laser ophthalmoscope (Heidelberg Engineering, Heidelberg, Germany) in conjunction with the AS module, corneal AS-OCT scans of the AOC were performed to calculate the depth of CoNV and corneal thickness in the AOC with the system-integrated software.

Image Analysis

Video pictures taken immediately after the injection of fluorescein or ICG were analyzed independently by two observers (BS and CP) for appearance of dye. Color images were analyzed for quality and clarity of ROI. The best ICGA, FA, and color images were independently selected by same two observers based on the following qualitative subjective parameters: quality grading for ICGA and FA was categorized as 0 to 4 (0, no vessel discernible; 1, poor vessel delineation; 2, good vessel delineation; 3, very good vessel delineation; 4, excellent vessel delineation). The images with good vessel delineation would have at least 50% of vessels clearly evident with distinct boundaries and hyperfluorescence. Quality grading for color images was categorized as 0 to 3 (0, no focus on ROI; 1, poor focus on ROI, no details of corneal scar/vessel; 2, acceptable focus on ROI, identifiable corneal scar/vessel; 3, very good or excellent focus on ROI, details of corneal scar and vessels evident). Only patients with images of quality score 3 or more for both ICGA and FA and quality score 2 or more for color were included for further analysis. Haziness and increasing fluorescence of corneal stroma adjacent to the blood vessels on FA images was considered as evidence of leakage. The relationship between leakage of fluorescein dye and duration of CNV was also examined. The best available ICGA, FA, and color image of the study eye of each patient was exported in TIFF format for the purpose of further analysis.

Table 1. Clinical Patient Characteristics in the Three Groups

	Active CoNV	Inactive CoNV	Regressed CoNV
<i>n</i>	14	22	4
Age (mean, y)	65.2 ± 15.4 (minimum [min] 43, maximum [max] 87)	55.4 ± 23.1 (min 14, max 85)	68.3 ± 10.1 (min 56, max 78)
% female	14.3 (<i>n</i> = 2)	18.2 (<i>n</i> = 4)	50.0 (<i>n</i> = 2)
BCVA (mean)	0.22 ± 0.30	0.25 ± 0.36	0.31 ± 0.34
% topical steroids	28.6 (<i>n</i> = 4)	31.2 (<i>n</i> = 7)	0.0
% topical antimicrobials	85.7 (<i>n</i> = 12)	18.2 (<i>n</i> = 4)	0.0
% exudative keratopathy	42.9 (<i>n</i> = 6)	18.2 (<i>n</i> = 4)	0
% corneal edema	71.4 (<i>n</i> = 10)	4.5 (<i>n</i> = 1)	0
% epithelial defect	42.9 (<i>n</i> = 6)	0.0	0
% corneal scar	64.3 (<i>n</i> = 9)	100 (<i>n</i> = 22)	100 (<i>n</i> = 3)
% corneal infiltrate	35.7 (<i>n</i> = 5)	0.0	0
Relative loss of corneal thickness (% melting)	18.3 ± 22.01 (min 0, max 80)	22.7 ± 20.6 (min 0, max 80)	3.4 ± 5.6 (min 0, max 10)
Age of CoNV (median, wk)	4 ± 7 (min 1, max 28)	203 ± 381 (min 23, max 1720)	3104 ± 1418 (min 435, max 3432)

Outcome Parameters and Statistical Analysis

Outcome measures included the time to dye leakage, perfusion velocity, and depth of CoNV. The primary outcomes were tested for normal distribution, and if the normality was not satisfied, normality transformations, such as log or sort, were used. A Student *t*-test was used for if the data followed a normal distribution and a Mann-Whitney *U* test for nonparametric distribution. The associations between outcomes were tested using general linear models. A level of probability of less than 0.05 was considered statistically significant. A Bonferroni correction was made for multiple tests. Mean values with standard deviation are given for normally distributed data, and medians when the normality was not satisfied.

Results

Forty eyes of 39 consecutive patients with CoNV fulfilling the inclusion criteria were included. There were 31 men and 8 women, with a mean overall age of 60.1 ± 20.4 years. The most common diagnoses were herpetic keratitis (*n* = 15), trophic ulcer (*n* = 8), and bacterial keratitis (*n* = 6). Other diagnoses included graft rejection (*n* = 4), interstitial keratitis (*n* = 3), Acanthamoeba keratitis (*n* = 2), exposure keratitis (*n* = 1), and chemical burn (*n* = 1). The median of the age of CoNV was 96 weeks (minimum 1, maximum 3432).

Eleven cases (27.5%) were treated with steroid eye

drops, and 16 cases (40.0%) treated with topical antimicrobial treatments at the time of the study examination.

Patients were classified as cases with active CoNV (stages 1 or 2; 14 cases), inactive CoNV (stages 3 or 4; 22 cases), or regressed CoNV (stage 5; 4 cases). Clinical characteristics of included patients in these three groups are given in Table 1, OCT-based and angiographic characteristics in Table 2.

The patients in the three groups did not differ significantly with regard to age, sex, diagnoses, and BCVA. Topical steroids were used in 28.6% of cases in the active and 31.2% in the inactive group and in none of the regressed CoNV group. Within these groups, steroid use was not associated with a longer time to fluorescein leakage (34.2 ± 5.7 vs. 30.7 ± 5.8, *P* = 0.450 in the active group; 45.7 ± 27.3 vs. 62.9 ± 33.4, *P* = 0.677 in the inactive group). Time to fluorescein leakage was significantly associated with the clinical staging of CoNV, with longer time to leakage in more advanced stages ($R^2 = 0.24$; *P* = 0.0011 and $R^2 = 0.22$; *P* = 0.0018). Likewise, there was a significant association between the time to ICG leakage and clinical staging ($R^2 = 0.37$; *P* = 0.0001 and $R^2 = 0.31$; *P* = 0.0002). Additionally, there was a significant association between the time to fluorescein leakage and the age of CoNV ($R^2 = 0.32$; *P* = 0.0002, Fig. 1). ICG leakage within 10 minutes was observed significantly more frequently in active than the inactive group and was not observed in regressed cases (*P* <

Table 2. Angiographic and OCT-Based Characteristics of CoNV

	Active CoNV	Inactive CoNV	Regressed CoNV	P
n	14	22	4	-
Time to fluorescein leakage, s	31.7 ± 5.8 (min 23, max 42)	57.4 ± 31.9 (min 25, max 130)	95.8 ± 89.7 (min 45, max 230)	0.007*
Presence of ICG leakage, %	100.0 (13/13) ^a	9.1 (2/22)	0.0 (0/4)	<0.0001*
FA perfusion time, s	29.3 ± 7.2 (min 17, max 40)	44.0 ± 34.3 (min 21, max 185)	60.0 ± 23.8 (min 36, max 86)	0.102
ICGA Perfusion time, s	28.8 ± 7.3 (min 17, max 43)	50.7 ± 48.5 (min 22, max 255)	63.2 ± 24.8 (min 38, max 85)	0.146
Depth of CoNV, μm (n = 28)	271.9 ± 129.2 (min 120, max 528)	256.1 ± 105.4 (min 150, max 400)	258.3 ± 117.9 (min 133, max 367)	0.921
Posterior depth of scar/infiltrate, μm (n = 28)	226.0 ± 88.3	330.5 ± 158.5	486.3 ± 178.9	0.056

* Significance set at $P < 0.0083$ (Bonferroni correction).

^a One case excluded due to lacking ICG angiographic data.

0.0001). ICG leakage was observed in 100% of the active group, 9.1% of cases in the inactive group and no cases in the regressed group. The mean time to ICG leakage was 316 ± 175.4 sec. ICG leakage was not

observed in cases with CoNV older than 28 weeks (Fig. 1). Representative cases of all three subgroups are shown in Figure 2, including color photographs, ICG, and fluorescein angiograms.

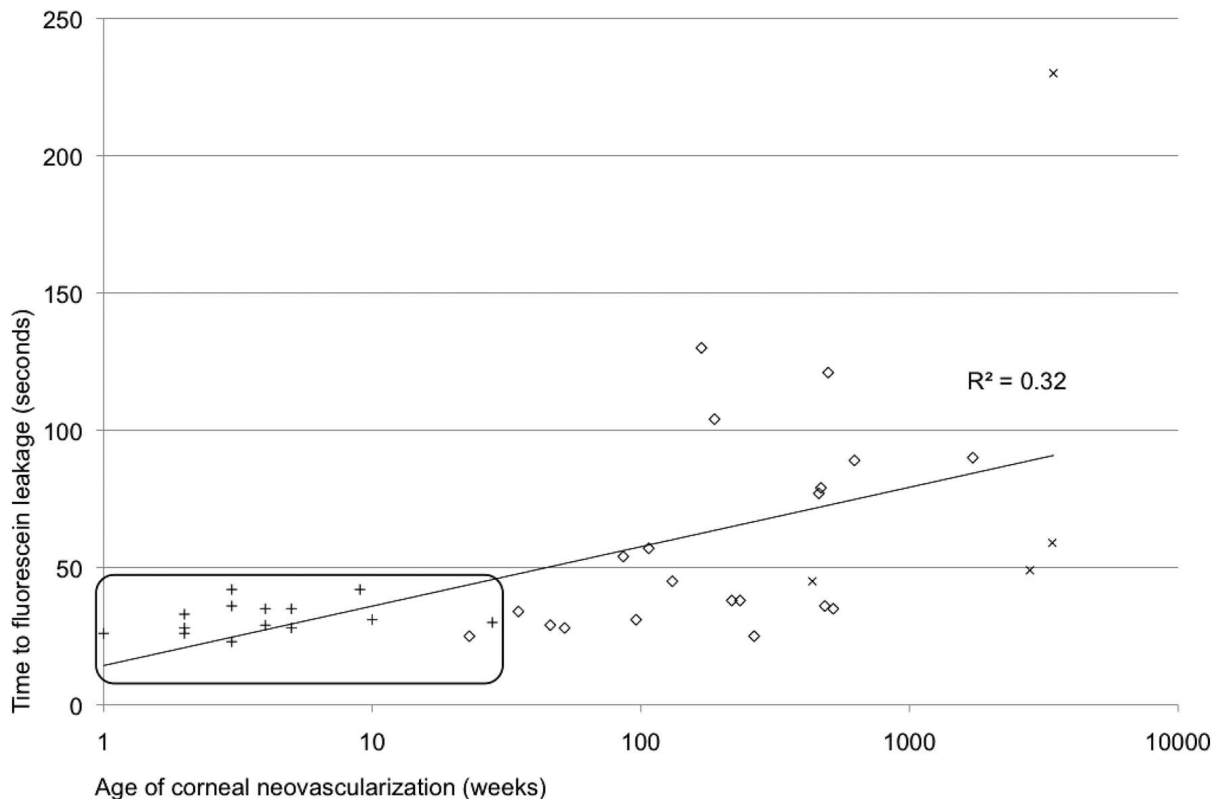


Figure 1. Association between time to fluorescein leakage and age of CoNV. The clinical stage of CoNV is indicated as follows: + active CoNV, ◇ inactive CoNV, × regressed CoNV. All cases with observed ICG leakage are contained in the marked square.

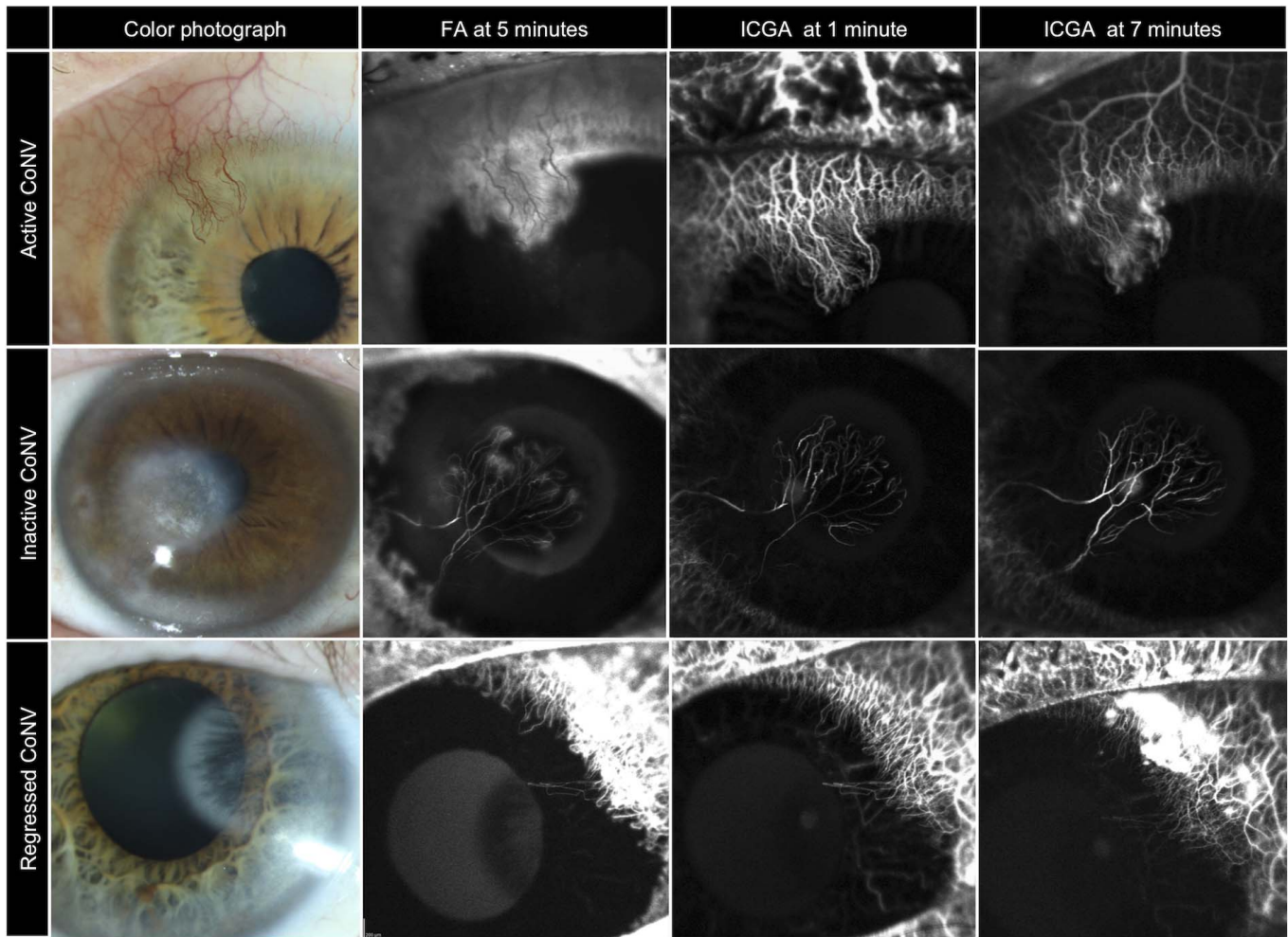


Figure 2. Fluorescein and ICG angiograms of representative cases from the three subgroups of clinical stages of CoNV, showing significant ICG leakage from active but not inactive or regressed CoNV.

Discussion

It is known that the angioregressive potential of locally applied corticosteroids or inhibiting agents of VEGF receptor (anti-VEGF) decrease with the maturity of the targeted CoNV.^{7,14} Therefore, surgical methods, such as FND, are then recommended to treat mature CoNV.^{7,10,11} During vessel maturation in corneal angiogenesis, pericyte coverage is a histologic indicator of decreasing VEGF dependence. Pericyte recruitment is a fairly rapid process occurring in the majority of CoNV between its onset and keratoplasty.²¹ It is however, difficult to estimate the level of vessel maturity in vivo. The proposed clinical staging scales of CoNV lack objective measures of vessel maturity and the biomicroscopic characteristics have not been correlated with histologic evidence of vessel maturity.¹³

In this study, we identified functional angiographic parameters that were significantly associated with clinically evident stages of CoNV. Based on previous preliminary evidence supporting the hypothesis of changing fluorescein leakage behavior during maturation of CoNV,¹⁶ our results confirm that the time to both fluorescein and ICG leakage increase with clinical staging of CoNV. Specifically, ICG leakage was predominately found in young and active CoNV, which strongly suggests this parameter as an indicator of vessel immaturity and thus potential responsiveness to anti-VEGF treatment. While the time to leakage is useful for FA, ICG leakage is best described as either present or absent.

The use of a previously proposed five-grade biomicroscopic staging scale of CoNV¹³ was attempted but found to be of limited clinical feasibility due to unreliable differentiation between stages 1 and 2 or

stages 3 and 4, as also acknowledged by the authors in the original description.¹³ This very limitation underlines the need for objective measures reflecting functional stages and maturity of CoNV. We found a simplified clinical three-stage classification (active, inactive, and regressed CoNV) to be supported by the angiographic findings and age of CoNV, and to be easier to use. Leakage of ICG dye within 10 minutes was identified in 100% of active but only in 6.3% of inactive or regressed CoNV. The leakage of ICG from CoNV has not previously been described in literature, but was recently reported in conjunctival vessels in patients with active but not inactive atopic keratoconjunctivitis.²² ICG is more than 95% albumin bound in human plasma and was previously thought to not leak from corneal vessels. Transvascular leakage of large molecules from conjunctival vessels in the presence of proinflammatory cytokines may be facilitated by capillary endothelial fenestrations.²³ The mechanism of transvascular ICG leakage from unfenestrated CoNV may be explained by ultrastructural changes during corneal angiogenesis. It is known, that new corneal vessels form from existing limbal blood vessels.¹⁵ Endothelial sprouting by individual endothelial tip cells is preceded by a decrease in cell junction integrity and degradation of the endothelial lamina by matrix metalloproteinases.^{24,25} Thus, intercellular gaps during tube formation may serve as possible exit points of plasma proteins, intravenous dyes, and even erythrocytes, in agreement with previously described localized corneal stromal bleeding in areas of actively progressing CoNV.¹³ ICG leakage was observed to a maximum age of CoNV of 28 weeks. This is in line with histologic findings reporting at least partial pericyte coverage of more than 80% of all vessels after 3 months.²¹

In this study, we performed ICGA imaging for 10 minutes after injection. Any occurrence of leakage at a later time may therefore have been missed. The quality of ICG angiograms, however, gradually decreases over time, which in our experience limits the feasibility of ICGA to 10 minutes.

This study is cross-sectional and limited by a heterogeneous study population with varying levels of ocular surface inflammation at the time of study inclusion. Although patients were included irrespective of current topical medication potentially affecting the observed dye leakage behavior, no significantly increased time to fluorescein leakage was observed in steroid users within the groups. Although steroid usage may be a potential confounder not being used in the regressed group, the proportion of steroid use was equal in the active (29%) and inactive groups (31%).

Our study underlines the importance of intravenous

angiographic analysis of CoNV despite the increasing use of noninvasive optical coherence-based angiography (OCTA). Ang and co-worker²⁶ found OCTA comparable to ICGA for assessment of the area of CoNV. In a comparative analysis by our group, OCTA provided lower-quality images and was less precise in capturing small vessels of neovascular trees compared with ICGA.²⁷ Current OCTA systems do not provide information on the afferent or efferent quality of CoNV, perfusion velocity, and leakage behavior or maturity of corneal vessels, as does FA/ICGA.¹⁶ Despite its current limitations in image quality OCTA is a feasible tool to assess quantitative information on CoNV. It cannot, however, currently replace intravenous angiography for qualitative assessment of CoNV. In the future, a more thorough understanding of changes of vessel architecture, arborization patterns and the capillary bed of CoNV over time may potentially allow deductions on vessel maturity from OCTA angiograms.

The results of this study connect biomicroscopic clinical assessment of CoNV with functional angiographic properties of CoNV. Intravenous dye leakage may be associated with incomplete pericyte coverage of CoNV as a promising predictor of the CoNV treatment response to anti-VEGF agents and serve as a clinically useful guide to the most appropriate therapeutic approach in the preconditioning treatment of CoNV, specifically between surgical (e.g., fine needle diathermy)¹¹ and medical options.²⁸

In conclusion, we found simplification of the staging of CoNV to active, inactive, and regressed to be clinically feasible and to be significantly associated with the time to extravascular leakage of fluorescein and indocyanine. Although a longitudinal study is needed, these features as features of vessel maturity may be useful to guide the selection of appropriate treatments of CoNV.

Acknowledgments

Disclosure: **C. Palme**, None; **V. Romano**, None; **M. Brunner**, None; **R. Vinciguerra**, None; **S.B. Kaye**, None; **B. Steger**, None

References

1. Gain P, Jullienne R, He Z, et al. Global survey of corneal transplantation and eye banking. *JAMA Ophthalmol.* 2016;134:167–173.

2. Steger B, Curnow E, Cheeseman R, et al. Sequential bilateral corneal transplantation and graft survival. *Am J Ophthalmol*. 2016;170:50–57.
3. Bachmann B, Taylor RS, Cursiefen C. Corneal neovascularization as a risk factor for graft failure and rejection after keratoplasty: an evidence-based meta-analysis. *Ophthalmology*. 2010;117:1300–1305.e7.
4. Hopkinson CL, Romano V, Kaye R, et al. The influence of donor and recipient gender incompatibility on corneal transplant rejection and failure. *Am J Transplant*. 2017;17:210–217.
5. Steger B, Curnow E, Cheeseman R, et al. Sequential bilateral corneal transplantation and graft survival. *Am J Ophthalmol*. 2016;170:50–57.
6. Cursiefen C, Colin J, Dana R, et al. Consensus statement on indications for anti-angiogenic therapy in the management of corneal diseases associated with neovascularisation: outcome of an expert roundtable. *Br J Ophthalmol*. 2012;96:3–9.
7. Spiteri N, Romano V, Brunner M, et al. The management of corneal neovascularisation – update on new clinical data and recommendations of treatment. *Eur Ophthalmic Rev*. 2016;10:86–93.
8. Trikha S, Parikh S, Osmond C, et al. Long-term outcomes of Fine Needle Diathermy for established corneal neovascularisation. *Br J Ophthalmol*. 2014;98:454–458.
9. Faraj LA, Elalfy MS, Said DG, et al. Fine needle diathermy occlusion of corneal vessels. *Br J Ophthalmol*. 2014;98:1287–1290.
10. Romano V, Spiteri N, Kaye SB. Angiographic-guided treatment of corneal neovascularization. *JAMA Ophthalmol*. 2015;133:e143544.
11. Romano V, Steger B, Brunner M, et al. Method for angiographically guided fine-needle diathermy in the treatment of corneal neovascularization. *Cornea*. 2016;35:1029–1032.
12. Asena L, Akova YA, Cetinkaya A, et al. The effect of topical bevacizumab as an adjunctive therapy for corneal neovascularization. *Acta Ophthalmol (Copenh)*. 2013;91:e246–248.
13. Faraj LA, Said DG, Al-Aqaba M, et al. Clinical evaluation and characterisation of corneal vascularisation. *Br J Ophthalmol*. 2016;100:315–322.
14. Dastjerdi MH, Al-Arfaj KM, Nallasamy N, et al. Topical bevacizumab in the treatment of corneal neovascularization: results of a prospective, open-label, noncomparative study. *Arch Ophthalmol*. 2009;127:381–9.
15. Cursiefen C, Kuchle M, Naumann GO. Angiogenesis in corneal diseases: histopathologic evaluation of 254 human corneal buttons with neovascularization. *Cornea*. 1998;17:611–613.
16. Anijet DR, Zheng Y, Tey A, et al. Imaging and evaluation of corneal vascularization using fluorescein and indocyanine green angiography. *Invest Ophthalmol Vis Sci*. 2012;53:650–658.
17. Romano V, Steger B, Zheng Y, et al. Angiographic and in vivo confocal microscopic characterization of human corneal blood and presumed lymphatic neovascularization: a pilot study. *Cornea* 2015;34:1459–1465.
18. Steger B, Romano V, Kaye SB. Corneal indocyanine green angiography to guide medical and surgical management of corneal neovascularization. *Cornea*. 2016;5:41–45.
19. Kirwan RP, Zheng Y, Tey A, et al. Quantifying changes in corneal neovascularization using fluorescein and indocyanine green angiography. *Am J Ophthalmol*. 2012;154:850–858.e2.
20. Lange C, Feltgen N, Junker B, et al. Resolving the clinical acuity categories “hand motion” and “counting fingers” using the Freiburg Visual Acuity Test (FrACT). *Graefes Arch Clin Exp Ophthalmol*. 2009;247:137–142.
21. Cursiefen C, Hofmann-Rummelt C, Kuchle M, et al. Pericyte recruitment in human corneal angiogenesis: an ultrastructural study with clinicopathological correlation. *Br J Ophthalmol*. 2003;87:101–106.
22. Steger B, Romano V, Kaye SB. Angiographic evaluation of inflammation in atopic keratoconjunctivitis. *Ocul Immunol Inflamm*. 2018;26:685–688.
23. Iwamoto T, Smelser GK. Electron microscope studies on the mast cells and blood and lymphatic capillaries of the human corneal limbus. *Invest Ophthalmol Vis Sci*. 1965;4:815–834.
24. Samolov B, Steen B, Seregard S, et al. Delayed inflammation-associated corneal neovascularization in MMP-2-deficient mice. *Exp Eye Res*. 2005;80:159–166.
25. Gerhardt H. VEGF and Endothelial Guidance in Angiogenic Sprouting. Austin, TX: Landes Bioscience; 2013.
26. Ang M, Cai Y, MacPhee B, et al. Optical coherence tomography angiography and indocyanine green angiography for corneal vascularisation. *Br J Ophthalmol*. 2016;100:1557–1563.
27. Brunner M, Romano V, Steger B, et al. Imaging of corneal neovascularization: optical coherence tomography angiography and fluorescence angiography. *Invest Ophthalmol Vis Sci*. 2018;59:1263–1269.
28. Liu S, Romano V, Steger B, et al. Gene-based antiangiogenic applications for corneal neovascularization. *Surv Ophthalmol*. 2018;63:193–213.