

Brachymetatarsia of the fourth metatarsal, lengthening scarf osteotomy with bone graft

Ankit Desai, Surjit Lidder,
Andrew R. Armitage,
Samuel S. Rajaratnam,
Andrew D. Skyrme

Department of Trauma and Orthopaedics,
Eastbourne District General Hospital,
East Sussex, UK

Abstract

A 16-year-old girl presented with left fourth metatarsal shortening causing significant psychological distress. She underwent lengthening scarf osteotomy held with an Omnitech® screw (Biotech International, France) with the addition of two 1 cm cancellous cubes (RTI Biologics, United States). A lengthening z-plasty of the extensor tendons and skin were also performed. At 6 weeks the patient was fully weight bearing and at one-year follow up, the patient was satisfied and discharged. A modified technique of lengthening scarf osteotomy is described for congenital brachymetatarsia. This technique allows one stage lengthening through a single incision with graft incorporation by 6 weeks.

Introduction

Brachymetatarsia is a congenital shortening of the metatarsal of the foot. It can be either uni or bilateral,¹ and is most commonly associated with the 4th toe but can affect any of the metatarsal bones.² Patients may present due to metatarsalgia, soft tissue contractures,² or psychological distress during adolescence. Operative intervention can improve function as well as cosmesis. Lengthening may be achieved through callotaxis using a mini-external fixator or through a single stage procedure utilising an osteotomy, bone grafting and soft tissue correction.^{2,3} This case illustrates the use of a lengthening scarf osteotomy augmented with cancellous bone graft cubes and soft tissue correction to treat brachymetatarsia. This modified technique provides improved metatarsal length and cosmetic benefit with a single operative procedure.

Case Report

A 16-year-old female was referred with unilateral shortening of the left 4th toe. The toe

was not painful, however caused psychological distress when wearing opened toed footwear and whilst barefoot at swimming pools. Examination revealed a left 4th toe that was clearly short and sitting dorsally. Radiographs (Figure 1) showed a 4th metatarsal which was approximately 7 mm shorter than the 5th metatarsal with a dysplastic metatarsal head. The etiology of her deformity was unknown.

A single stage lengthening metatarsal scarf osteotomy was performed. The rationale for a single procedure was to limit disruption from schooling. The 4th metatarsal was approached through a laterally based Z-plasty incision. A wide capsular release was performed and the metatarsal was elevated up and a lengthening scarf osteotomy performed. Two 1cm allograft cancellous cubes (RTI Biologics, United States) were used and the osteotomy held with one Omnitech® screw (Biotech International, France) (Figure 2). Z lengthening of the short and long extensor tendons was performed.

Post operatively, the patient remained heel-weight bearing for 6 weeks. The patient had routine post-operative follow up (Figure 3) and the additional length of 9 mm (2 mm longer than 5th metatarsal) had been maintained, however, there was some scar contracture keeping the toe dorsally elevated by ten degrees. The patient remained satisfied with her overall increase in length of the 4th toe and was discharged at one year.

Discussion

The forefoot deformity known as brachymetatarsia is a malformation of any of the metatarsals. It most often affects the 4th toe and may be either uni or bilateral.⁴ The incidence of this rare deformity is reported between 0.02 to 0.05% and is up to twenty five times more prevalent in women compared to men.² Although the main proportion of congenital brachymetatarsia is idiopathic in nature it can also be associated with endocrinopathies, such as pseudo-hypoparathyroidism, as well as systemic syndromes such as Turner's syndrome.^{4,5} The underlying cause of this shortened metatarsal is thought to be due to the premature closure of the metatarsal epiphyseal growth plate, however, the aetiology behind this is not fully understood.^{2,5} There are a number of other acquired causes for the development of shortened metatarsals. Principally trauma and infection, however tumours, radiation exposure and previous surgery are also associated.⁵ Morton's foot, a short first metatarsal, is another less common form of brachymetatarsia that becomes obvious by the age of 10 years old.

Patients with brachymetatarsia may present in a number of ways. The short toe may sit dor-

Correspondence: Surjit Lidder, Department of Trauma and Orthopaedics, Eastbourne District General Hospital, Kings Drive, Eastbourne, East Sussex BN21 2UD, UK.
Tel. +44.1323.418241 - Fax: +44.1323.414963.
E-mail: surjitlidder@me.com

Key words: omnitech, scarf osteotomy, lengthening.

Acknowledgements: we would like to thank Dr. S. Molki for illustrations.

Contributions: the authors contributed equally.

Conflict of interests: the authors declare no potential conflict of interests.

Received for publication: 28 January 2013.

Revision received: 28 May 2013.

Accepted for publication: 17 June 2013.

This work is licensed under a Creative Commons Attribution NonCommercial 3.0 License (CC BY-NC 3.0).

©Copyright A. Desai et al., 2013
Licensee PAGEPress, Italy
Orthopedic Reviews 2013; 5:e21
doi:10.4081/or.2013.e21

sally which affects cosmesis and impairs load transference of the foot.^{1,6} This can lead to metatarsalgia and callosities particularly over the second and third metatarsal heads.^{2,6} With soft tissue imbalance, clawing of the toe may be problematic for shoe wearing.⁴

The aim of surgery in these cases is to provide symptomatic relief and cosmesis. The two main methods of surgical correction are of distraction osteotomy providing a gradual increase in length, and the single stage osteotomy with bone graft to produce a rapid lengthening (Table 1).

Our case presents a modified surgical technique using a scarf osteotomy with a fixating Omnitech® screw, alongside a tendon Z-plasty of the short and long extensor tendons to produce desirable results. By using a scarf osteotomy rather than a transverse, we allow for controlled elongation of the metatarsal with secured fixation. This decreases the chance of metatarsal shortening post operatively, which can be seen with the transverse osteotomy. It also removes the need for a holding Kirschner wire which is often inserted and removed at a later date once the transverse osteotomy has begun to heal. The cancellous bone blocks were held in place by compression press fit. When the scarf osteotomy is performed, distraction at the site causes surround soft tissue compression and maintains a press fit for the bone blocks.

The management of brachymetatarsia can be complicated and it is particularly important to

Table 1. The two most common methods used for the management of brachymetatarsia.

Method	Surgical technique	Advantages	Disadvantages	References
Distraction osteogenesis with mini-external fixation	Application of mini-external fixator after a transverse osteotomy. Up to 12 days of gradual increasing of length	Longer lengthening possible	Significant scarring, skin tension from four fixator pin sites, patient co-operation, pin site infections, requires second procedure to remove distraction device	Takakura <i>et al.</i> , 1997, (7 patients, Follow up 4.4 years) Magnan <i>et al.</i> , 1995 (7 patients, mean follow up 6.5 years)
Single stage with allograft bone graft	Tendon Z-Plasty Transverse osteotomy with bone block between held in place by k-wire	Single main procedure, tendon z-plasty, smaller scar	K-wire requires removing, limited lengthening due to soft tissue tension, post-procedure reduction in lengthening, autologous donor site morbidity	Giannini <i>et al.</i> , 2010 (29 patients, mean follow up 5 years)

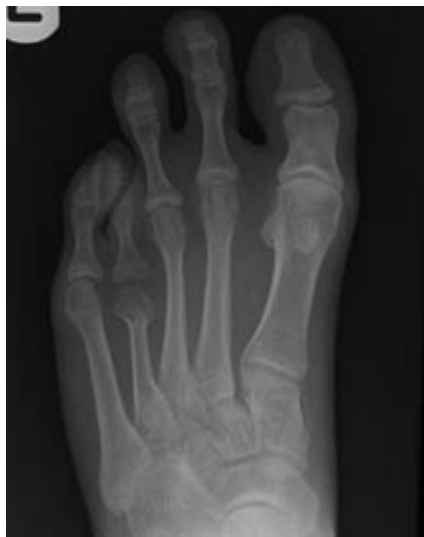

Figure 1. AP radiograph of the left foot showing 7 mm shortening of the 4th metatarsal compared to the 5th metatarsal head.

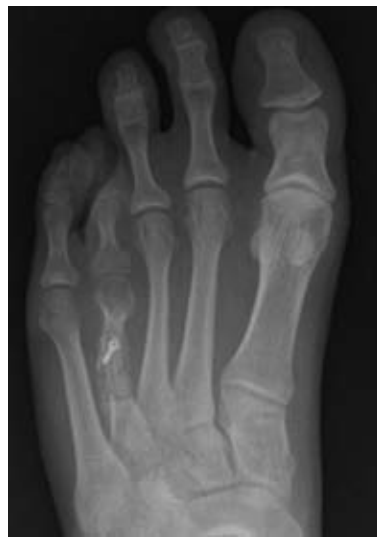

Figure 3. Post-operative AP radiograph at 6 weeks of the left foot showing the lengthening scarf osteotomy, incorporation of the bone blocks and fixation with an Omnitech[®] screw of the 4th metatarsal. The 4th metatarsal head is 2 mm longer than the 5th metatarsal head.

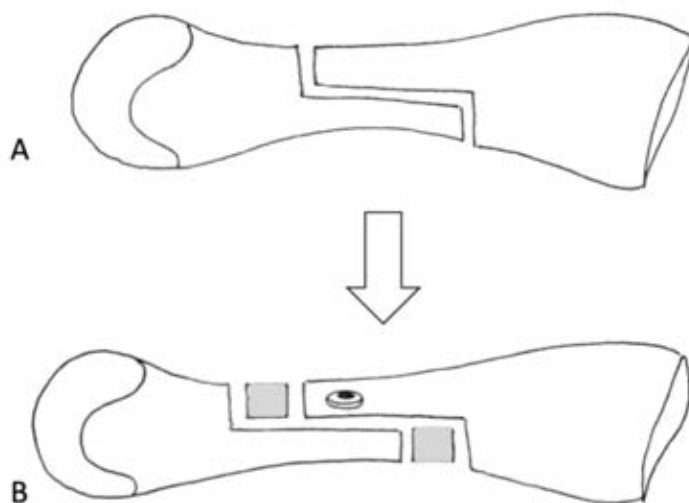


Figure 2. Diagram showing lengthening scarf osteotomy of the metatarsal (A) with bone grafts and Omnitech[®] screw fixation (B).

consider that young women, the main patient group, desire a cosmetic improvement due to the already high levels of psychological distress. This was true in our case where it was felt that a single-stage operation would be the most appropriate method and would be the least restricting on her daily life. The scarf osteotomy augmented with bone graft cubes should decrease the risk of the patient requiring a second operation and early results have so far shown this. This case indicates the importance of patient selection when considering which operative procedure to undertake and to consider the long-term impact of the operation.

A lengthening scarf osteotomy with screw fixation and the use of cancellous bone blocks is a modified technique for the surgical management of brachymetatarsia that provides a good alternative to traditional techniques.

References

1. Rozburch S, Ilizarov S. Limb lengthening and reconstruction surgery. London: Informa Healthcare; 2006.
2. Giannini S, Faldini C, Pagkrati S, et al. One-stage metatarsal lengthening by allograft interposition: a novel approach for congenital brachymetatarsia. *Clin Orthop Relat Res* 2010;468:1933-42.
3. Guizar-Cuevas S, Mora-Ríos FG, Mejía-Rohenes LC, et al. [Elongation with callosities for congenital brachymetatarsia]. *Acta Ortop Mex* 2010;24:395-9. [Article in Spanish].
4. Magnan B, Bragantini A, Regis D, Bartolozzi P. Metatarsal lengthening by callosities during the growth phase. *J Bone Joint Surg Br* 1995;77:602-7.
5. Scuderi G, Tria A. Minimally invasive surgery in orthopaedics. New York: Springer Publications; 2009.
6. Takakura Y, Tanaka Y, Fujii T, Tamai S. Lengthening of short great toes by callus distraction. *J Bone Joint Surg Br* 1997; 79:955-8.