


CASE REPORTS

Anesthesia for a cesarean section on a pregnant patient with Cockayne syndrome: case report



Viviane Barrada Ribeiro, Leonardo Teixeira Ribeiro Alonso de Faria, Roberta de Lima Machado, Bruno Mendonça Barcellos, Marco Antonio Cardoso de Resende, Rogério Luiz da Rocha Videira *

Universidade Federal Fluminense (UFF), Hospital Universitário Antônio Pedro, Niterói, RJ, Brazil

Received 27 February 2019; accepted 26 October 2019

Available online 12 February 2020

KEYWORDS

Cockayne syndrome;
Difficult airway;
Obstetric anesthesia;
Pregnancy;
Progeria

Abstract Cockayne syndrome is an autosomal recessive multi-systemic disorder due to DNA repair failure. It was originally described in 1936 in children of small stature, retinal atrophy and deafness, characterized by dwarfism, cachexia, photosensitivity, premature aging and neurologic deficits. The most typical feature is described as birdlike facies: protruding maxilla, facial lipoatrophy, sunken eyes, large ears and thin nose. Difficult airway management with subglottic stenosis and risk of gastric content aspiration has been described. Although the clinical characteristics of Cockayne syndrome have been well described in pediatric publications, there is only one report in the literature on anesthesia for an obstetric patient. We report the case of a pregnant patient diagnosed with Cockayne syndrome, submitted successfully to spinal anesthesia for a cesarean section due to cephalopelvic disproportion. In view of the difficult decision between inducing general anesthesia in a patient with a likely difficult airway, or neuraxial anesthesia in a patient with cardiovascular, respiratory and neurocognitive limitations, we suggest tailored management to reach the best results for the mother and newborn.

© 2020 Published by Elsevier Editora Ltda. on behalf of Sociedade Brasileira de Anestesiologia. This is an open access article under the CC BY-NC-ND license (<http://creativecommons.org/licenses/by-nc-nd/4.0/>).

PALAVRAS-CHAVE

Síndrome de
Cockayne;
Via aérea difícil;
Anestesia obstétrica;
Gravidez;
Progeria

Anestesia para cesárea em gestante com síndrome de Cockayne: relato de caso

Resumo A síndrome de Cockayne é doença multissistêmica autossômica recessiva devido à falha no reparo do DNA. Originalmente descrita em 1936 em crianças de baixa estatura, atrofia retiniana e surdez, é caracterizada por nanismo, caquexia, fotossensibilidade, envelhecimento acelerado e déficits neurológicos. O mais típico é a fácies, descrita como similar à de um pássaro: maxila proeminente, atrofia do coxim adiposo bucal, olhos profundos, orelhas grandes e nariz

* Corresponding author.

E-mail: videirarogério@id.uff.br (R.L. Videira).

fino. Tem sido descrita dificuldade no manejo da via aérea com estreitamento subglótico e risco de aspiração gástrica. Embora as características clínicas da síndrome de Cockayne sejam bem relatadas em publicações pediátricas, há apenas um relato de anestesia em paciente obstétrica na literatura. Relatamos o caso de gestante com diagnóstico de síndrome de Cockayne, submetida com sucesso a raquianestesia para parto cesariano por desproporção cefalopélvica. Diante da difícil decisão entre induzir anestesia geral em paciente com provável via aérea difícil ou anestesia neuroaxial, em meio a limitações cardiovasculares, respiratórias e neurocognitivas da paciente, conduta individualizada é sugerida para alcançar os melhores resultados para a gestante e o neonato.

© 2020 Publicado por Elsevier Editora Ltda. em nome da Sociedade Brasileira de Anestesiologia. Este é um artigo Open Access sob a licença de CC BY-NC-ND (<http://creativecommons.org/licenses/by-nc-nd/4.0/>).

Background

Cockayne syndrome (CS) is an autosomal recessive multi-systemic disorder associated with a DNA repair defect. Originally described in 1936 in children presenting small stature, retinal atrophy and deafness, CS is characterized by dwarfism, cachexia, photosensitivity, premature aging and neurologic deficits.¹ Some features, such as microcephaly, gradual development of cerebellar ataxia, choreoathetosis, and intellectual deficit can be associated with sensorineural hearing impairment and blindness, and with intracranial calcification of the basal ganglia. The typical feature is the birdlike facies: protruding maxilla, facial lipoatrophy, sunken eyes, large ears and thin nose. Additionally, possible difficult airway management is described with subglottic stenosis and risk of gastric content aspiration.² The estimated incidence is 2.7 per 1,000,000 births in the Western Europe population.³

Although the clinical features of CS have been described in publications in pediatric literature, there is only one case report published describing the anesthetic care of an obstetric patient.² We report the anesthetic management of a pregnant patient diagnosed with CS since infancy, and submitted to spinal anesthesia for a C-section due to cephalopelvic disproportion.

Case report

The case was a 26 year old, 39 kg, 150 cm height nullipara patient with a diagnosis of Cockayne Syndrome (CS) admitted in labor at the gestational age of 39 weeks. An emergency C-section was indicated due to cephalopelvic disproportion (Fig. 1). Diagnosis of CS was confirmed by genetic tests, in addition to a fibroblast culture test that measures decreased RNA synthesis response after UV-radiation exposure. The physical examination showed distinctive CS features: short stature, cachexia, mildly retracted chin with birdlike facies, difficult interaction due to intellectual deficit, and hearing aid due to hearing loss (Fig. 2). Airway assessment revealed small mouth opening, protuberant teeth and Mallampati score Class IV (Fig. 3). At the operation theater, an 18 G venous cannula was instated, and continuous ECG (DII and V5), non-invasive blood pressure, and



Fig. 1 39 week pregnant patient with Cockayne syndrome. Manifest short stature and cachexia.

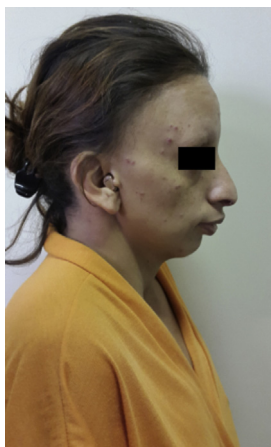

Fig. 2 Bird-like facies. Probable challenging airway management.

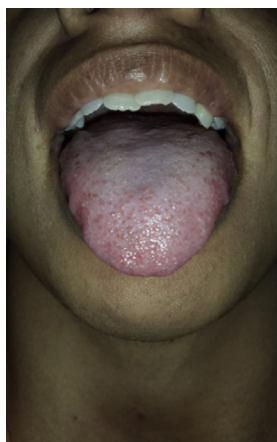


Fig. 3 Mallampati Class IV score airway assessment.

oximetry (SpO₂) monitoring was employed. Pre-induction vital signs were arterial blood pressure of 140/80 mmHg, heart rate of 110 bpm with sinus heart rhythm, and SpO₂ of 98% at room air. The patient was positioned in left lateral decubitus, and after skin preparation and under sterile conditions, a L3–L4 spinal paramedian anesthesia with a 25 G Quincke needle and intrathecal injection of 8 mg of 0.5% hyperbaric bupivacaine and 40 µg of morphine was performed. After 10 minutes, T4 analgesia level was observed by the pin prick test associated with satisfactory motor blockage, allowing the surgical incision. Six minutes later, a 3,475 g baby boy was delivered with a 9/9 Apgar score. During the 65 minute procedure the patient received 10 mg of ephedrine IV, 1 L of Ringer Lactate solution and an IV infusion of 10 U of oxytocin during the 30 minutes following birth. The mother was sent from the post anesthesia recovery room to the floor after 60 minutes with complete motor blockage recovery. There was no maternal complication in the post-partum period. The morphine dose administered proved to be safe and satisfactory. Due to the patient's intellectual deficit, her brother signed the consent form for the publication of the case report and to use patient images.

Discussion

This case report describes an uncommon anesthetic management of an obstetric patient presenting a rare syndrome, low life expectancy and low fertility rate. CS is associated with mutations of two genes: "CS-A", or Excision-Repairation Cross-Complementation Group 8 (ERCC8), "CS-B", or Excision-Repairation Cross-Complementation Group 6 (ERCC6), located at chromosomes 5q12 and 10q11, respectively. Both genes encode proteins that interact with components of the transcription mechanism and proteins that perform excision and repair of abnormal nucleosides detected in the DNA when transcription to RNA is interrupted. The majority of cases (80%) are associated with mutations in the CS-B gene.⁴

The wide phenotypic spectrum of signs and symptoms expressed by CS patients is the basis for the following classification: CS Type I (Moderate) is considered as the classic syndrome type, with signs of psychomotor development delay from the second year of age. CS Type II (Severe) shows early onset and clinical signs developing a few months after birth. Patients have fast progressing abnormalities, and the prognosis is very poor, leading to premature death.⁴ On the other hand, CS Type III (Mild or Atypical) is diagnosed later in childhood and patients present mild clinical characteristics, normal intellectual development, growth and reproductive function. No correlation has been shown between genotype and phenotype in CS. No specific treatment has been proposed for CS, only symptomatic treatment is available, and few CS patients reach adulthood.³

CS female patients present underdeveloped secondary sexual characteristics, although some may present menarche with irregular menstrual cycles. It is unclear if the infertility associated with CS only has an endocrinal basis or is also due to the cognitive and neurologic dysfunction caused by the syndrome.² Digestive changes, such as gastro esophageal reflux, vomiting and choking contribute to the anorexia often observed in CS cachectic patients.³ Clinical findings of CS are accompanied by co-morbidities and limitations to pregnancy. At the preoperative assessment of CS patients some clinical conditions related to early aging, such as high blood pressure, renal and hepatic dysfunction, progressive cataract, diabetes mellitus and myocardial ischemia can be found.^{4,5}

Regarding anesthetic management, a small mouth associated with normally developed, and therefore disproportionately large teeth are predictors of difficult airway. The birdlikefacies is characterized by the loss of the oral adipose pad, enophthalmos, thin nose, in addition to microcephaly. Some patients also present small mouth opening due to temporomandibular joint dysfunction and some may present subglottic stenosis.¹ CS patients frequently require general anesthesia for management of their associated disorders, and their facial features can make tracheal intubation challenging.

Despite readily available devices (masks, bougie, Magill's forceps, video laryngoscope and smaller diameter tracheal tubes with stylets) for a possible difficult ventilation or tracheal intubation, neuraxial blockade was chosen, as the patient's back anatomy presented no abnormalities, such as scoliosis which is commonly observed in some phenotypes.

In face of this clinical scenario, spinal anesthesia was beneficial for our patient. Facing the dilemma of either inducing general anesthesia in the presence of a probable challenging airway management, or performing a neuraxial blockade in a patient with possible hemodynamic, respiratory and neurocognitive limitations, we suggest that the decision of a tailored anesthesia technique should be made targeting the best results, and to enable early interaction between mother and newborn.

Conflicts of interest

The authors declare no conflicts of interest.

References

1. Pasquier L, Laugel V, Lazaro L, et al. Wide clinical variability among 13 new Cockayne syndrome cases confirmed by biochemical assays. *Arch Dis Child*. 2006;91:178–82.
2. Rawlinson SC, Webster VJ. Spinal anaesthesia for caesarean section in a patient with Cockayne syndrome. *Int J Obstet Anesth*. 2003;12:297–9.
3. Natale V. A Comprehensive Description of the Severity Groups in Cockayne Syndrome. *Am J Med Genet Part A*. 2011;155:1081–95.
4. Gaddam D, Thakur MS, Krothapalli N, et al. Case report dental management of a 14-year-old with Cockayne syndrome under general anesthesia. *Case Rep Dent*. 2014;2014:1–3.
5. Wilson BT, Stark Z, Sutton RE, et al. The Cockayne Syndrome Natural History (CoSyNH) study: clinical findings in 102 individuals and recommendations for care. *Genet Med*. 2016;18:483–93.