

HOSTED BY



Contents lists available at ScienceDirect

Saudi Pharmaceutical Journal

journal homepage: [www.sciencedirect.com](http://www.sciencedirect.com)

Original article

# The ameliorative effect of *Primula vulgaris* on cisplatin-induced nephrotoxicity in rats and quantification of its phenolic components using LC-ESI-MS/MS



Ibrahim Turan<sup>a,\*</sup>, Deniz Canbolat<sup>b</sup>, Selim Demir<sup>c</sup>, Gokcen Kerimoglu<sup>d</sup>, Fatih Colak<sup>e</sup>, Nihal Turkmen Alemdar<sup>f</sup>, Ahmet Mentese<sup>g</sup>, Yüksel Aliyazicioglu<sup>g</sup>

<sup>a</sup> Department of Biochemistry, Faculty of Pharmacy, University of Health Sciences, 06010, Ankara, Turkey

<sup>b</sup> Medicinal Aromatic Plants Application and Research Center, Artvin Coruh University, 08000, Artvin, Turkey

<sup>c</sup> Department of Nutrition and Dietetics, Faculty of Health Sciences, Karadeniz Technical University, 61080, Trabzon, Turkey

<sup>d</sup> Department of Histology and Embryology, Faculty of Medicine, Karadeniz Technical University, 61080, Trabzon, Turkey

<sup>e</sup> Department of Urology, Faculty of Medicine, Karadeniz Technical University, 61080, Trabzon, Turkey

<sup>f</sup> Department of Medical Services and Techniques, Vocational School of Health Services, Recep Tayyip Erdogan University, 53100, Rize, Turkey

<sup>g</sup> Department of Medical Biochemistry, Faculty of Medicine, Karadeniz Technical University, 61080, Trabzon, Turkey

## ARTICLE INFO

### Article history:

Received 3 July 2023

Accepted 28 July 2023

Available online 3 August 2023

### Keywords:

Apoptosis

Cisplatin

Nephrotoxicity

LC-MS-MS

*Primula vulgaris*

## ABSTRACT

Cisplatin (CDDP) is an important chemotherapeutic agent, accumulation of which in kidney tissue causes nephrotoxicity and renal failure. The aim of this study was to evaluate, for the first time in the literature, the protective effect of dimethyl sulfoxide (DMSO) extract of *Primula vulgaris* leaf (PVE) against CDDP-induced nephrotoxicity in rats.

The PVE content was characterized using liquid chromatography-mass spectrometry. Nephrotoxicity was induced with a single dose of CDDP (7.5 mg/kg). Thirty female Wistar-Albino rats were divided into five groups (control, DMSO, CDDP (7.5 mg/kg), CDDP + PVE (25 mg/kg), and CDDP + PVE (50 mg/kg)). Biochemical and histopathological analyses were then performed.

Rutin, gallic acid, *p*-coumaric acid and protocatechuic acid were identified as major components of PVE. Total antioxidant status and glutathione (GSH) values increased significantly in the serum samples from the treatment group compared to the CDDP group, while blood urea nitrogen, creatinine, oxidative stress index, malondialdehyde (MDA), tumor necrosis factor- $\alpha$  (TNF- $\alpha$ ), total oxidant status, and 8-hydroxy-2'-deoxyguanosine (8-OHdG) values decreased significantly. GSH levels increased significantly in the treatment group compared to the CDDP group, while TNF- $\alpha$ , caspase-3, 8-OHdG, MDA levels and damage scores decreased significantly.

In conclusion, PVE exhibited strong protective effects through its anti-apoptotic, antioxidant, and anti-inflammatory activities against nephrotoxicity and oxidative damage caused by CDDP in rats.

© 2023 The Author(s). Published by Elsevier B.V. on behalf of King Saud University. This is an open access article under the CC BY-NC-ND license (<http://creativecommons.org/licenses/by-nc-nd/4.0/>).

\* Corresponding author at: Department of Biochemistry, Faculty of Pharmacy, University of Health Sciences, 06010, Ankara, Turkey.

E-mail addresses: [ibrahim.turan@sbu.edu.tr](mailto:ibrahim.turan@sbu.edu.tr) (I. Turan), [denizcanbolat@artvin.edu.tr](mailto:denizcanbolat@artvin.edu.tr) (D. Canbolat), [selim.demir@ktu.edu.tr](mailto:selim.demir@ktu.edu.tr) (S. Demir), [gkerimoglu@ktu.edu.tr](mailto:gkerimoglu@ktu.edu.tr) (G. Kerimoglu), [fatihcolak@ktu.edu.tr](mailto:fatihcolak@ktu.edu.tr) (F. Colak), [nihal.turkmen@erdogan.edu.tr](mailto:nihal.turkmen@erdogan.edu.tr) (N. Turkmen Alemdar), [amentese28@ktu.edu.tr](mailto:amentese28@ktu.edu.tr) (A. Mentese), [yayazici@ktu.edu.tr](mailto:yayazici@ktu.edu.tr) (Y. Aliyazicioglu).

Peer review under responsibility of King Saud University.



Production and hosting by Elsevier

## 1. Introduction

Cancer is excessive cell proliferation caused by reduced apoptosis and/or loss of cell cycle control mechanisms (Turan et al., 2018). The treatment of most cancers usually involves the use of chemotherapy and radiotherapy (Demir et al., 2018). Although cisplatin (CDDP) is an important pharmaceutical agent used in the treatment of solid tumors, side-effects such as nephrotoxicity limit its use (Sayed, 2009; Kandhare et al., 2017). The mechanisms involved in the nephrotoxicity caused by CDDP are complex and include several processes, such as CDDP-induced epithelial cell death, mitochondrial dysfunction, DNA damage, apoptosis, inflammation, and oxidative stress. Consequences of impaired kidney

<https://doi.org/10.1016/j.jsps.2023.101730>

1319-0164/© 2023 The Author(s). Published by Elsevier B.V. on behalf of King Saud University.

This is an open access article under the CC BY-NC-ND license (<http://creativecommons.org/licenses/by-nc-nd/4.0/>).

function in a decrease in glomerular filtration rate, hypokalemia, decreased renal blood flow, increased blood creatinine levels and hypomagnesemia (Elsherbiny et al., 2016; Miller et al., 2010). More than 8000 polyphenols and polyphenol-derived compounds exhibiting antioxidant activity have been identified in plants (Chang et al., 2023). Natural products containing these are therefore used as potential agents for the treatment and prevention of conditions such as aging, cardiovascular diseases, diabetes, and cancer (Li et al., 2014). The use of herbal medicines has recently increased due to their protective effects against organ toxicities (Dogan et al., 2022). *Primula vulgaris* belongs to the Primulaceae family, which contains more than 400 species (Demir et al., 2019). *Primula* species are rich in saponins, tannins, alkaloids, terpenes, and phenolic compounds, and their antigenotoxic, wound-healing, anti-inflammatory and antiproliferative properties have been described in various studies (Demir et al., 2018, 2019; Turan et al., 2017, 2018). Our study investigated the *in vivo* protective effect of *P. vulgaris* leaf extract (PVE), with its powerful antioxidant properties, against damage such as apoptosis, DNA injury, increased inflammation, oxidative stress, and nephrotoxicity caused by CDDP.

## 2. Materials and methods

### 2.1. Chemicals

Cis-diamminedichloroplatinum (II) (CDDP), H<sub>3</sub>PO<sub>4</sub>, thiobarbituric acid (TBA), acetic acid, dimethyl sulfoxide (DMSO, 99.5%), 1,1,3,3-tetramethoxypropane, HCl, and H<sub>2</sub>SO<sub>4</sub> were purchased from Sigma (St. Louis, MO, USA). Pierce BCA protein assay kits were obtained from Thermo Scientific (Waltham, MA, USA), glutathione (GSH), caspase3- (CASP3), 8-hydroxy 2' deoxyguanosine (8-OHdG), and tumor necrosis factor alpha (TNF- $\alpha$ ) enzyme-linked immunosorbent assay (ELISA) kits from USCN (Wuhan, China), and total oxidant status (TOC) and total antioxidant status (TAC) analysis kits from Rel Assay (Gaziantep, Türkiye).

### 2.2. Extract preparation

*P. vulgaris* leaves collected from Trabzon province in Türkiye were dried at room temperature and converted into powder (IKA, Staufen, Germany). Next, 0.5 g of powder was mixed with 10 mL of DMSO and left to incubate for 24 h at 45 °C with continuous shaking (Shell Lab, Cornelius, USA) at 150 rpm. The resulting supernatant was then lyophilized (Xianou-12 N, China). In the experimental stages, the extracts were dissolved with DMSO (Demir et al., 2018).

### 2.3. Identification and quantitation of phenolic compounds

Liquid chromatography – triple quadrupole mass spectrometry (LC-MS/MS) analyses were conducted using a Dionex Ultimate 3000 model Thermo Scientific UHPLC coupled to a tandem MS (TSQ Quantum Access Max) instrument. A liquid chromatography device consisting of an autosampler, column chamber, dual pump, and degasser was used. A C18 reversed-phase Inertsil ODS Hypersil (250 mm  $\times$  4.6 mm, 5  $\mu$ m) analytical column used for chromatographic separation, the temperature being fixed at 30 °C. The elution gradient consisted of mobile phase A (water with 0.1% formic acid) and mobile phase B (methanol). The program was fixed as follows: 0–1 min, 0% B; 1–22 min, 95% B; 22–25 min, 95% B; 25–30 min, 100% B. The total evaluation time was set to 34 min with conditioning time. The solvent flow rate and injection volume were adjusted to 0.7 mL/min and 20  $\mu$ L, respectively. The mobile phase employed for this study was selected after a combi-

**Table 1**  
Results of phytochemical characterization of PVE with LC-MS/MS.

Analyte	$\mu$ g/g sample
Pyrogallol	ND
Gallic acid	60.58
Protocatechuic acid	28.42
Protocatechuic aldehyde	0.64
Sesamol	ND
Catechin	ND
Gentisic_acid	ND
Epicatechin	ND
Caffeic acid	ND
Vanillin	2.44
Syringic acid	ND
Syringaldehyde	ND
Taxifolin	14.56
p Coumaric acid	23.36
Sinapic_acid	ND
Salicylic acid	ND
Ferulic acid	ND
4-Hydroxybenzoic acid	0,4
Rosmarinic acid	ND
Oleuropein	ND
Rutin	385.28
Resveratrol	2,06
Ellagic acid	8,28
Cinnamic_acid	ND
Naringenin	ND
Quercetin	14.14
Kaempferol	ND
Galangin	ND
Flavone	20.92

nation of several trials to determine the optimal ionization and separation of the molecules. The compounds listed in Table 1 were analyzed using LC MS/MS (Kayir et al., 2023).

### 2.4. Experimental design

Eight-week-old female Wistar-Albino rats weighing 200–250 g were used in the study (Abdel Moneim et al., 2014). The experiments were conducted with the World Medical Association Declaration of Helsinki and approved by the Karadeniz Technical University animal experiments local ethical committee (protocol no. 2019/64). All rats were housed under optimum conditions (appropriate ventilation system, light cycle 12-h light/12-h dark, relative humidity 50–60% and temperature 23  $\pm$  2 °C) and were given water *ad libitum* and pellet feed (Palipoch et al., 2013).

The rats were divided into five groups and housed in cages with six animals in each group;

Group I, the control group, received 0.5 mL saline solution intraperitoneally (i.p.) for six days.

Group II, the CDDP group, received 0.5 mL CDDP (7.5 mg/kg) on the first day and saline for the following five days.

Group III, the DMSO group, received 0.5 mL DMSO for six days.

Group IV, the PVE-1 group, received CDDP (7.5 mg/kg) on the first day and PVE (25 mg/kg) for five days.

Group V, the PVE-2 group, received CDDP (7.5 mg/kg) on the first day and PVE (50 mg/kg) for five days (Jamshidzadeh et al., 2016; Korkmaz et al., 2017). On the seventh day, blood and kidney tissues were collected from all the experimental group rats under deep anesthesia. After the experimental period, all rats were sacrificed by removing blood from the left ventricle under deep anaesthesia with ketamine (90 mg/kg) + xylazine (10 mg/kg). Animals under deep anesthesia blood samples were taken. Blood samples taken in biochemistry tubes with separator gel were kept at room temperature for 20 min for clotting. After clotting, they were centrifuged at 4000 rpm for 10 min. After centrifugation, the serum

portions were carefully transferred to micro-volume tubes and stored at  $-80^{\circ}\text{C}$  until the study. (Baltaci et al., 2016).

## 2.5. Biochemical analysis

One hundred milligrams of tissue sample was homogenized at 9500 rpm in 2 mL of phosphate buffer (PBS) (pH: 7.4) (IKA, Staufen, Germany). The protein content of the samples was measured using a commercial kit (Thermo Scientific Pierce BCA Protein Assay Kit, Rockford, IL, USA). Malondialdehyde (MDA) levels were determined using the method developed by Uchiyama and Mihara (Uchiyama and Mihara, 1978). Tissue MDA levels were expressed as nmol/mg protein. Tissue TAC and TOC values were determined using colorimetric kits (Rel Assay Diagnostics, Gaziantep, Türkiye) in line with the producer's recommendations. The TOC/TAC ratio was adopted as the oxidative stress index (OSI) using the formula (Demir et al., 2020)

$$\text{OSI (arbitrary unit)} = \frac{\text{TOS } (\mu \text{ mol hydrogen peroxide equivalent/L})}{\text{TAS } (\mu \text{ mol trolox equivalent/L})} \times 100$$

GSH, 8-OHdG, caspase-3, and TNF- $\alpha$  levels were measured using ELISA kits (USCN, Wuhan, China). Creatinine (Crea) and blood urea nitrogen (BUN) values were determined using an autoanalyzer (Beckman Coulter AU5800, Brea, CA, USA).

## 2.6. Histological analysis

Kidney tissues were subjected to routine histological tissue processing. Serial sections 5  $\mu\text{m}$  in thickness were then taken from the paraffin-embedded blocks (Leica RM 2255, Leica Instruments, Nussloch, Germany). The slides were stained with hematoxylin-eosin (H&E), evaluated under a light microscope (Olympus BX -51; Olympus Co., Tokyo, Japan), and photographed (Olympus DP 71 Olympus Co., Japan). Degeneration of the Bowman's space and/or glomeruli, proximal and distal tubule degeneration and/or cast formation, and vascular congestion and/or interstitial edema were determined as three indicative criteria of kidney damage. Each pre-

parate was scored between 0 and 3 (0: no damage, 1: mild damage, 2: moderate damage, 3: severe damage) for each criterion, with total possible scores of 0–9 (Iseri et al., 2007).

## 2.7. Statistical analysis

Normality of distribution of the study data was evaluated using the Kolmogorov-Smirnov test. Non-normally distributed data were first evaluated using Kruskal-Wallis analysis of variance and then with the Mann-Whitney-U test. Data were expressed as median and 25–75% quartiles (interquartile range). p values < 0.05 were considered statistically significant.

## 3. Results

### 3.1. LC-MS/MS findings

The LC-MS/MS analysis results are shown in Table 1. Gallic acid (60.58  $\mu\text{g/g}$  sample), protocatechuic acid (28.42  $\mu\text{g/g}$  sample), protocatechuic aldehyde (0.64  $\mu\text{g/g}$  sample), vanillin (2.44  $\mu\text{g/g}$  sample), taxifolin (14.56  $\mu\text{g/g}$  sample), p coumaric acid (23.36  $\mu\text{g/g}$  sample), 4-Hydroxybenzoic acid (0.020  $\mu\text{g/g}$  sample), rutin (385.28  $\mu\text{g/g}$  sample), resveratrol (2.06  $\mu\text{g/g}$  sample), ellagic acid (8.28  $\mu\text{g/g}$  sample), quercetin (14.14  $\mu\text{g/g}$  sample), and flavone (20.92  $\mu\text{g/g}$  sample) values were determined in the PVE.

### 3.2. Biochemical findings

The biochemical results from the tissue samples are shown in Table 2. MDA (p = 0.047), TOC (p = 0.037), OSI (p = 0.047), caspase-3 (p = 0.01), TNF- $\alpha$  (p = 0.01), and 8-OHdG (p = 0.004) values increased significantly in tissue samples from the CDDP group compared to the control group. Tissue MDA (p = 0.004), caspase-3 (p = 0.016), TNF- $\alpha$  (p = 0.01), and 8-OHdG (p = 0.01) levels were significantly lower in the P. vulgaris groups compared to the CDDP group. Tissue GSH levels (p = 0.025) were significantly lower in the CDDP group compared to the control group. However, significant increases in tissue GSH levels (p = 0.037) were observed in the P.

**Table 2**  
Biochemical parameter results from the tissue samples.

	Control	DMSO	CDDP (7.5 mg/kg)	CDDP (7.5 mg/kg) P. vulgaris (25 mg/kg/day)	CDDP (7.5 mg/kg) P. vulgaris (50 mg/kg/day)
MDA (nmol/mg protein)	17.5 (16.2–19.8)	18.2 (17.3–19.4)	20.4 <sup>a</sup> (19.3–21.7) <sup>a</sup> p = 0.047	17.3 <sup>b</sup> (16.4–18.3) <sup>b</sup> p = 0.019	15.0 <sup>b</sup> (13.8–16.0) <sup>b</sup> p = 0.004
TOC ( $\mu\text{M H}_2\text{O}_2$ equivalent)	14.6 (13.6–16.6)	15.5 (15.1–15.8)	18.6 <sup>a</sup> (16.0–21.5) <sup>a</sup> p = 0.037	16.4 (14.8–18.0)	16.3 (13.7–18.7)
TAC (mM trolox equivalent)	0.80 (0.54–0.93)	0.62 (0.53–0.74)	0.57 (0.51–0.71)	0.64 (0.55–0.86)	0.73 (0.69–0.77)
OSI (arbitrary unit)	2.10 (1.53–2.68)	2.40 (2.13–2.93)	3.50 <sup>a</sup> (2.28–4.00) <sup>a</sup> p = 0.047	2.65 (1.78–3.23)	2.20 (1.85–2.53)
Caspase-3 (ng/mg protein)	0.27 (0.18–0.47)	0.40 (0.32–0.42)	0.53 <sup>a</sup> (0.49–0.62) <sup>a</sup> p = 0.01	0.43 (0.34–0.60)	0.30 <sup>b</sup> (0.22–0.45) <sup>b</sup> p = 0.016
TNF- $\alpha$ (pg/mg protein)	67.1 (32.0–113.6)	84.2 (35.6–103.2)	166.7 <sup>a</sup> (138.9–190.0) <sup>a</sup> p = 0.01	100.5 <sup>b</sup> (49.3–136.6) <sup>b</sup> p = 0.033	64.5 <sup>b</sup> (42.3–115.4) <sup>b</sup> p = 0.01
GSH ( $\mu\text{g/mg}$ protein)	3.53 (3.07–8.82)	4.30 (3.58–5.17)	2.48 <sup>a</sup> (2.12–3.13) <sup>a</sup> p = 0.025	4.67 (1.90–6.56)	4.46 <sup>b</sup> (2.86–5.89) <sup>b</sup> p = 0.037
8-OHdG (pg/mg protein)	69.0 (62.2–73.1)	62.8 (56.5–72.4)	95.9 <sup>a</sup> (87.3–118.2) <sup>a</sup> p = 0.004	74.3 (47.5–97.8)	60.2 <sup>b</sup> (55.8–83.8) <sup>b</sup> p = 0.01

Data were expressed as median and 25%–75% quartiles (interquartile range (IQR)). p < 0.05 was considered statistically significant. <sup>a</sup> Significantly different compared with the negative control group (p < 0.05), <sup>b</sup> Significantly different compared with the CDDP group (p < 0.05).

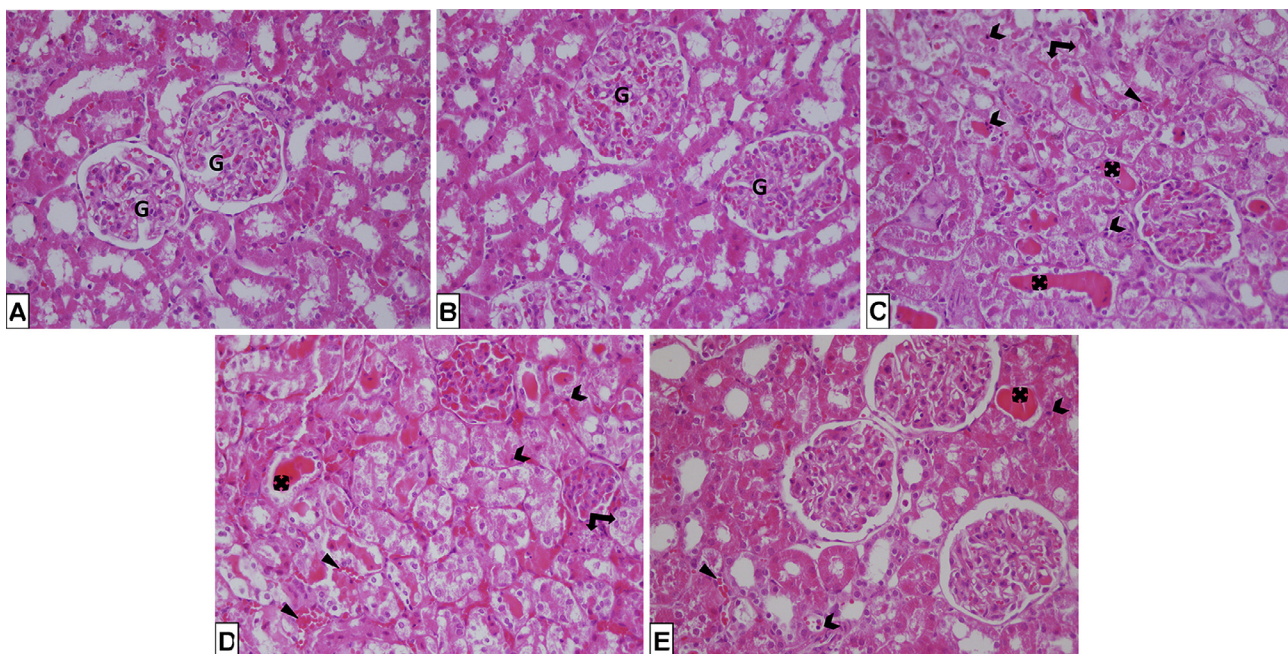
**Table 3**  
Biochemical parameter results from the serum samples.

	Control	DMSO	CDDP (7.5 mg/kg)	CDDP (7.5 mg/kg) <i>P. vulgaris</i> (25 mg/kg/day)	CDDP (7.5 mg/kg) <i>P. vulgaris</i> (50 mg/kg/day)
MDA (nmol/mL)	1.30 (1.11–1.84)	1.35 (1.18–1.48)	3.55 <sup>a</sup> (1.65–5.70) <sup>a</sup> <i>p</i> = 0.025	1.35 <sup>b</sup> (0.99–1.68) <sup>b</sup> <i>p</i> = 0.033	1.12 <sup>b</sup> (0.89–2.17) <sup>b</sup> <i>p</i> = 0.020
TOC (μM H <sub>2</sub> O <sub>2</sub> equivalent)	15.3 (7.2–17.7)	13.7 (11.7–17.7)	28.2 <sup>a</sup> (22.0–35.1) <sup>a</sup> <i>p</i> = 0.016	17.8 (14.0–22.7)	16.8 <sup>b</sup> (11.0–18.8) <sup>b</sup> <i>p</i> = 0.025
TAC (mM trolox equivalent)	0.98 (0.86–1.08)	0.99 (0.89–1.24)	0.73 <sup>a</sup> (0.61–0.84) <sup>a</sup> <i>p</i> = 0.016	0.88 (0.74–0.93)	0.89 <sup>b</sup> (0.82–0.95) <sup>b</sup> <i>p</i> = 0.045
OSI (arbitrary unit)	1.46 (0.84–1.98)	1.36 (1.07–1.95)	4.38 <sup>a</sup> (2.74–5.29) <sup>a</sup> <i>p</i> = 0.013	2.28 <sup>b</sup> (1.58–2.62) <sup>b</sup> <i>p</i> = 0.047	1.71 <sup>b</sup> (1.24–2.36) <sup>b</sup> <i>p</i> = 0.016
Caspase-3 (ng/mL)	1.59 (1.21–1.70)	1.50 (1.46–1.80)	6.90 (0.87–12.8)	1.69 (0.73–2.87)	1.80 (0.82–2.50)
TNF-α (pg/mL)	44.7 (23.1–58.4)	38.1 (29.2–51.8)	134.1 (36.4–333.3)	51.1 (35.7–68.0)	25.8 <sup>b</sup> (20.5–40.7) <sup>b</sup> <i>p</i> = 0.016
GSH (μg/mL)	213.9 (192.3–217.2)	208.9 (205.9–219.6)	175.0 <sup>a</sup> (164.2–185.2) <sup>a</sup> <i>p</i> = 0.016	198.6 <sup>b</sup> (188.7–214.8) <sup>b</sup> <i>p</i> = 0.032	205.6 <sup>b</sup> (189.3–219.6) <sup>b</sup> <i>p</i> = 0.025
8-OHdG (pg/mL)	1086.9 (855.6–1407.4)	1077.2 (894.4–1266.7)	2563.2 <sup>a</sup> (1522.2–2741.3) <sup>a</sup> <i>p</i> = 0.047	1906.3 <sup>a</sup> (1748.7–2048.2) <sup>a</sup> <i>p</i> = 0.011	1287.7 (908.6–1824.4)
BUN (mg/dL)	21.5 (21.0–24.0)	20.5 (18.0–22.0)	268.0 <sup>a</sup> (255.0–281.0) <sup>a</sup> <i>p</i> = 0.0001	187.0 <sup>a,b</sup> (157.0–220.0) <sup>a</sup> <i>p</i> = 0.0001 <sup>b</sup> <i>p</i> = 0.0001	19.5 <sup>b,c</sup> (18.0–20.0) <sup>b</sup> <i>p</i> = 0.0001 <sup>c</sup> <i>p</i> = 0.0001
Creatinine (mg/dL)	0.345 (0.340–0.370)	0.320 (0.240–0.370)	3.65 <sup>a</sup> (3.40–4.57) <sup>a</sup> <i>p</i> = 0.0001	2.59 <sup>a</sup> (1.35–4.16) <sup>a</sup> <i>p</i> = 0.0001	0.295 <sup>b,c</sup> (0.250–0.520) <sup>b</sup> <i>p</i> = 0.0001 <sup>c</sup> <i>p</i> = 0.0001

Data were expressed as median and 25%–75% quartiles (interquartile range (IQR)).  $p < 0.05$  was considered statistically significant. a, Significantly different compared with the negative control group ( $p < 0.05$ ), b, Significantly different compared with the CDDP group ( $p < 0.05$ ), c, Significantly different ( $p < 0.05$ ) compared with the *P. vulgaris* 25 mg/kg/day group.

*vulgaris* groups compared to the CDDP group. The biochemical results from the blood samples are shown in Table 3. MDA ( $p = 0.025$ ), TOC ( $p = 0.016$ ), OSI ( $p = 0.013$ ), 8-OHdG ( $p = 0.047$ ),

BUN ( $p = 0.0001$ ), and creatinine ( $p = 0.0001$ ) values increased significantly in serum samples from the CDDP group compared to the control group. Serum MDA ( $p = 0.020$ ), TOC ( $p = 0.025$ ), OSI



**Fig. 1.** Hematoxylin-eosin stained histopathological images of kidney tissue samples from the control group (A), DMSO group (B), CDDP group (C), CDDP + PV group (25 mg/kg/day) (D), and CDDP + PV group (50 mg/kg/day) (E). Glomeruli (G), tubular degeneration (double arrow), cast formation in the tubule lumen (four arrows), apoptotic cells and bodies (chevrons), vascular congestion (arrowhead), Bowman's space and degeneration in the glomeruli (bow).

**Table 4**  
Histological damage scores in the kidney tissue samples.

	Control	DMSO	CDDP (7.5 mg/kg)	CDDP (7.5 mg/kg) <i>P. vulgaris</i> (25 mg/kg/day)	CDDP (7.5 mg/kg) <i>P. vulgaris</i> (50 mg/kg/day)
<b>Damage Scores</b>	2.50 (2.00–3.25)	4.00 (3.00–4.00)	9.00 <sup>a</sup> (8.50–9.00) <sup>a</sup> <i>p</i> = 0.003	7.00 <sup>a, b</sup> (6.25–8.50) <sup>a</sup> <i>p</i> = 0.009 <sup>b</sup> <i>p</i> = 0.047	6.50 <sup>a, b</sup> (6.00–7.75) <sup>a</sup> <i>p</i> = 0.003 <sup>b</sup> <i>p</i> = 0.009

Data were expressed as median and 25%–75% quartiles (interquartile range (IQR)). *p* < 0.05 was considered statistically significant. a, Significantly different compared with the negative control group (*p* < 0.05), b, Significantly different compared with the CDDP group (*p* < 0.05).

(*p* = 0.016), TNF- $\alpha$  (*p* = 0.016), 8-OHdG (*p* = 0.011), BUN (*p* = 0.0001), and creatinine (*p* = 0.0001) were significantly lower in the *P. vulgaris* groups compared to the CDDP group. While serum TAC (*p* = 0.016) and GSH (*p* = 0.016) levels decreased significantly in the CDDP group compared to the control group, significant increases in tissue TAC (*p* = 0.045) and GSH (*p* = 0.025) levels were observed in the *P. vulgaris* groups compared to the CDDP group.

### 3.3. Histological findings

Histopathological images from the experimental groups are shown in Fig. 1. Glomeruli exhibited a normal structure in slides from the control group and the DMSO group, and no pathological findings were observed. Degeneration of tubules (double arrow), cast formation in the tubule lumen (four arrows), apoptotic cells and bodies (chevrons), vascular congestion (arrowhead) (H&E X400) were observed in kidney sections from the CDDP group, CDDP + 25 mg/kg/day PVE group (D), and CDDP + 50 mg/kg/day PVE group (H&E X400). Histological damage scores for the kidney tissue samples from the experimental groups are given in Table 4. Damage scores in the CDDP and control groups were significantly higher compared to those in the control group (*p* = 0.003), and significantly lower in the PVE groups than in the CDDP group (*p* = 0.009).

## 4. Discussion

The main functions of the kidney include the metabolism and excretion of substances administered for the treatment and diagnosis of diseases. CDDP accumulates in renal tissue, increases reactive oxygen species (ROS), and inhibits the activity of antioxidant enzymes, and severe renal damage has been reported in several studies as a result. Anticancer drugs are reported to cause renal tubular damage. (Iseri et al., 2007; Yilmaz et al., 2013; Sindhu et al., 2015). Oxidative stress is involved in CDDP-induced acute kidney injury. ROS directly disrupt the structures of cellular components, such as DNA, lipids and proteins. They also activate tumor necrosis factor alpha, which causes a series of inflammatory changes that mediate kidney damage. While MDA levels rise, antioxidant enzymes, such as, GSH, superoxide dismutase (SOD), and catalase (CAT) are inhibited (Sayed, 2009; Miller et al., 2010; Hassan et al., 2017). Traditional medicine, including treatment using medicinal plants, is used by 80% of the world population, and antioxidants have been proven to be effective in preventing CDDP-induced toxicities. Primulacea species have also been reported to be capable of reducing nephrotoxicity and hepatotoxicity (Shabbir et al., 2022; Gilani et al., 2022; Junming et al., 2019). *P. vulgaris* has been reported to exhibit anticancer and powerful antioxidant properties in the leaf part (Demir et al., 2018, 2019; Turan et al., 2017). The present study represents the first report of the effect of PVE on DNA damage, and MDA, GSH, TAC, TOC, and OSI levels in blood and kidney tissues in CDDP-induced experimental kidney injury in rats. The findings showed that PVE significantly reversed these deleterious effects caused by CDDP.

Rutin (385.28  $\mu$ g/g. sample), gallic acid (60.58  $\mu$ g/g. sample), protocatechuic acid (28.42  $\mu$ g/g. sample) and *p*-coumaric acid (23.36  $\mu$ g/g. sample) were identified as major compounds in PVE as a result of screening 29 different polyphenolic compounds and compound groups by means of LC-MS-MS analysis in this study. In their flower content analysis of *P. vulgaris*, Ozkan et al. identified rutin and *p*-coumaric acid as major phenolics, with gallic acid, vanillic acid, protocatechuic acid, catechin, and caffeic acid also being reported (Ozkan et al., 2017). The results of present study are similar to those of Ozkan et al. Content analysis of PVE in the existing literature is limited. Colombo et al. reported kaempferol in 2014, and Harborn gossypin in 1968 (Colombo et al., 2014; Harborne, 1968). The inconsistencies between the results of the present study and previous research may be due to the investigation of more polyphenolic compounds in this study, the use of different solvents, and differences in location.

Within this study, nephrotoxicity was induced by single injection of CDDP (7.5 mg/kg). MDA, TOC, Casp-3, TNF- $\alpha$ , and 8-OHdG increased significantly in the CDDP group compared to the control group, and the histological changes observed confirmed the presence of renal damage and nephrotoxicity. The DMSO group results confirmed that the *P. vulgaris* extract solvents were not toxic or at high enough doses to affect the experimental results.

MDA and TOC levels in blood and tissue samples increased significantly in the CDDP group compared to the control group in this study. However, MDA levels in blood and tissue samples decreased significantly and in a dose-dependent manner in the PVE groups compared to the CDDP group. TOC levels in serum samples decreased significantly in the PVE group compared to the CDDP group. A comparison of TAC values in the various tissue samples revealed no significant difference between the groups. TAC values in serum samples increased in the PVE groups compared to CDDP group. Additionally, OSI values in serum samples decreased significantly in a dose-dependent manner in the PVE groups compared to the CDDP group. No previous studies have been conducted with PVE in the context of nephrotoxicity, although similar results have been obtained in research involving natural product extracts and phenolic compounds. Kamel et al. reported that rutin, one of the major compounds of PVE, exhibited a protective effect by reducing MDA levels in kidney tissues in a CDDP-induced nephrotoxicity model in rats. (Kamel et al., 2014) Akdemir et al. investigated the protective efficacy of *p*-coumaric acid against CDDP-induced renal damage in rats and reported that it significantly lowered renal tissue MDA levels that were raised by CDDP (Akdemir et al., 2017). In another study, Hakyemez et al. reported that *p*-coumaric acid ameliorated gentamicin-induced nephrotoxicity and reduced renal tissue OSI levels. (Hakyemez et al., 2022). In addition, Demir et al. reported that gallic acid administration significantly reduced ovarian tissue MDA, TOC, and OSI values in CDDP-induced ovarian damage. (Ayazoglu Demir et al., 2023). Dogan et al. reported that MDA levels, which increased in renal tissues due to CDDP toxicity, decreased in a gallic acid-treated group in their study of CDDP-induced nephrotoxicity in rats. (Dogan et al., 2022). The protective properties of polyphenolic compounds found in PVE against nephrotoxicity described in the previous literature are consistent

with our results. The protective effect of PVE against lipid peroxidation and oxidative stress caused by CDDP may be due to the synergistic antioxidant properties of the phenolic compounds in its content.

Levels of GSH, one of the antioxidant enzymes, in tissue and blood samples decreased significantly in the CDDP group compared to the control group. However, GSH levels in tissue and blood samples increased significantly in the PVE group compared to the CDDP group. Kamel *et al.* reported that rutin increased the lowered GSH levels observed in kidney tissues in CDDP-induced nephrotoxicity in rats (Kamel *et al.*, 2014). Similarly, Eslamifar *et al.* reported that gallic acid ameliorated CDDP-induced nephrotoxicity and GSH levels, which were low in the CDDP group but increased in the gallic acid group. (Eslamifar *et al.*, 2021). In Savci *et al.*'s study, in which 2,3,7,8-tetrachlorodibenzo-p-dioxin (TCDD)-induced nephrotoxicity was reduced by protocatechuic acid, TCDD-suppressed GSH levels were reported to be increased by protocatechuic acid (Savci and Ozdemir, 2020).

Oxidative stress is the primary mediator of chemotherapeutic nephrotoxicity. ROS forming as a result of oxidative stress exert adverse effects on cellular macromolecules, such as DNA (Amini *et al.*, 2022; Turan *et al.*, 2015). 8-OHdG is used as a biomarker for the measurement of oxidative damage (Valavanidis *et al.*, 2009). In the present study, 8-OHdG levels were measured to assess DNA damage in blood and tissue samples, and these increased significantly in the CDDP group compared to the control group. 8-OHdG levels in tissue samples from the PVE group were significantly compared to the CDDP group ( $p < 0.01$ ). Dogan *et al.* reported that gallic acid significantly reduced 8-OHdG levels in kidney tissues compared to a CDDP group in their CDDP-induced nephrotoxicity study (Dogan *et al.*, 2022). Similarly in Sener *et al.*'s study of CDDP-induced nephrotoxicity, the authors found that quercetin significantly lowered renal tissue 8-OHdG levels compared to the CDDP group (Sener *et al.*, 2020). The protective effects achieved in the present study are attributable to the active substances in *P. vulgaris* and are compatible with the results from the previous literature.

TNF- $\alpha$  is important in CDDP-induced nephrotoxicity (Kumar *et al.*, 2017). In the present study, TNF- $\alpha$  levels increased in the CDDP group compared to the control group, and were also lower in the PVE groups than in the CDDP group. In their study of CDDP-induced nephrotoxicity, Alhoshani *et al.* reported that TNF- $\alpha$  expressions increased in the CDDP group and decreased significantly in the CDDP + rutin group (Alhoshani *et al.*, 2017). Similarly, in Rafiee *et al.*'s study of doxorubicin-induced nephrotoxicity, the authors reported that TNF- $\alpha$  levels increased in the doxorubicin group and decreased in the doxorubicin + *p*-coumaric acid group (Rafiee *et al.*, 2020). We think that the inflammation caused by the use of CDDP is reduced by the active substances we detected in *P. vulgaris*, with its known antioxidant properties.

Apoptosis of renal cells has been the focus of investigation in CDDP-nephrotoxicity. The intrinsic apoptosis pathway is particularly prominent in CDDP nephrotoxicity. Activation of caspases 3, 8 and 9 occurs 12 h after CDDP interaction with renal epithelial cells. Inhibition of caspase activity suppresses CDDP-induced cell death (Miller *et al.*, 2010; Pabla and Dong, 2008). In the present study, serum caspase-3 levels in the CDDP group increased significantly compared to those in the control group. Tissue CASP3 levels also decreased significantly in the treatment groups compared to the CDDP group. These results suggest that PVE suppresses apoptosis to prevent damage in kidney tissue as a result of its potent antioxidant content. Arjumand *et al.* reported that rutin exhibited an inhibitory effect on caspase-3-mediated tubular cell apoptosis and provided histopathological restoration. (Arjumand *et al.*,

2011). Demir *et al.* reported that gallic acid exhibited a protective effect against apoptosis by reducing renal tissue caspase-3 levels in CDDP-induced ovarian toxicity (Ayazoglu Demir *et al.*, 2023).

CDDP nephrotoxicity causes a decrease in the glomerular filtration rate (GFR) and increased serum BUN and creatinine levels in the kidneys (Elsherbiny *et al.*, 2016; Sanchez-Gonzalez *et al.*, 2011). In the present study, BUN and creatinine levels in serum samples decreased significantly in the PVE groups compared to the CDDP groups. Kamel *et al.* reported that rutin prevented kidney damage by significantly lowering blood BUN and creatinine levels in their CDDP-induced nephrotoxicity study (Kamel *et al.*, 2014). Bencheikh *et al.* reported significantly lower blood BUN and creatinine levels than in a gentamicin group, in their study of gentamicin-induced nephrotoxicity with *Zizyphus lotus* L. extract, with its similar polyphenolic compound content to that of PVE (Bencheikh *et al.*, 2021). Similarly, Hakyemez *et al.* reported that *p*-coumaric acid significantly reduced serum creatinine and urea levels compared to the gentamicin group in gentamicin-induced nephrotoxicity (Hakyemez *et al.*, 2022). In agreement with the previous literature, the polyphenolic compounds found in PVE appear to inhibit chemotherapeutic toxicity.

CDDP accumulation at high concentrations in the kidneys causes nephrotoxicity through necrosis, apoptosis, tubular inflammation and vascular factors (Elsherbiny *et al.*, 2016). Histological examinations in the present study revealed damage in the kidney tissues from the CDDP-treated group. This damage was significantly ameliorated in the PVE treatment groups. Prasad *et al.* examined the effect of rutin on CDDP-induced toxicity in mice. Those authors reported that CDDP treatment caused severe changes in the histoarchitecture, such as tubular congestion and glomerular degeneration, while this condition improved in the rutin + CDDP group, and concluded that rutin exhibited a nephroprotective effect (Prasad and Prasad, 2021). Yamabe *et al.* reported that protocatechuic acid improved the histological appearance of CDDP-treated rat kidneys and reduced tubular cell damage (Yamabe *et al.*, 2015). Similarly, Rafiee *et al.* reported that *p*-coumaric acid significantly reversed doxorubicin-induced nephrotoxicity by improving histopathological scores (Rafiee *et al.*, 2020). The results in the literature are consistent with our own study data.

## 5. Conclusion

It is known that oxidative stress, inflammation and apoptosis are the main mechanisms involved in the etiopathogenesis of CDDP-induced nephrotoxicity. (Hassan *et al.*, 2017) In our study, the changes in oxidative stress, inflammation and apoptosis parameters in the CDDP group are consistent with this literature. As a result of the chemical characterization study of PVE, it was determined that it is rich in phenolic compounds such as gallic acid, protocatechuic acid, taxifolin, *p*-coumaric acid, rutin and quercetin. Phenolic compounds have strong antioxidant activity due to their chain breaking, hydrogen donating, metal chelating and radical scavenging potentials. (Pereira *et al.*, 2009) In this study, it is thought that the protective effect of PVE against CDDP-induced kidney damage is mainly due to the antioxidant properties of the phenolic compounds it contains. However, future studies need to evaluate the renoprotective effect of PVE by including cell signaling.

## Declaration of Competing Interest

The authors declare that they have no known competing financial interests or personal relationships that could have appeared to influence the work reported in this paper.

## References

- Abdel Moneim, A.E., Othman, M.S., Aref, A.M., 2014. Azadirachta indica attenuates cisplatin-induced nephrotoxicity and oxidative stress. *Biomed Res. Int.* 2014, 1–11.
- Alhoshani, A.R., Hafez, M.M., Husain, S., Al-Sheikh, A.M., Alotaibi, M.R., Al Rejaie, S.S., Alshammari, M.A., Almutairi, M.M., Al-Shabaneh, O.A., 2017. Protective effect of rutin supplementation against cisplatin-induced Nephrotoxicity in rats. *BMC Nephrol.* 18 (1), 1–10.
- Amini, N., Badavi, M., Mard, S.A., Dianat, M., Moghadam, M.T., 2022. The renoprotective effects of gallic acid on cisplatin-induced nephrotoxicity through anti-apoptosis, anti-inflammatory effects, and downregulation of lncRNA TUG1. *Naunyn Schmiedeberg's Arch. Pharmacol.* 395 (6), 691–701.
- Arjumand, W., Seth, A., Sultana, S., 2011. Rutin attenuates cisplatin induced renal inflammation and apoptosis by reducing NF $\kappa$ B, TNF- $\alpha$  and caspase-3 expression in wistar rats. *Food Chem. Toxicol.* 49 (9), 2013–2021.
- Ayazoglu Demir, E., Mentese, A., Livaoglu, A., Turkmen Alemdar, N., Demir, S., 2021. Ameliorative effect of gallic acid on cisplatin-induced ovarian toxicity in rats. *Drug Chem. Toxicol.* 46, 1–7.
- Baltaci, B. B., Uygur, R., Caglar, V., Aktas, C., Aydin, M., Ozen, O. A., 2016. Protective effects of quercetin against arsenic-induced testicular damage in rats. *Andrologia.* 48, 1202–1213
- Bencheikh, N., Bouhrim, M., Kharoucha, L., Al Kamaly, O.M., Mechchate, H., Es-Safi, I., Dahmani, A., Ouahhoud, S., El Assri, S., Eto, B., Bnouham, M., Çukri, M., Elachouri, M., 2021. The nephroprotective effect of Zizyphus lotus L. (desf.) fruits in a gentamicin-induced acute kidney injury model in rats: a biochemical and histopathological investigation. *Molecules* 26 (16), 4806.
- Chang, Y., Cui, P., Zhou, S., Qiu, L., Jiang, P., Chen, S., Cheng, W., Wang, J., 2023. Metal-phenolic network for cancer therapy. *J. Drug Delivery Sci. Technol.* 104194.
- Colombo, P.S., Flamini, G., Fico, G., 2014. Primula latifolia Lapeyr. and Primula vulgaris Hudson flavonoids. *Nat. Prod. Res.* 28 (19), 1641–1644.
- Demir, S., Turan, I., Aliyazicioğlu, R., Yaman, S.O., Aliyazicioğlu, Y., 2018. Primula vulgaris extract induces cell cycle arrest and apoptosis in human cervix cancer cells. *J. Pharm. Anal.* 8 (5), 307–311.
- Demir, S., Turan, I., Aliyazicioğlu, Y., 2019. Antioxidant properties of Primula vulgaris flower extract and its cytotoxic effect on human cancer cell lines. *Kahramanmaraş Sütçü İmam Üniversitesi Tıp ve Doğa Dergisi* 22 (1), 78–84.
- Demir, S., Kazaz, I.O., Aliyazicioğlu, Y., Kerimoglu, G., Teoman, A.S., Yaman, S.O., Arslan, A., Mentese, A., 2020. Effect of ethyl pyruvate on oxidative state and endoplasmic reticulum stress in a rat model of testicular torsion. *Biotech. Histochem.* 95 (4), 317–322.
- Doğan, D., Meydan, I., Kömüroğlu, A.U., 2022. Protective effect of silymarin and gallic acid against cisplatin-induced nephrotoxicity and hepatotoxicity. *Int. J. Clin. Pract.* 2022, 1–10.
- Ekinci Akdemir, F.N., Albayrak, M., Çalık, M., Bayir, Y., Gülçin, İ., 2017. Sisplatinin neden olduğu akut karaciğer ve böbrek hasarlarında p-kumarik asidin koruyucu etkileri. *Biyotıp* 5 (2), 18.
- Elsherbiny, N.M., Eladl, M.A., Al-Gayyar, M.M., 2016. Renal protective effects of arjunolic acid in a cisplatin-induced nephrotoxicity model. *Cytokine* 77, 26–34.
- Eslamifard, Z., Moridnia, A., Sabbagh, S., Ghaffari, R., Jafaripour, L., Behzadifard, M., 2021. Ameliorative effects of gallic acid on cisplatin-induced nephrotoxicity in rat variations of biochemistry, histopathology, and gene expression. *BioMed Research International.* 2021.
- Gilani, S.J., Bin-Jumah, M.N., Al-Abbasi, F.A., Nadeem, M.S., Alzarea, S.I., Ahmed, M. M., Seyyid, N., Kazmi, I., 2022. Rosinidin protects against cisplatin-induced nephrotoxicity via subsiding proinflammatory and oxidative stress biomarkers in rats. *Int. J. Environ. Res. Public Health* 19 (15), 9719.
- Hakyemez, I.N., Cevizci, M.N., Aksoz, E., Yilmaz, K., Uysal, S., Altun, E., 2022. Protective effects of p-coumaric acid against gentamicin-induced nephrotoxicity in rats. *Drug Chem. Toxicol.* 45 (6), 2825–2832.
- Harborne, J.B., 1968. Comparative biochemistry of the flavonoids—VII: Correlations between flavonoid pigmentation and systematics in the family Primulaceae. *Phytochemistry* 7 (8), 1215–1230.
- Hassan, S.M., Khalaf, M.M., Sadek, S.A., Abo-Youssef, A.M., 2017. Protective effects of apigenin and myricetin against cisplatin-induced nephrotoxicity in mice. *Pharm. Biol.* 55 (1), 766–774.
- Iseri, S., Ercan, F., Gedik, N., Yüksel, M., Alican, İ., 2007. Simvastatin attenuates cisplatin-induced kidney and liver damage in rats. *Toxicology* 230 (2–3), 256–264.
- Jamshidzadeh, A., Heidari, R., Golzar, T., Derakhshanfar, A., 2016. Effect of Eisenia foetida extract against cisplatin-induced kidney injury in rats. *J. Diet. Suppl.* 13 (5), 551–559.
- Junming, W., Jinhua, L., Hong, C., Yueyue, Z., Jinyang, L., Ying, C., 2019. Leigongteng (Radix et Rhizoma Tripterygii) via compatibility with Jinqiancao (Herba Lysimachiae): its toxicity-reduced efficacy in H22-bearing mice. *J. Tradit. Chin. Med.* 39 (04), 550.
- Kamel, K.M., Abd El-Raouf, O.M., Metwally, S.A., Abd El-Latif, H.A., El-sayed, M.E., 2014. Hesperidin and rutin, antioxidant citrus flavonoids, attenuate cisplatin-induced nephrotoxicity in rats. *J. Biochem. Mol. Toxicol.* 28 (7), 312–319.
- Kandhare, A.D., Mukherjee, A., Bodhankar, S.L., 2017. Efficacy of antioxidant supplements on prevention and amelioration of cisplatin-induced nephrotoxicity: a systematic review and meta-analysis of randomized controlled trials. *Value Health* 20 (9), A895.
- Kayir, Ö., Doğan, H., Alver, E., Bilici, İ., 2023. Quantification of phenolic component by LC-HESI-MS/MS and evaluation of antioxidant activities of crocus Ancrensis (Ankara Çiğdemi) Extracts obtained with different solvents. *Chem. Biodivers.* 20 (4), e202201186.
- Korkmaz, N., Sener, S.O., Akkaya, S., Aliyazicioğlu, R., Özgen, U., Badem, M., 2017. Evaluation of the antioxidant activity of Primula vulgaris water extract on the kidney of methotrexate-induced testicular damaged in rats, IVEK 3rd International convention of pharmaceuticals and pharmacies. 2017, 529.
- Kumar, P., Sulakhiya, K., Barua, C.C., Mundhe, N., 2017. TNF- $\alpha$ , IL-6 and IL-10 expressions, responsible for disparity in action of curcumin against cisplatin-induced nephrotoxicity in rats. *Mol. Cell. Biochem.* 431, 113–122.
- Li, A.N., Li, S., Zhang, Y.J., Xu, X.R., Chen, Y.M., Li, H.B., 2014. Resources and biological activities of natural polyphenols. *Nutrients* 6 (12), 6020–6047.
- Miller, R.P., Tadagavadi, R.K., Ramesh, G., Reeves, W.B., 2010. Mechanisms of cisplatin nephrotoxicity. *Toxins* 2 (11), 2490–2518.
- Ozkan, M., Aliyazicioğlu, R., Demir, S., Misir, S., Turan, I., Yıldırım, S., Aliyazicioğlu, Y., 2017. Phenolic characterisation and antioxidant activity of Primula vulgaris and its antigenotoxic effect on fibroblast cells. *Jundishapur J. Nat. Pharmaceut. Prod.* 12 (1), e40073.
- Pabla, N., Dong, Z., 2008. Cisplatin nephrotoxicity: mechanisms and renoprotective strategies. *Kidney Int.* 73 (9), 994–1007.
- Palipoch, S., Punsawad, C., Chinnapun, D., Suwannaler, P., 2013. Amelioration of cisplatin-induced nephrotoxicity in rats by curcumin and  $\alpha$ -tocopherol. *Trop. J. Pharm. Res.* 12 (6), 973–979.
- Pereira, D.M., Valentao, P., Pereira, J.A., Andrade, P.B., 2009. Phenolics: From Chemistry to Biology. *Molecules.* 17;14(6), 2202–2211.
- Prasad, R., Prasad, S.B., 2021. Histoprotective effect of rutin against cisplatin-induced toxicities in tumor-bearing mice: rutin lessens cisplatin-induced toxicities. *Hum. Exp. Toxicol.* 40 (2), 245–258.
- Rafiee, Z., Moaiedi, M.Z., Gorji, A.V., Mansouri, E., 2020. p-Coumaric acid mitigates doxorubicin-induced nephrotoxicity through suppression of oxidative stress, inflammation and apoptosis. *Arch. Med. Res.* 51 (1), 32–40.
- Sanchez-Gonzalez, P.D., Lopez-Hernandez, F.J., Perez-Barriocanal, F., Morales, A.I., Lopez-Novoa, J.M., 2011. Quercetin reduces cisplatin nephrotoxicity in rats without compromising its anti-tumour activity. *Nephrol. Dial. Transplant.* 26 (11), 3484–3495.
- Savcı, A., Özdemir, İ., 2020. Role of Protocatechuic Acid (PCA) on Hepatotoxicity and Nephrotoxicity Induced by 2, 3, 7, 8-Tetrachlorodibenzo-p-Dioxin (TCDD) in Rats. *Düzce Üniversitesi Bilim ve Teknoloji Dergisi* 8 (1), 546–553.
- Sayed, A.A.R., 2009. Proanthocyanidin protects against cisplatin-induced nephrotoxicity. *Phytother. Res.* 23 (12), 1738–1741.
- Şener, T., Çadırcı, S., Çevik, Ö., Ercan, F., Köroğlu, M., Sakarcan, S., Şener, G., 2020. Protective effects of quercetin against cisplatin induced urogenital organ toxicity. *J. Res. Pharm.* 24 (5).
- Shabbir, U., Anjum, I., Naveed Mushtaq, M., Nasir Hayat Malik, M., Ismail, S., Javed, J., Noreen, S., Pervaiz, A., Tariq, A., Wazir, M., Islam, Z., Majide, M., Mansha, S., Ur Rehman, Z., 2022. Uroprotective and Hepatoprotective Potential of Anagallis arvensis against the Experimental Animal Model. *Journal of Tropical Medicine.* 2022, 1–10.
- Sindhu, G., Nishanthi, E., Sharmila, R., 2015. Nephroprotective effect of vanillic acid against cisplatin induced nephrotoxicity in wistar rats: a biochemical and molecular study. *Environ. Toxicol. Pharmacol.* 39 (1), 392–404.
- Turan, I., Değer, O., Aliyazicioğlu, Y., Demir, S., Kiliç, K., Sümer, A., 2015. Effects of Turkish propolis on expression of hOGG-1 and NEIL-1. *Turk. J. Med. Sci.* 45 (4), 804–811.
- Turan, İ., Demir, S., Aliyazicioğlu, R., Aliyazicioğlu, Y., 2017. Primula vulgaris Yaprak Ekstraktının Antioksidan ve Sitotoksik Özelliklerinin Değerlendirilmesi. *KSÜ Doğa Bil. Derg.* 20 (4), 361–367.
- Turan, I., Demir, S., Kiliç, K., Yaman, S.O., Misir, S., Kara, H., Genç, B., Mentese, A., Aliyazicioğlu, Y., Deger, O., 2018. Cytotoxic effect of Rosa canina extract on human colon cancer cells through repression of telomerase expression. *J. Pharm. Anal.* 8 (6), 394–399.
- Uchiyama, M., Mihara, M., 1978. Determination of malonaldehyde precursor in tissues by thiobarbituric acid test. *Anal. Biochem.* 86 (1), 271–278.
- Valavanidis, A., Vlachogianni, T., Fiotakis, C., 2009. 8-hydroxy-2'-deoxyguanosine (8-OHdG): a critical biomarker of oxidative stress and carcinogenesis. *J. Environ. Sci. Health C* 27 (2), 120–139.
- Yamabe, N., Park, J.Y., Lee, S., Cho, E.J., Lee, S., Kang, K.S., Hwang, S.G., Kim, S., Kim, Y. H., Shibamoto, T., 2015. Protective effects of protocatechuic acid against cisplatin-induced renal damage in rats. *J. Funct. Foods* 19, 20–27.
- Yilmaz, I., Demiryılmaz, I., Turan, M. I., Suleyman, B., Turan, I. S., Altuner, D., Alp H. H., Suleyman, H. 2013. The Protective Effect of Melatonin and agomelatin against cisplatin-Induced nephrotoxicity and oxidative Stress in the rat Kidney. *Latin American Journal of Pharmacy.* *Lat Am J Pharm.* 32 (8), 1231–1235.