



Case report

Total femoral allograft with simultaneous revision total hip and knee arthroplasty: 18 year follow-up

Ryan N. Harris, DO ^{a, b}, Trevor M. Owen, MD ^{c, d}, Joseph T. Moskal, MD, FACS ^{a, d, *}^a Department of Orthopaedic Surgery, Adult Reconstruction, Carilion Clinic, Roanoke, VA, USA^b Department of Orthopaedic Surgery, Virginia Tech Carilion School of Medicine, Christiansburg, VA, USA^c Orthopaedic Trauma, Limb Lengthening and Deformity Correction, Carilion Clinic, Roanoke, VA, USA^d Department of Orthopaedic Surgery, Virginia Tech Carilion School of Medicine, Roanoke, VA, USA

ARTICLE INFO

Article history:

Received 12 March 2015

Received in revised form

12 April 2015

Accepted 14 April 2015

Available online 28 August 2015

Keywords:

Total hip arthroplasty

Total knee arthroplasty

Excessive bone loss

Simultaneous revision

Rheumatoid arthritis

Femoral allograft

Total femoral replacement

ABSTRACT

Massive allograft can be a useful option in revision total joint arthroplasty for treatment of significant bone loss. In rare cases, revision hip and knee arthroplasty procedures can be performed simultaneously using massive allograft-prosthetic composites. We present an 18 year follow up of a patient who received a simultaneous revision hip and knee total femoral allograft and discuss recent literature as it relates to this case. Copyright © 2015 Published by Elsevier Inc. on behalf of American Association of Hip and Knee Surgeons. This is an open access article under the CC BY-NC-ND license (<http://creativecommons.org/licenses/by-nc-nd/4.0/>).

Introduction

Revision total joint arthroplasty has many variables to consider when surgical planning begins. One of the most important of those is the amount of bone available to facilitate the revision. In the event of excessive bone loss, the options become even more limited. When the joints being revised involve the ipsilateral total hip and total knee arthroplasty simultaneously, the options include resection arthroplasty, megaprosthesis, large structural allograft, or amputation. In order to preserve as much function as possible, resection arthroplasty and amputation are avoided at all costs.

One or more of the authors of this paper have disclosed potential or pertinent conflicts of interest, which may include receipt of payment, either direct or indirect, institutional support, or association with an entity in the biomedical field which may be perceived to have potential conflict of interest with this work. For full disclosure statements refer to <http://dx.doi.org/10.1016/j.artd.2015.04.003>

* Corresponding author. 3 Riverside Circle, Roanoke, VA 24016, USA. Tel.: +1 540 526 1472.

E-mail address: jtmoskal@carilionclinic.org

<http://dx.doi.org/10.1016/j.artd.2015.04.003>

2352-3441/Copyright © 2015 Published by Elsevier Inc. on behalf of American Association of Hip and Knee Surgeons. This is an open access article under the CC BY-NC-ND license (<http://creativecommons.org/licenses/by-nc-nd/4.0/>).

Case history

A 79-year-old female with severe rheumatoid arthritis underwent right total femoral allograft with simultaneous THA revision and TKA revision in 1996. The massive allograft was used for treatment of a distal femoral periprosthetic fracture with persistent non-union despite several surgical interventions attempting to achieve bony union (Fig. 1). A femoral allograft was selected pre-operatively based on templating the patient's host bone for size and components likely to be used for procedure. A lateral approach was used as well as a trochanteric slide to expose the length of the femur. An oscillating saw was used to split the lateral cortex of the femur and the previous components were taken out proximally and distally, while verifying the acetabulum and tibial components were still stable. Using standard instrumentation, a long-stemmed femoral hip implant and semi-constrained knee implant were cemented simultaneously to create a single uniform cement mantle. The allograft was then placed into the host bone shell that remained hinged medially, and bone graft was placed at the interface to enhance union. Multiple cerclage wires and cable grip greater trochanter attachment were used to finalize fixation [1].

Two weeks post-op, she did have a dislocation that was closed reduced and treated with a single leg spica cast for a period of six

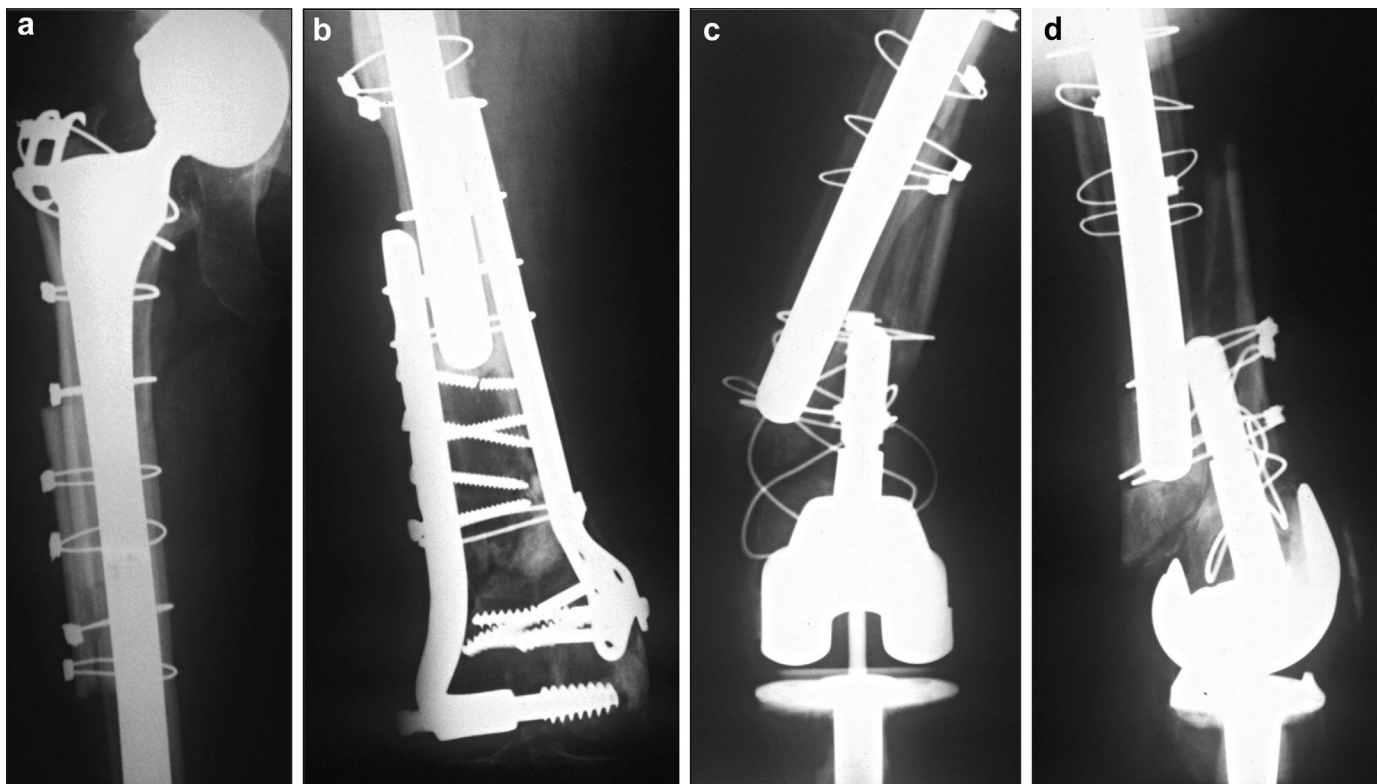


Figure 1. AP radiograph of right hip (a) and knee (b) after initial hip revision and internal fixation of the distal femur. AP (c) and lateral (d) radiographs of right knee after periprosthetic fracture following conversion to total knee replacement.

weeks. She was seen at two years having returned to her pre-fracture level of function, ambulating with a cane, WBAT and doing well. At three years she was seen, also doing well, with a Harris Hip Score of 75 at that time. Office notes were reviewed at 8 and 10 years, where she stated no pain in the right hip and that she was doing well, with no additional procedures to the right hip noted during the interval. The patient continued to do well and was very functional for over 17 years post-operatively (Fig. 2). This patient and method were previously described by Urch and Moskal [1].

After nearly two decades with a well functioning prosthesis the patient was diagnosed with acute methicillin-resistant *Staphylococcus aureus* (MRSA) sepsis and bacteremia of unknown origin. She was hospitalized for several weeks in another facility and was in the ICU secondary to concern for sepsis related cardiac events. She was found to have an infected pacemaker that was subsequently removed. She was treated with IV antibiotics and recovered sufficiently to be discharged from the hospital. Two weeks after discharge she developed right hip and knee pain. Clinical evaluation showed a right knee effusion and an aspiration revealed 15,655 WBCs with 83% neutrophils, and the knee aspiration culture showed 2+ MRSA. Given her TKA infection and hip pain with probable infection of her entire allograft, removal of her entire component was recommended. Because of her advanced age and multiple medical comorbidities, hip disarticulation was recommended, as it was not felt she could safely tolerate staged revision with antibiotic spacer. Additionally, debridement and chronic antibiotic suppression were also discussed, however due to the size of her allograft, complete debridement would be difficult with significant risk of recurrence.

Intra-operative findings noted full incorporation of her allograft and continued mechanical stability. A tract was identified at the time of surgery between areas of the allograft and the outer host bone that was closed and cabled around the allograft during the

initial procedure (Fig. 3). Purulent material tracked from the TKA components proximally to the THA components and prosthetic infection of the hip was confirmed. The patient has since healed her disarticulation incision site well with no signs of recurrent infection and has been able to transfer herself from bed to wheelchair without assistance (Fig. 4).

Discussion

The surgical options for managing patients with excessive bone loss have evolved over the past century. These options have also been greatly impacted by the advent of THA and TKA. The first review of massive bone allografts dates back to the early 1900s by Lexer, while the first femur allograft procedure was described in 1965 by Buchman [2,3]. Before that, the only options were amputation or hip disarticulation. Resection arthroplasty became a viable option when the need to retain the limb or salvage an extremity was greater than the need for an amputation, or when there was concern that a patient could not tolerate a more extensive procedure. As treatment protocols evolved and the ability to replace bone loss became more practical, the pendulum swung toward limb salvage in the majority of cases. The ability to retain mobility and range of motion using metal arthroplasty for degenerative joint disease and other pathology further advanced retention of a functional limb to aid in mobility. This case update looks at selected literature since our patient was first presented in Journal of Arthroplasty in 1998.

Patients in need of these procedures usually fall into two subsets: bone loss due to tumor/malignancy or bone loss associated with total joint arthroplasty. In 2010, Ruggieri reviewed results of patients who received either a megaprosthesis or an allograft for a tumor diagnosis. The review comprised of 23 patients over 19 years. Six patients continued to be disease free, 13 died from

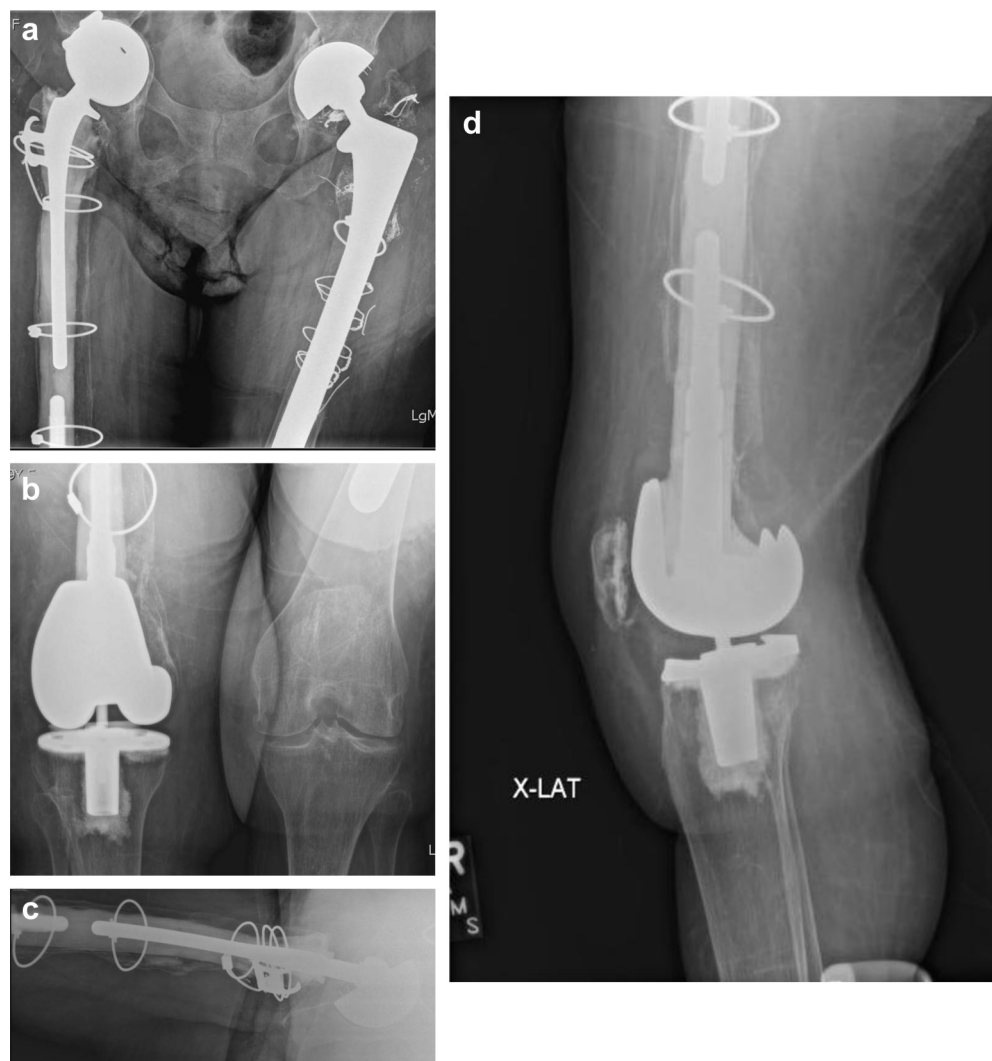

Figure 2. AP pelvis (a) and right knee (b) radiograph 17 years after right total femoral allograft. Lateral right femur (c) and right knee (d) radiograph 17 years after right total femoral allograft.

malignancy at an average of 17 months post-op, one had no evidence of disease after remission, one was alive with disease in stable condition, and two were lost to follow-up. Five out of 21 (24%) had complications requiring revision surgery, 2 infections and 3 mechanical failures. Importantly, it should be noted all patients in this review underwent hemiarthroplasty of their hip without placement of an acetabular cup [4].

Amanatullah et al. in *JOA* in 2014 (Manuscript accepted) reviewed 20 non-tumor related allografts. Overall infection rate was 35%, average follow-up was 73 months, overall instability was 25%, and an HHS score increase of 35 points on average in functional scoring between pre-op and post-op was noted. Additionally, as opposed to the Ruggieri review, no hemiarthroplasties were performed in this cohort with all implants including acetabular replacement [4,5].

Another orthopedic oncology based review from Puri et al. in India reported on 8 patients that received a total femoral prosthesis at an average of 32 years old. One infection required hardware removal, but 7 of 8 still had functional use at 5 years. A Kaplan Meier survival score of 88% of the prosthesis persisted at the time of publication. One other element of interest from this publication, the implant that was used was locally manufactured and cost only

\$2000. It was noted that similar hardware used internationally would average a cost more than 9 times this amount, or \$18,000. This could prove to be fiscally significant in a time of constant cost analysis and call for savings [6].

Mankin reviewed 15 patients over a 23-year period; the majority of which had procedures performed for tumor related processes. Ten of the 15 patients had procedures with TKA and THA allograft composites implanted similar to our case study, whereas the other 5 underwent replacement with megaprosthesis. Seven patients were still living with well functioning prostheses, but eight patients died during that time. Of note, the two non-oncologic patients in this group, one was a Paget's disease patient and one with osteonecrosis, were alive at follow up, showing the potential effectiveness of this procedure on a non-oncology condition. Mankin showed that there were no functional differences between the 10 allografts and the 5 megaprosthesis. There were no dislocations in the group and also only one irrigation and debridement washout with implant retention for treatment of infection. Trendelenburg gait tended to be higher in patients with all metal devices versus patients with allografts prosthetic composites [7].

Muscolo et al. reported on 6 cases of femoral allograft followed for 22–36 years. This review included three intercalary grafts, one

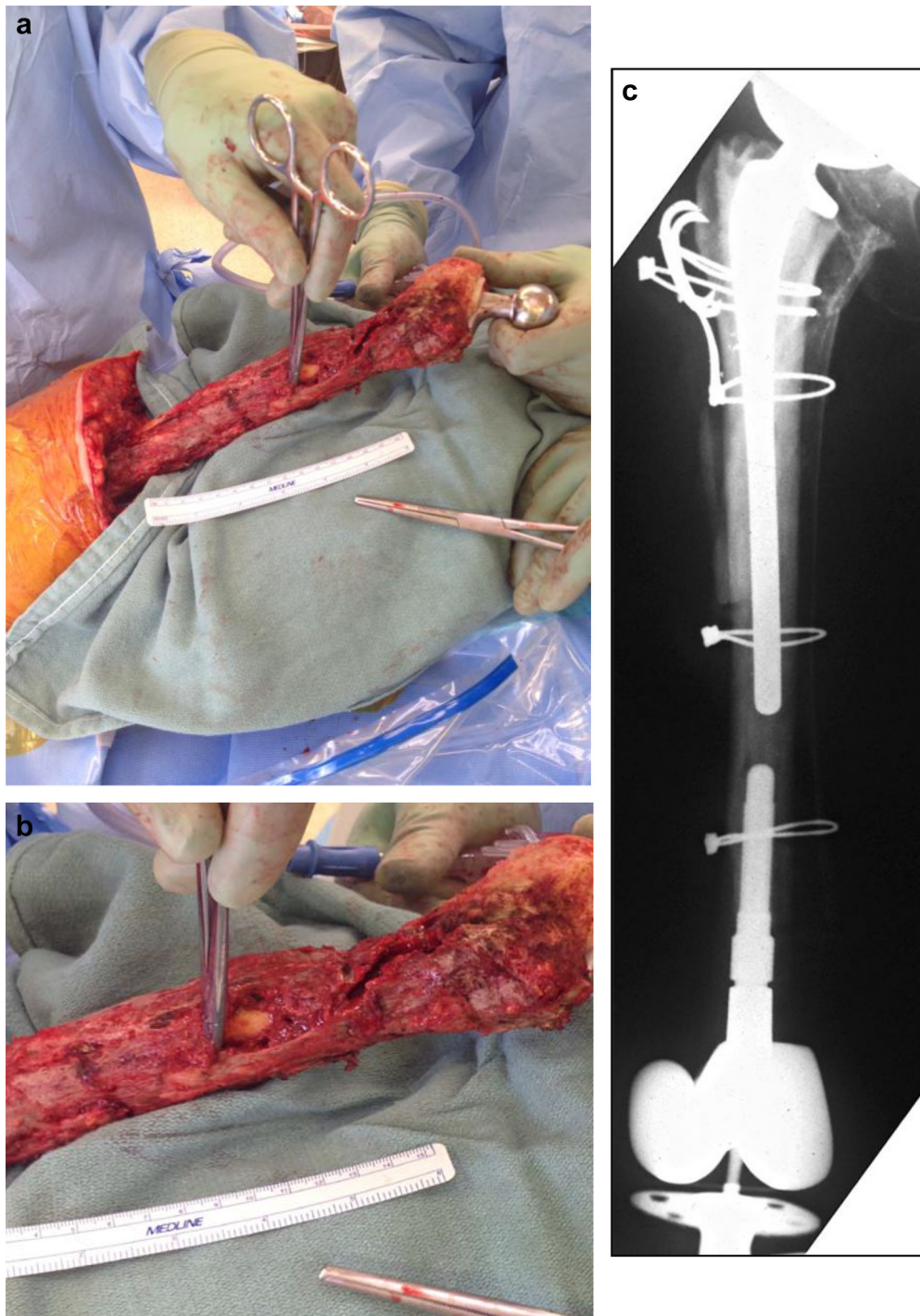


Figure 3. Intra-operative photographs (a and b) and AP radiograph of composite allograft (c). The surgical tool in the photographs is pointing to the sinus tract between the allograft and host bone noted during hip disarticulation.

entire femoral allograft, and two osteoarticular allografts. The entire femoral allograft had low functional scores due to walking limitations, but pain was not a limiting factor for this patient. Four allografts did have fractures, and with 3 going on to healing and retained a good functional status post-intervention. Otherwise, MTSS functional scores averaged 82% and this study showed potential longevity up to 36 years in these patients [8].

Jones et al. reviewed 54 total femoral replacements from 3 institutional databases with a very thorough functional score

analysis. The analysis included 41 fixed bearing knees, 13 rotating hinge knees, 37 hip hemiarthroplasties, and 17 total hip arthroplasties. The functional scores from the 54 TFRs were compared to patients with proximal femoral replacements ($n = 31$) and distal femoral replacements ($n = 85$). Toronto Extremity Salvage Scores were utilized for functional analysis. There was no significant difference in rotating platform versus fixed bearing TKA or in hemiarthroplasty versus total hip replacement patients. The functional scores of the TFRs were significantly less than those of the PFRs and

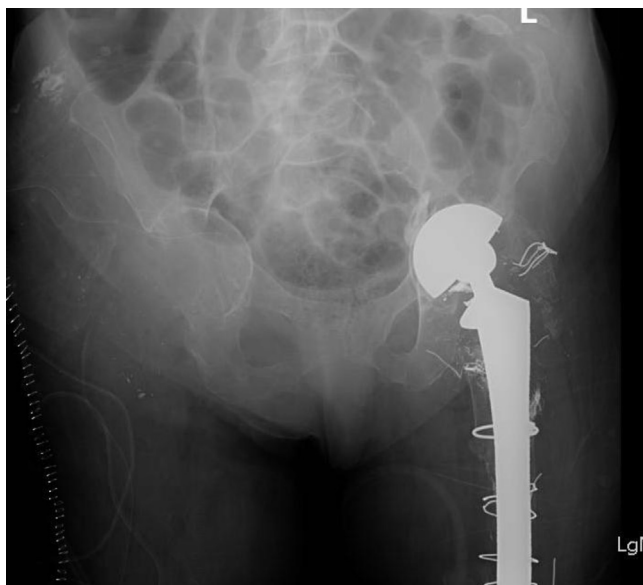


Figure 4. Post-operative AP radiograph following right hip disarticulation.

the DFRs both. Additionally, mechanical complications noted were 5 hip dislocations, 4 of which were noted to be due to abductor deficiency on surgical re-evaluation [9].

Haddad et al. performed a review of proximal femur allografts, but not entire femoral allografts, and raised several good points that bear mentioning. There are noted advantages and disadvantages for using allografts in these patients. The ability of allografts to incorporate with host bone and allow for soft tissue attachment may enhance stability in these patients, improving function and satisfaction. The disadvantages also have to be considered, however, which include the potential for disease transmission, immune response, graft resorption, and the length of time required for graft-host union. Unrestricted weight bearing may not be allowed for 3–6 months depending on graft incorporation. If weight bearing is attempted early, the risk of loosening increases if in-growth has not been achieved. Additionally, there may be a need for bracing post-op to allow soft tissue healing and to enhance stability. Haddad et al. also noted infection rates in proximal femoral allografts alone can be as high as 4%–13% [10].

Summary

In conclusion, despite the advancement of engineering and technology, the total femoral allograft remains a valid treatment

option in the patients with ipsilateral hip and knee bone loss who require revision. The longevity of these constructs can last over 30 years in the medically appropriate candidate [8]. There is some evidence showing this method, due to soft tissue healing potential, may enhance abductor functioning and alleviate limp in some patients, as compared to some megaprosthesis designs that do not facilitate greater trochanter capture [7]. Infection rate is always a concern, with reported rates between 6% and 35% [4–8]. Our patient had a history of severe rheumatoid arthritis, which may have lead to her long prosthetic survival with low functional demands, however it may have contributed to her infection with immune system compromise allowing for seeding of her prosthesis during systemic bacteremia. Her risk also was substantially elevated secondary to the number of procedures she had on her right lower extremity, hip and knee, before the allograft was placed. Four hip procedures (primary THA plus 3 revisions) and three knee procedures (ORIF times two and then primary TKA) were noted before the allograft was placed and would have increased her chances of acquiring infection during every intervention. However, the functional benefits she achieved over the 17 years since her procedure, combined with the literature review of similar procedures outcomes, allow this treatment to be considered an acceptable alternative to reconstruction with total femur replacement.

References

- [1] Urch SE, Moskal JT. Simultaneous ipsilateral revision total hip arthroplasty and revision total knee arthroplasty with entire femoral allograft: case report. *J Arthroplasty* 1998;13:833.
- [2] Lexer E. Substitution of whole or half joints from freshly amputated extremities by free plastic operations. *Surg Gynecol Obstet* 1908;6:601.
- [3] Buchman J. Total femur and knee joint replacement with a vitallium endoprosthesis. *Bull Hosp Joint Dis* 1965;26:21.
- [4] Ruggieri P, Bosco G, Pala E, Errani C, Mercuri M. Local recurrence, survival and function after total femur resection and megaprosthesis reconstruction for bone sarcomas. *Clin Orthop Relat Res* 2010;468:2860.
- [5] Amanatullah DF, Trousdale RT, Hanssen AD, Lewallen DG, Taunton MJ. Non-oncologic total femoral arthroplasty: retrospective review. *J Arthroplasty* 2014;29(10):2013.
- [6] Puri A, Gulia A, Chan WH. Functional and oncologic outcomes after excision of the total femur in primary bone tumors: results with a low cost total femur prosthesis. *Indian J Orthop* 2012 Jul–Aug;46:470.
- [7] Mankin HJ, Hornicek FJ, Harris M. Total femur replacement procedures in tumor treatment. *Clin Orthop Relat Res* 2005;438:60.
- [8] Muscolo DL, Petracchi LJ, Ayerza MA, Calabrese ME. Massive femoral allografts followed for 22 to 36 years. Report of six cases. *J Bone Joint Surg Br* 1992;74-B(6):887.
- [9] Jones J, Griffin AM, Coonoor RC, et al. Patient-oriented functional results of total femoral endoprosthesis reconstruction following oncologic resection. *J Surg Oncol* 2011 Nov 1;104(6):561.
- [10] Haddad FS, Garbuz DS, Masri BA, et al. Femoral bone loss in patients managed with revision hip replacement: results of circumferential allograft replacement. *J Bone Joint Surg* 1999;81-A(3):420.