

Robotic-Assisted Laparoscopic Extravesical Ureteroneocystostomy for Management of Adult Ureteral Duplication With Upper Pole Prostatic Urethral Insertion

Jeffrey A. Larson, MD, Jeffrey J. Tomaszewski, MD,
Marc C. Smaldone, MD, Stephen V. Jackman, MD

ABSTRACT

A 55-year-old male presented with progressive lower urinary tract symptoms and renal colic. The workup revealed a complete left ureteral duplication with a hydronephrotic upper pole moiety inserting into the prostatic urethra. Using a 5-port transperitoneal robotic-assisted laparoscopic technique, an extravesical upper pole ureteroneocystostomy was performed. Clinical follow-up and repeat imaging documented symptomatic and radiographic improvement. Robotic-assisted laparoscopic reconstructive techniques are feasible and efficacious in the management of adult ureteral anomalies.

Key Words: Robotic-assisted, Laparoscopy, Ureteral duplication, Ectopia.

INTRODUCTION

Complete ureteral duplication with ectopic prostatic urethral insertion is rarely described in adult patients. With the advent of prenatal ultrasound, duplication anomalies are commonly diagnosed and corrected in childhood. The use of robotic-assisted laparoscopic techniques for ureteral reconstruction have been well described in the pediatric population, but there are few such reports for adults. The use of a robotic platform offers potential advantages over traditional laparoscopic techniques, most notably increased manual dexterity facilitating more efficient intracorporeal suturing. We present a case of an adult male presenting with a symptomatic obstruction of an ectopic upper pole moiety inserting into the prostatic urethra managed with robotic-assisted laparoscopic extravesical ureteroneocystostomy.

CASE REPORT

A 55-year-old male presented with progressive obstructive urinary symptoms and was diagnosed with prostatitis by an outside urologist. Despite antibiotic and alpha-blocker therapy, his symptoms failed to improve, and he acutely presented to the emergency department with left-sided renal colic, nausea, and vomiting. A noncontrast computed tomographic (CT) scan of the abdomen and pelvis revealed a complete duplication of the left collecting system with a 7-mm distal ureteral stone obstructing the upper pole moiety. Initial attempts at retrograde endoscopic therapy were unsuccessful due to the inability to identify or access the upper pole ureter requiring acute percutaneous nephrostomy drainage. Antegrade placement of a wire identified the upper pole ureteral orifice at the level of the verumontanum, and the patient's stone was successfully treated with rigid ureteroscopy and laser lithotripsy. Three months after ureteral stent removal, the patient still reported significant lower urinary tract symptoms, and repeat imaging revealed a persistently dilated left upper pole collecting system despite resolution of his stone burden with functional upper pole renal parenchyma (**Figure 1**).

At this point, the patient was referred to our practice for surgical management of his left-sided ureteral duplication

Department of Urology, University of Pittsburgh School of Medicine, Pittsburgh, Pennsylvania, USA (all authors).

Address reprint requests to: Jeffrey A. Larson, MD, Department of Urology, University of Pittsburgh School of Medicine, Suite 700, 3471 Fifth Avenue, Pittsburgh, PA 15213, USA. E-mail: larsonja2@upmc.edu

© 2009 by JSL, *Journal of the Society of Laparoendoscopic Surgeons*. Published by the Society of Laparoendoscopic Surgeons, Inc.

anomaly. The patient's medical and surgical history was notable for a remote laparoscopic cholecystectomy. Digital rectal examination revealed a normal 20-gm prostate, and a dilated upper pole ureteral prostatic insertion point was not palpable. His urine culture was negative, his creatinine was 1.1mg/dL, and his prostate specific antigen was 2.3 ng/mL. A functional renal evaluation was deferred due to adequate renal parenchyma visualized on CT scan. The surgical options discussed included ureteroneocystostomy by open or minimally invasive methods, pyeloureterostomy, or upper pole nephrectomy. The patient decided to proceed with robotic-assisted laparoscopic ureteroneocystostomy as definitive therapy.

The patient was placed in the low dorsal lithotomy position. Rigid cystoscopy failed to reveal the upper pole ureteral orifice in the prostatic urethra, despite careful inspection. The left lower pole ureteral orifice was visu-

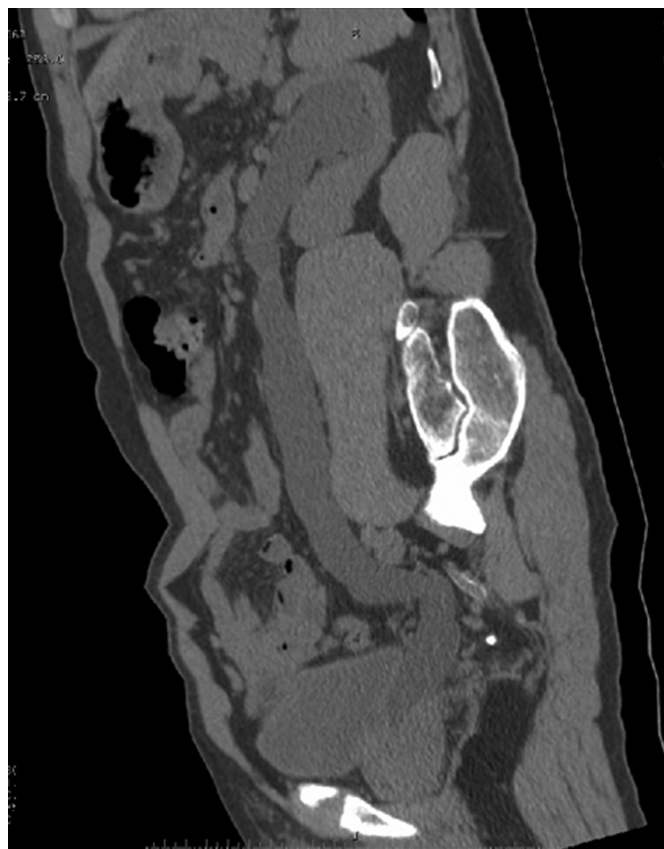

Figure 1. Sagittal reconstructed computed tomography images, demonstrating a left duplicated collecting system. Of note, there is a hydronephrotic upper pole with preserved renal parenchyma and a dilated ureter to the level of its ectopic insertion into the prostatic urethra.

alized in the orthotopic position and was cannulated with a lighted external stent. A 12-mm camera port was placed through a VisiPort 1cm above the umbilicus in the midline. Two additional 8-mm robotic working ports were placed in the lower abdomen lateral to the rectus muscle. A 5-mm step port was placed at the Verress needle entry site in the left upper quadrant as well as an additional 5-mm step port in the left lower quadrant 2cm above the left anterior-inferior iliac spine.

The white line of Toldt was incised and the left colon was reflected, exposing the external and common iliac arteries and revealing the dilated upper pole ureter running anterior to the lower pole ureter that was clearly identified by the previously placed lighted stent. The upper pole ureter was dissected distally towards the bladder, leaving the posterolateral half of its attachments in place for good blood supply. The upper pole ureter was transected near the level of the bladder. The decision was made intraoperatively not to excise the distal ureteral stump, which was left open. Flexible cystoscopy was performed and scissors were used to cut through the left posterolateral bladder wall while maintaining direct cystoscopic vision. A wire was cystoscopically placed through the cystotomy into the peritoneal cavity. A running anastomosis was performed using two 3–0 Monocryl sutures tied together from 6 to 12 o'clock (**Figure 2**). The wire was fed into the ureter and guided to the level of the renal pelvis and an 8 Fr x 26-cm ureteral stent was passed over the wire under direct vision before conclusion of the anastomosis. The bladder was

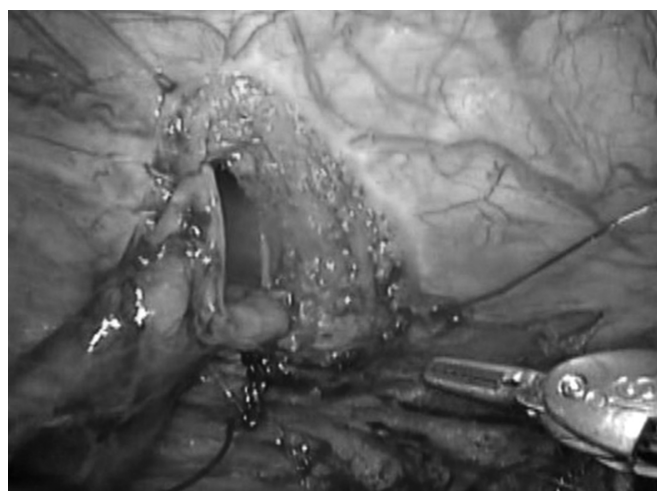


Figure 2. Intraoperative photograph demonstrating an incomplete uretero-vesical anastomosis. A guidewire was passed through a posterolateral cystotomy via flexible cystoscope and a running ureterovesical anastomosis was performed using two 3–0 Monocryl sutures tied together from 6 to 12 o'clock.

inflated to 400cc of saline without evidence of leakage or ureteral kinking. A 7-mm Blake drain was placed in the vicinity of the ureterovesical anastomosis and an 18Fr Foley catheter was left to gravity drainage.

The estimated blood loss was less than 20cc, and the total robotic time was 120 minutes. The patient was discharged home without complaint on postoperative day 2. A follow-up voiding cysturethrogram obtained one week postoperatively demonstrated no evidence of extravasation from the anastomosis or the residual ureteral stump (**Figure 3**), and the Foley catheter was removed. At his 3-month postoperative visit, the patient's voiding symptoms had improved, he had no evidence of flank pain, and his hydronephrosis had resolved on intravenous pyelogram (**Figure 4**).

DISCUSSION

The diagnosis of ureteral anomalies during adulthood are uncommon and are most often incidental findings on routine imaging studies. However, the presenting complaints in symptomatic patients are often determined by the location of the distal ureteral implantation site. In women, the most frequent complaints are of chronic urinary tract infections and irritative voiding symptoms. In men, presenting symptoms range from irritative voiding symptoms to recurrent epididymitis/prostatitis, related to ectopic insertion into the seminal vesicles, ejaculatory ducts, or prostatic utricle.

Surgical management of ureteral duplication anomalies has traditionally consisted of open techniques including nephroureterectomy, ureteroneocystostomy, ureteroureterostomy, or ipsilateral pyeloureterostomy. However, both pure laparoscopic and robotic-assisted laparoscopic techniques for ureteral reconstruction have recently been

described in both pediatric and adult populations for vesicoureteral reflux (VUR), ureteropelvic junction obstruction, and ureteral stricture disease. Potential advantages of robotic-assisted techniques in reconstructive surgery compared with conventional laparoscopy include an enhanced ability to perform precise intracorporeal suturing, increased manual dexterity, and enhanced stereoscopic visualization offering true depth-of-field vision, while the chief deterrents are increased cost and lack of tactile feedback. Despite the benefits of the robotic platform, upper and lower urinary tract reconstruction is certainly feasible utilizing pure laparoscopic techniques and has been reported by high volume centers proficient with intracorporeal suturing.

There are scattered case reports describing the minimally invasive management of complete ureteral duplication with prostatic urethral insertion in adult patients. Pinggera et al¹⁰ described a 54-year-old male presenting with paravertebral pain and recurrent prostatitis who was found to have right ureteral duplication with prostatic urethral insertion managed successfully with pure laparoscopic ureteropyelostomy and distal ureterectomy. Duchene et al

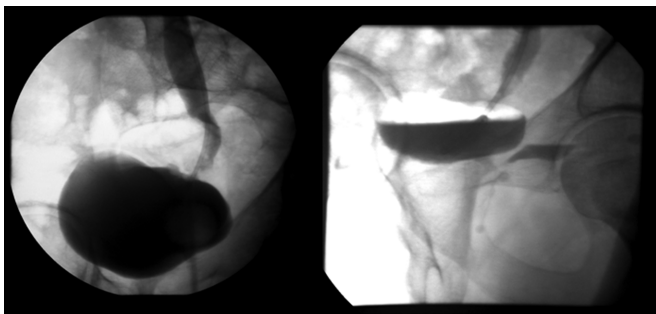


Figure 3. Voiding cystourethrogram obtained on postoperative day number 7 demonstrating no evidence of extravasation from the ureterovesical anastomosis with the ureteral stent in place (a) or the distal ureteral stump on the postvoid film (b).

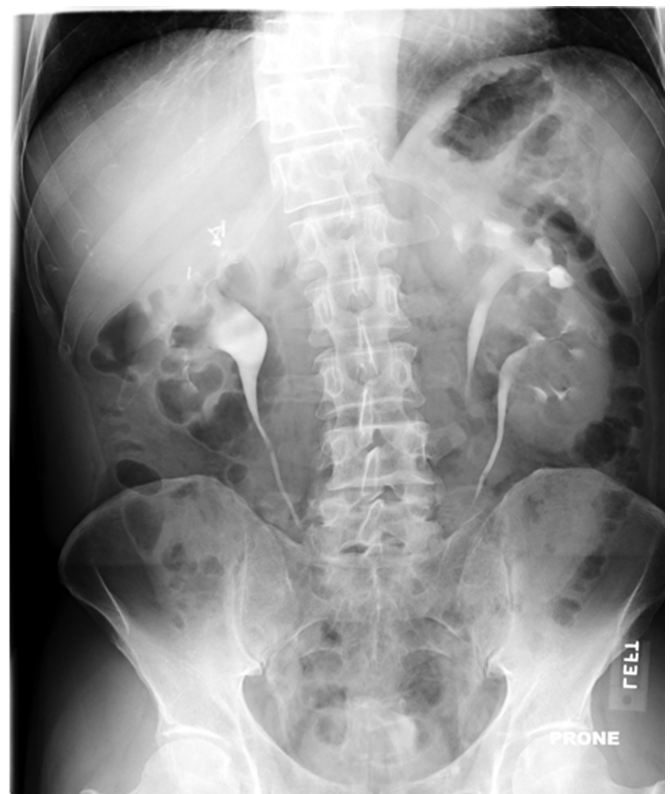

Figure 4. Intravenous pyelogram obtained 3 months postoperatively, demonstrating resolution of hydronephrosis.

reported a 52-year-old male presenting with recurrent prostatitis and hematuria who was found to have a left upper pole ectopic ureter inserting distal to the bladder neck. This patient was managed with a robotic-assisted laparoscopic ureteropyelostomy in which the distal ureter was clipped but not excised.

We feel that worsening lower urinary tract symptoms and development of upper pole moiety hydronephrosis in our patient was a progressive change from age-related prostate growth and worsening ectopic ureteral obstruction. On abdominal CT, his upper pole moiety still had significant parenchyma despite a chronically dilated collecting system. In a known stone former, upper pole ureteroneocystostomy rather than ipsilateral pyeloureterostomy was the preferred approach to decrease future risk of simultaneous upper and lower pole obstruction by a ureteral calculus. Distal ureterectomy was avoided to minimize prostatic dissection and associated pelvic nerve or urinary sphincter trauma. At 3-month follow-up, the patient was asymptomatic and on repeat radiologic imaging his hydronephrosis has resolved.

CONCLUSION

Ureteral duplication with ectopic insertion into the prostatic urethra is a diagnosis rarely made in adult patients. To our knowledge, this is the first such case managed with robotic-assisted laparoscopic extravesical ureteroneocystostomy. Application of the robotic platform is a safe and feasible approach in adult patients with ureteral duplication anomalies and adds to the growing armamentarium of minimally invasive options for urologic reconstructive surgery.

References:

1. Albers P, Foster RS, Bihle R, Adams MC, Keating MA. Ectopic ureters and ureterocele in adults. *Urology*. 1995;45(5):870–874.

2. Kutikov A, Nguyen M, Guzzo T, Canter D, Casale P. Laparoscopic and robotic complex upper-tract reconstruction in children with a duplex collecting system. *J Endourol*. 2007;21(6):621–624.
3. Mufarrij PW, Shah OD, Berger AD, Stifelman MD. Robotic reconstruction of the upper urinary tract. *J Urol*. 2007;178(5):2002–2005.
4. Prieto Ugidos N, Marana Fernandez M, Escobal Tamayo V, Pereira Arias JC, Bernuy Malfaz C. [Ectopic ureter in prostatic urethra. Unusual discovery in an adult]. *Arch Esp Urol*. 1995;48(8):843–846. Spanish.
5. Caldamone AA. Duplication anomalies of the upper tract in infants and children. *Urol Clin North Am*. 1985;12(1):75–91.
6. Casale P, Patel RP, Kolon TF. Nerve sparing robotic extravesical ureteral reimplantation. *J Urol*. 179(5):1987–1989, 2008; discussion 1990.
7. Weise ES, Winfield HN. Robotic computer-assisted pyeloplasty versus conventional laparoscopic pyeloplasty. *J Endourol*. 2006;20(10):813–819.
8. Patil NN, Mottrie A, Sundaram B, Patel VR. Robotic-assisted laparoscopic ureteral reimplantation with psoas hitch: a multi-institutional, multinational evaluation. *Urology*. 2008;72(1):47–50; discussion 50. Epub 2008 Apr 2.
9. Rassweiler JJ, Gozen AS, Erdogru T, Sugiono M, Teber D. Ureteral reimplantation for management of ureteral strictures: a retrospective comparison of laparoscopic and open techniques. *Eur Urol*. 51(2):512–22, 2007; discussion 522–523.
10. Pinggera GM, Mitterberger M, Pallwein L, et al. Case report: laparoscopic ureteropyelostomy and distal ureterectomy for management of duplication with ectopia. *J Endourol*. 2007;21(6):614–617.
11. Duchene DA, Thiel DD, Winfield HN. Robotic-assisted laparoscopic ureteropyelostomy for treatment of prostatitis secondary to ectopic ureteral insertion of a completely duplicated collecting system. *J Endourol*. 2007;21(5):455–457.