

[CASE REPORT]

New-onset Takayasu's Arteritis as Acute Myocardial Infarction

Yusuke Ishiyama, Kazuo Eguchi, Katsuaki Yokota, Tomokazu Ikemoto and Kazuomi Kario

Abstract:

We herein report the case of a 25-year-old Japanese woman with left-main-trunk acute myocardial infarction (LMT-AMI). She had cardiogenic shock, so emergency percutaneous intervention was performed. Intravascular ultrasound of LMT-AMI showed that the three-layered structure of the intima, tunica media, and adventitia was not clearly visible, and the vessel was concentrically thickened; unstable plaque and calcification were not seen. AMI is rarely seen in young women, but Takayasu's arteritis is one major cause. If a young woman complaining of typical chest pain as acute coronary syndrome is encountered, systemic diseases must be considered.

Key words: acute myocardial infarction, Takayasu's arteritis, young woman, chest pain, cardiogenic shock

(Intern Med 57: 1415-1420, 2018)

(DOI: 10.2169/internalmedicine.9690-17)

Introduction

The prevalence of juvenile-onset acute myocardial infarction (AMI) has been increasing due to the increasing exposure to coronary risk factors, such as smoking, diabetes mellitus and familial hypercholesterolemia. The reported incidence of AMI in patients <45 years of age was 2-6% in the 1980s (1) and 4-10% in the 1990s (2, 3). Classic coronary risk factors are not commonly seen in young women, and relatively uncommon causes, such as congenital heart disease, Kawasaki disease, vasculitis syndrome, and hemostatic abnormalities are considered (4-6). Among them, Takayasu's arteritis is an uncommon disease. The incidence of new cases of Takayasu's arteritis is 1-3/million person-years in the United States and Europe (7), but these cases can have a dramatic clinical presentation and are sometimes fatal.

We encountered a patient with new-onset Takayasu's arteritis who presented with a left-main-trunk (LMT) AMI. She was successfully treated with emergent coronary intervention and steroid therapy.

Case Report

A 25-year-old Japanese woman was referred to our hospi-

tal with severe chest pain and consciousness disturbance. She had no known history of heart disease or other chronic diseases, including connective tissue diseases, nor any medication or smoking histories.

From four days before the hospitalization, she began to feel chest pain on exercise, and it gradually worsened, sometimes accompanied by cold sweat. Several hours prior to her visit to our hospital, she felt severe chest pain with cold sweat and was taken to a nearby clinic. She fainted in the waiting room and was transferred to a nearby general hospital. Electrocardiogram showed marked ST-T changes (Fig. 1a). On echocardiography, the wall motion of the left ventricle was diffusely reduced, but the motion of only the basal inferior wall was preserved. Thus, severe myocardial ischemia due to LMT lesions was suspected, and she was transferred to our hospital.

On admission, her consciousness was Glasgow Coma Scale E1V1M5, and her blood pressure and percutaneous oxygen saturation could not be measured. The heart rate was 113 beats/min, irregular; the jugular vein was dilated; and a coarse crackle was audible in her chest, but no abnormal heart sounds or murmurs were audible. No edema was detected in her extremities.

As shown in Table 1, elevations in the white blood cell count and levels of aspartate aminotransferase, lactate dehy-

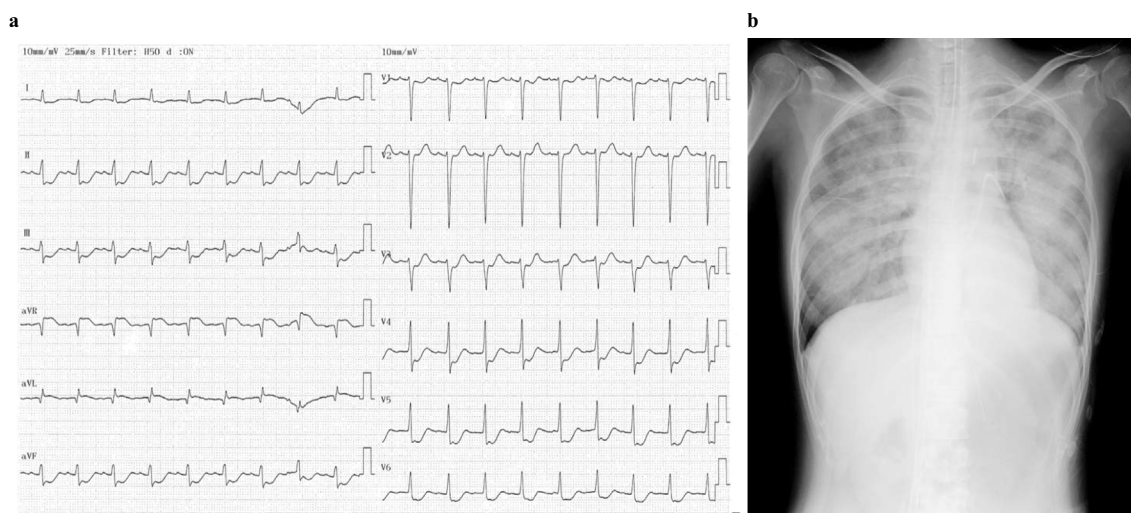


Figure 1. a: 12-lead electrocardiogram showed ST elevation in the aVR lead and extensive ST depression in the other leads. b: Chest X-ray on admission showed pulmonary congestion.

Table 1. Laboratory Findings.

WBC	19,400 / μ L	CRP	8.18 mg/dL
Hemoglobin	12.5 g/dL	Total protein	8.8 g/dL
Platelets	56.7 $\times 10^3/\mu$ L	Albumin	2.9 g/dL
PT-INR	1.17	BUN	15.0 mg/dL
APTT	36.8 sec	Creatinine	0.56 mg/dL
FDP	9.9 μ g/mL	Uric acid	6.5 mg/dL
Fibrinogen	704 mg/dL	Total bilirubin	0.44 mg/dL
D dimer	4.2 μ g/mL	AST	75 IU/L
ANA	80 times	ALT	14 IU/L
dsDNA antibody	8.4 IU/mL	LDH	417 IU/L
C3	91 mg/dL	γ -GT	31 IU/L
C4	40 mg/dL	Creatine kinase	1,100 IU/L
CH50	46.9 IU/mL	CK-MB	89 IU/L
Anti cardiolipin IgG	<8.0	Sodium	136 mmol/L
CL β 2GPI antibody	<0.7	Potassium	4.9 mmol/L
MPO-ANCA	<1.3	Chloride	100 mmol/L
PR3-ANCA	<3.5	Magnesium	2.8 mg/dL
pH	7.016	Glucose	341 mg/dL
PCO ₂	81.2 Torr	Hemoglobin A1c	4.6 %
PO ₂	37.7 Torr	Total cholesterol	158 mg/dL
HCO ₃ ⁻	21 mmol/L	LDL-C	100 mg/dL
Base excess	-11.4 mmol/L	HDL-C	48 mg/dL
Anion gap	19.8 mmol/L	Triglycerides	47 mg/dL
Lactate	10.3 mmol/L		

ALT: alanine aminotransferase, ANA: antinuclear antibody, APTT: activated partial thromboplastin time, AST: aspartate aminotransferase, BUN: blood urea nitrogen, CK-MB: Creatine kinase-muscular brain type, CL β 2GPI: cardiolipin β glycoprotein I, CRP: C-reactive protein, dsDNA: double stranded deoxyribonucleic acid, FDP: fibrin degradation product, γ -GT: γ -glutamyl transferase, HDL-C: high-density lipoprotein cholesterol, LDH: lactate dehydrogenase, LDL-C: low-density lipoprotein cholesterol, MPO-ANCA: myeloperoxidase-anti-neutrophil cytoplasmic antibodies, PR3-ANCA: proteinase-3-anti-neutrophil cytoplasmic antibodies, PT-INR: prothrombin time-international ratio, WBC: white blood cell

drogenase, creatine kinase (CK), CK-muscular brain type, and troponin T were present, but other laboratory values were within normal ranges. IgG4 was not measured. A

blood gas analysis showed lactic acidosis, and several inflammatory markers were elevated, but the measured antibodies were all within normal ranges. Chest X-ray showed

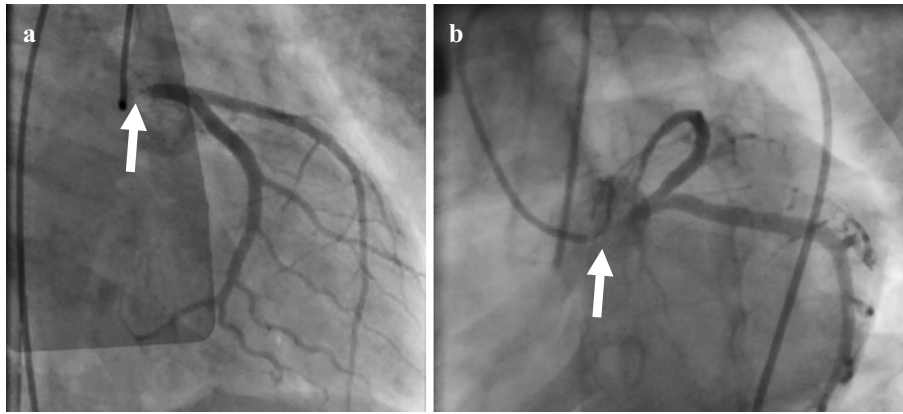


Figure 2. Coronary angiography showed 99% stenosis in the left main trunk. a: Right anterior oblique view. b: Left caudal view

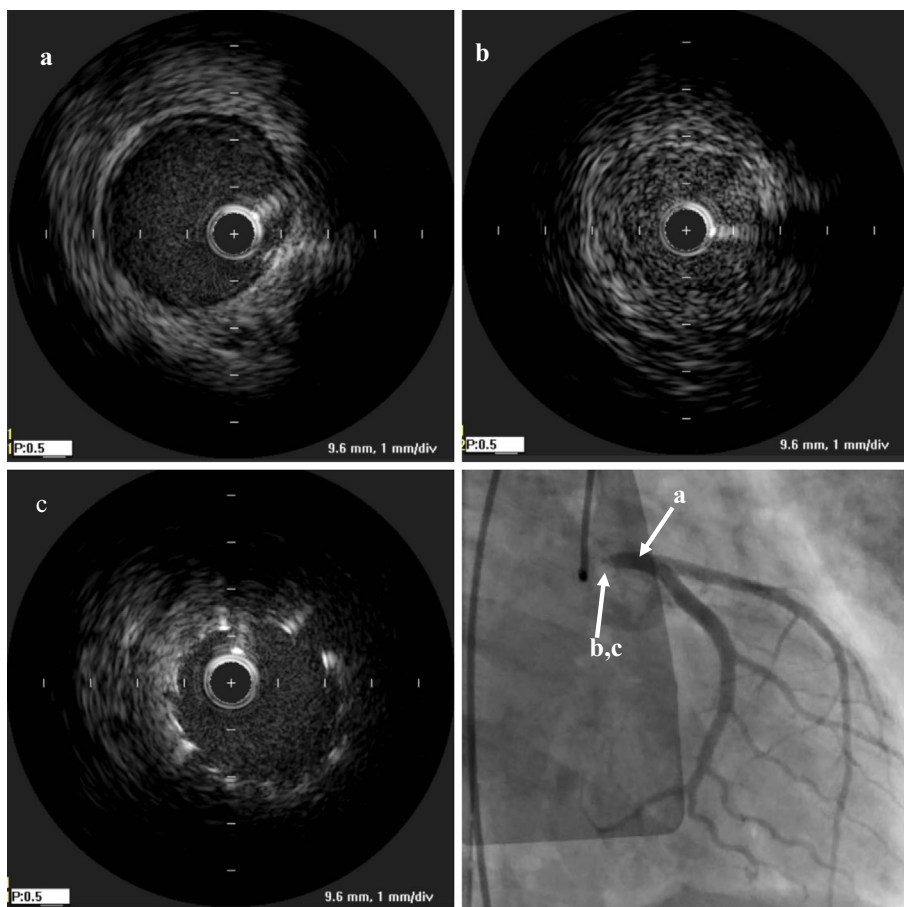


Figure 3. Intravascular ultrasound showed (a) intact lesion of LMT, (b) the three-layered structure of the intima, tunica media, and adventitia was unclear and concentrically thickened in LMT. (c) Post-stenting

pulmonary congestion (Fig. 1b).

Because of cardiogenic shock with pulseless electrical activity and ventricular tachycardia, cardiopulmonary resuscitation was initiated. After the insertion of venoarterial extracorporeal membrane oxygenation (VA-ECMO), we performed coronary angiography, and it showed 99% stenosis at the LMT (Fig. 2). Intravascular ultrasound (IVUS; Opti-Cross, Boston Scientific, Fremont, USA) showed that there

was no calcification and that the three-layered structure of the intima, tunica media, and adventitia was unclear and concentrically thickened (Fig. 3).

After percutaneous transluminal coronary angioplasty was performed, a bare metal stent (3.5 mm×12 mm) was successfully placed (Fig. 3c), and thrombolysis in myocardial infarction grade 3 flow was obtained. We applied intra-aortic balloon pumping (IABP), and the patient was transferred to

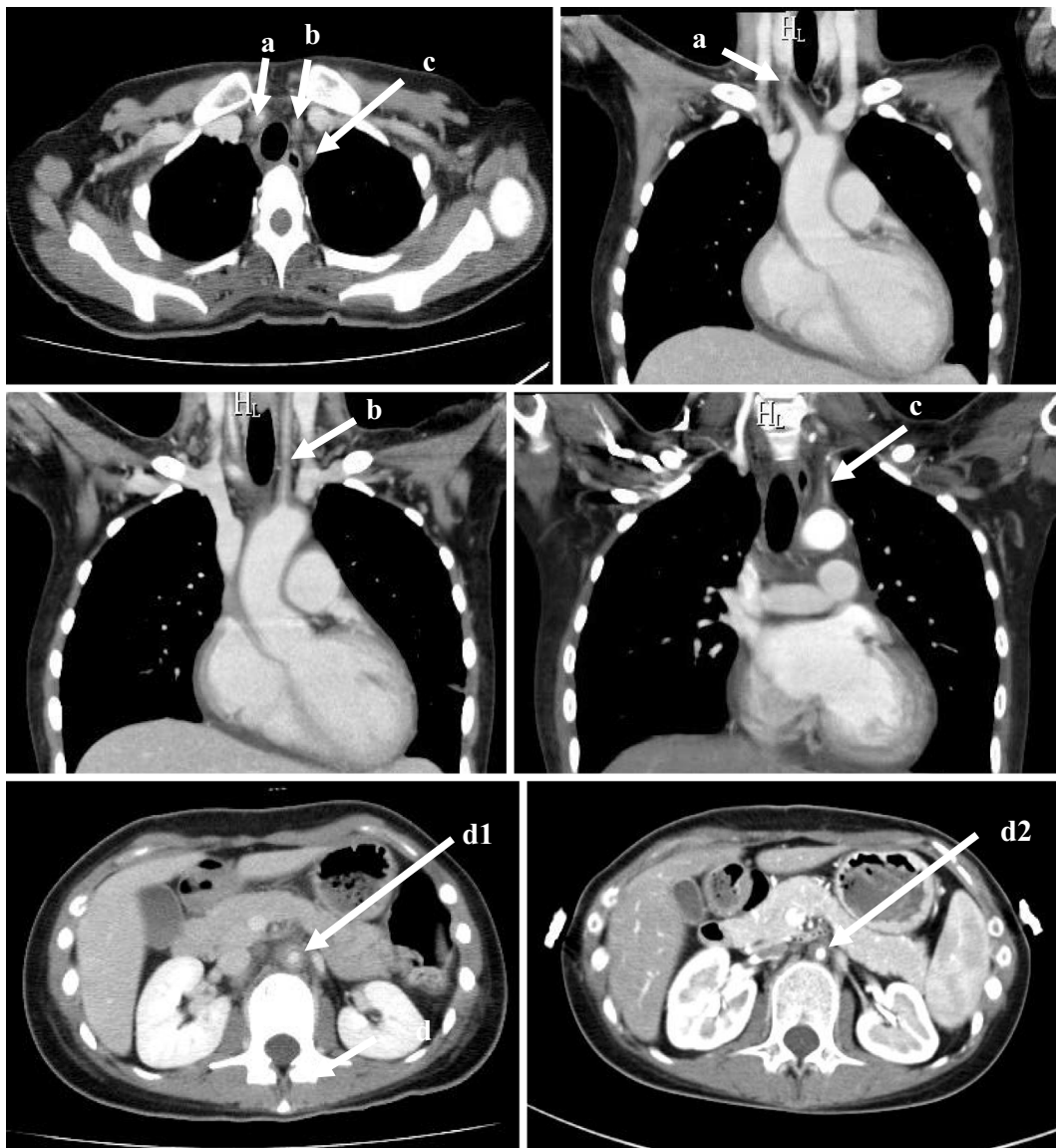


Figure 4. Computed tomography showed wall thickening and narrowing in the right brachiocephalic artery (a), left common carotid artery (b), left subclavian artery (c), abdominal aorta under the branch of renal artery (d1), and abdominal aorta at the 4th months from the start of prednisolone (d2). The vascular wall thickening improved.

the coronary care unit. The maximum value of CK was 9,770 IU/L, and the VA-ECMO and IABP were withdrawn on the 3rd and 8th hospital days, respectively. Regarding the diagnosis of Takayasu's arteritis, based on the American College of Rheumatology 1990 criteria for the classification of Takayasu's arteritis (7), four of the six diagnostic criteria of Takayasu's arteritis (less than 40 years of age, pulse weakness of the brachial artery, vascular murmur at the subclavian artery or aorta, abnormality of arteriography) were met in this case (Fig. 4). In addition, based on the Japanese Circulation Society 2008 criteria for the diagnosis of Takayasu's arteritis, the diagnosis of Takayasu's arteritis was definite: computed tomography showed multiple vascular wall thickening and stenosis in the aorta and its first branch, and C-reactive protein (CRP) was high at the time of the visit. Differential diagnoses, such as atherosclerosis, inflam-

matory aneurysm, and giant cell arteritis, were completely ruled out.

We started prednisolone at the 43rd hospital day. At this point, ^{18}F -fluorodeoxyglucose positron emission tomography (FDG-PET) revealed weak positivity, and the CRP decreased to 0.68 mg/dL (8.18 mg/dL at the emergency room); the erythrocyte sedimentation rate also decreased to 26 mm (44 mm at the 18th hospital day). We therefore considered that the extent of systemic inflammation was weak, and a rheumatologist advised us to start low-dose prednisolone at 10 mg/day. The patient was released from the hospital on the 67th hospital day.

Discussion

We encountered a patient with Takayasu's arteritis who

Table 2. Case Reports of Takayasu's Arteritis Developed as Acute Myocardial Infarction.

Reference	Age(yrs), Sex	Lesion	CK (IU/L)
9	23, F	LAD aneurysm	911 (admission)
10	55, M	RCA middle	n.a.
11	22, F	LMT	n.a.
12	16, F	RCA ostium+LMT	6,748 (max)
13	19, M	RCA proximal aneurysm	1,524 (admission)
14	39, F	RCA ostium	n.a.
15	17, M	RCA middle	n.a.

M: Male, F: Female, LAD: left anterior descending artery, RCA: right coronary artery, LMT: left main trunk, n.a.: not available

presented with AMI due to LMT occlusion. She recovered with intensive therapy including emergent percutaneous coronary intervention. This case contains several important clinical messages about juvenile-onset AMI.

AMI in the young is extremely rare. It is reported that the incidence of AMI in those younger than 40 years of age is only about 5% in total, and 90% of these cases are men (8). In the Framingham Study (4), the incidence of AMI in women 45-54 years of age was 0.7/1,000 person-years, and 0.2/1,000 person-years in women 35-44 years of age. The rarity of AMI in young women is due to the anti-arteriosclerotic effect of estrogen. The causes of AMI in women under 45 years of age were arteriosclerotic in 80% of cases, cardio-embolic in 5% of cases (i.e. paradoxical embolism or infective endocarditis), a hypercoagulant state in 5% of cases, congenital coronary artery abnormality in 4% of cases, and others in 6% of cases, including coronary artery spasm, coronary artery dissection, vasculitis, chest trauma, and irradiation of the mediastinum (5).

A Japanese study examined the etiology of AMI in young women (6). Among 2,457 cases of AMI, the number of women under 50 years of age was 24, and 10 of these cases were non-atherosclerotic on angiography; only 3 cases had Takayasu's arteritis. In the same study, there were 251 men under 50 years of age with AMI, and a non-atherosclerotic etiology was noted in only 1 case of embolism. Although it is rare, AMI can occur in young women, and rigorous surveys for systemic causes are essential.

In the present case, the patient fell into a very severe condition and was rescued by intensive treatments. We ruled out other causes of cardiogenic shock, such as cardiac rupture, mitral chordal rupture, and ventricular septal perforation. There were no potential causes of the shock other than AMI at the LMT lesion. The early detection and diagnosis of Takayasu's arteritis before progression to such a severe condition are important. Regarding the initial symptoms of Takayasu's arteritis, a fever (17.1%) is most common, followed by dizziness (12.9%), pulse deficit (11.2%), and general malaise (7.8%), but angina pectoris (2.8%) is uncommon. Ischemic heart disease occurs in 10.7% of Takayasu's arteritis cases during the entire course, but cases diagnosed by the presentation as AMI have been reported as case re-

ports (Table 2) (9-15).

Coronary artery lesions are present in 70-80% of Takayasu's arteritis cases, as pathologically, the inflammatory process extends to the intima and proliferates, which contracts the fibrotic media and adventitia from the ascending aorta (16, 17). Especially in the active phase of Takayasu's arteritis, increases in a thrombotic tendency due to endothelial dysfunction, platelet aggregation, and coagulation activity (18-20) contribute to the development of AMI. Therefore, percutaneous coronary intervention combined with steroid therapy is effective for preventing restenosis (21). However, in the present case, Takayasu's arteritis was not in the very active phase, as FDG-PET showed only a weak uptake at the LMT.

Only one IVUS finding of LMT of effort angina due to Takayasu's arteritis has been reported (22), and LMT-AMI has never been reported as a cause, to our knowledge. In the present case, unstable plaque and calcification were not seen, but the three-layered structure of the intima, tunica media, and adventitia was not clearly visible, and the vessel was concentrically thickened (Fig. 3). Therefore, the pathophysiological mechanism of LMT-AMI in this case is not plaque rupture but concentric narrowing of the vessel itself.

In conclusion, in young women who complain of chest pain, a specific cause of coronary artery disease may exist, and systemic causes of vascular diseases, including Takayasu's arteritis, should be considered.

The authors state that they have no Conflict of Interest (COI).

References

1. Jalowiec DA, Hill JA. Myocardial infarction in the young and in women. *Cardiovasc Clin* **20**: 197-206, 1998.
2. Fournier JA, Sánchez A, Quero J, Fernández-Cortacero JA, González-Barrero A, et al. Myocardial infarction in men aged 40 years or less: a prospective clinical angiographic study. *Clin Cardiol* **19**: 631-636, 1996.
3. Doughty M, Mehta R, Bruckman D, et al. Acute myocardial infarction in the young-the university of Michigan experience. *Am Heart J* **143**: 56-62, 2002.
4. Lerner DJ, Kannel WB. Patterns of coronary heart disease morbidity and mortality in the sexes: A 26-year follow-up of the Fram-

- ingham population. *Am Heart J* **111**: 383-390, 1986.
5. Lubna C, James DM. Myocardial infarction in young patients. *Am J Med* **107**: 254-261, 1999.
 6. Toyofuku M, Goto Y, Matsumoto T, et al. Acute myocardial infarction in young Japanese women. *J Cardiol* **28**: 313-319, 1996 (in Japanese, Abstract in English).
 7. Arend WP, Michel BA, Bloch DA, et al. The American College of Rheumatology 1990 criteria for the classification of Takayasu arteritis. *Arthritis Rheum* **33**: 1129-1134, 1990.
 8. Hamsten A, Norberg R, Bjorkholm M, et al. Antibodies to cardiolipin in young survivors of myocardial infarction: an association with recurrent cardiovascular events. *Lancet* **327**: 113-116, 1986.
 9. Araszkiwicz A, Prech M, Hrycaj P, Lesiak M, Grajek S, Cieslinski A. Acute myocardial infarction and rapid development of coronary aneurysms in a young woman - unusual presentation of Takayasu arteritis? *Can J Cardiol* **23**: 61-63, 2007.
 10. Miyagawa K, Shiraishi J, Nasu M, et al. Usefulness of ultrasonography in carotid arteries and combined positron emission tomography for diagnosis of Takayasu arteritis with unusual presentation as acute myocardial infarction: a case report. *J Cardiol* **50**: 317-324, 2007.
 11. Hamdan A, Porter A, Georghiou GP, et al. Unusual presentation of Takayasu arteritis. *Int J Cardiol* **119**: 249-250, 2007.
 12. Roghi A, Pedrotti P, Milazzo A, et al. Acute myocardial infarction and cardiac arrest in atypical Takayasu aortitis in a young girl: unusual diagnostic role of cardiac magnetic resonance imaging in emergency. *Circulation* **121**: e370-e375, 2010.
 13. Ouali S, Kacem S, Fradj FB, et al. Takayasu arteritis with coronary aneurysms. *Tex Heart Inst J* **38**: 183-186, 2011.
 14. Yoshida T, Oi K, Shinohara N, Mihara A, Yokoyama K. Emergency surgery for coronary ostial occlusion and aortic root aneurysm associated with Takayasu's arteritis; report of a case. *Kyobu Geka* **66**: 1196-1198, 2013 (in Japanese, Abstract in English).
 15. Chen T, Mi J, Zhong MH, et al. Acute inferior myocardial infarction as the first manifestation of Takayasu arteritis in a young boy. *Chin Med J* **128**: 2414, 2015.
 16. Matsubara O, Kuwata T, Nemoto T, Kasuga T, Numano F. Coronary artery lesions in Takayasu arteritis - pathological considerations. *Heart Vessels* **7** (Suppl.): 26-31, 1992.
 17. Amano J, Suzuki A. Coronary artery involvement in Takayasu's arteritis. Collective review and guideline for surgical treatment. *J Thorac Cardiovasc Surg* **102**: 554-560, 1991.
 18. Akazawa H, Ikeda U, Yamamoto K, Kuroda T, Shimada K. Hypercoagulable state in patients with Takayasu's arteritis. *Thromb Haemost* **75**: 712-716, 1996.
 19. Watanabe T, Kishi Y, Numano F, Isobe M. Enhanced platelet sensitivity to prostacyclin in patients in an active stage of Takayasu arteritis. *Thromb Res* **104**: 77-83, 2001.
 20. Kasuya N, Kishi Y, Isobe M, Yoshida M, Numano F. P-selection expression, but not GPIIb/IIIa activation, is enhanced in the inflammatory stage of Takayasu's arteritis. *Circ J* **70**: 600-604, 2006.
 21. Yokota K, Shimpo M, Iwata T, et al. A case of Takayasu arteritis with repeated coronary artery restenosis after drug-eluting stent implantation successfully treated with a combination of steroids. *Intern Med* **51**: 739-743, 2012.
 22. Park H, Otani H, Yamamoto Y, et al. Percutaneous coronary intervention for left main trunk ostial stenosis in a patient with Takayasu's arteritis. *Cardiovasc Interv Ther* **26**: 70-73, 2011.

The Internal Medicine is an Open Access article distributed under the Creative Commons Attribution-NonCommercial-NoDerivatives 4.0 International License. To view the details of this license, please visit (<https://creativecommons.org/licenses/by-nc-nd/4.0/>).