

Case Report

Alloimmune haemolysis in a renal transplant recipient receiving sirolimus

Adam J. Hedley¹, Shaun Flint¹, Annabel Tuckfield², Rowan Walker¹ and Solomon Cohney¹

¹Department of Nephrology and ²Department of Haematology, Royal Melbourne Hospital, Victoria, Australia 3050

Keywords: anti-ABO antibodies; haemolytic anaemia; passenger lymphocyte syndrome; renal transplantation

Background

Anaemia commonly occurs following renal transplantation related to surgical blood loss, myelosuppression from immunosuppressive agents, antimicrobial prophylaxis and persisting renal impairment. A rare cause of anaemia after solid organ transplantation is alloimmune haemolysis due to antibodies from donor-derived lymphocytes accompanying the donor organ. We report the case of a 27-year-old patient receiving sirolimus who developed alloimmune haemolysis related to passenger lymphocytes. Although this has previously been reported in renal transplant recipients receiving a variety of immunosuppressive agents [11], to our knowledge this is the first case described in a patient receiving sirolimus.

Case

A 27-year-old male received a renal transplant from his father after 2 years on maintenance haemodialysis for end-stage renal failure due to Alport's syndrome. On Day 14 post-transplant he was re-admitted with symptomatic haemolytic anaemia.

The donor's blood group was O positive and recipient A positive with a three-antigen HLA mismatch. The donor and recipient were both CMV negative and EBV positive.

Initial immunosuppression consisted of tacrolimus (0.25 mg/kg/day), sirolimus (0.5 mg/day) and corticosteroids (methylprednisolone 500 mg at surgery followed by prednisolone 25 mg/day). The graft functioned immediately, and the recipient was discharged on Day 6 with a serum creatinine of 0.12 mmol/L and a stable haemoglobin of 88 g/L. He continued on darbepoetin 60 mcg/week,

and in the week following discharge, serum creatinine and haemoglobin remained stable (0.12–0.13 mmol/L and 88–98 g/L, respectively).

On Day 14 he presented to the emergency department with 2 days of generalized lethargy, episodic diarrhoea and 24 h of fever. He was jaundiced [serum bilirubin was 79 µmol/L (cf. 13 µmol/L 5 days prior)] with mild splenomegaly. His anaemia had worsened (Hb 77 g/L), with polychromasia and spherocytes noted on the blood film, but a normal platelet count and a total white cell count of $18.1 \times 10^9/L$. The serum creatinine was 0.14 mmol/L. Sirolimus was ceased in view of its myelosuppressive effect; he was transfused to maintain the haemoglobin >70 g/L (a total of four units), and prednisolone increased to 1 mg/kg/day. Subsequent results demonstrated an elevated lactate dehydrogenase of 944 IU/L and a lowered haptoglobin of <0.06 g/L, both consistent with haemolysis.

An immune basis for the haemolysis was supported by a positive direct antiglobulin test (DAT) with IgG antiglobulin (titre 512), and anti-A antibody was eluted from the recipient's serum and red cells. The minor ABO mismatch (recipient A and donor O) suggested that the anti-A antibodies were derived from donor lymphocytes.

The patient's condition improved and from Day 19 he remained transfusion independent with Hb >80 g/L. However, there was ongoing haemolysis (Figure 1) with persistent anti-A antibodies, and the direct antiglobulin test remained positive (unchanged titre 512) despite prednisolone 50 mg/day.

On Day 21 mycophenolate mofetil (1000 mg/day) was introduced, and over the following week, the patient's haemoglobin slowly rose to 91 g/L, whilst markers of haemolysis normalized.

Discussion

Alloimmune haemolysis attributable to antibodies from donor-derived lymphocytes is a rare cause of anaemia after solid organ transplantation. An elevated lactate dehydrogenase is frequently observed in patients taking sirolimus [9], but haemolysis was confirmed by blood film,

Correspondence and offprint requests to: Shaun Flint, Department of Nephrology, Royal Melbourne Hospital, Victoria 3050, Australia. E-mail: shaun.flint@mh.org.au

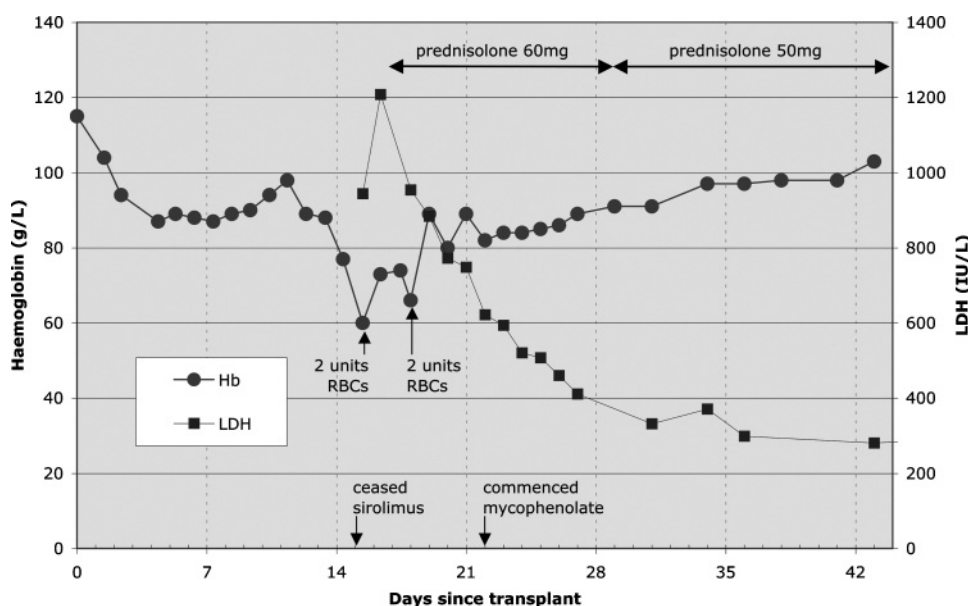


Fig. 1. Time course of alloimmune haemolysis demonstrating interventions and gradual resolution by 1 month post transplant.

reticulocytosis, reduced haptoglobins and hyperbilirubinaemia while the positive DAT and presence of anti-A antibodies indicate an alloimmune aetiology associated with the minor ABO mismatch. There are 75 previously reported cases (references available from the corresponding author on request) affecting renal transplant recipients, but to our knowledge this is the first case described in a patient receiving sirolimus.

Donor-derived lymphocytes have been reported to produce antibodies against ABO, Rhesus and minor blood group antigens and are also described in recipients of other solid organ transplants [11]. This mechanism of haemolysis was initially suggested in 1971 by Beck [1]; 10 years later Stevens coined the term 'passenger lymphocytes' now commonly used to describe the phenomenon [15]. Gm phenotyping has placed beyond doubt that such antibodies are of donor origin [3]. Of interest, haemolysis and alloantibodies have been detected even after graft nephrectomy—suggesting passenger lymphocytes migrate from the graft to other sites [12]. Moreover, Schlitt [14] has shown in liver transplantation that a range of immunologically active cells are transplanted with the allograft itself and that they are not removed by perfusion during harvesting.

Ramsey in a 1991 review [11] reported an incidence of alloimmune anti-ABO antibodies in minor ABO mismatched renal transplants of 17%, with 9% showing active haemolysis. Liver and heart–lung transplants appear to have a higher incidence, perhaps due to a greater number of accompanying lymphocytes. Ramsey's [11] review noted that neither age, gender, race, organ source (living or cadaveric), nor ABH secretor status altered the risk of developing alloimmune haemolysis. However, alloimmune haemolysis occurred more frequently in O to A mismatches.

Several authors [8,11] have reported an increased incidence in association with the use of cyclosporin in comparison to those receiving azathioprine and prednisolone

alone. They suggested that cyclosporin usage resulted in a 'permissive' effect, attributable to a predominant inhibition of T-lymphocyte regulatory function [6,8,17]. It was further suggested that secondary immune responses of competent, primed B-lymphocytes (as seen in alloimmune haemolysis), are resistant to cyclosporin (AB and H blood group antigens are T-cell independent) [6,12,16]. Moreover, the inhibition of T-lymphocyte function by cyclosporin may prevent the recipient's immune system from recognizing and damaging donor-derived passenger B-lymphocytes [2,8]; it has been previously shown that donor-derived passenger lymphocytes comprise up to 24% of all circulating lymphocytes in the recipient in the first week following liver transplantation, and these remain detectable several weeks following transplantation [13].

Therefore, the use of immunosuppressive agents with anti-B-lymphocyte activity would be expected to prevent alloimmune haemolysis. Mycophenolate mofetil and sirolimus possess anti-B-cell activity, with mycophenolate thought to be an important component of ABO incompatible transplantation [7]. However, alloimmune haemolysis has been reported in patients receiving mycophenolate mofetil, albeit in combination with calcineurin inhibitors [2,10]. In the case presented, sirolimus also failed to prevent alloimmune haemolysis despite possessing anti-B-cell activity [5].

In most cases alloimmune haemolytic anaemia is a self-limiting condition remitting spontaneously within 2 months [11]. A response to high-dose corticosteroids has been reported, whilst in other instances the immunosuppressive regimen was altered (including reduction in calcineurin inhibitor dose) but no treatment has been uniformly successful. Should red cell transfusion be required, the donor's blood group should be used to prevent further haemolysis [11]. Ishida *et al.* reported a reduction in alloimmune haemolytic anaemia in patients receiving prophylactic allograft irradiation [4].

Conclusion

Alloimmune haemolysis remains a rare but important cause of anaemia in the early post-transplant period despite the increasing use of immunosuppressive agents directed against B-cells.

Conflict of interest statement. The authors declare that the results presented in this paper have not been published previously in whole or part, except in abstract format. S.C. reports receiving lecture fees and travel support from a number of pharmaceutical companies, including Wyeth (manufacturers of sirolimus). R.W. reports having been involved with a number of clinical trials for Novartis, Wyeth, Roche and Janssen-Cilag over 15 years and also having served at various times on their Australian-based advisory boards in renal transplantation. The remaining authors have no conflicts of interest to declare.

References

1. Beck MG, HF, Oberman HA. Unexpected serologic findings following lung homotransplant. *24th Annual Meeting of the American Association of Blood Banks*, Chicago, 1971, 98
2. Debska-Slizien A, Chamienia A, Krol E *et al.* Hemolytic anemia after renal transplantation: analysis of case reports. *Transplant Proc* 2003; 35: 2233–2237
3. Frohn C, Jabs WJ, Fricke L *et al.* Hemolytic anemia after kidney transplantation: case report and differential diagnosis. *Ann Hematol* 2002; 81: 158–160
4. Ishida H, Tanabe K, Tokumoto T *et al.* The evaluation of graft irradiation as a method of preventing hemolysis after ABO-mismatched renal transplantation. *Transpl Int* 2002; 15: 421–424
5. Kim HS, Raskova J, Degiannis D *et al.* Effects of cyclosporine and rapamycin on immunoglobulin production by preactivated human B cells. *Clin Exp Immunol* 1994; 96: 508–512
6. Klaus GG. Cyclosporine-sensitive and cyclosporine-insensitive modes of B cell stimulation. *Transplantation* 1988; 46: 11S–14S
7. Mannami M, Mitsuhashi N. Improved Outcomes after ABO-incompatible living-donor kidney transplantation after 4 weeks of treatment with mycophenolate mofetil. *Transplantation* 2005; 79: 1756–1758
8. Mangal AK, Grove GH, Sinclair M *et al.* Acquired hemolytic anemia due to “auto”-anti-A or “auto”-anti-B induced by group O homograft in renal transplant recipients. *Transfusion* 1984; 24: 201–205
9. Masterson R, Leikis M, Perkovic V *et al.* Sirolimus: a single center experience in combination with calcineurin inhibitors. *Transplant Proc* 2003; 35: 99S–104S
10. Odabas AR, Tutucu KN, Turkmen A *et al.* Severe alloimmune hemolytic anemia after renal transplantation. *Nephron* 2002; 92: 743–745
11. Ramsey G. Red cell antibodies arising from solid organ transplants. *Transfusion* 1991; 31: 76–86
12. Ramsey G, Israel L, Lindsay GD *et al.* Anti-Rho(D) in two Rh-positive patients receiving kidney grafts from an Rh-immunized donor. *Transplantation* 1986; 41: 67–69
13. Schlitt HJ, Kanehiro H, Raddatz G *et al.* Persistence of donor lymphocytes in liver allograft recipients. *Transplantation* 1993; 56: 1001–1007
14. Schlitt HJ, Raddatz G, Steinhoff G *et al.* Passenger lymphocytes in human liver allografts and their potential role after transplantation. *Transplantation* 1993; 56: 951–955
15. Stevens J, Callender CO, Jilly PN. Emergence of red blood cell agglutinins following renal transplantation in a patient with systemic lupus erythematosus. *Transplantation* 1981; 32: 398–400
16. Thomson AW. The effects of cyclosporin A on non-T cell components of the immune system. *J Autoimmun* 1992; 5(Suppl A): 167–176
17. Watzke H, Kovarik J, Gassner H. A permissive effect of cyclosporin on the development of isohaemagglutinins of graft origin in ABO-mismatched organ transplantation. *Nephrol Dial Transplant* 1988; 3: 89–90

Received for publication: 16.12.07

Accepted in revised form: 13.2.08