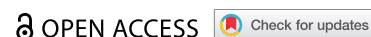

CASE REPORT



Coronary vasospasm complicating atrial fibrillation ablation: a case report and review of the literature

Nirmal Guragai^a, Upamanyu Rampal^b, Rahul Vasudev^a, Pragya Bhandari^c, Atul Prakash^a, Hartaj Virk^a, Mahesh Bikkina^a and Shamoon Fayez^a

^aDepartment of Cardiology, St Joseph Regional Medical Center, Paterson, NJ, USA; ^bDepartment of Cardiology, Banner Estrella Medical Center, Phoenix, AZ, USA; ^cManipal College of Medical Sciences, Pokhara, Nepal

ABSTRACT

Radiofrequency ablation is one of the alternative treatment strategies in patients with atrial fibrillation. With the increasing number of such ablation procedures being performed it is important for the physicians to be aware of the associated complications. We present a very rare case of severe triple coronary vessel spasm during radiofrequency catheter ablation. The procedure was complicated by cardiac arrest secondary to ventricular fibrillation and cardiogenic shock requiring subsequent management with a temporary mechanical circulatory support device. Multi-vessel spasm is a rare and life-threatening complication leading to ventricular fibrillation and cardiac arrest. One should be extra vigilant in monitoring patients during extensive ablations and the procedure should be terminated at the earliest signs of ischemia in order to prevent this rare but fatal complication.

ARTICLE HISTORY

Received 17 December 2019
Accepted 15 April 2020

KEYWORDS

Coronary vasospasm; atrial fibrillation; radiofrequency ablation; catheter ablation

1. Introduction

Radiofrequency ablation is one of the alternative treatment strategies in patients with atrial fibrillation (Afib). The process involves pulmonary vein mapping, isolation of pulmonary vein, and ablation that usually involves using either radiofrequency catheter or cryoballoon catheter. With the increasing number of such ablation procedures being performed it is important for the physicians to be aware of the associated complications. We present a very rare case of severe triple coronary vessel spasm during radiofrequency (RF) catheter ablation. The procedure was complicated by cardiac arrest secondary to ventricular fibrillation and cardiogenic shock requiring subsequent management with left ventricular assist device.

2. Case

The patient is a 58-year-old male with a past medical history of hypertension, diabetes mellitus, dyslipidemia, and prior cryoablation of atrial fibrillation presented to the hospital with chief complaints of dyspnea with minimal exertion and palpitations. On examination the heart rate was 120 with an irregularly irregular pulse. Heart and lung examination was otherwise unremarkable. Laboratory showed normal blood count and serum chemistry except elevated random blood sugar of 270 mg/dl. Chest X-ray was unremarkable. EKG revealed that the patient was in Afib with rapid ventricular response, therefore was

initially treated with intravenous (IV) diltiazem. The patient subsequently underwent transesophageal echocardiography (TEE) followed by cardioversion back to normal sinus rhythm (NSR). The patient was started on oral amiodarone; however, 12 hours following cardioversion, the patient was again noted to be in Afib. Due to ongoing symptoms of palpitations it was decided that patients should undergo repeat Afib ablation. The patient was taken to the electrophysiological laboratory for repeat pulmonary vein isolation, mitral isthmus, left atrial, and coronary sinus ablation. Radiofrequency ablation was initially performed at the left atrial roof and the mitral valve isthmus. However, the fibrillation did not terminate at any point therefore additional ablations were in the carina on the right side between the right superior and inferior pulmonary veins. The patient continued to be in atrial fibrillation, and it was decided to perform ablation inside the coronary sinus as well with 5 watts of energy. At this time, the patient became hypotensive and marked ST-elevation was noted in the EKG telemetry monitor on precordial as well as limb leads (Image 1). The patient developed ventricular fibrillation and was immediately shocked back to NSR (Image 2). Emergent coronary angiography was performed which revealed severe multivessel spasm involving the left anterior descending (LAD), left circumflex (LCX), first obtuse marginal (OM1), and right coronary artery (RCA) (Image 3,4). 400 µg of intracoronary (IC) nitroglycerin was administered in the left system and 200 µg of IC nitroglycerin

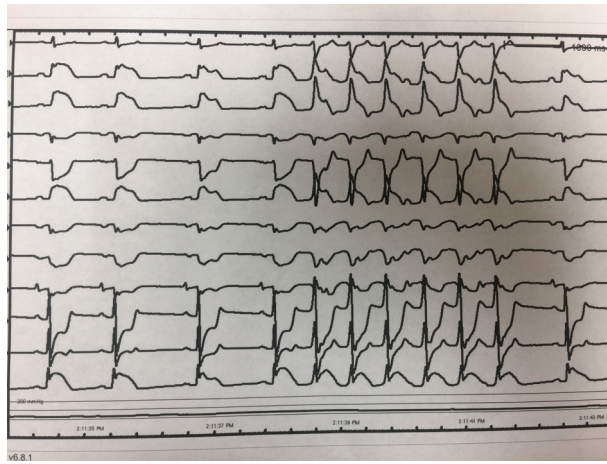


Image 1. Telemetry monitor showing ST-segment elevation in chest lead.

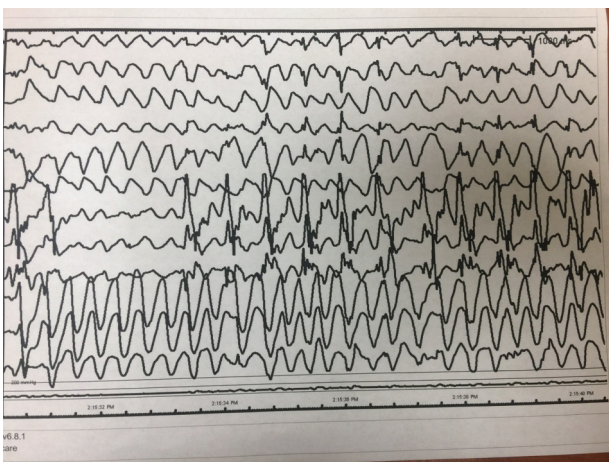


Image 2. ST-elevation subsequently converted to ventricular fibrillation.

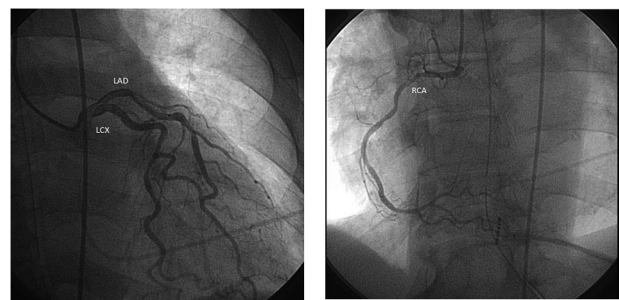


Image 5,6. Resolution of the spasm with minimal residual coronary artery disease.

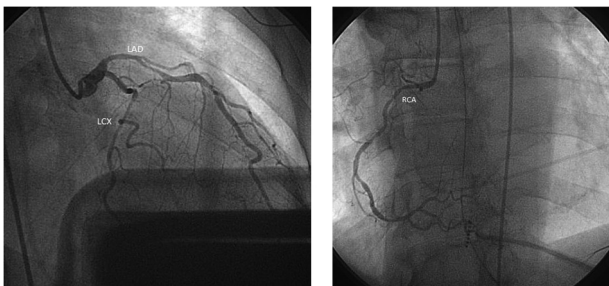


Image 3,4. Left heart catheterization showing severe multi-vessel spasm involving the left anterior descending (LAD), left circumflex (LCX), and right coronary artery (RCA).

in the RCA. This resulted in a significant resolution of the spasm and ST-elevation with minimal focal stenotic segments noted in the LCX and LAD (Image 5,6). Left ventriculogram was performed which revealed an acute reduction of left ventricular ejection fraction (LVEF) to 20%. As the patient was hypotensive requiring vasopressor support at this time, it was decided to place a temporary mechanical circulatory support device (Impella CP) for hemodynamic support. During the course of hospitalization

the patient was started initially on IV nitroglycerin which was changed to isosorbide mononitrate later. The patient’s condition gradually improved with complete recovery of LV function noted on day 7 of hospitalization.

3. Discussion

Ablative procedures have been developed as a curative approach for various arrhythmias including atrial fibrillation. Such procedures focus on the interruption of the electrical pathways that contribute to atrial fibrillation through modifying the arrhythmia triggers [1]. Percutaneous catheter-based radiofrequency ablation (RFA) is a widely used technique for atrial fibrillation where intracardiac mapping identifies a discrete arrhythmogenic focus that is the target of ablation. The ablation can be done, either endocardial or epicardial approach. Coronary artery spasm following ablation is rare and has been reported previously. Most of the case reports involve transient one vessel spasm with spontaneous resolution or requiring administration of IC nitroglycerin. However, ventricular fibrillation due to diffuse spasm of multiple coronary vessels after RFA is exceedingly rare. Upon our literature review (Table 1) we found only two cases (Fujiwara et al. and Kagawa et al.) that

Table 1.

Case	Age/sex	Presentation	Vessel involvement	EKG changes	Management
1 Davies et al.	49/M	Angina	Mid-left anterior descending artery	ST-elevation and hyper-acute T waves in leads V2, V3, and V4	SL nitroglycerin and IV morphine
2 Fujiwara et al.	62/M	Cardiac arrest	Right coronary artery (RCA) and left circumflex artery (LCX)	ST-elevation in leads I, II, III, aVf, aVL, and V3–6	IV nitrates and IC nitrates
3 Kagawa et al.	A)53/M, B)68/M, C)68/M	A) Angina B) Cardiac arrest C) Asymptomatic with ST-elevation in monitor	Multivessel spasm in all three cases	A) ST segment elevation B) ST segment elevation C) ST segment elevation	A) IV nitrates B) nitroglycerine C) Calcium channel blocker
4 Michael et al.	59/M	Angina	Branch of the 1st diagonal	subtle ST segment elevation in leads I and aVL	Intravenous nitrates and a continuous heparin infusion
5 Yajima et al.	63/m	Chest pain	RCA	ST-elevations in II, III, and aVf	IC nitroglycerine
6 Miyazaki	65/M	ST-elevation	N/A	ST-elevation in inferior leads	Injection of intravenous nitroglycerin
7 Lehmann	50/M	Cardiogenic shock	Left main coronary artery	global ST-depression and progressive ST-elevation in aVR	IC nitroglycerine veno-arterial extracorporeal cardiac life support system
8 Hishikari et al.	66/M	Cardiogenic shock	Ostium of the RCA	ST-segment elevation in II, III, aVF	IV nitroglycerine
9 Le et al.	71/M	Cardiogenic shock	N/A	ST-segment elevation was noted in the inferior leads	phenylephrine, right atrial pacing
10 Our case	58/M	Ventricular fibrillation with myocardial stunning leading to cardiogenic shock	Multiple vessels	ST segment in anterio-lateral lead	IC nitroglycerine Impella percutaneous assist device placement for cardiogenic shock

developed cardiac arrest [1–9]. Among all the reported cases of coronary artery spasm, only the case by Kagawa et al. had the involvement of multiple coronary vessels. Analyzing the published case reports, it was found that the most commonly involved artery was the right coronary artery. Usage of nitroglycerine either intravenous or intracoronary was noted to be the most common management for such spasms. ST-segment elevation in inferior leads was the most commonly noted ECG findings.

Coronary vasospasm may cause arrhythmias and myocardial injury leading to even sudden cardiac death. Various mechanisms have been proposed behind the spasm of coronary arteries after RFA. The most common theory postulates the direct transfer of thermal energy being generated during RFA to the adjacent coronary artery leading to spasm [10]. When ablation is performed in the coronary sinus, its proximity with the left circumflex artery can provoke vasospasm. Various inflammatory markers released after ablation causing an imbalance in the autonomic nervous system have also been proposed to provoke coronary spasm. Dynamic fluctuation in vagal activity due to the involvement of epicardial ganglionated plexus located near the pulmonary veins can also cause stimulation of parasympathetic activity leading to spasm of coronary artery [11]. Additionally, patients with paroxysmal AF may coincidentally exhibit coronary artery spasm in some

cases [3]. Sometimes drug with alpha 2 blocking properties (e.g., dexmedetomidine) has been reported to cause coronary spasm; however, our patient was given propofol, excluding that possibility. Cardiac tamponade, vascular access site complication, stroke, phrenic nerve injury, pulmonary vein stenosis, and esophageal fistula are other well-known complications following RFA.

Coronary artery spasm post ablation is usually present with angina like symptoms. Calcium channel blockers and nitrates are the most appropriate therapy in these patients [12]. The prognosis of vasospastic angina is relatively good in general; however, it is known to be a cause of serious life-threatening ventricular-arrhythmias and resultant sudden cardiac death in some cases [13]. Coronary artery spasm is usually limited to a single coronary artery and can rarely cause ventricular arrhythmias. It is exceedingly rare to see spasm of multiple vessels leading to myocardial stunning causing ventricular fibrillation and cardiac arrest. The LVEF was acutely reduced to 20% in our patient which was attributed to myocardial stunning secondary to severe triple vessel spasm. In our case there was complete recovery of EF in a few days highlighting that favorable outcomes can be achieved with early identification of this rare complication and treatment using IC/IV nitrates with adequate hemodynamic support (percutaneous assist devices) in cases complicated by cardiogenic shock.

In conclusion, endocardial ablation therapy for atrial and ventricular arrhythmia can cause coronary artery spasm. Multi-vessel spasm is a rare and life-threatening complication leading to ventricular fibrillation and cardiac arrest. One should be extra vigilant in monitoring patients during extensive ablations and the procedure should be terminated at the earliest signs of ischemia in order to prevent this rare but fatal complication.

Disclosure statement

No potential conflict of interest was reported by the authors.

References

- [1] Davies O, Ajayeoba O, Kurian D. Coronary artery spasm: an often overlooked diagnosis. *Niger Med J*. 2014 Jul-Aug;55(4):356–358.
- [2] Fujiwara R, Yoshida A, Hirata K. Ventricular fibrillation associated with multi-vessel coronary spasms following radiofrequency ablation of atrial fibrillation and atrial flutter. *Europace*. 2014 Jul;16(7):1060.
- [3] Kagawa Y, Fujii E, Fujita S, et al. Three cases of vasospastic angina following catheter ablation of atrial fibrillation. *J Arrhythm*. 2017 Oct;33(5):511–513.
- [4] Michael KA, Redfearn DP, Simpson CS, et al. An unusual complication of a pulmonary vein isolation. *Interv Card Electrophysiol*. 2009 Sep;25(3):203–205.
- [5] Yajima K, Yamase Y, Oishi H, et al. Coronary artery spasm during cryoballoon ablation in a patient with atrial fibrillation. *Intern Med*. 2018 Mar 15; 57(6): 819–822.
- [6] Shinsuke M, Noboru I, Takamitsu T, et al. Coronary artery spasm during cryothermal cavotricuspid isthmus ablation. *J Cardiovasc Electrophysiology* 2015 Sep;26(9):1019–1020.
- [7] Lehrmann H, Potocnik C, Comberg T, et al. Near-fatal coronary artery spasm during cryoballoon pulmonary vein isolation: an unreported complication. *Circ Arrhythm Electrophysiology* 2014 Dec;7(6):1273–1274.
- [8] Hishikari K, Kuwahara T, Takahashi A, et al. Severe coronary artery spasm during radiofrequency ablation for atrial fibrillation. *Int J Cardiol*. 2014 Apr 1;172(3): e513–5.
- [9] Le BH, Black JN, Huang SK. Transient ST-segment elevation during transseptal catheterization for atrial fibrillation ablation. *Tex Heart Inst J*. 2010;37(6):717–721.
- [10] Castaño A, Crawford T, Yamazaki M, et al. Coronary artery pathophysiology after radiofrequency catheter ablation: review and perspectives. *Heart Rhythm*. 2011;8(12):1975–1980..
- [11] Watanabe T, Hachiya H, Miyazaki S, et al. Recurrent and late-onset coronary spasms after cryoballoon ablation procedure in a patient with atrial fibrillation. *HeartRhythm Case Rep*. 2016 Sep;2(5):421–424.
- [12] Guragai N, Rampal U, Vasudev R, et al. A rare case of late onset saphenous vein graft spasm. *J Community Hosp Intern Med Perspect*. 2017;7(5):332–335..
- [13] Hung M-J, Patrick H, Hung M-Y. Coronary artery spasm: review and update. *Int J Med Sci*. 2014;11(11):1161–1171.