

Collision tumors in the gastrointestinal tract: a rare case series

Aruna Bhattacharya¹

Rama Saha¹

Jayanta Biswas²

Jhuma Biswas¹

Biswajit Ghosh¹

¹Institute of Postgraduate Medical Education and Research, ²NRS Medical College and Hospital, Kolkata, West Bengal, India

Abstract: A collision tumor is one where histology shows the presence of two distinct primaries involving the same organ without intermixture of individual cell types, ie, a side by side pattern. Here we present three rare cases of collision tumors involving the stomach and transverse colon. There were two cases of collision tumors involving the stomach, one of which was a combination of adenocarcinoma and low-grade non-Hodgkin's (mucosa-associated lymphoid tissue) lymphoma, and the other showed the presence of non-Hodgkin's lymphoma involving the entire stomach wall along with adenocarcinoma infiltrating the muscle layer. The third case comprised a mucinous adenocarcinoma and carcinoid tumor in the large gut.

Keywords: collision tumor, histology, gastrointestinal tract

Cases 1 and 2

The coexistence of a gastric adenocarcinoma and a primary gastric lymphoma occurs rarely, as evidenced by the paucity of relevant case reports.¹⁻⁴ However, there might be some causal relationship with infections caused by *Helicobacter pylori* and Epstein-Barr virus.^{3,5}

Case 1 was a 55-year-old Indian man who presented with hematemesis and a sensation of fullness in the upper abdomen. On ultrasound there was gross thickening of the gastric wall along with enlarged gastric lymph nodes. The patient underwent total gastrectomy and esophagojejunostomy. Histology of the specimen confirmed the presence of an infiltrating gastric carcinoma and mucosa-associated lymphoid tissue (MALT) lymphoma.

Case 2 was a 67-year-old Indian man who presented with a sensation of fullness in the abdomen, and a history of anorexia and weight loss. A total gastrectomy specimen showed the presence of adenocarcinoma invading the muscle layer and non-Hodgkin's lymphoma involving the entire thickness of the stomach wall.

Pathological findings

In case 1, the gross gastric specimen measured approximately 14 × 7 × 2 cm. In the distal part of the stomach, an ulceroproliferative growth with a maximum diameter of 4 cm was seen, involving the entire thickness of the wall. Multiple large lymph nodes, each measuring approximately 1.5 × 1 cm, were seen in the lesser curvature. A section from the stomach showed moderately differentiated adenocarcinoma involving the muscle layer along with lymphoid cells distributed diffusely throughout the gastric wall (Figure 1). Lymphoid follicles with a germinal center and lymphoepithelial lesions

Correspondence: Aruna Bhattacharya
35 AKG School Road, East Anandapuri,
PO Nonachandanpukur, Barrackpur,
Kolkata 700122, West Bengal, India
Tel +94 3346 5339
Email draruna.bhattacharya@gmail.com

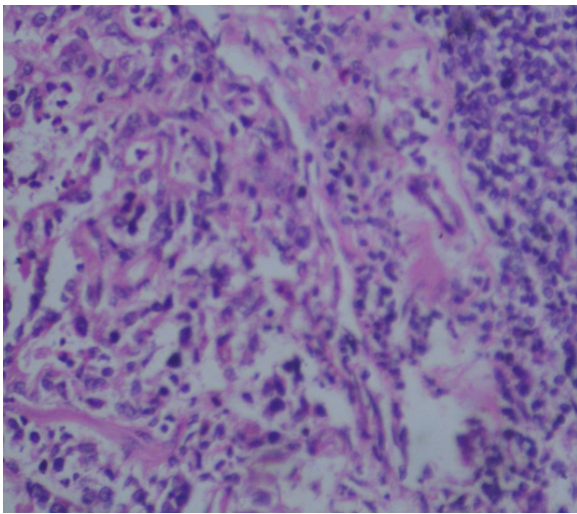


Figure 1 Case 1: Adenocarcinoma and lymphomatous portion (hematoxylin and eosin staining, high power).

were also identified in the specimen, and multiple curved bacteria-like bodies were seen on the mucosal surface of gastric wall. *H. pylori* was suspected but could not be confirmed because of lack of silver staining at our facility at that time. Immunohistochemistry of the carcinomatous area was cytokeratin-positive, confirming adenocarcinoma (Figure 2), and the lymphoid cells showed CD20 positivity, confirming non-Hodgkin's lymphoma (Figure 3). The final diagnosis was of a collision tumor comprising moderately differentiated adenocarcinoma and non-Hodgkin's lymphoma.

In case 2, the gross specimen measured about $10 \times 6 \times 2$ cm, with an ulceroproliferative growth involving the prepyloric region of the stomach. The section from the stomach showed both adenocarcinomatous and lymphoid elements (Figure 4). The lymphoid cells were distributed diffusely throughout the stomach wall, and were confirmed to be

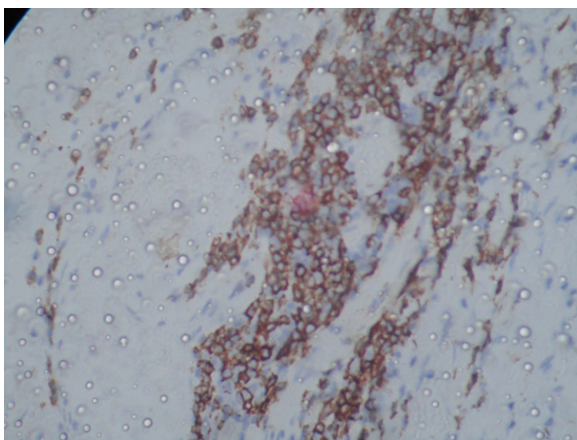


Figure 2 Case 1: Adenocarcinomatous portion showing cytokeratin positivity.

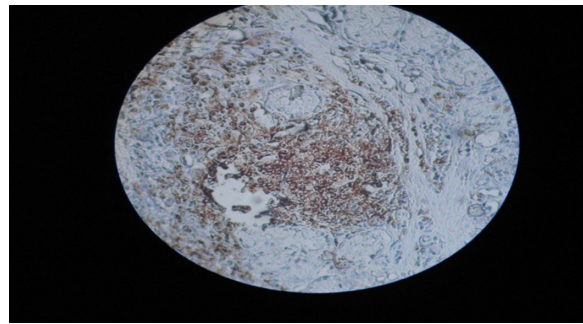


Figure 3 Case 1: CD20 positivity shown by lymphomatous portion.

CD20-positive on immunohistochemistry (Figure 5). The final diagnosis was of a collision tumor comprising adenocarcinoma and non-Hodgkin's lymphoma.

Case 3

Adenocarcinoma is the commonest malignancy of the colon, with collision tumors at this site being extremely rare. Reports of a combination of two independent tumor phenotypes in the colon have included adenocarcinoma with carcinoid, with transitional cell carcinoma,⁶ and with lymphoma.^{7-9,12} Possible explanations include simultaneous proliferation of two different cell lines, a common origin for pluripotent precursor stem cells that differentiate into two components, and chance apposition of two unrelated tumors.¹²

Case 3 was a 65-year-old Indian man with symptoms of hematochesza, anorexia for 5 months, epigastric pain, a lump in the epigastrium, and loose stools for 2-3 months. He underwent total colectomy and the specimen showed the presence of a collision tumor on histological examination.

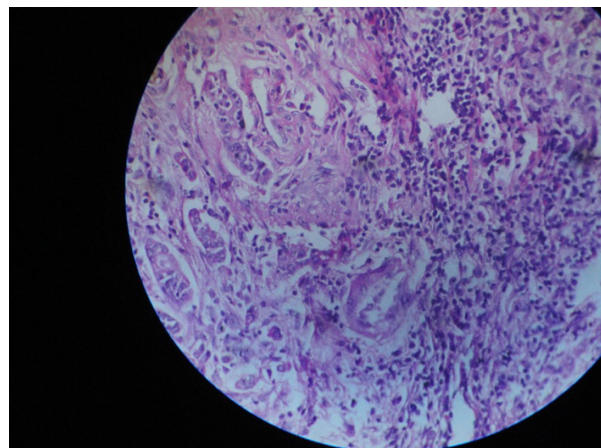


Figure 4 Case 2: Adenocarcinoma with lymphoma.

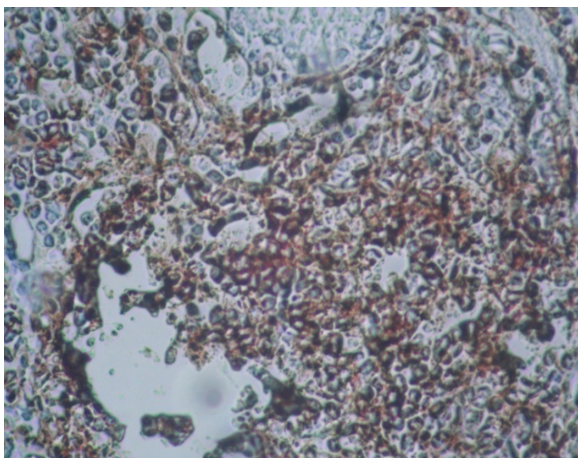


Figure 5 Case 2: Lymphoid portion of the tumor showing CD20 positivity.

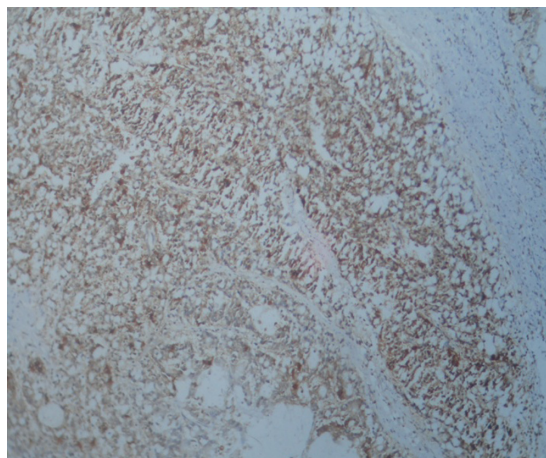


Figure 7 Case 3: Chromogranin positivity of carcinoid portion.

Pathological findings

Gross pathological examination showed an ulceroproliferative growth measuring 7.6 cm in the transverse colon. This was a mucinous tumor containing irregular glands lined by mucinous epithelium with large areas of extracellular mucin material consistent with adenocarcinoma, with an adjacent area showing monomorphic cells in solid nests, consistent histopathologically with a diagnosis of carcinoid tumor (Figure 6). Immunohistochemistry showed the carcinoid area to be chromogranin-positive (Figure 7). The final diagnosis was of a collision tumor comprising adenocarcinoma and carcinoid tumor.

Discussion

A neoplasm consisting of more than one type of neoplastic tissue is called a mixed tumor, with two possible subtypes,

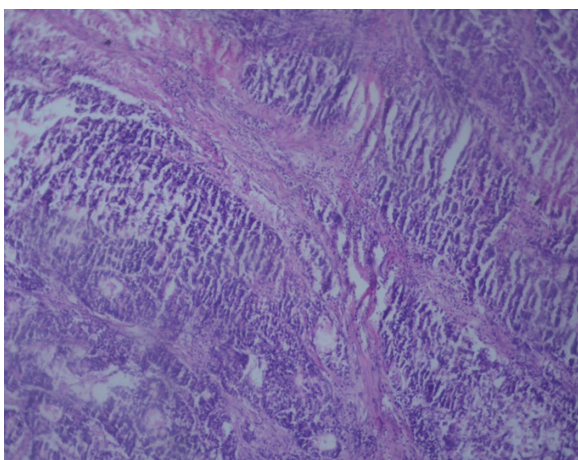


Figure 6 Case 3: Carcinoid and adenocarcinomatous portion (hematoxylin and eosin staining, high power).

ie, combined and composite. In the composite tumor, two neoplastic components are intimately intermingled, whereas in the combined tumor, two separate components are present with a distinct interface between them. A further subset of the combined tumor is the so-called collision tumor.

Certain types of tumor, including lymphoma, gastrointestinal stromal tumor, and carcinoid, can occur in collision with gastric adenocarcinoma.^{10,11} *H. pylori* plays an important role in the development of both gastric adenocarcinoma and MALT lymphoma. However, genetic instability may possibly be the precipitating factor for such malignancies.²⁴

To our knowledge, there have been 35 cases of gastric collision tumor composed of epithelial and nonepithelial malignant neoplasm reported in the literature.¹⁹ The average age of onset for collision tumor is 61 (range 42–80) years and the most frequent combination is adenocarcinoma and malignant lymphoma.^{12–19} A relationship between *H. pylori* and MALT lymphoma has been hypothesized because of observation of regression of the lymphoma component with antibiotic treatment for *H. pylori*.²⁰ In our case series, collision tumors in the stomach presented as a combination of adenocarcinoma and lymphoma. We also suspected *H. pylori* invasion in case 1, although this could not be confirmed.

Immunohistochemistry shows that MALT lymphoma is positive for CD20, CD21, CD35, and CD79a, with some cases also positive for Bcl-2. CD5 negativity is useful for the diagnosis of MALT lymphoma.²⁵ At our facility, we were only able to test for CD20. In case 2, we demonstrated CD20 positivity, which suggests a diagnosis of non-Hodgkin's lymphoma.²⁷

Due to the lack of any large series with long-term follow-up, the prognosis of such tumors has not been properly clarified. However, it seems that the survival rate is similar to that of patients with gastric adenocarcinoma but worse than that of patients with MALT-type lymphoma without gastric adenocarcinoma.²¹ The incidence of a carcinoid tumor of the gastrointestinal tract coexisting with an adenocarcinoma has been reported to be 0.3%–4.3%.¹⁹ Most cases of mixed tumor consisting of adenocarcinomatous and carcinoid components arise from the colon in patients with longstanding ulcerative colitis. The possible mechanism for development of adenocarcinoma from longstanding colitis is probably dysplastic changes triggered by the ongoing inflammatory process, whereas carcinoid rarely arises from ulcerative colitis.²⁶ Reports of tumors arising de novo are few.²² In our small case series, we did not see any features of ulcerative colitis. In mixed adenocarcinoid tumors, the prognosis and overall survival depends upon the glandular component.²³

Disclosure

The authors report no conflicts of interest in this work.

References

- Czerniak A, Lotan G, Engelberg IS, et al. The simultaneous coexistence of adenocarcinoma and primary malignant lymphoma in the stomach. *J Surg Oncol*. 1985;30:42–45.
- Kasahara Y, Takemoto M, Morishita A, Kuyama T, Takahashi M, Tanji K. Coexisting adenocarcinoma and malignant lymphoma of the stomach: case report and review of the Japanese literature. *Am J Gastroenterol*. 1988;83:190–193.
- Wotherspoon AC, Isaacson PG. Synchronous adenocarcinoma and low grade B-cell lymphoma of mucosa associated lymphoid tissue (MALT) of the stomach. *Histopathology*. 1995;27:325–331.
- Adachi Y, Mori M, Enjoji M, Saku M. Coexistence of pseudolymphoma and early carcinoma in the stomach. *Arch Pathol Lab Med*. 1986;110:1080–1082.
- Goteri G, Ranaldi R, Rezai B, Baccarini MG, Bearzi I. Synchronous mucosa-associated lymphoid tissue lymphoma and adenocarcinoma of the stomach. *Am J Surg Pathol*. 1997;21:505–509.
- Olinic CD, Domşa I, Crişan D. Collision adenocarcinoma-carcinoid tumor of the colon. Case report and review of the literature. *Rom J Morphol Embryol*. 2007;48:75–78.
- Mannweiler S, Dinges HP, Beham-Schmid C, Hauser H, Starlinger M, Re gauer S: Colliding/concomitant tumors of the intestine: report of three cases.
- Takafumi A, Mitsuru S, Daisuke I, Fuyuki I, Hiroyuki S: Coexistence of primary colonic malignant lymphoma and rectal adenocarcinoma. A case report and common clinical features in literatures.
- Mayur Brahmania, Chandra S Kanthan, Rani Kanthan. Collision tumor of the colon – colonic adenocarcinoma and ovarian granulosa cell tumor. *World Journal of Surgical Oncology*. 2007;5:118. doi:10.1186/1477-819-5-118.
- Nishino N, Konno H, Baba S, et al. Synchronous lymphoma and adenocarcinoma occurring as collision tumor in stomach; report of a case. *Surg Today*. 1996;26:508–512.
- Lin SW, Chen GH, Hisch PP. Collision tumor of stomach: a case report of mixed GIST and adenocarcinoma. *J Clin Gastroenterol*. 2002;35:332–334.
- Lewin KJ, Appelman HD. Endocrine cell proliferation of the stomach. In: Rosai J, ed. *Tumor of the Esophagus and Stomach*. Washington, DC: Armed Forces Institute of Pathology. 1996:331–356. *Atlas of Tumor Pathology*; 3rd series, fascicle 18.
- Mohinelo C, Requena M, Zaragoza M, Caballero E, Torres J, Guijarro A. Tumor de colision gastrico con metaplasia osea. *Rev Esp Enf Digest*. 1997;89:317–319.
- Corsi A, Bosman C. Adenocarcinoma and atypical carcinoid: morphological study of a gastric collision-type tumor in the carcinoma-carcinoid spectrum. *Ital J Gastroenterol*. 1995;27:303–308.
- Morishita Y, Tanaka T, Kato K, et al. Gastric collision tumor (carcinoid and adenocarcinoma with gastritis cystica profunda). *Arch Pathol Lab Med*. 1991;115:1006–1010.
- Chodankar CM, Pandit SP, Motiwale SS, Deodhar KP. Collision tumor of stomach. *Indian J Gastroenterol*. 1989;8:297–298.
- Yamashina M, Flinner RA. Concurrent occurrence of adenocarcinoma and carcinoid tumor in the stomach: a composite tumor or collision tumors? *Am J Clin Pathol*. 1985;83:233–236.
- Morishita Y, Sugitani M, Sheikh A, et al. Collision Tumor of the Stomach: A Rare Case of an Adenocarcinoma and Carcinoid Tumor. *Arch of Pathol and Lab Med*. 2004;129:407–409
- Mardi K, Sharma J, Gupta S. Gastric Collision Tumor: A Rare case of an Adenocarcinoma and Carcinoid tumor. *The Internet Journal of Gastroenterology*. 2009;7(2).
- Wotherspoon AC, Doglioni C, Diss TC, et al. Regression of primary low-grade B-cell gastric lymphoma of mucosa-associated lymphoid tissue type after eradication of *Helicobacter pylori*. *Lancet*. 1993;342:575–577. doi: 10.1016/0140-6736(93)91409-F. <http://www.ncbi.nlm.nih.gov/pubmed/8102719>; [http://dx.crossref.org/10.1016%2F0140-6736\(93\)91409-F](http://dx.crossref.org/10.1016%2F0140-6736(93)91409-F)
- Nakamura S, Aoyagi K, Iwanaga S, Yao T, Tsuneyoshi M, Fujishima M. Synchronous and metachronous primary gastric lymphoma and adenocarcinoma: a clinicopathological study of 12 patients. *Cancer*. 1997;79:1077–1085. doi:10.1002/(SICI)1097-0142(19970315)79:6<1077::AID-CNCR4>3.0.CO;2-D. <http://www.ncbi.nlm.nih.gov/pubmed/9070483>; [http://dx.crossref.org/10.1002%2F\(SICI\)1097-0142\(19970315\)79%3A6%3C1077%3A%3AAID-CNCR4%3E3.0.CO%3B2-D](http://dx.crossref.org/10.1002%2F(SICI)1097-0142(19970315)79%3A6%3C1077%3A%3AAID-CNCR4%3E3.0.CO%3B2-D)
- Lyss AP, Thomson JJ, Glick JH. Adenocarcinoid of the colon arising in preexisting ulcerative colitis. *Cancer*. 1981;48:833–839.
- Varghese NM, Zaitoun AM, Thomas SM, Senapati A, Theodossi A. Composite glandular carcinoid tumour of the terminal ileum. *J Clin Pathol*. 1994;47:427–429.
- Zucca E, Bertoni F, Roggero E, Cavalli F. The gastric marginal zone B- cell lymphoma of MALT type. *Blood*. 2000;96:409–410.
- Dorfman DM, Pinkus GS. Utility of immunophenotypic studies in the diagnosis of low grade lymphoma of mucosa associated lymphoid tissue (MALT) and other low grade Non-Hodgkin's Lymphoma of extra nodal sites. *Appl Immunohistochem*. 1995;3:160–167.
- Morson BC, Pang LSC. Rectal biopsy as an aid to cancer control in ulcerative colitis. *Gut*. 1967;8:423–434.
- Ayala AG, Ro JY, Raymond AK. *Anderson's Pathology*. Tenth Edition. 1990;2:2559.

International Medical Case Reports Journal

Dovepress

Publish your work in this journal

The International Medical Case Reports Journal is an international, peer-reviewed open-access journal publishing original case reports from all medical specialties. Previously unpublished medical posters are also accepted relating to any area of clinical or preclinical science. Submissions should not normally exceed 2,000 words or

4 published pages including figures, diagrams and references. The manuscript management system is completely online and includes a very quick and fair peer-review system, which is all easy to use. Visit <http://www.dovepress.com/testimonials.php> to read real quotes from published authors.

Submit your manuscript here: <http://www.dovepress.com/international-medical-case-reports-journal-journal>