

Management of Traumatic Diaphragmatic Injury—A Peep into Bowel Repair via Thoracotomy

Abstract

Background: Traumatic diaphragmatic injury (TDI) is a relatively rare condition, and there is a high tendency for it to be missed if thorough clinical assessment and imaging review are not carried out. The surgical approach for TDI can be challenging, especially with bowel perforation. **Materials and Methods:** This is a retrospective case series of all consecutive patients with TDI from two tertiary hospitals in the southern part of Nigeria between January 2013 and December 2019. The demographic data of the patients, type, cause, and clinical diagnosis, intraoperative findings, Injury Severity Score, and outcome were noted. The descriptive statistics were presented in percentages and fractions. **Results:** Fourteen (4.3%) of the 326 chest trauma patients had TDI with 57.1% from penetrating causes and 42.9% from blunt causes. The causes of the TDI were gunshot injuries (42.9%), road traffic crashes (35.7%), stab injury (14.3%), and domestic accidents (7.1%). The preoperative method of diagnosis was mainly by massive haemothorax necessitating open thoracotomy (42.9%) and mixed clinical evaluation, chest radiograph, and upper gastrointestinal contrast studies (35.7%), and the drainage of intestinal content following the insertion of a chest tube to initially drain haemothorax (21.4%) and other modality of diagnoses (7.1%). The operative finding was mainly intestine content in the chest (50%) and only diaphragmatic injury (35.7%). The major complication after surgery was empyema thoracis (14.3%) and the mortality rate (14.3%). **Conclusion:** Penetrating injury of the chest was the major factor responsible for the TDI, and even with bowel perforation and acute TDI, thoracotomy offered an effective surgical approach for all the patients.

Keywords: Bowel perforation, chest trauma, diaphragmatic injury, thoracotomy

Introduction

The nature and mechanism of diaphragmatic injury may depend on whether it is the blunt or penetrating cause, the side of the diaphragm affected, and the portion of the trunk involved.^[1-3] The diagnosis of diaphragmatic injury can be a challenge, but the careful search for clinical features suggestive of diaphragmatic injury in patients who sustain blunt or penetrating thoracoabdominal trauma can be quite helpful.^[4] This is because factors that may affect the diagnosis of diaphragmatic injury will depend on clinical features of diaphragmatic injury, associated injuries, and evidence of pleural collection, especially if massive may blur any content in the thoracic cavity.^[4,5]

The diagnosis of diaphragmatic injury can be made, apart from clinical examination, from a plain chest radiograph or computed tomography (CT) in most situations.

This is an open access journal, and articles are distributed under the terms of the Creative Commons Attribution-NonCommercial-ShareAlike 4.0 License, which allows others to remix, tweak, and build upon the work non-commercially, as long as appropriate credit is given and the new creations are licensed under the identical terms.

For reprints contact: reprints@medknow.com

Another diagnostic modality is the use of the diagnostic height index (DHI). This is specifically with diaphragmatic injury resulting from blunt chest trauma, and with the value of DHI being positive when the right side is higher and negative when the left side is higher.^[6] Some more subtle features will require careful analysis of CT images and examination with magnetic resonance imaging to improve the detection of diaphragmatic injuries in thoracoabdominal trauma patients.^[5,7-9]

The surgical approach for traumatic diaphragmatic injury (TDI) has been a point of discourse. For acute TDI, laparotomy was highly recommended over the thoracotomy approach, whereas the reverse is the case for chronic TDI.^[10,11] However, in a large national study, there was no consensus on the surgical approach (thoracotomy or laparotomy approach) to be used for TDI.^[12] In an uncommon case of bowel injury such as perforation, thoracotomy was the approach chosen to

How to cite this article: Okonta KE, Ekwunife CN, Okonta EM, Aghaji MA. Management of traumatic diaphragmatic injury—A peep into bowel repair via thoracotomy. *J West Afr Coll Surg* 2022;12:53-7.

**Kelechi E. Okonta¹,
Christopher N.
Ekwunife²,
Emeka M. Okonta³,
Martin A. C. Aghaji⁴**

¹Department of Surgery, University of Port Harcourt, Port Harcourt, Rivers State, ²Department of Surgery, Federal Medical Centre, Owerri, Imo State, ³Department of Human Anatomy, College of Basic Medical Sciences, Bingham University, Karu, Nasarawa State, ⁴Cardiac Surgical Unit, Department of Surgery, University of Nigeria, Nsukka, Enugu State, Nigeria

Received: 10-Apr-2022

Accepted: 31-May-2022

Published: 27-Aug-2022

Address for correspondence:

Dr. Kelechi E. Okonta,
Department of Surgery,
University of Port Harcourt,
Port Harcourt, Rivers State,
Nigeria.
E-mail: kelechi.okonta@uniport.edu.ng

Access this article online

Website:

www.jwacs-jcoac.com

DOI: 10.4103/jwas.jwas_94_22

Quick Response Code:



repair the condition.^[13] This does not change the fact that the diagnosis of TDI remains difficult and often delayed.^[14]

Methods

This is a retrospective case series of all the consecutive patients with TDI following chest trauma who presented in the University of Port Harcourt and Federal Medical Centre Owerri all in the southern part of Nigeria over 6 years at the emergency department and the surgical clinic. The demographic data of the patients, the type of chest injury (blunt versus penetrating), the cause of the diaphragmatic injury, the clinical diagnoses, the intraoperative findings, the Injury Severity Score (ISS), the complications, and the outcome of dead or alive were collated. The diagnoses were made from the clinical evaluation of the patient, chest ultrasound, chest radiograph, upper gastrointestinal contrast studies [Figure 1], quantity or quality of the inserted chest tube drainage, and intraoperative finding [Figure 2]. The descriptive statistics were presented in percentages and fractions.

Results

A total of 326 with chest trauma were got from the records between January 2013 and December 2019. Of these 326 patients, 14 (4.3%) had TDI. The age range was 8–65 years, with a mean age of $35.60 \pm$ standard deviation 14.64 years and a male to female ratio of 6:1. Eight (57.1%) had penetrating mechanisms and six (42.9%) had a blunt injury. The cause of injury was gunshot injuries in six (42.9%) patients, road traffic crashes in five (35.7%) patients, stab injury in two (14.3%) patients, and domestic accidents in one (7.1%) patient. The preoperative method of diagnosis was massive haemothorax (massive haemothorax defined

by the drainage of 1.5 L of blood at the insertion of the chest tube or the drainage of 200–300 mL hourly for 3 consecutive hours) necessitating open thoracotomy in six (42.9%) patients, bowel sound on auscultation during clinical evaluation, chest radiograph, and upper gastrointestinal contrast studies showing evidence of diaphragmatic injury in the chest in five (35.7%) patients [Figure 1], the drainage of intestinal content following the insertion of a chest tube to initially drain haemothorax in three (21.4%) patients, and the detection of distortion in the diaphragmatic outline in one (7.1%) patient. The operative findings were intestine content in the chest in seven (50%) patients [Figure 2], isolated diaphragmatic injury in five (35.7%) patients, and the presence of spleen and the left lobe of the liver in one (7.1%) each. The surgery was complicated by empyema thoracis in 14.3% of patients, and the mortality rate was two (14.3%) [Table 1].

Discussion

This is a retrospective case series of TDI in two tertiary institutions in the country. TDI is a relatively rare condition, and there is a high tendency for it to be missed if thorough clinical assessment and imaging review are not carried out, and the absolute number of TDI is dependent on the overall number of chest trauma; the number of cases of TDI (is directly proportional to the incidence of chest trauma) tends to increase as the number of chest trauma increases.^[14] The incidence of TDI in patients with chest trauma ranges between 1.3% and 6.5%^[14,15] and about 54.2% of those had thoracotomy following chest trauma from our recent review.^[16] The incidence of 4.3% from this series is similar to the 6.5% reported by Adegboye *et al.* about two decades ago.^[15] The implication is that TDI following truncal injuries is quite uncommon, and thus attending emergency physicians should be alert to identify any of

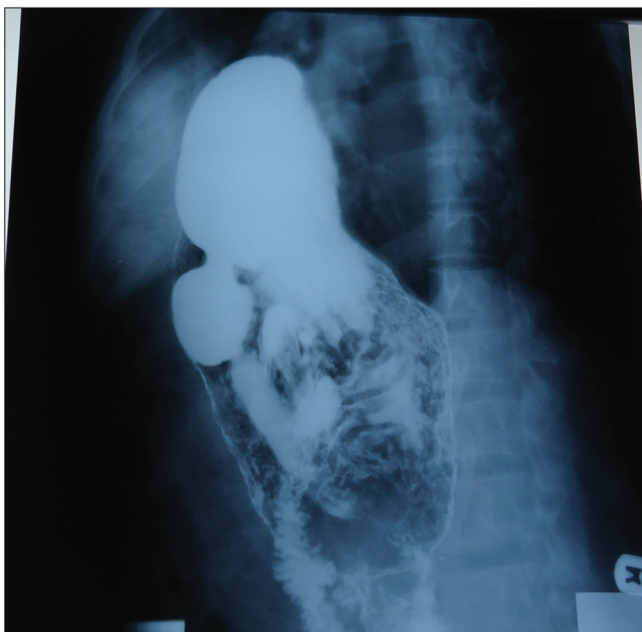

Figure 1: A contrast study showing the outline of the stomach in the chest

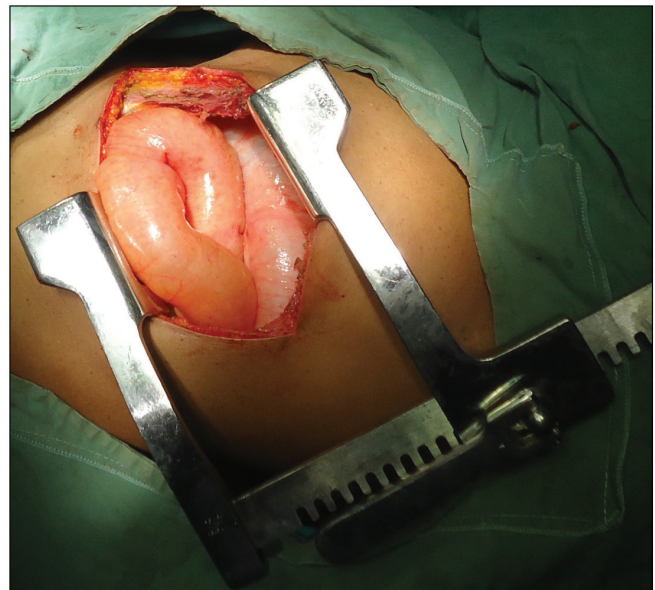


Figure 2: Bowel in the chest after thoracotomy

Table 1: Characteristics of patients with diaphragmatic injury

No	Age	Sex	Type	Expediency of surgery	Mechanism	Preoperative diagnosis	Modality of diagnosis	Operative finding	ISS	Complication	Outcome
1	37	M	Blunt	Emergency	RTC	Massive haemothorax	CTTD/thorac	Diaphragmatic injury	32	None	Alive
2	23	M	Blunt	Emergency	RTC	Bowel in the chest	Clinical evaluation	Diaphragmatic injury + intestine	32	None	Alive
3	39	F	Blunt	Emergency	RTC	Bowel in the chest	Clinical evaluation	Diaphragmatic injury + intestine	16	None	Alive
4	65	M	Blunt	Emergency	RTC	Bowel in the chest	Clinical evaluation	Diaphragmatic injury + intestine	16	None	Alive
5	8	F	Blunt	Emergency	DA	Bowel in the chest	Clinical evaluation/ chest radio	Diaphragmatic injury + intestine	16	None	Alive
6	27	M	Pene	Emergency	Stab injury	Massive haemothorax	CTTD/thorac	Diaphragmatic injury + spleen	25	None	Alive
7	32	M	Pene	Emergency	GSI	Massive haemothorax	CTTD/thorac	Diaphragmatic injury	25	None	Alive
8	30	M	Pene	Emergency	GSI	Massive haemothorax	CTTD/thorac	Diaphragmatic injury	16	None	Alive
9	34	M	Pene	Emergency	GSI	Massive haemothorax	CTTD/thorac	Diaphragmatic injury + bowel injury	25	None	Dead
10	47	M	Pene	Urgency	GSI	Chest tube drained bowel content	CTTD	Bowel injury	16	ET	Alive
11	23	M	Pene CI	Urgency	Stab injury	Chest tube drained bowel content	CTTD	Bowel injury	16	ET	Alive
12	63	M	Blunt CI	Elective	RTC	Bowel in the chest	Chest radio	Diaphragmatic injury	16	None	Alive
13	40	M	Pene CI	Elective	GSI	Diaphragmatic injury	Chest radio	Diaphragmatic injury	25	None	Alive
14	31	M	Pene CI	Emergency	GSI	Haemothorax	Chest radio	Diaphragmatic injury	32	None	Dead

CI = chest injury, CTTD = closed-tube thoracostomy drainage, DA = domestic accident, ET = empyema thoracis, F = female, GSI = gunshot injury, M = male, pene = penetrating, radio = radiograph, RTC = road traffic crash, thorac = thoracotomy

such injuries in order to avoid the complications that may result from a missed diagnosis.^[17,18]

The TDI can be broadly divided into that due to blunt causes and that due to penetrating causes. From this study, the commonest cause of TDI following the blunt chest injury was a road traffic crash, and the commonest cause of TDI following penetrating chest injury was a gunshot and stab injury mainly from a knife. It is important to note that all diaphragmatic wounds will require operation, no matter the length or duration of the rent to avoid secondary bleeding and bowel herniation as well as missing of associated visceral injuries,^[9] and thus the expediency of surgery can be emergent, urgent, and elective.^[15]

The differential pressure within the trunk after TDI may lead to the movement of the mobile organ or viscera across the opening in the diaphragm. This may also be dependent on the contiguousness and mobility of abdominal structures, and thus structures such as the spleen or part of the liver

may be found in the thorax, and mobile structures such as the small intestine, the large intestine, the omentum, and the stomach may also be found in the chest cavity.

In TDI from penetrating the chest, an injury may dictate the need for immediate thoracotomy and therefore aid in the diagnosis of diaphragmatic injury; there may be a delay in diagnosis and diagnostic conundrum from a blunt mechanism.^[16,19] This is because concurrent massive haemothorax in the blunt mechanism may mask the diaphragmatic injury and thus make the detection of bowel in the thoracic cavity on clinical evaluation and imaging difficult.^[5,7,16]

Penetrating cause of TDI as against the blunt one was reported as being higher in many pieces of literature.^[19,20] The reason for this observation was a result of the increased use of firearms in some of the states in the country.^[21] Another reason may be because most of the penetrating upper truncal injuries were referred specifically to the

thoracic surgical unit and thus immediate diagnoses were able to be made, thoracotomy was carried out.

Making a diagnosis of TDI may be quite difficult as bowel herniation or diaphragmatic distortion can be overshadowed by a significant amount of blood within the thoracic cavity and associated injuries.^[8,14,16] In our series, massive haemothorax was the overshadowing factor in establishing the preoperative diagnosis. But, when there was no associated haemothorax to blur the diaphragmatic outline, then the presence of diaphragmatic discontinuity, abnormal diaphragmatic elevation to 4 cm or more, diaphragmatic thickening, herniation of abdominal viscera into the thoracic cavity, signs such as the collar/hump sign, and dependent viscera signs will be identified.^[22] Recommendations were made in favour of laparoscopy over CT for diagnosis, nonoperative versus operative approach for the right-sided penetrating injuries, abdominal versus thoracic approach for acute TDI, and laparoscopy (with the appropriate skill set and resources) versus open approach for isolated TDI.^[11] The preferred operative approach: thoracotomy allows for a better access to the injured diaphragm and its repair, as well as any herniated viscera.

From this review, about 21.4% of patients were suspected to have sustained bowel injury for trocar inbuilt chest tube during the drainage of haemothorax after chest trauma. The diagnosis of bowel injury was subsequently made when the chest tube started draining faecal materials after the initial drainage of blood. There had been a similar report of herniated bowel into the chest through the diaphragmatic defect getting injured by the trocar during the chest tube insertion or the bowel becoming incarcerated and, subsequently, perforate due to transmural ischemia.^[7,23] Either the trocar or the herniation of the bowel through the diaphragmatic defect may have been responsible for the bowel injury.

To avoid bowel injury during the chest tube insertion, it is advised that the chest tube should be passed without using the inbuilt trocar especially if TDI is suspected. Another method that has been suggested to avoid injury to the bowel especially when masked with haemothorax was the use of video-assisted thoracoscopy. Video thoracoscopy and video laparoscopy could contribute to the diagnosis and treatment of these lesions, with possibilities for a better postoperative period^[10,24,25] and increased diagnostic yield, especially in patients with multiple rib fractures involving the lower chest wall.^[24,26]

Surgical management remains controversial, especially when the choice of the surgical approach, the technique, and the use of mesh or not was considered.^[14] In a report of 15 consecutive cases with TDI, laparotomy was the surgical approach preferred in most of the cases.^[27] But with the 14 consecutive cases in this series, the approach was via thoracotomy for all the cases. The reasons that may be responsible for the use of any of the surgical approaches are

the subspecialty of the surgeon and general surgeon versus thoracic surgeon respectively. However, an earlier report of the surgical approach in a centre with both specialists, thoracic and general surgeons, in the country, suggested the adoption of mixed surgical approaches.^[15]

The surgical approach for the thoracic surgeon is mainly via thoracotomy. The use of the thoracotomy approach allowed us to repair all the injured bowels and also the injured diaphragms. The space provided by the thoracotomy was quite enough to effect the bowel repair. In another study, the most common surgical approach was the transabdominal approach, which allowed for the complete exploration of the abdominal viscera for associated injuries and was effective in most cases with occult diaphragmatic injury.^[19] It seems that the greatest benefit for these patients would be their care by a multiprofessional team composed of thoracic and abdominal surgeons so that the choice of approach would not be conditioned simply by the surgeon's greater ability to manipulate one or the other of the cavities.^[10] Laparoscopic approach is associated with a decreased length of stay and more routine discharge than open abdominal and thoracotomy approaches,^[12,25] ditto for video-assisted thoracoscopy.^[25]

In all these, the thoracotomy offered the opportunity for the repair of the injured bowel and the diaphragm with a good outcome.

Conclusion

TDI still constitutes a diagnostic conundrum for the surgeon, and the thoracotomy approach was effective for both acute TDI and the repair of perforated bowel and associated injuries.

Recommendations

1. Clinical evaluation with the intent of proper chest auscultation
2. Avoid the use of trocar for chest tube insertion in a patient with chest trauma with massive haemothorax or the suspicion of diaphragmatic injury
3. Pass a nasogastric tube to decompress the stomach and possibly aid the stomach to fall back into the abdomen before passing the chest tube
4. Repeat a chest radiograph after the drainage of the pleural space
5. Severe blunt truncal injury should raise the suspicion of diaphragmatic injury.

Declaration of patient consent

The authors certify that they have obtained all appropriate patient consent forms. In the form the patient(s) has/have given his/her/their consent for his/her/their images and other clinical information to be reported in the journal. The patients understand that their names and initials will not be published and due efforts will be made to conceal their identity, but anonymity cannot be guaranteed.

Financial support and sponsorship

Nil.

Conflicts of interest

There are no conflicts of interest.

References

- Bosanquet D, Farboud A, Luckraz H. A review of diaphragmatic injury. *Respir Med CME* 2009;2:1-6.
- Lim KH, Park J. Blunt traumatic diaphragmatic rupture: Single-center experience with 38 patients. *Medicine (Baltimore)* 2018;97:e12849.
- Fair KA, Gordon NT, Barbosa RR, Rowell SE, Watters JM, Schreiber MA. Traumatic diaphragmatic injury in the American College of Surgeons National Trauma Data Bank: A new examination of a rare diagnosis. *Am J Surg* 2015;209:864-8; discussion 868-9.
- Turmak M, Deniz MA, Özmen CA, Aslan A. Evaluation of the multi-slice computed tomography outcomes in diaphragmatic injuries related to penetrating and blunt trauma. *Clin Imaging* 2018;47:65-73.
- Iochum S, Ludig T, Walter F, Sebbag H, Grosdidier G, Blum AG. Imaging of diaphragmatic injury: A diagnostic challenge? *Radiographics* 2002;22:S103-16; discussion S116-8.
- Kwon J, Lee JC, Moon J. Diagnostic significance of diaphragmatic height index in traumatic diaphragmatic rupture. *Ann Surg Treat Res* 2019;97:36-40.
- Beshay M, Krüger M, Singh K, Borgstedt R, Benhidjeb T, Bölke E, *et al.* Grave thoraco-intestinal complication secondary to an undetected traumatic rupture of the diaphragm: A case report. *Eur J Med Res* 2021;26:19.
- Gmachowska A, Pacho R, Anysz-Grodzicka A, Bakoń L, Gorycka M, Jakuczun W, *et al.* The role of computed tomography in the diagnostics of diaphragmatic injury after blunt thoraco-abdominal trauma. *Pol J Radiol* 2016;81: 522-8.
- Gao JM, Du DY, Li H, Liu CP, Liang SY, Xiao Q, *et al.* Traumatic diaphragmatic rupture with combined thoracoabdominal injuries: Difference between penetrating and blunt injuries. *Chin J Traumatol* 2015;18:21-6.
- Silva GP, Cataneo DC, Cataneo AJM. Thoracotomy compared to laparotomy in the traumatic diaphragmatic hernia. Systematic review and proportional. *Act Cir Bras* 2018;33:49-66.
- McDonald AA, Robinson BRH, Alarcon L, Bosarge PL, Dorion H, Haut ER, *et al.* Evaluation and management of traumatic diaphragmatic injuries: A practice management guideline from the Eastern Association for the Surgery of Trauma. *J Trauma Acute Care Surg* 2018;85:198-207.
- Paul S, Nasar A, Port JL, Lee PC, Stiles BC, Nguyen AB, *et al.* Comparative analysis of diaphragmatic hernia repair outcomes using the nationwide inpatient sample database. *Arch Surg* 2012;147:607-12.
- Offman RP, Spencer RM. Incarcerated diaphragmatic hernia with bowel perforation presenting as a tension pneumothorax. *West J Emerg Med* 2014;15:142-4.
- Thiam O, Konate I, Gueye ML, Toure AO, Seck M, Cisse M, *et al.* Traumatic diaphragmatic injuries: Epidemiological, diagnostic and therapeutic aspects. *Springerplus* 2016;5:1614.
- Adegboye VO, Ladipo JK, Adebo OA, Brimmo AI. Diaphragmatic injuries. *Afr J Med Med Sci* 2002;31:149-53.
- Okonta KE, Amadi CE, Okoh PD, Ekwunife CN. Thoracotomy for chest trauma: Indication, operative finding, and outcome. *Saudi Surg J* 2020;8:180-4.
- Tavakoli H, Rezaei J, Miratashi Yazdi SA, Abbasi M. Traumatic right hemi-diaphragmatic injury: Delayed diagnosis. *Surg Case Rep* 2019;6:92.
- Sekusky AL, Lopez RA. Diaphragm trauma. In: *StatPearls*. Treasure Island (FL): StatPearls Publishing; 2021.
- Turhan K, Makay O, Cakan A, Samancilar O, Firat O, Icoz G, *et al.* Traumatic diaphragmatic rupture: Look to see. *Eur J Cardiothorac Surg* 2008;33:1082-5.
- Shanmuganathan K, Mirvis SE. Imaging diagnosis of nonaortic thoracic injury. *Radiol Clin North Am* 1999;37:533-51, vi.
- Ekeke ON, Okonta KE. Trauma: A major cause of death among surgical inpatients of a Nigerian tertiary hospital. *Pan Afr Med J* 2017;28:6.
- Chen HW, Wong YC, Wang LJ, Fu CJ, Fang JF, Lin BC. Computed tomography in left-sided and right-sided blunt diaphragmatic rupture: Experience with 43 patients. *Clin Radiol* 2010;65:206-12.
- Mehrotra AK, Feroz A, Dawar S, Kumar P, Singh A, Khublani TK. Diaphragmatic rupture precipitated by intercostal chest tube drainage in a patient of blunt thoraco-abdominal trauma. *Lung India* 2016;33:85-7.
- Powell L, Chai J, Shaikh A, Shaikh A. Experience with acute diaphragmatic trauma and multiple rib fractures using routine thoracoscopy. *J Thorac Dis* 2019;11:1024-8.
- Okonta KE. The expected indications for video-assisted thoracoscopy surgery in Sub-Saharan Africa. *Sub-Saharan J Endosc Proced* 2022;1:2.
- Hussain A, Hunt I. Acute diaphragmatic injuries associated with traumatic rib fractures: Experiences of a major trauma centre and the importance of intra-pleural assessment. *J Chest Surg* 2021;54:59-64.
- Porojan VA, David OI, Coman IS, Coman EV, Draghici DA, Popescu C, *et al.* Traumatic diaphragmatic lesions—Considerations over a series of 15 consecutive cases. *Chirurgia (Bucur)* 2019;114:73-82.