



Case report

Dupilumab-associated blepharoconjunctivitis

Sefy A. Paulose, Suzanne W. Sherman, Lora R. Dagi Glass, Leejee H. Suh*

Edward S. Harkness Eye Institute, Columbia University Medical Center, New York, NY, USA



ARTICLE INFO

Keywords:

Dupilumab
Blepharoconjunctivitis
Lipiflow
Atopic dermatitis
Ocular side effects

ABSTRACT

Purpose: To report a case of dupilumab-associated blepharoconjunctivitis.

Observations: A 48 year-old Caucasian male presented with bilateral blepharitis, multiple chalazia, dry eye disease and significant papillary conjunctivitis. The past medical history included fourteen years of severe atopic dermatitis. After failed attempts to treat atopic dermatitis with topical corticosteroids, the patient enrolled into a four-year clinical trial of biweekly dupilumab injections. Four to six weeks after initiation of dupilumab, the patient reported blurred vision, ocular irritation and redness. Slit lamp examination demonstrated bilateral meibomian gland dysfunction, edematous eyelids with multiple chalazia and significant papillary conjunctivitis. Meibography by Lipiscan revealed significant truncation, atrophy and bifurcation of meibomian glands bilaterally. The patient's multiple chalazia were excised and eyelid hygiene was closely followed. Cliradex wipes and Avenova were added to the patient's regime and one session of Lipiflow treatment was administered. The patient continued this eyelid hygiene regimen along with neomycin/polymyxin B/dexamethasone ophthalmic ointment after each dupilumab infusion.

Conclusions and Importance: Five weeks after Lipiflow treatment with concomitant use of Cliradex and Avenova, visual acuity and ocular discomfort improved. Current treatment includes Cliradex eyelid wipes along with neomycin/polymyxin B/dexamethasone ophthalmic ointment for a week after each dupilumab infusion. Topical steroids and antibiotics with eyelid hygiene are effective ways to treat atopic dermatitis patients exhibiting dupilumab's ocular side effects. Lipiflow therapy may also help in treatment.

1. Introduction

Dupilumab is a fully human monoclonal antibody specifically preventing the signaling of IL-4 and IL-13 by inhibiting the IL-4 receptor alpha subunit. This treatment has been evaluated for diseases that are implicated by Th2 pathways predominant with IL-4 and IL-13 such as moderate-to-severe atopic dermatitis, asthma and chronic sinusitis. Dupilumab's dual antagonism against these cytokines potently inhibits the Th2 effector responses resulting in significant clinical improvements. Studies evaluating the administration of dupilumab have shown to be effective in terms of clinical outcome and patient-reported symptoms of anxiety and health-related quality of life.

Dupilumab has reported possible ocular side effects such as conjunctivitis, blepharitis, keratitis, eye pruritus and dry eye. Specifically, in patients with atopic dermatitis, studies have reported an increased incidence of conjunctivitis with dupilumab use. To our knowledge, this is the first report of blepharoconjunctivitis associated with dupilumab use.

2. Case report

A 48-year-old Caucasian male presented with bilateral blepharitis, multiple bilateral chalazia and dry eye complaining of blurred vision, ocular irritation and redness starting four to six weeks after dupilumab use. Fourteen years ago, the patient was diagnosed with severe atopic dermatitis. After failed treatment with several topical corticosteroids, the patient enrolled in a clinical trial of biweekly dupilumab injections for the past four years.

Approximately four to six weeks following the initiation of dupilumab, significant improvement in symptoms of atopic dermatitis was noted. Six months later, multiple chalazia developed which worsened with topical antibiotic drops prescribed by an outside ophthalmologist. Instead, the patient attempted conservative care with warm compresses. Despite these efforts, persistent chalazia resulted in induced astigmatism and reduced vision and patient presented to our clinic for excisions. On presentation, his best corrected visual acuity was 20/40 in right eye and 20/30 in the left eye. Slit lamp examination revealed bilateral meibomian gland dysfunction, edematous eyelids with multiple chalazia and significant papillary conjunctivitis with inferior

* Corresponding author. Edward S. Harkness Eye Institute, Columbia University Medical Center, 635 West 165th Street, New York, NY, 10032, USA.
E-mail address: lhs2118@cumc.columbia.edu (L.H. Suh).

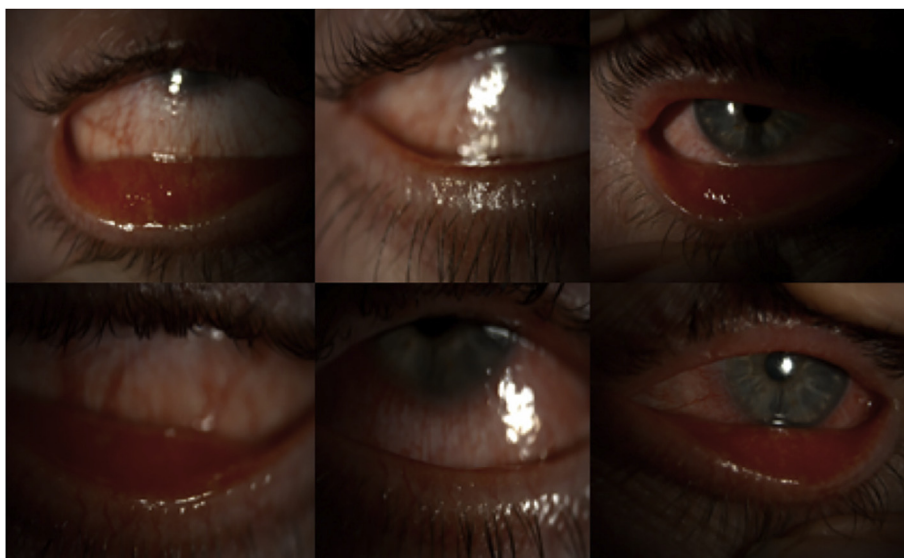


Fig. 1. External photographs showing bilateral blepharoconjunctivitis and left lower eyelid chalazion.

bulbar injection. There was a bilateral superficial punctate keratitis and a decreased tear breakup time noted. The rest of the exam was within normal limits. He was started on neomycin/polymyxin B/dexamethasone ophthalmic ointment and tobramycin/dexamethasone eyedrops twice a day. He ultimately underwent excision of his multiple chalazia.

Examination three weeks after initiation of therapy showed newly presenting early corneal scarring in left eye with no significant improvement in his symptoms. His treatment was subsequently changed to loteprednol eye drops and frequent preservative-free artificial tears. Despite being on one month of loteprednol eye drops, the patient presented with persistent blepharoconjunctivitis and significant Meibomian gland disease. Under slit lamp examination, superficial punctate keratitis with bilateral peripheral corneal neovascularization were noted (Fig. 1). The patient felt that his ocular symptoms improved on the loteprednol but opted to stop as he felt it was causing depression. As a result, the patient was placed back on neomycin/polymyxin B/dexamethasone ophthalmic ointment.

Meibography by LipiScan revealed significant truncation, atrophy and bifurcation of the patient's meibomian glands bilaterally (Fig. 2). The patient underwent manual debridement of his eyelids margin. Avenova and cliradex wipes were added to his lid hygiene regime

followed by Lipiflow treatment.

At follow up five weeks after the Lipiflow treatment, the best corrected visual acuity was 20/40 in both eyes. Patient reported significant improvement in ocular discomfort since the last visit. A cotton applicator test showed significant improvement of meibomian gland expression and a stimulation of 0.3 PSI pressure on the patient's eye by the meibomian gland evaluator examined the oil quality, quantity and number of functional glands. Slit lamp examination identified mild improvement of palpebral conjunctiva with stable corneal presentation. Current treatment includes Cliradex eyelid wipes, Avenova along with neomycin/polymyxin B/dexamethasone ophthalmic ointment for a week after each dupilumab infusion.

3. Discussion

As the most common inflammatory skin disorder, atopic dermatitis affects 10% of the population worldwide with approximately 20% of patients suffering from moderate-to severe disease.¹ Despite this high incidence, current treatment options are limited and symptoms for moderate-to-severe atopic dermatitis are inadequately controlled by topical corticosteroids. However, dupilumab is the first FDA-approved biological systemic treatment for moderate-to-severe atopic dermatitis.²

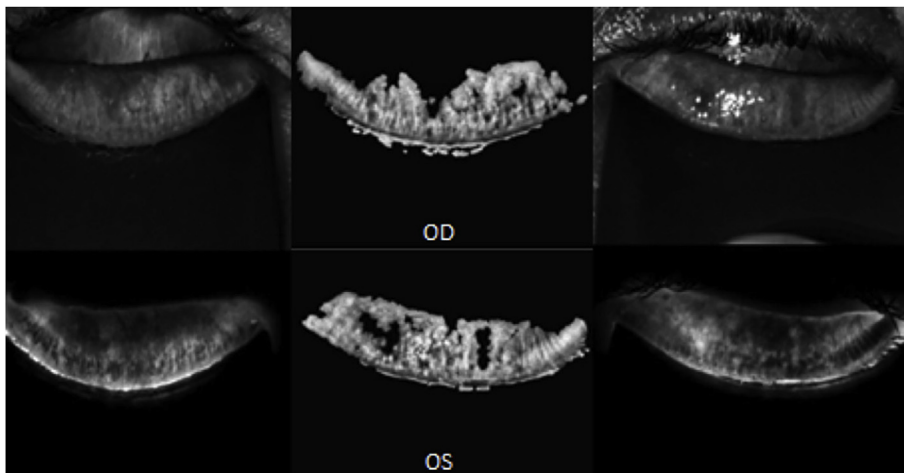


Fig. 2. LipiScan meibography image of the right and left eye, respectively, of a blepharoconjunctivitis patient showing overall truncation and atrophy of meibomian glands.

In addition to improving symptoms of atopic dermatitis, clinical trials have also reported a reduction of patient-reported symptoms of anxiety, depression and improvement in overall quality of life.³

Several trials have reported ocular complications with dupilumab use for atopic-dermatitis.^{1,3–5} In a randomized, double-blind, placebo-controlled clinical trial, conjunctivitis was also reported in 16% of dupilumab users as compared to 9% of the placebo group.² In another randomized placebo-controlled phase IIb trial, 2–11% of atopic dermatitis patients using dupilumab reported conjunctival infections, irritations and inflammations as compared to the 3% in the placebo group.¹ In this trial, as well as another randomized placebo-controlled phase III trial, the incidence of ocular side effects varied depending on the patient's dupilumab dosing regimen.^{1,3}

A few further classified ocular side effects as non-infectious allergic conjunctivitis and infectious conjunctivitis which includes conjunctivitis of unspecified cause.^{3,5} One of these trials, indicated an increased occurrence of non-infectious conjunctivitis in patients using dupilumab ranging from 14 to 19% in contrast to 8% in the placebo group in a phase IIb trial.⁵ Unlike our patient, most reports of conjunctivitis events were noted to be mild to moderate in severity.^{5,6} More than 75% of the reported conjunctivitis resolved during the trial treatment, however one of 920 patients and one of 740 patients withdrew from the trial treatment due to adverse effects.³ Additionally, Barnes et al.⁷ presented a patient with severe-atopic dermatitis who discontinued dupilumab treatment due to eyelid inflammation and cicatricial ectropion.

Although the underlying mechanism and cause of conjunctivitis in these cases are still unclear, dupilumab use for asthma or nasal polyposis was not associated to have higher rates of conjunctivitis. This suggests a unique relationship between dupilumab use for atopic dermatitis and ocular complications rather than an inherent effect of dupilumab.^{3,6}

Studies have not revealed why the incidence of conjunctivitis and severity of its presentation varies with dupilumab use. One trial found conjunctivitis occurrence in 3% and 5% of users in weekly and biweekly dose groups, respectively thus postulating that there may be an inverse relationship between serum concentrations of dupilumab.³ Some hypothesize that this inverse relationship may be due to the pharmacokinetics of dupilumab such that there is a higher target burden or lower tissue distribution.⁶ The local area's low serum concentration may play a role in the inhibition of TH2 cells ultimately leading to conjunctivitis.⁶ However, this inverse relationship is not reported in other varied dupilumab dosing regimen studies.^{1,5}

Others suggest dupilumab's blocked IL-4 and IL-13 response may result in an increased activity of ligands involved in atopic keratoconjunctivitis.⁶ However, in the phase III trial, atopic keratoconjunctivitis was reported in less than 0.5% users with no significant difference between the trial and placebo group.⁶ Of note, these cases were not examined by ophthalmologists which may not render the true incidence of conjunctivitis or a subtype of conjunctivitis with dupilumab use.⁶

In our patient, dupilumab was helpful in treating the symptoms of atopic dermatitis. However, the continuous use of dupilumab resulted in significant blepharoconjunctivitis. Treatment of blepharoconjunctivitis includes a variety of therapies. Topical and oral antibiotics and steroids have shown to resolve most refractory cases of blepharoconjunctivitis. Stimulation of meibomian glands with warm lid compressions and eyelid hygiene have also been reported to alleviate blepharoconjunctivitis.⁸

Eyelid hygiene with Lipiflow, a thermal pulsation system, was elected due to the severity and recurrence of blepharoconjunctivitis, multiple chalazia and dry eye syndrome seen in our patient. Lipiflow is therapeutically used to increase the quality of gland secretion, lipid layer thickness, long term ocular surface disease index and standard patient evaluation of eye dryness (SPEED) in dry eye patients.⁹ Lipiflow treatment consists of heating both the inner and outer eyelid surfaces,

while unblocking glandular plugs while simultaneously mechanically massaging meibomian glands to relieve any obstruction.⁹ Several studies have reported significant improvement of tear film break up time and dry eye symptoms after one twelve-minute treatment session with Lipiflow.^{9,10} A single Lipiflow session has also shown to be as effective as three months of twice daily warm compresses.¹⁰ In our particular case of blepharoconjunctivitis that was unresponsive to medical treatment, improving meibomian gland dysfunction using eyelid hygiene with Lipiflow treatment may have helped improve the blepharoconjunctivitis.

In our patient, dupilumab significantly improved symptoms of severe atopic dermatitis while also improving patient-reported quality of life. However, with continued use of dupilumab, adverse events such as blepharoconjunctivitis and dry eye disease were noted. Rather than discontinuing dupilumab, supportive care with topical steroids, topical antibiotics, and lid hygiene were seen to be successful. Treatment with Lipiflow may also help with the patient's signs and symptoms.

Patient consent

The patient consented to publication of the case orally. This report does not contain any personal information that could lead to the identification of the patient.

Funding

No funding or grant support.

Conflicts of interest

The following authors have no financial disclosures: SAP, SWS, LDG, LHS.

Authorship

Each of the authors has contributed to, read and approved this manuscript. All authors attest that they meet the current ICMJE criteria for Authorship.

Acknowledgements

None.

References

1. Thaci D, Simpson EL, Beck LA, et al. Efficacy and safety of dupilumab in adults with moderate-to-severe atopic dermatitis inadequately controlled by topical treatments: a randomised, placebo-controlled, dose-ranging phase 2b trial. *Lancet*. 2016;387:40–52.
2. Dupixent (Dupilumab) [package insert]. Tarrytown, NY: Regeneron Pharmaceuticals Inc.; 2017.
3. Simpson EL, Bieber T, Guttman-Yassky E, et al. Two phase 3 trials of dupilumab versus placebo in atopic dermatitis. *N Engl J Med*. 2016;375:2335–2348.
4. Ou Z, Chen C, Chen A, et al. Adverse events of Dupilumab in adults with moderate-to-severe atopic dermatitis: a meta-analysis. *Int Immunopharmacol*. 2018;54:303–310.
5. Blauvelt A, de Bruin-Weller M, Gooderham M, et al. Long-term management of moderate-to-severe atopic dermatitis with dupilumab and concomitant topical corticosteroids: a 1-year, randomised, double-blinded, placebo-controlled, phase 3 trial. *Lancet*. 2017;389:2287–2303.
6. Mennini M, Simpson EL, Akinlade B, et al. Two phase 3 trials of dupilumab versus placebo in atopic dermatitis. *N Engl J Med*. 2017;376:1090–1091.
7. Barnes AC, Blandford AD, Perry JD. Cicatricial ectropion in a patient treated with dupilumab. *Am J Ophthalmol Case Rep*. 2017;7:120–122.
8. Ianchenko SV, Sakhnov SN, Malyshev AV, et al. [Treatment of chronic allergic blepharoconjunctivitis]. *Vestn Oftalmol*. 2014;130(78):80–84.
9. Blackie CA, Carlson AN, Korb DR. Treatment for meibomian gland dysfunction and dry eye symptoms with a single-dose vectored thermal pulsation: a review. *Curr Opin Ophthalmol*. 2015;26:306–313.
10. Zhao Y, Veerappan A, Yeo S, et al. Clinical trial of thermal pulsation (LipiFlow) in meibomian gland dysfunction with pretreatment meibography. *Eye Contact Lens*. 2016;42:339–346.