


CASE REPORT

Open Access



Type II Pfeiffer misdiagnosed as Crouzon syndrome with additional features of supernumerary teeth and localized symmetrical gigantism: a case report

Karim P. Manji^{1*} , Mariam Mngoya Massomo², Edna Samson Akyoo² and McLean Abisai Luvinga²

Abstract

Background: Pfeiffer syndrome is among the syndromes seen in the recognized variant of the FGFR2 gene. There are several conditions related to this variant and a very closely related condition is Crouzon syndrome. This case is important to report because the neonate was a delayed referral from another region, without clear counseling and information on the gravity of situation. We describe additional features, not previously described in Pfeiffer or Crouzon syndrome, supernumerary teeth and localized symmetrical gigantism of thumbs and great toes on both sides. That a genetic testing is essential to further manage and counsel to avoid lost opportunities for future births. Several cases are seen in this unit annually, and there is need for a more consolidated and comprehensive counseling and genetic testing. Once early diagnosis is done and the case is recognized to be untreatable, it was avert the need to refer.

Case presentation: A 2-week-old male African neonate referred from outside the region, presented with massive proptosis soon after delivery, with signs of pan-ophthalmitis and neonatal sepsis. The infant had additional multiple malformations and features initially diagnosed as Crouzon syndrome, but later confirmed after genetic testing to be Type II Pfeiffer syndrome. A through clinical evaluation and genetic testing would prevent undue referral to a tertiary center, or if needed, the baby should have been referred much earlier. The uniqueness of this case is the presence of supernumerary teeth.

Conclusion: A complicated, difficult to remedy case, referred to tertiary center, investigated, and sent back home with no significant intervention. Genetic test confirmed the typical findings of Pfeiffer Type II. Presented for describing additional unique features of supernumerary teeth and localized gigantism and ethical challenges in management.

Keywords: Type II Pfeiffer syndrome, Early diagnosis, Ethical issues, Genetic testing

Background

Pfeiffer syndrome is among the syndromes seen in the recognized variant of the FGFR2 gene. There are several conditions related to this variant and a very closely

related condition is Crouzon syndrome. Several similar cases are seen in this unit annually, and there is need for a more consolidated and comprehensive counseling and genetic testing. Once early diagnosis is made and the case is recognized to be untreatable or futile, it would avert the need to refer to a tertiary center

*Correspondence: kpmanji@gmail.com

¹ Pediatrics and Child Health, Muhimbili University of health and Allied Sciences, P.O. Box 65001, Dare-es-Salaam, Tanzania
Full list of author information is available at the end of the article



© The Author(s) 2022. **Open Access** This article is licensed under a Creative Commons Attribution 4.0 International License, which permits use, sharing, adaptation, distribution and reproduction in any medium or format, as long as you give appropriate credit to the original author(s) and the source, provide a link to the Creative Commons licence, and indicate if changes were made. The images or other third party material in this article are included in the article's Creative Commons licence, unless indicated otherwise in a credit line to the material. If material is not included in the article's Creative Commons licence and your intended use is not permitted by statutory regulation or exceeds the permitted use, you will need to obtain permission directly from the copyright holder. To view a copy of this licence, visit <http://creativecommons.org/licenses/by/4.0/>. The Creative Commons Public Domain Dedication waiver (<http://creativecommons.org/publicdomain/zero/1.0/>) applies to the data made available in this article, unless otherwise stated in a credit line to the data.

The case

A male African baby born at term. He is the third sibling. Uneventful pregnancy and delivered normally. Mother is in early third decade and father in the later third decade. Non-Consanguineous. Referred to this tertiary neonatal unit for further management in the second week of life.

Presented with multiple congenital malformations, the most prominent of which was externally protruding eyes, with abnormal facies. Wide forehead, clover shaped head, and abnormal ears, nasal blockage, supernumerary teeth, and locally hypertrophic toes and thumbs on both sides.

Further physical examination

Proptosis, Cranio-synostosis, clover head, supernumerary teeth, localized gigantism. Severe, widely opened sutures, high arched palate, and nasal obstruction, low set ears. In short, there were abnormalities of facial appearance with proptosis, skull shape, cranial sutures with wide open from frontal to occipital, pinnae, skeletal system with kyphoscoliosis (Figs. 1A–C, 2A, B).

Cardiac examination revealed an Atrial Septal Defect (ASD) and a Ventricular Septal Defect (VSD). There were no clinical features of heart failure, and cardiologist was of the opinion of conservative management for time being.

The ophthalmologist reviewed the child, but since there was severe edema and pan-ophthalmitis, it was difficult to place sutures to close the eyelids, and due to the configuration of spine and neck, it was not possible to provide anesthesia for enucleating.

The unique features of this child were supernumerary teeth and large (localized gigantism) thumbs and great toes bilateral. These are the features not commonly described and add to medical literature particularly to differentiate between this case and the phenotypically similar Crouzon syndrome.

Investigations

MRI of the Brain revealed abnormal skull configuration and prematurely fused base of skull, with ventriculomegaly and poor developed corpus callosum and vermis. The cortex was poorly configured (Fig. 3A, B)

ECHO revealed an atrial septal defect and a ventriculo-septal defect.

Genetic testing of the child was done through a genetic firm which helps to do free genetic testing (4) and a complete genome sequencing. The results showed a heterozygous pathogenic variant for Pfeiffer syndrome was identified in the FGFR2 gene. The genetic diagnosis of an autosomal dominant FGFR-related craniosynostosis is confirmed. Genetic review:

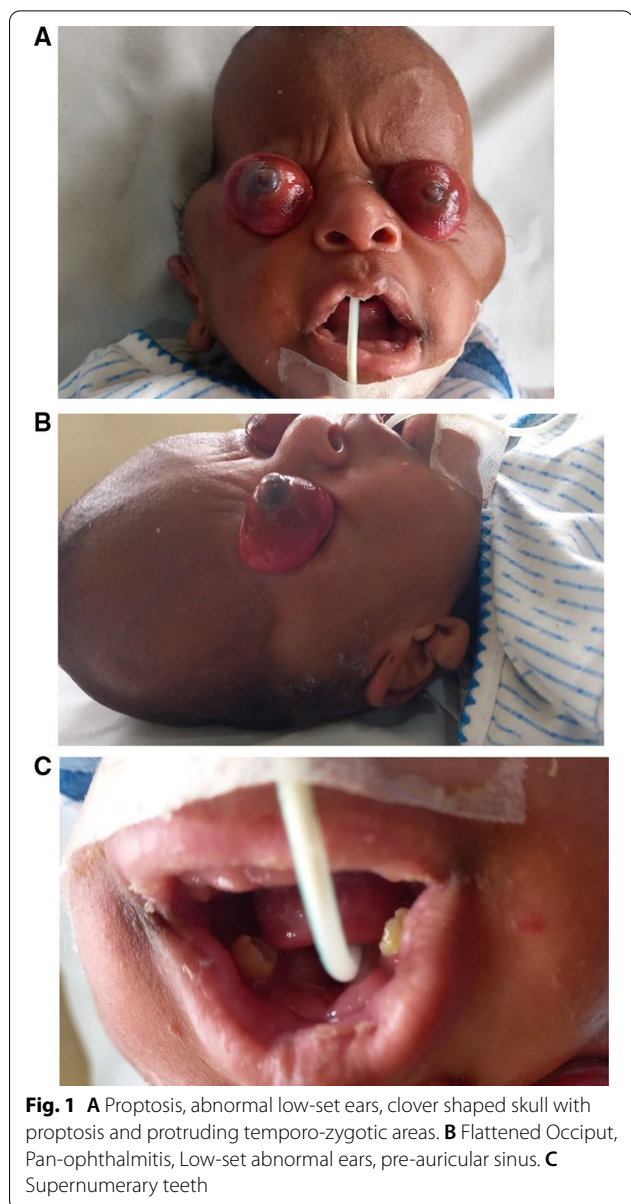
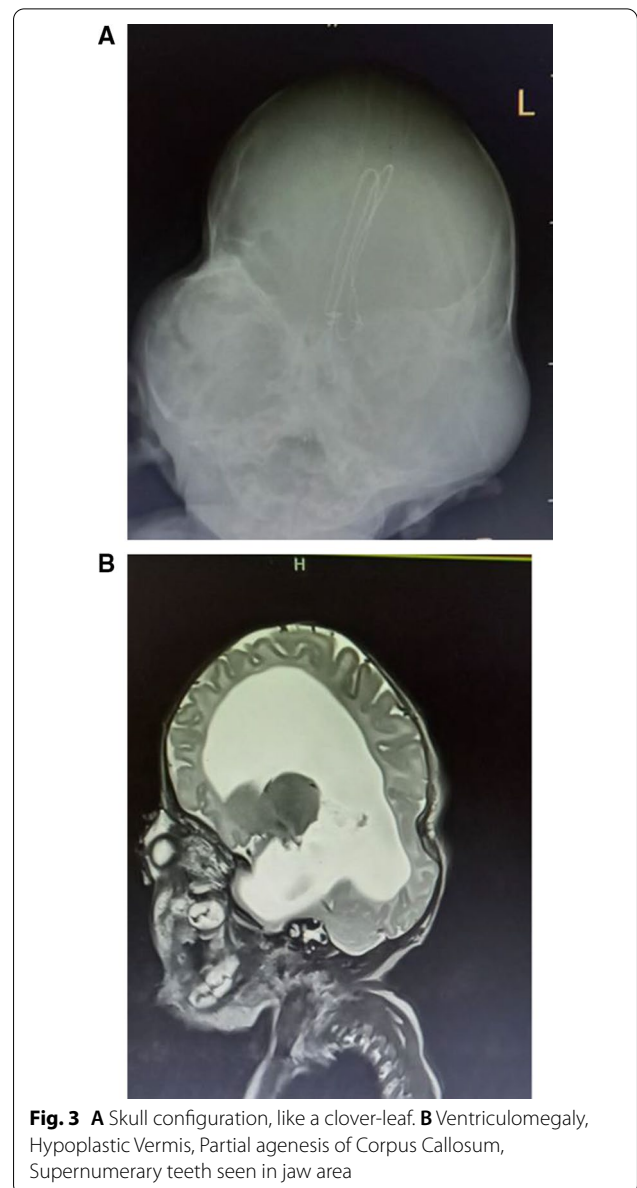
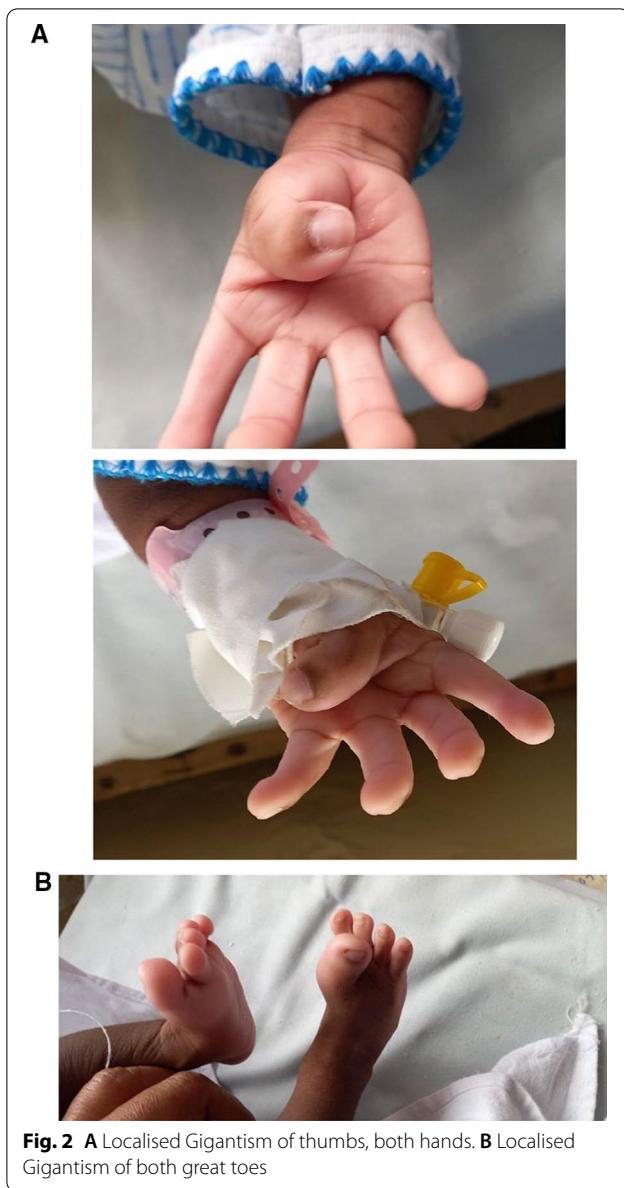

Fig. 1 **A** Proptosis, abnormal low-set ears, clover shaped skull with proptosis and protruding temporo-zygotic areas. **B** Flattened Occiput, Pan-ophthalmitis, Low-set abnormal ears, pre-auricular sinus. **C** Supernumerary teeth

The dried blood spots for genetic testing was done after due consent from the mother. This was sent to Centogene in Germany, who provided free testing for our hospital patients, under our agreements. The report described the presence of FGFR2 variant c.870G>C p.(Trp290Cys). This variant causes an amino acid change from Trp to Cys at position 290. This is the typical variant for Pfeiffer syndrome Type II. This variant has been described previously. Eight disorders are recognized with this FGFR mutation. These include Pfeiffer syndrome, Apert syndrome, Crouzon syndrome, Beare-Stevenson syndrome, FGFR2-related isolated coronal synostosis, Jackson-Weiss syndrome,



Crouzon syndrome with acanthosis nigricans (AN), and Muenke syndrome [1–3]

Differential diagnosis

Pfeiffer Type II and Crouzon Syndrome are very closely related in their phenotype.

Treatment

Conservative management

1. There was eye dressing and sterile patch daily.
2. Nasogastric feeds , with expressed mothers’ milk
3. Antibiotic drops for the eye

4. Lasix and Aldactone to relieve congestive cardiac failure.

Parental carrier testing is recommended to establish whether the detected variant is inherited or de novo. We recommend clinical evaluation for genotype-phenotype-correlation.

Outcome

The child stayed for almost seven weeks at the neonatal unit. Consultations were done with ophthalmologists, neurologists and cardiologists. The neurologist was the opinion of conservative management. The child was

discharged back home to the region and counseled about the gravity of the situation. Child died at home within a week of discharge. From the telephone interview, the child died of possible septicemia and multi-organ failure. She described difficult breathing, inability to feed and inability to pass urine. Due to social-cultural reasons we did not dwell further in the verbal autopsy of the child.

Discussion

This is a genetic disorder. The anomalies could have been detected during antenatal period using an antenatal ultrasound scan for anomalies.

This unit receives about 2-3 cases of similar nature annually; these are clinically very similar. It is necessary to continue to inform and educate the colleagues about the need for early referral and treatment.

Similar cases have been published by colleagues from this unit and a clinical diagnosis made, the child had bilateral choanal atresia [4].

Ten percent of neonatal teeth are supernumerary, and unusual in neonates with Crouzon, and those described in Pfeiffer are usually conical and more on the incisor. These were molars and had cusps [5].

Syndactyly distinguishes Aperts syndrome from Crouzon syndrome. This baby has separate fingers, but the thumbs and toes were hypertrophied, and appeared to be like localized gigantism [6, 7].

Environmental factors include when to refer, where to refer and whether to refer at all and these overlap with the ethical dilemmas.

Ethical dilemmas in the neonatal unit include issues like these of decisions of when and where to refer. This case highlights various issues of diagnosis and management of this rare disease. Pfeiffer syndrome is reported to happen in about 1: 80,000 deliveries. There was no ultrasound done [8], and on delivery immediate eye care was not provided. The baby was fed by Nasogastric tube. The eyes developed exposure keratitis and developed panophthalmitis as seen in the Fig. 1A, B. Genetic counseling was not done, and the father was unable to travel to this center for further counseling. We received the results from the Centogene [9] a month later. After contacting the mother, she informed us of the child's demise and was clearly disappointed and not willing to discuss anything further, although she did not mind her child to be reported in medical literature. for educating purpose.

Pfeiffer syndrome and Crouzon syndrome are compatible with life, and many children can live near normal life. This child has many additional malformations. A rapid intervention and multidisciplinary approach are required. The factors related to finances and travel from another region also needs to be considered.

Craniofacial dysostosis is a genetically transmitted complex disorder. The specific mutation is spontaneous and is not associated with consanguinity. The genetic testing revealed FGFR-a specific mutation in Chromosome 10. It has a variable penetrance and manifestation, and this baby has a significant gene penetrance.

In conclusion

We provide unreported features of Supernumerary teeth and localized gigantism of toes and thumbs in Type II Pfeiffer syndrome. This child presented with several ethical issues of concern, challenges in Clinical management and genetic counseling.

Acknowledgements

1. Dr Kandi Muze of department of Pediatrics and Child health, Muhimbili National Hospital. 2. The Ophthalmology, Neurology team at the Muhimbili National Hospital. 3. CENTOGENE AG, Am Strande 7, 18055, Rostock, Germany (+49(0)381801113-416, www.centogene.com) for the free genetic testing and report.

Author contributions

The authors have contributed to the clinical diagnosis and care of the patient. KM wrote the manuscript and all the authors read, reviewed and approved the final manuscript. KM is the lead author; others are equal contributors. All authors read and approved the final manuscript.

Funding

No funding. The Centogene provided the genetic testing free.

Availability of data and materials

Case report and genetic testing result attached as submission

Declarations

Ethics approval and consent to participate

The mother consented for the pictures for educational purposes. Anonymization: The name, the dates and the region from which the neonate was referred from have not been mentioned, for anonymization.

Consent for publication

Written informed consent was obtained from the patient's legal guardian for publication of this case report and any accompanying images. A copy of the written consent is available for review by the Editor-in-Chief of this journal.

Competing interests

No competing interests.

Author details

¹Pediatrics and Child Health, Muhimbili University of health and Allied Sciences, P.O. Box 65001, Dare-es-Salaam, Tanzania. ²Neonatal Unit, Muhimbili National Hospital, P.O. Box 65001, Dar-es-Salaam, Tanzania.

Received: 18 March 2022 Accepted: 21 August 2022

Published online: 01 November 2022

References

1. Tartaglia M, Valeri S, Velardi F, Di Rocco C, Battaglia PA. Trp290Cys mutation in exon IIIa of the fibroblast growth factor receptor 2 (FGFR2) gene is associated with Pfeiffer syndrome. *Hum Genet.* 1997;99(5):602–6. <https://doi.org/10.1007/s004390050413>.
2. Ariga H, Endo Y, Ujiiie N, Ishii T, Ishibashi N, Fujita T, Suzuki H. Trp290Cys mutation of the FGFR2 gene in a patient with severe Pfeiffer syndrome

- type 2. *Pediatr Int.* 2001;43(3):293–5. <https://doi.org/10.1046/j.1442-200x.2001.01379.x>.
3. Nazzaro A, Della Monica M, Lonardo F, Di Blasi A, Baffico M, Baldi M, Nazzaro G, De Placido G, Scarano G. Prenatal ultrasound diagnosis of a case of Pfeiffer syndrome without cloverleaf skull and review of the literature. *Prenat Diagn.* 2004;24(11):918–22. <https://doi.org/10.1002/pd.844>.
 4. Amiji I, Kalezi ZE, Abdulshakoor A, Tarimo JF, Leiya R, Zuechner A, Naburi HE, Massawe A, Manji KP. Pfeiffer Syndrome type 2; A case report of cranio-orbitofaciostenosis with bilateral choanal atresia at Muhimbili National Hospital Tanzania. *Clin Case Rep.* 2020;8(9):1613–7. <https://doi.org/10.1002/ccr3.2959>;PMID:32983461;PMCID:PMC7495869.
 5. Torun GS, Akbulut A. Crouzon syndrome with multiple supernumerary teeth. *Niger J Clin Pract.* 2017;20(2):261–3. <https://doi.org/10.4103/1119-3077.187332>.
 6. Faizan M, Ahmed S, Khalid S, Zahid M. Localized gigantism. *Saudi Med J.* 2015;36(6):762–3.
 7. Mathijssen IM and Working Group on Craniosynostosis. Pfeiffer syndrome, another craniosynostosis, is also epitomized by short, broad big toes and thumbs in contrast to the previously mentioned normal digits of those with Crouzon syndrome. Guideline for Care of Patients with the Diagnoses of Craniosynostosis. *J Craniofac Surg.* 2015;26(6):1735–807.
 8. Blaumeiser B, Loquet P, Wuyts W, Nöthen MM. Prenatal diagnosis of Pfeiffer syndrome type. *Prenat Diagn.* 2004;24(8):644–6. <https://doi.org/10.1002/pd.960>.
 9. Centogene GmbH . The rare disease company. Am Strande 7, 18055 Rostock, Germany www.centogene.com. Accessed 25 May 2022.

Publisher's Note

Springer Nature remains neutral with regard to jurisdictional claims in published maps and institutional affiliations.

Ready to submit your research? Choose BMC and benefit from:

- fast, convenient online submission
- thorough peer review by experienced researchers in your field
- rapid publication on acceptance
- support for research data, including large and complex data types
- gold Open Access which fosters wider collaboration and increased citations
- maximum visibility for your research: over 100M website views per year

At BMC, research is always in progress.

Learn more biomedcentral.com/submissions

