

Case Report

DOI: 10.22114/ajem.v0i0.77

Extranodal Natural Killer/T-cell Lymphoma in a Child with a Prior History of Nasal Trauma: a Case ReportSuha N. Aloosi¹, Shakhawan M. Ali^{2*}, Vian F. Mohammed³, Payman Kh. Mahmud⁴, Hemin A. Hassan⁵

1. Department of Oral and Maxillofacial Surgery, School of Medicine, Faculty of Dentistry, University of Sulaimany, Kurdistan Region, Iraq.

2. KBMS Trainee, Maxillofacial Department, Sulaimany Teaching Hospital, Sulaimany, Kurdistan Region, Iraq.

3. Hiwa Hospital for Blood Disease and Cancer, Sulaimany, Kurdistan Region, Iraq.

4. KBMS Trainee, Oral medicine Department, Sulaimany Teaching Hospital, Sulaimany, Kurdistan Region, Iraq.

5. Histopathologist and Laboratory Manager, Hiwa Oncology Hospital, Sulaimany, Kurdistan Region, Iraq.

*Corresponding author: Shakhawan M. Ali; Email: shakhawandr@hotmail.com

Published online: 2018-04-08

Abstract

Introduction: Facial lesions usually have a benign self-limited prognosis, but in rare cases they have a poor outcome. Extranodal natural killer/T-cell lymphoma (ENK/TCL) is a rare aggressive lesion presenting with a midline facial lesion that can easily be misdiagnosed. Diagnosis is often difficult and requires a thorough clinical examination and the use of immunohistochemistry for analysis of biopsies. Such malignancies affecting the head and neck area provide an interesting but difficult diagnosis. The purpose of this article is to report a severe case of ENK/TCL-nasal type in a boy with a previous history of nasal trauma.

Case presentation: An 11-year-old boy was referred to the maxillofacial unit of Sulaimany Teaching Hospital, Iraq, with midline facial destruction. The patient stated that about 6 months prior he had fallen down and suffered nasal trauma; 3 months after the trauma, an asymptomatic ulcer appeared and gradually increased in size. Two biopsies were performed with no conclusive results. In the third biopsy, histology showed atypical lymphoid tissue surrounded by intense necrosis. The diagnosis was confirmed by immunohistochemistry. The treatment of choice was chemotherapy followed by radiotherapy. The patient had a satisfactory response but 2 months later during chemotherapy the patient unfortunately died from a pulmonary embolism.

Conclusion: Suspicious midline ulcerative lesions in the head and neck region must have ENK/TCL considered in the differential diagnosis and repeated biopsies may be necessary to confirm the diagnosis.

Key words: Case reports; Child; Face; Head and neck neoplasms; Lymphoma, non-Hodgkin

Cite this article as: Aloosi SN, Ali ShM, Mohammed VF, Mahmud PKh. Extranodal Natural Killer/T-cell Lymphoma in a Child with a Prior History of Nasal Trauma: A Case Report. *Adv J Emerg Med.* 2018;2(3): e34.

INTRODUCTION

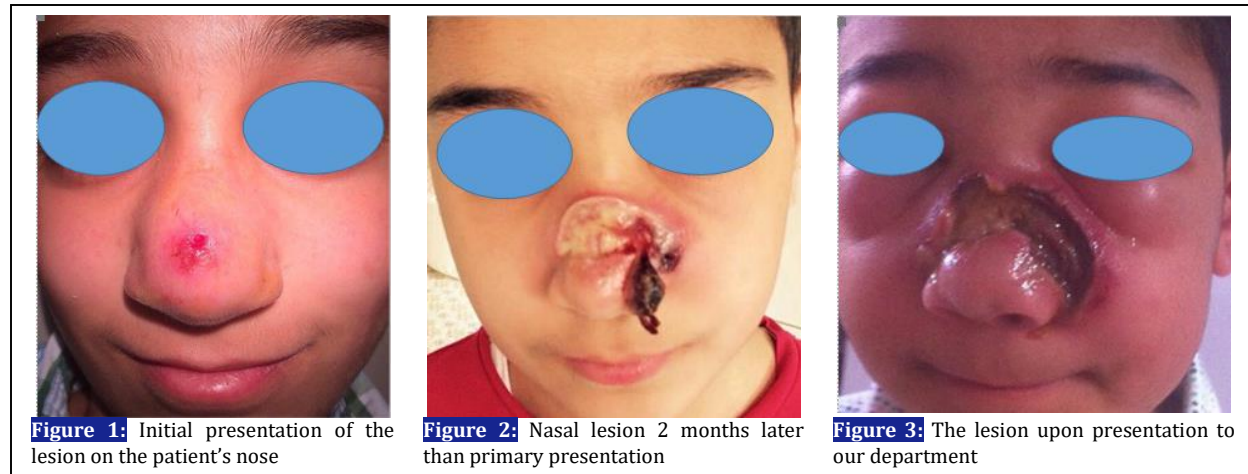
Facial lesions presenting with purulent discharge following a traumatic event in a person who underwent surgery likely suggest a diagnosis such as sinusitis, soft tissue infection or surgical complications. Extranodal natural killer/T-cell lymphoma (ENK/TCL) is a rare aggressive cancer that presents with a midline facial lesion that could easily be misdiagnose (1, 2). Such malignancies affecting the head and neck area form an interesting but difficult diagnosis. The purpose of this article is to report a severe case of ENK/TCL-nasal type in a boy with a previous history of nasal trauma.

CASE PRESENTATION

An 11-year-old boy was referred to the maxillofacial unit of Sulaimany Teaching Hospital, Iraq with midline facial destruction. The patient

stated that about 6 months prior he had fallen and suffered a nasal fracture and a septal hematoma, and then underwent surgery for reduction of the fractured nasal bone with hematoma drainage under general anesthesia. He had a complete recovery after one month. However, 3 months after the traumatic event, an ulcer like a site of an insect bite (figure 1) appeared and did not heal for 2 weeks, gradually increasing in size (figure 2). As the lesion enlarged, his nose became blocked with a purulent discharge, leading to a diagnosis of chronic sinusitis.

On admission to our hospital unit, destruction of the entire midface was apparent (figure 3). He had fever, headache, and appetite loss; disfiguring erosion of the nose; conjunctivitis; and also swelling of the bilateral periorbital, eyelids, and lower part of the nose. There were no intraoral



lesions. The regional lymph nodes were not enlarged. The chest was also normal clinically and radiologically. A computed tomography (CT) scan of the face and paranasal sinuses revealed an irregular enhancing lesion in the affected region of the nose extending to both nasal cavities and the ethmoid sinus with erosion and perforation of the nasal septum. The brain parenchyma was normal. Intravenous fluids and antibiotics were given and during cleaning & debridement of the wound a biopsy was taken. Daily irrigation of the wound was started. The patient was not anemic, was HIV-seronegative and did not have syphilis. There was leukocytosis and lymphocytosis, and a culture of the purulent discharge from the lesion grew fungal hypha, so he was given Amphotericin-B 1 mg/kg/day. The biopsy of the lesion showed mucoid material mixed with a fibrinopurulent exudate, with no evidence of malignancy. A second biopsy showed nonspecific inflammation and then a third biopsy was performed and an atypical lymphocytic infiltrate was found, suggesting malignancy (Figure 4). Immunohistochemistry analysis of the biopsy specimen was strongly positive for cytoplasmic CD3, P53, and CD56. All of these features confirmed the diagnosis of ENK/TCL-nasal type with a T immunophenotype (figure 5). Staging was performed by a medical oncologist through a complete blood count and film, ESR, lactate dehydrogenase (LDH), and a CT scan of the brain, neck, chest, and abdomen, also bone marrow aspiration and biopsy with CSF cytology were performed. PET scanning was not available. The patient was staged with a localized destructive lesion with no metastasis associated with a high LDH.

Chemotherapy was started using an adriamycin and L-asparaginase containing regimen (UKALL 2003 protocol) because this type of non-Hodgkin

lymphoma (NHL) usually responds well to such chemotherapy with cranial prophylaxis. At the end of the induction phase of treatment, he entered a very good partial remission (Figure 4). During the consolidation phase, he developed sagittal vein thrombosis and febrile neutropenia as a complication of chemotherapy. Chemotherapy

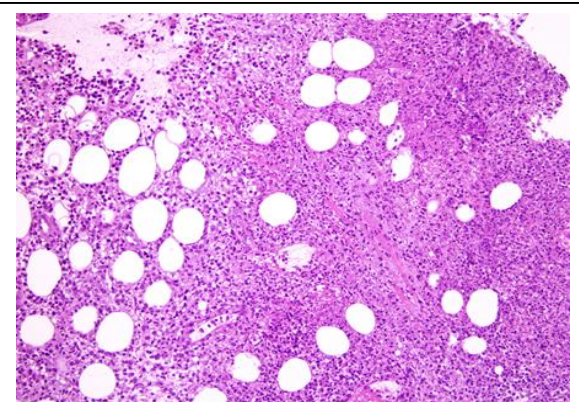


Figure 4: High-magnification image of extranodal natural killer T-cell lymphoma, nasal type (ENK/TCL), with large atypical lymphoid cells

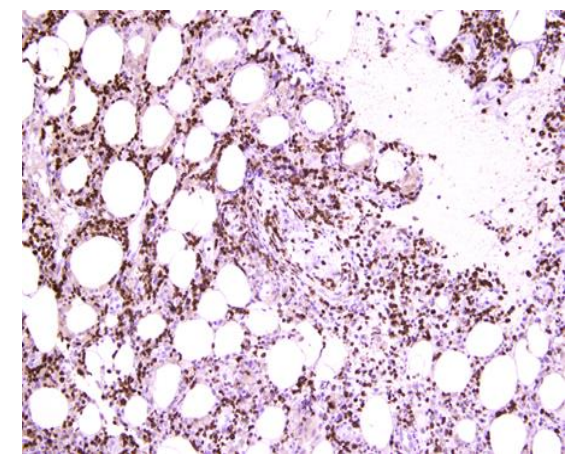


Figure 5: CD3 staining is positive in the cytoplasm of ENKTL

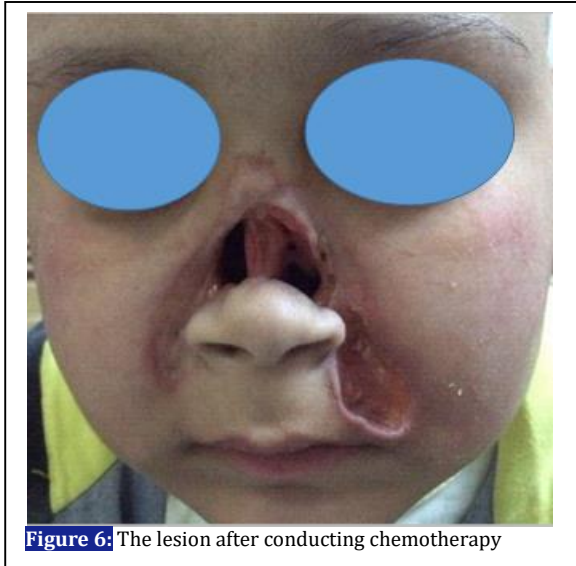

Figure 6: The lesion after conducting chemotherapy

was stopped for a short period and supportive treatment started with a very good response. However, after a week he developed a progressive lesion. Chemotherapy was restarted with concomitant radiotherapy, again with a partial response (figure 6). The patient began preparation for a stem cell transplantation but unfortunately died because of a pulmonary embolism, most probably due to a side effect of L-asparaginase, which causes coagulopathy, although it had been stopped and he was on low molecular weight heparin at the time.

DISCUSSION

Extranodal natural killer/T-cell lymphoma (ENK/TCL) is a rare subtype of NHL with a poor prognosis that has some association with Epstein-Barr virus (EBV) (1, 2). It is characterized by progressive midline oral and nasal cavity destruction and has a limited survival rate because of its fast aggressive malignant progress (3, 4). These lymphomas are frequently seen in middle-aged men from Asian and Latin American countries, but are rare in Europe and North America (3-6).

ENK/TCL primarily involves the nasal cavity and its signs and symptoms are nonspecific, including epistaxis, nasal stuffiness, obstruction, pain, and purulent discharge (4). It rapidly progresses and invades the upper anterior aerodigestive tract structures, leading to ulcerative and destructive lesions of the midface (5, 7). Secondary infection and occasional hemorrhagic events are frequent, but metastasis is uncommon (8).

Alongside ENK/TCL, tuberculosis, nasopharyngeal squamous cell carcinoma, fungal infections, other

types of lymphomas, tertiary syphilis, Wegener granulomatosis, blastomycosis, and nasal destruction due to cocaine abuse are among other possible differential diagnoses of destructive diseases affecting the mid-facial structures (6). Therefore, histopathological, immunological, and molecular studies need to be conducted to reach the correct definitive diagnosis. ENK/TCL usually presents with a low number of atypical lymphocytes and its extensive areas of necrosis make it difficult to choose the best site for a proper biopsy, so it is often reported as acute and chronic inflammation, histopathologically (5). These characteristics may prevent doctors from making incorrect diagnoses or giving up when primary biopsies are inconclusive.

Immunohistochemistry among other tests is an important tool to confirm the diagnosis, showing a positive expression of CD2, CD3, and CD56 (9). A series of biopsies may need to be performed to obtain a correct diagnosis, which is often necessary to confirm the diagnosis of this neoplasm.

The optimal treatment is still unclear. Radiotherapy usually has a favorable outcome in the localized ENK/TCL-nasal type. However, once the tumor has invaded, radiotherapy must be supplemented with adjunct chemotherapy. Some believe that concomitant chemotherapy and radiotherapy is always the best choice, whereas others have good results with using only chemotherapy. Surgery is not an appropriate treatment of choice without adjuvant medical therapy (10).

Local recurrence has been reported in almost 50% of cases. Generally, their prognosis is poor; wide local invasion, regional lymph node involvement, elevated serum LDH, an increased EBV-DNA titer, and systemic signs such as night sweats, fever or weight loss are associated with a worse prognosis (7, 11-13).

Literature reviews have shown that most reported cases follow a similar course. Rhinorrhea, ulceration and necrosis of soft tissue occur first, followed by bone and cartilage destruction of the nasal septum and hard palate, leading to perforation. Further superinfections, cachexia or other complications lead to death (14). In the presented case, a prior history of nasal trauma and the patient's age lead to a misdiagnosis. After establishment of the definite diagnosis of ENK/TCL-nasal type, initial treatment was started with chemotherapy. Unfortunately, the age of the patient, the delayed diagnosis and the malignant nature of the disease lead to the loss of the patient.

CONCLUSIONS

ENK/TCL is a rare cause of lesions in the head and neck. Its early diagnosis depends on professional knowledge and several biopsies may be required to confirm the diagnosis. Considering trauma as a predisposing factor especially in a child, needs further study and discussion before confirmation.

ACKNOWLEDGMENTS

Here in Iraq, we do not have committees or organizations for ethical approval. Taking informed consent is the only standard ethical process within hospital permission rules because all hospitals in Iraq are teaching governmental hospitals, and therefore informed consent is acquired before doing any procedure or publishing the information of any patient. Written informed consent was obtained from the patient for publication of this case report and the accompanying images.

REFERENCES

1. Meng W, Zhou Y, Zhang H, Jiang L, Wang Z, Li X, et al. Nasal-type NK/T-cell lymphoma with palatal ulcer as the earliest clinical manifestation: a case report with literature review. *Pathol Oncol Res.* 2010;16(1):133-7.
2. Paik YS, Liess BD, Scheidt TD, Ingram EA, Zitsch RP, 3rd. Extranodal nasal-type natural killer/T-cell lymphoma masquerading as recalcitrant sinusitis. *Head & neck.* 2010;32(2):268-73.
3. Swerdlow SH, Campo E, Pileri SA, Harris NL, Stein H, Siebert R, et al. The 2016 revision of the World Health Organization classification of lymphoid neoplasms. *Blood.* 2016;127(20):2375-90.
4. Wang ZY, Li YX, Wang H, Wang WH, Jin J, Liu YP, et al. Unfavorable prognosis of elderly patients with early-stage extranodal nasal-type NK/T-cell lymphoma. *Ann Oncol.* 2011;22(2):390-6.
5. Neville B, Damm D, Allen C, Bouquot J, Neville B. Hematologic Disorders. In: Neville BW, Damm DD, Allen CM, Bouquot J, editors. *Oral and Maxillofacial Pathology.* Third ed: Saunders Elsevier; 2009.
6. Rodrigo JP, Suarez C, Rinaldo A, Devaney KO, Carbone A, Barnes L, et al. Idiopathic midline destructive disease: fact or fiction. *Oral Oncol.* 2005;41(4):340-8.
7. Liang R. Advances in the management and monitoring of extranodal NK/T-cell lymphoma, nasal type. *Br J Haematol.* 2009;147(1):13-21.
8. Gill H, Liang RH, Tse E. Extranodal Natural-Killer/T-Cell Lymphoma, Nasal Type. *Adv Hematol.* 2010;2010(2010):627401.
9. Altemani A, Barbosa AC, Kulka M, Takahashi T, Endo L, Vassallo J, et al. Characteristics of nasal T/NK-cell lymphoma among Brazilians. *Neoplasma.* 2002;49(1):55-60.
10. Takahashi E, Asano N, Li C, Tanaka T, Shimada K, Shimada S, et al. Nodal T/NK-cell lymphoma of nasal type: a clinicopathological study of six cases. *Histopathology.* 2008;52(5):585-96.
11. Kim TM, Park YH, Lee SY, Kim JH, Kim DW, Im SA, et al. Local tumor invasiveness is more predictive of survival than International Prognostic Index in stage I(E)/II(E) extranodal NK/T-cell lymphoma, nasal type. *Blood.* 2005;106(12):3785-90.
12. Isobe K, Uno T, Tamaru J, Kawakami H, Ueno N, Wakita H, et al. Extranodal natural killer/T-cell lymphoma, nasal type: the significance of radiotherapeutic parameters. *Cancer.* 2006;106(3):609-15.
13. Al-Hakeem DA, Fedele S, Carlos R, Porter S. Extranodal NK/T-cell lymphoma, nasal type. *Oral Oncol.* 2007;43(1):4-14.

AUTHORS' CONTRIBUTION

SNA performed the surgery; SMA designed and wrote the manuscript and helped with the operation, VFM performed chemotherapy management, and PKHM followed up the patient. All authors read and approved the final manuscript.

CONFLICTS OF INTEREST

All authors of this manuscript declare that they have no conflicts of interest with any person or organization.

FUNDING

This work was performed solely by the authors of this manuscript. No one else participated in the preparation or financial aid of this work. The treatment was performed in a public hospital that is open to everybody. We just put in extra time to collect the data and put it together in the form of a case report.

14. Mangrio SA, Dhanani R, Ikram M, Tariq MU. Lethal midline granuloma: a case report. The Egypt J Otolaryngol. 2017;33(1):131.