

# Clinical Outcomes and Prognostic Factors in Patients With Recurrent Patellar Lateral Dislocation Treated With Isolated Medial Patellofemoral Ligament Reconstruction

## A Retrospective Single-Center Analysis

Zhidong Zhao,<sup>\*†</sup> PhD, Yuxing Wang,<sup>\*†</sup> PhD, Ji Li,<sup>\*†</sup> PhD, Haoran Wang,<sup>\*†</sup> MD, Xiaowei Bai,<sup>\*†</sup> PhD, Qi Wang,<sup>\*†</sup> PhD, and Zhongli Li,<sup>\*†‡</sup> MD, PhD

*Investigation performed at the Department of Orthopedics, Chinese PLA (People's Liberation Army) General Hospital, Beijing, China*

**Background:** Medial patellofemoral ligament reconstruction (MPFLR) is widely used to treat patellofemoral instability. However, it is still unclear when a concomitant bony procedure is needed.

**Purpose:** To evaluate the therapeutic efficacy of isolated MPFLR for recurrent patellar lateral dislocation and to identify the prognostic factors for clinical outcomes.

**Study Design:** Case series; Level of evidence, 4.

**Methods:** A total of 237 patients who had undergone unilateral isolated MPFLR between January 2011 and December 2016 were included. Patellar tracking (J sign) and radiologic information including patellar height, trochlear dysplasia, tibial tubercle–trochlear groove distance, and patellar tilt was collected preoperatively, and the Kujala and International Knee Documentation Committee (IKDC) functional scores were used to assess postoperative recovery. Failure was defined as redislocation or patient-reported and clinically confirmed patellar instability. The influence of radiologic features and the J sign on knee functional scores was explored via subgroup analysis. Potential prognostic factors were explored using univariate and multivariate regression analyses, and risk factors for a positive J sign were evaluated using Spearman coefficient correlation analysis.

**Results:** The mean  $\pm$  SD follow-up period was  $70.67 \pm 18.05$  months (range, 36–108 months). From preoperatively to final follow-up, all patients had statistically and clinically significant improvements in the Kujala score (from  $51.43 \pm 6.87$  to  $88.52 \pm 4.83$ ;  $P < .001$ ) and IKDC score (from  $49.78 \pm 6.05$  to  $81.16 \pm 4.20$ ;  $P < .001$ ). Subgroup analysis indicated no significant difference in functional score improvements based on radiologic features or the J sign. Overall, 20 knees (8.4%) experienced postoperative failure: 11 with redislocation and 9 with patellar instability. A preoperative positive J sign was shown to be an independent prognostic factor for postoperative failure via logistic regression analyses: univariate (odds ratio, 3.340; 95% CI, 1.316–8.480;  $P = .011$ ) and multivariate (odds ratio, 3.038; 95% CI, 1.179–7.827;  $P = .021$ ). In addition, the J sign was closely associated with patellar height ( $r_s$ , 0.159;  $P = .014$ ) and trochlear dysplasia ( $r_s$ , 0.235;  $P < .001$ ).

**Conclusion:** Isolated MPFLR appears to be an effective strategy for recurrent patellar lateral dislocation, with significant functional improvement and a low failure rate. A preoperative positive J sign was identified as a potential prognostic risk factor for postoperative failure.

**Keywords:** medial patellofemoral ligament; patellar dislocation; MPFLR; J sign; risk factor

Recurrent patellar lateral dislocation, a common knee injury in adolescents,<sup>6,10</sup> is a multifactorial issue that includes soft tissue imbalance and bony pathoanatomy.<sup>38</sup> Specifically,

medial retinacular deficiency, trochlear dysplasia, tibia tubercle lateralization, and patella alta are commonly recognized pathologic factors.<sup>33</sup> Recurrent patellar instability seriously influences quality of life and makes patients prone to developing osteoarthritis if they do not receive effective treatment.<sup>4,35</sup>

To date, there are >100 operative treatment methods for patellar instability. Unfortunately, no single technique can

The Orthopaedic Journal of Sports Medicine, 9(4), 2325967121995803

DOI: 10.1177/2325967121995803

© The Author(s) 2021

This open-access article is published and distributed under the Creative Commons Attribution - NonCommercial - No Derivatives License (<https://creativecommons.org/licenses/by-nc-nd/4.0/>), which permits the noncommercial use, distribution, and reproduction of the article in any medium, provided the original author and source are credited. You may not alter, transform, or build upon this article without the permission of the Author(s). For article reuse guidelines, please visit SAGE's website at <http://www.sagepub.com/journals-permissions>.

treat this condition faultlessly.<sup>19</sup> In 2016, a therapy algorithm for patellofemoral instability (PFI) was proposed, in which medial patellofemoral ligament (MPFL) reconstruction (MPFLR), tibial tubercle transfer, trochleoplasty, and lateral retinacular release were suggested alone or combined after comprehensive consideration of the tibial tubercle–trochlear groove (TT-TG), Caton-Deschamps index, trochlear dysplasia phenotype, and patellar tilt extent.<sup>41</sup> Unfortunately, although we have realized that these bony pathoanatomies are etiologic factors for patellar instability and may be risk factors that influence clinical outcomes, when and how to accurately manage these factors is still unclear.<sup>36</sup> Additionally, the complications of osseous surgical techniques, such as the potential risk of nonunion brought by tibial tubercle transfer indicated for patients with a TT-TG >20 mm, make the treatment choices more challenging.<sup>20</sup> Meanwhile, trochleoplasty, a technique suggested for trochlear dysplasia B or D, increases the risk of developing secondary osteoarthritis at long-term follow-up.<sup>27</sup>

MPFLR has become the most practical means for treating knee instability, and it has been frequently used for its ideal outcomes and relatively low rate of complications.<sup>30</sup> The majority of researchers have concluded that MPFLR alone could achieve reliable outcomes even in patients with bony deformity,<sup>2,3,8,9,13,18,39</sup> while others believe that it may be insufficient with isolated soft tissue surgery.<sup>1,14,34</sup> However, no consensus has been reached concerning when a concomitant bony procedure should be added to strengthen the MPFLR. This is supported by the International Association for the Treatment of the Patellofemoral Joint and the Society for Arthroscopy and Joint Surgery Knee-Patellofemoral Committee.<sup>12,19,25</sup> Therefore, it is important to verify the clinical outcomes of isolated MPFLR and identify any risk factors that can influence outcomes, which will facilitate treatment decision making for patellar instability.

Previous researchers have demonstrated satisfactory short-term clinical results of isolated MPFLR in select populations.<sup>30</sup> Specifically, some studies<sup>24,26</sup> have excluded patella alta, increased TT-TG, and severe trochlear dysplasia in their study populations. This may not comprehensively represent the actual characteristics of the majority of patients with recurrent patellar dislocation because these are common characteristics with PFI.<sup>16</sup> For example, Dejour et al<sup>5</sup> demonstrated that >90% of patients with PFI had femoral trochlear dysplasia. It is thus important to investigate the clinical outcomes of MPFLR in these populations with patellar instability.

The purpose of this study was to summarize and report the clinical outcomes in patients with recurrent patellar

lateral dislocation treated using isolated MPFLR, irrespective of possible concomitant bony deformity, and to explore the potential predictive factors for clinical outcomes, including postoperative failure and knee functional score improvement.

## METHODS

This study was approved by an institutional review board, and all participants provided informed consent.

### Participants

Patients who were diagnosed with recurrent patellar lateral dislocation and underwent surgery in our department between January 1, 2011, and December 30, 2016, were included. The inclusion criteria were as follows: (1) a history of PFI with >2 lateral patellar dislocations and failure of normative nonoperative treatment, including bracing and strengthening; (2) a positive patellar apprehension sign; and (3) no radiographic appearance of patellofemoral joint osteoarthritis. The corresponding exclusion criteria were as follows: (1) previous patellofemoral realignment procedure (bony or soft tissue); (2) concomitant serious ligamentous knee injury, such as anterior cruciate ligament injury; (3) severe miserable malalignment syndrome (inward version of patella); (4) incomplete clinical, radiologic, or operative data; (5) concomitant osteochondral injury that exceeds Outerbridge level 4; and (6) habitual dislocation (patella commonly dislocates when knee flexion exceeds 90° and cannot slide back into the trochlear groove during the whole process of knee deep flexion).

On the basis of these criteria, 237 patients who received unilateral isolated MPFLR were recruited from the original 283 patients. Of that total, 46 patients were excluded: 8 experienced concurrent anterior cruciate ligament injury; 8 had received previous realignment procedures; 6 had miserable malalignment syndrome; 6 had level 4 osteochondral injury; and 18 were unable to be contacted. Patients were followed up for a minimum of 3 years postoperatively with a mean ± SD follow-up of 70.67 ± 18.05 months (range, 36–108 months).

### Clinical Assessment and Follow-up

Basic patient characteristics including sex, occupation, age at surgery, and body mass index were recorded. Related PFI characteristics such as the involved knee side and corresponding mechanism were also collected. Kujala functional scores and the International Knee Documentation

†Address correspondence to Zhongli Li, MD, PhD, Department of Orthopedics, Chinese PLA General Hospital, No. 28 Fuxing Road, Haidian District, Beijing 100853, China (email: lizhongli@263.net).

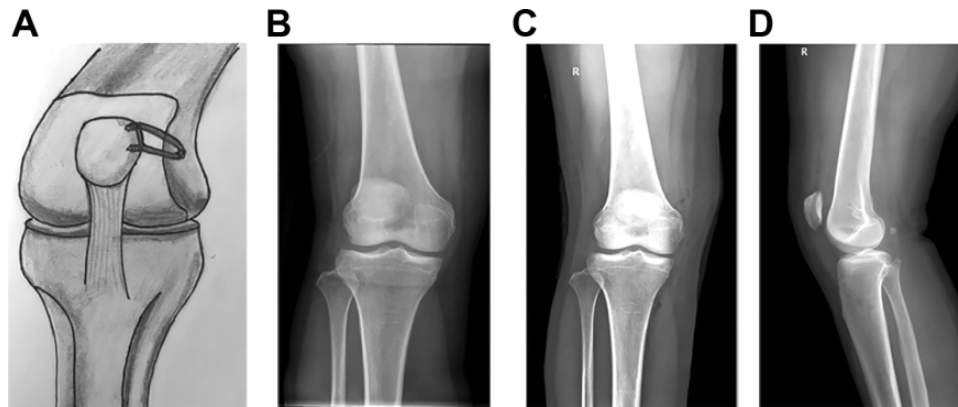
\*Medical School of Chinese PLA, Beijing, China.

†Department of Orthopedics, The First Medical Center, Chinese PLA General Hospital, Beijing, China.

Final revision submitted October 27, 2020; accepted November 29, 2020.

The authors declared that there are no conflicts of interest in the authorship and publication of this contribution. AOSSM checks author disclosures against the Open Payments Database (OPD). AOSSM has not conducted an independent investigation on the OPD and disclaims any liability or responsibility relating thereto.

Ethical approval for this study was obtained from the Chinese People's Liberation Army General Hospital ethics committee.



**Figure 1.** (A) Schematic diagram of double-bundle reconstruction of the medial patellofemoral ligament. (B) Preoperative radiograph shows patellar dislocation in the right knee. (C, D) Postoperative posteroanterior and lateral radiographs of the right knee.

Committee (IKDC) form were used to evaluate the clinical outcomes. These rating scales were completed preoperatively and served as basic data.

Clinical examination included an apprehension test, patellar tilt, and abnormality in patellar tracking (positive J sign). The J sign was marked positive when there was a sudden or obvious lateral patellar shift in knee motion of terminal extension.

Radiographic features predisposing patients to PFI include trochlear phenotype per the Dejour classification, patellar height based on the Caton-Deschamps index, degree of patellar tilt, and TT-TG distance. Radiographs, magnetic resonance imaging scans, or computed tomography scans were obtained for all patients preoperatively. Specifically, trochlear dysplasia was classified as normal or Dejour types A, B, C, and D. The TT-TG distance was measured on a computed tomography scan, and  $>20$  mm was considered elevated. Patellar height was characterized via the Caton-Deschamps ratio in strict lateral radiographs, and  $>1.2$  was recorded as patella alta. Patellar tilt was measured on transverse sections of computed tomography images according to previously published methods,<sup>16</sup> and  $\geq 20^\circ$  was marked as excessive tilt.

Patients were evaluated at the outpatient clinic postoperatively at 6 weeks, 3 and 6 months, and then annually. Postoperative complications, such as knee joint stiffness, patellar redislocation or subluxation, and complex regional pain syndrome, were recorded. Postoperative failure was defined as redislocation or patient-reported and clinically confirmed patellar instability.

### Surgical Technique

All surgical procedures were accomplished using the same methods by 2 senior sports medicine specialists who had strict training and were all skilled in solving PFI problems. With the patient in the supine position and the epidural anesthesia finished, a tourniquet was applied to the thigh to facilitate operative visualization. A comprehensive diagnostic arthroscopy was first performed using standard portals to discover and address any possible concomitant

injuries, such as osteochondral injury and loose bodies. The patellofemoral kinematics trajectory was evaluated carefully and dynamically under arthroscopy. An ipsilateral autogenous semitendinosus was then harvested and prepared to obtain a tendon with sufficient strength for reconstruction.

The patella was approached through a 2.5-cm longitudinal incision. Two superficial bony grooves were created in the center and upper thirds of the patella via an orthopaedic rongeur. Two anchors equipped with fiber wires were drilled into the center and upper thirds of the patella. Subsequently, the prepared graft was fixed on the patella via the loaded sutures. A 2-cm incision was made across the medial epicondyle and adductor tubercle to locate the femoral checkpoint of the MPFL. A guide pin was placed in the border area and drilled toward the lateral femoral cortex and skin. The locating point was verified using fluoroscopy,<sup>31</sup> followed by drilling with an auger with equivalent diameter to the transplant graft to obtain enough depth. Once the location was finished, the ends of the graft were passed from the patellar incision to the medial femoral epicondyle incision through the artificial tunnel between the capsule and deep fascia. Then, the graft was pulled into the femoral tunnel under full extension conditions. To accommodate the reconstructed tendon, the knee was moved from extension to full flexion several times. The graft tension was modulated according to the kinematics trajectory of the patellofemoral evaluation under arthroscopy. Eventually, an interference screw was used to fix the graft with the knee in  $30^\circ$  of flexion. Then, the wound was closed layer by layer (Figure 1).

### Rehabilitation

Rehabilitation protocols were as follows. The involved leg was placed into a hinged knee brace equipped with a corresponding patellofemoral stabilizing subassembly. Then, the brace was set to obtain a range of motion from  $0^\circ$  to  $30^\circ$  for the 3 weeks after surgery. Meanwhile, the patient was allowed partial weightbearing with the aid of crutches. Full weightbearing and full range of motion were allowed at 6 weeks after surgery. Isometric quadriceps exercises were

TABLE 1  
Preoperative Patient and PFI Characteristics<sup>a</sup>

	No. (%) <sup>b</sup>
Sex	
Male	89 (37.4)
Female	148 (62.6)
Age at surgery, y, median (range)	19 (13-45)
Age group, y	
<18	80 (33.8)
≥18	157 (66.2)
BMI, mean ± SD	23.90 ± 3.73
Side	
Left	125 (52.7)
Right	112 (47.3)
Occupation	
Student	159 (67.0)
Soldier	30 (12.7)
Other	48 (20.3)
Injury mechanism	
Running	91 (38.4)
Basketball	41 (17.3)
Football	31 (13.1)
Military training	25 (10.5)
Other	49 (20.7)

<sup>a</sup>BMI, body mass index; PFI, patellofemoral instability.

<sup>b</sup>Data are presented as No. (%) unless otherwise indicated.

encouraged from the end of the operation and throughout the whole rehabilitation recovery process. Eight weeks after surgery, patients were advised to substitute the brace with a knee pad to protect the patella during rehabilitation exercises. Two months after surgery, patients were allowed to participate in daily living activities. Three months postoperatively, jogging, running, and other functional sports were permitted. After 6 months, patients could return to normal sports progressively.

### Statistical Analysis

Normality tests were conducted for continuous quantitative data before description and analysis. Means and SDs were used to describe the normally distributed data, while medians and ranges were used for nonnormally distributed data. Categorical variables were described as frequencies and percentages. The change in Kujala and IKDC scores from pre- to postoperatively was compared using a paired *t* test. Subgroup analysis of functional score evolution based on classification of the J sign, patellar height, patellar tilt, TT-TG distance, and trochlear dysplasia was performed using an independent *t* test or analysis of variance. A binary multivariate logistic regression analysis was applied to examine the potential risk factors associated with postoperative failure. Initially, considered factors were selected through a preliminary univariate approach by setting the *P* value threshold as 20%. Spearman correlation analysis was used to explore factors related to a positive J sign. All statistical analyses were performed using SPSS for Windows (Standard Version 17.0; IBM Corp). Statistical significance was defined as a 2-sided *P* value < .05.

TABLE 2  
Preoperative Clinical and Radiologic Characteristics<sup>a</sup>

	No. (%) or Mean ± SD (Range)
J sign	
Positive	60 (25.3)
Negative	177 (74.7)
Patellar height, CDI	1.16 ± 0.17 (0.78-1.62)
<1.2	146 (61.6)
≥1.2	91 (38.4)
TT-TG distance, mm	14.32 ± 4.73 (4.3-23.4)
<20	203 (85.7)
≥20	34 (14.3)
Trochlear dysplasia	
Normal	14 (5.9)
Type A	92 (38.8)
Type B	75 (31.6)
Type C	40 (16.9)
Type D	16 (6.8)
Patellar tilt	22.3 ± 4.98 (10.2-39.6)
<20°	81 (34.2)
≥20°	156 (65.8)
Follow-up, mo	70.67 ± 18.05 (36-108)
Outcome	
Failure	20 (8.4)
Success	217 (91.6)

<sup>a</sup>CDI, Caton-Deschamps index; TT-TG, tibial tubercle-trochlear groove.

## RESULTS

### Participants

Among the 237 study participants, female patients accounted for 62.6%. The median age at surgery was 19 years (range, 13-45 years), with 66.2% aged ≥18 years and 33.8% aged <18 years. The mean follow-up time was 70.67 ± 18.05 months (range, 36-108 months). The baseline demographic and knee instability data are summarized in Table 1, and the baseline clinical and radiologic characteristics are summarized in Table 2.

### Clinical Results

At the final follow-up, there was a statistically significant improvement in Kujala scores between pre- and postoperatively (from 51.43 to 88.52; *P* < .001). Similarly, overall functional score improvements were observed on the IKDC (from 49.78 to 81.16; *P* < .001) (Table 3). More than 80% of patients achieved preoperative playing levels and returned to sports activities.

The subgroup analysis suggested no significant difference in functional score improvement based on radiologic features (trochlear dysplasia, patellar height, increased TT-TG distance, and patellar tilt) or the J sign (Table 4).

### Failure and Related Risk Factors

At the end of the follow-up, 20 knees (8.4%) experienced postoperative failure: 9 knees had patient-reported and

TABLE 3  
Comparison of Pre- and Postoperative Knee Functional Scores<sup>a</sup>

	Score, Mean ± SD		<i>t</i> Value	<i>P</i> Value <sup>b</sup>
	Preoperative	Final Follow-up		
Kujala	51.43 ± 6.87	88.52 ± 4.83	-89.75	<.001
Functional IKDC	49.78 ± 6.05	81.16 ± 4.20	-80.6	<.001

<sup>a</sup>IKDC, International Knee Documentation Committee.  
<sup>b</sup>*P* < .05 for each comparison.

TABLE 4  
Analysis of Variables Influencing Changes in Functional Scores<sup>a</sup>

Variable	Δ Kujala <sup>b</sup>	Δ IKDC <sup>c</sup>
J sign		
Positive	36.27 ± 4.58	31.67 ± 4.27
Negative	37.25 ± 6.84	32.24 ± 6.02
<i>t</i> value ( <i>P</i> value)	1.041 (.299)	0.678 (.498)
Patellar height, CDI		
<1.2	36.93 ± 6.02	31.84 ± 5.04
≥1.2	37.13 ± 6.89	32.35 ± 5.92
<i>t</i> value ( <i>P</i> value)	-0.244 (.808)	-0.891 (.374)
Patellar tilt		
<20°	37.96 ± 6.24	32.58 ± 5.22
≥20°	36.51 ± 6.37	31.84 ± 5.82
<i>t</i> value ( <i>P</i> value)	1.681 (.094)	0.961 (.338)
TT-TG distance, mm		
<20	37.11 ± 6.62	32.17 ± 5.78
≥20	36.35 ± 4.46	31.65 ± 4.63
<i>t</i> value ( <i>P</i> value)	0.645 (.519)	0.498 (.619)
Trochlear dysplasia		
Normal	35.57 ± 9.17	29.86 ± 8.67
Type A	36.77 ± 6.14	32.08 ± 5.68
Type B	37.89 ± 5.83	32.07 ± 4.63
Type C	37.35 ± 6.11	33.60 ± 5.22
Type D	36.56 ± 7.45	30.50 ± 6.87
<i>F</i> value ( <i>P</i> value)	1.201 (.311)	1.608 (.173)

<sup>a</sup>CDI, Caton-Deschamps index; IKDC, International Knee Documentation Committee; TT-TG, tibial tubercle–trochlear groove.

<sup>b</sup>Change in Kujala score between preoperatively and final follow-up.

<sup>c</sup>Change in IKDC score between preoperatively and final follow-up.

TABLE 5  
Univariate Logistic Analysis of Risk Factors for Postoperative Failure<sup>a</sup>

Risk Factor	No. of Patients			<i>P</i> Value	OR (95% CI)
	Total	Success	Failure		
Sex				.468	1.445 (0.534-3.908)
Male	89	83	6		
Female	148	134	14		
Age group, y				.390	1.585 (0.554-4.528)
≥18	157	142	15		
<18	80	75	5		
Affected side				.797	1.127 (0.451-2.818)
Left	125	115	10		
Right	112	102	10		
J sign				.011 <sup>b</sup>	3.340 (1.316-8.480)
Negative	177	167	10		
Positive	60	50	10		
Patellar height, CDI				.117	2.093 (0.832-5.268)
<1.2	146	137	9		
≥1.2	91	80	11		
TT-TG distance, mm				.565	0.642 (0.142-2.903)
<20	203	185	18		
≥20	34	32	2		
Patellar tilt				.935	0.961 (0.368-2.512)
<20°	81	74	7		
≥20°	156	143	13		
Trochlear dysplasia					
Normal	14	12	2	.330	
Type A	92	87	5	.232	0.345 (0.060-1.979)
Type B	75	67	8	.695	0.716 (0.135-3.794)
Type C	40	38	2	.274	0.316 (0.040-2.489)
Type D	16	13	3	.744	1.383 (0.196-9.768)

<sup>a</sup>CDI, Caton-Deschamps index; OR, odds ratio; TT-TG, tibial tubercle–trochlear groove.

<sup>b</sup>*P* < .05.

TABLE 6  
Multivariate Logistic Analysis of Risk Factors for Postoperative Failure<sup>a</sup>

Risk Factor	<i>B</i>	<i>P</i> Value	OR (95% CI)
J sign: positive vs negative	1.111	.021 <sup>b</sup>	3.038 (1.179-7.827)
Patellar height: CDI ≥1.2 vs <1.2	0.989	.237	1.770 (0.687-4.558)

<sup>a</sup>CDI, Caton-Deschamps index; OR, odds ratio.

<sup>b</sup>*P* < .05.

clinically confirmed patellar instability, and 11 had patellar redislocation in sports activities or military training after a mean 3 years postoperatively (2-5 years). The causes for redislocation were posttraumatic, including falling from a bicycle, running, skiing, and military training. Seven patients received revision surgery by the initial surgeon, and 4 received therapy in another hospital. For patients with recurrent PFI, after comprehensive evaluation and detailed communication, all chose muscle functional exercises to strengthen the stability of the knee.

The results from the univariate logistic regression analysis (Table 5) indicated that the odds of postoperative failure increased with a positive preoperative J sign (odds ratio [OR], 3.340; 95% CI, 1.316-8.480; *P* = .011). Postoperative failure was not affected by patient characteristics (sex, age group, laterality) or by preoperative radiologic features.

According to the presupposed threshold of 20%, J sign and patellar height were incorporated into a multivariate logistic analysis model. The results, shown in Table 6, indicated that the J sign (OR, 3.038; *P* = .021) is a potential independent prognostic factor for postoperative failure,

TABLE 7  
Spearman Correlation Analysis of Factors Influencing  
the J Sign<sup>a</sup>

Factor	$r_s$	$P$ Value
Patellar height	0.159	.014 <sup>b</sup>
Trochlear dysplasia	0.235	<.001 <sup>b</sup>
Patellar tilt	-0.010	.877
TT-TG distance	-0.045	.495

<sup>a</sup>TT-TG, tibial tubercle–trochlear groove.

<sup>b</sup> $P < .05$ .

while patellar height (OR, 1.770;  $P = .237$ ) is not. Spearman correlation analysis demonstrated no significant association between positive J sign and patellar tilt or TT-TG. However, patellar height (Caton-Deschamps index  $\geq 1.2$ ) was significantly associated with a positive J sign ( $r_s$ , 0.159;  $P = .014$ ), as was trochlear dysplasia ( $r_s$ , 0.235;  $P < .001$ ). The results are presented in Table 7.

### Complications

Apart from the 20 failure cases, no major postoperative complications were reported. Eight knee stiffness events occurred in 8 patients 2 months postoperatively; these were successfully resolved via joint loosening under local anesthesia. No postoperative infection or hematoma was investigated or reported.

### DISCUSSION

The intention of this research was to investigate the clinical efficacy of isolated MPFLR for recurrent patellar lateral dislocation and explore the potential risk factors predictive of postoperative failure and knee functional score improvement. The comprehensive data analysis demonstrated that isolated MPFLR is an effective procedure for its significant functional score improvement (Kujala score from 51.43 to 88.52; IKDC from 49.78 to 81.16;  $P < .001$  for both) and low failure rate (8.4%). More than 80% of patients could achieve preoperative playing levels and return to sports activities by the end of the final follow-up. More importantly, the current study identified 1 possible predictive factor for postoperative failure (patellar redislocation and PFI occurrence): a positive preoperative J sign. Trochlear dysplasia and patellar height were closely correlated with a positive J sign.

Patellar instability is a common knee disorder that has received increasing attention.<sup>35</sup> For primary patellar dislocation, conservative treatment is the first-line choice.<sup>19</sup> For recurrent patellar dislocation, however, absolute agreement concerning the standard indications to select corresponding operative methods is still lacking on account of its inherent complexity.<sup>12</sup> Previous studies have shown that approximately 90% of the MPFL is injured in recurrent patellar dislocation.<sup>22</sup>

Based on the current research evidence, the MPFL provides 50% to 70% of the restraint on patellar outside

movement, especially during the range of initial knee flexion activity of 0° to 30° under physiologic conditions.<sup>15</sup> Hence, reconstruction of the MPFL is the integral choice for PFI.<sup>22,27</sup> Nevertheless, as current studies have suggested, multiple pathologic factors contribute to PFI, and under which conditions osseous operations are needed is still controversial.<sup>12,25</sup> Our study supports the use of isolated MPFLR as a safe and effective technique. This is consistent with the research of Liu et al,<sup>18</sup> who demonstrated satisfactory clinical efficacy of MPFLR even in a population with PFI and severe trochlear dysplasia. MPFLR, alone or with tibial tubercle transfer, presents obvious improvement in knee function, confirming the effectiveness of the procedure.<sup>23</sup>

Some studies have pointed out that isolated MPFLR is insufficient in some cases, such as patella alta.<sup>29</sup> From a comprehensive perspective, although we have discovered the bony pathoanatomic factors closely related to patellar instability that may be the risk factors influencing clinical outcomes, we have not been able to make clear how these factors influence the therapy outcomes alone or together. Hence, at present, no explicit cutoff value or threshold could be proposed to guide accurate surgical strategies. Under such circumstances, identifying the potential risk factors that may influence isolated MPFLR is of clinical significance.

A positive preoperative J sign was identified in our study as a potential risk factor for postoperative failure after isolated MPFLR, similar to the findings of Sappey-Marini et al.<sup>29</sup> Further analysis demonstrated that trochlear dysplasia and patellar height were significantly correlated with the J sign. These results remind us of possible J signs when encountering patella alta and trochlear dysplasia. The J sign refers to the sudden lateral subluxation of the patella during the terminal knee extension range of 0° to 30°.<sup>32</sup> Although the accurate mechanism of the J sign is not yet clear, possible correlative factors, such as femoral torsion, excessive patellar tilt, patella alta, and trochlear dysplasia, have been reported.<sup>7,40</sup> More importantly, some studies have concluded that the J sign is associated closely with postoperative outcomes.<sup>11,45</sup> In our research, we found that the postoperative failure risk in patients with a positive preoperative J sign was higher than that in patients with a negative J sign. However, the most commonly recognized risk factors for PFI, such as patella alta, trochlear dysplasia, and patellar tilt, have not been identified as risk factors for prognosis.

The discrepancy between radiologic characteristics and clinical examination findings such as the J sign demonstrates the clinical value of a comprehensive physical examination. We speculate that the J sign may represent a composite effect of various predisposing factors. Therefore, although the concrete mechanism has not been absolutely elucidated, we should pay attention to it. Zhang et al<sup>44,45</sup> also suggested that a positive J sign brings more postoperative patellofemoral laxity. With regard to other risk factors, such as patella alta, perhaps one of them was insufficient to affect clinical performance. However, when 1 deformity significantly exceeds the normal value or several of them reach some threshold, their effect may be

prominent. Moreover, in our view, surgical intervention may compensate for some concomitant bony deformities. Consider the MPFLR as an example: the mean tensile strength of the reconstructed MPFL, usually derived from the semitendinosus tendon, is far stiffer and stronger than that of the native MPFL, which may compensate for the predisposing anatomic factors to a certain extent.<sup>38</sup> Additionally, the established full-length femoral tunnel allows sufficient adjustment of tendon balance. Luceri et al<sup>21</sup> demonstrated that MPFLR not only provides a restraint to lateral translation (traditional viewpoint), but also has potential influence on lowering the patellar height. Given the point of the issue, successful surgery seems to be more critical because it may compensate for other potential risk factors.

The overall failure rate of isolated MPFLR in the current study was 8.4%, which nearly echoes previous clinical reports of failure ranging from 1.2% to 6% in a recent systematic review by Schneider et al.<sup>30</sup> Numerous studies have suggested the efficacy and satisfaction with isolated MPFLR for patellar dislocation. Nevertheless, most were comparative studies with selected risk factors that ignored the natural multifactorial characteristics of this disorder.<sup>26</sup> It is therefore necessary for us to take these potential risk factors into consideration. In our study, we incorporate the possible risk factors to represent the actual situation as much as possible. Kujala rating scales with the IKDC, the most frequently used patient-reported outcomes for patellofemoral disorder, were graded to evaluate the curative effect. Our preliminary results suggest that increased TT-TG, patella alta, trochlear phenotype, and patellar tilt did not significantly influence postoperative knee functional recovery or the failure rate.

Trochlear dysplasia was discovered in 94.1% of patients in our study population. The noteworthy improvements between pre- and postoperatively were consistent with the research results of Liu et al.<sup>18</sup> However, Hiemstra et al<sup>14</sup> reported that the presence of trochlear dysplasia was associated with poorer improvement in functional and quality of life scores after surgery. The variations among studies may be attributed to the heterogeneity of the selected population and evaluation standards. Moreover, insufficient interrater reliability matters in evaluating the classification of trochlear dysplasia owing to its native complexity. Fortunately, we combined radiologic imaging materials with arthroscopy to comprehensively evaluate the phenotype, which may increase the accuracy. Hence, a deeper understanding and validation of the evaluation system may be beneficial. Meanwhile, deepening trochleoplasty, in addition to its own technical challenge, brings a substantial risk profile. In a recent systematic review, Zaffagnini et al<sup>43</sup> concluded that in a population with recurrent patellar dislocation and moderate trochlear dysplasia, isolated MPFLR is as effective as combined MPFLR and trochleoplasty. Moreover, for cases of severe trochlear dysplasia, although the redislocation rate is lower in the combined group, the clinical outcomes are comparable, and the additional trochleoplasty brings a higher risk of limited postoperative knee range of motion. Trochleoplasty, based on the current evidence, may be more suitable as a reserve technology.

Likewise, controversy exists regarding whether increased TT-TG values influence postoperative outcomes. Some studies have concluded that an increased TT-TG brings lower functional scores.<sup>37</sup> In contrast, significant functional scale improvements have been observed in the population with patellar instability, with increased TT-TG >20 mm treated using isolated MPFLR.<sup>23</sup> Our results suggest that TT-TG does not influence postoperative outcomes; thus, the procedure of tibial tubercle transfer needs to be carefully considered. Consensus agreement from the American Orthopaedic Society for Sports Medicine and the Patellofemoral Foundation does not recommend tibial tubercle medialization as a common strategy for PFI because of lack of evidence to indicate it as a necessary part of the whole scheme.<sup>25</sup> Performing a tibial tubercle osteotomy adds time to the procedure and dramatically changes the postoperative recovery. With regard to patella alta, studies have drawn different results. A recent study conducted by Hiemstra et al<sup>14</sup> concluded that isolated MPFLR was able to correct mild patella alta in patients with patellar instability.<sup>13</sup> The outcomes again demonstrated the possible beneficial effect of MPFLR on other concomitant risk factors.

Currently, risky pathoanatomic factors varying from trochlear dysplasia and increased TT-TG have gained increasing attention for their potential role in causing patellar instability, influencing outcomes after stabilization procedures and the predictive value of recurrence rate. To date, much research evidence has confirmed the important role that they may play in the etiology and prognosis of PFI.<sup>25,38</sup> Nevertheless, owing to the native complexity of various risk factors and possible interplay among factors,<sup>42</sup> the specific effect sizes of etiologic factors in the pathology and prognosis of recurrent patellar instability cannot be clearly elucidated.<sup>19</sup> Meanwhile, the positive effects of various surgical techniques may offset  $\geq 1$  pathoanatomic factors, which makes it more difficult to clarify the potential variable etiology that contributes to postoperative outcomes. Under such circumstances, a successful surgical technique may be more important than is any individual risk factor. Hence, when and how to manage the concomitant bony deformity is still elusive.<sup>20</sup> Treating patients with PFI remains a challenge for surgeons. Therapeutic decision making is multifactorial, and there are no clear guidelines for optimal treatment available. Further illumination of the isolated or composite effect of these risk factors is required.

There are several limitations in the present study. First, it is inherently limited because this is a single-center retrospective study, which is more susceptible to confounding factors. Second, a gold standard control group was not set. However, based on current evidence, there is still a lack of an appropriate control group, owing to the diversity and validity of various techniques for patellar dislocation. Third, pivotal points of the MPFLR technique, such as the location of the femoral insertion, play a vital role.<sup>17</sup> Nevertheless, the focus of the present study was to explore other potential factors that may influence the outcomes of isolated MPFLR rather than the technique per se. Fourth, the stability of the patella and knee function depend on static and dynamic structures<sup>28</sup>—for example, the quadriceps,

especially the internal oblique muscle. The study did not take this factor into consideration. Meanwhile, owing to the sample size that was not very large, some potential risk factors may not have been clarified. Fifth, long-term clinical outcomes and failure events need to be investigated and reported to obtain more convincing clinical evidence than that based on short- to medium-term clinical follow-up.

## CONCLUSION

Overall, isolated MPFLR appears to be an effective and safe technical strategy for recurrent patellar lateral dislocation owing to its significant functional improvement and low failure rate. A preoperative positive J sign was identified in our study as a potential prognostic risk factor for postoperative failure.

## REFERENCES

- Belkin NS, Meyers KN, Redler LH, et al. Medial patellofemoral ligament isometry in the setting of patella alta. *Arthroscopy*. 2020;36(12):3031-3036.
- Blanke F, Watermann K, Haenle M, et al. Isolated medial patellofemoral ligament reconstruction can be an effective procedure in patellofemoral instability with risk factors. *J Knee Surg*. 2020;33(10):992-997.
- Bouras T, Edmond U, Brown A, Gallacher P, Barnett A. Isolated medial patellofemoral ligament reconstruction significantly improved quality of life in patients with recurrent patella dislocation. *Knee Surg Sports Traumatol Arthrosc*. 2019;27(11):3513-3517.
- Collin NJ, OEI EHG, de Kanter JL, Vicenzino B, Crossley KM. Prevalence of radiographic and MRI features of patellofemoral osteoarthritis in young and middle-aged adults with persistent patellofemoral pain. *Arthritis Care Res (Hoboken)*. 2019;71(8):1068-1073.
- Dejour H, Walch G, Nove-Josserand L, Guier C. Factors of patellar instability: an anatomic radiographic study. *Knee Surg Sports Traumatol Arthrosc*. 1994;2(1):19-26.
- Dewan V, Webb MSL, Prakash D, et al. When does the patella dislocate? A systematic review of biomechanical and kinematic studies. *J Orthop*. 2020;20:70-77.
- Dickschas J, Harrer J, Pfeifferkorn R, Strecker W. Operative treatment of patellofemoral maltracking with torsional osteotomy. *Arch Orthop Trauma Surg*. 2012;132(3):289-298.
- Erickson BJ, Nguyen J, Gasik K, et al. Isolated medial patellofemoral ligament reconstruction for patellar instability regardless of tibial tubercle-trochlear groove distance and patellar height: outcomes at 1 and 2 years. *Am J Sports Med*. 2019;47(6):1331-1337.
- Feller JA, Richmond AK, Wasiak J. Medial patellofemoral ligament reconstruction as an isolated or combined procedure for recurrent patellar instability. *Knee Surg Sports Traumatol Arthrosc*. 2014;22(10):2470-2476.
- Fithian DC, Paxton EW, Stone ML, et al. Epidemiology and natural history of acute patellar dislocation. *Am J Sports Med*. 2004;32(5):1114-1121.
- Frosch KH, Schmeling A. A new classification system of patellar instability and patellar maltracking. *Arch Orthop Trauma Surg*. 2016;136(4):485-497.
- Geierlehner A, Liebensteiner M, Schöttle P, Dirisamer F. Prevailing disagreement in the treatment of complex patellar instability cases: an online expert survey of the AGA Knee-Patellofemoral Committee. *Knee Surg Sports Traumatol Arthrosc*. 2020;28(8):2697-2705.
- Hiemstra LA, Kerslake S, Lafave MR, Tucker A. Patella alta is reduced following MPFL reconstruction but has no effect on quality-of-life outcomes in patients with patellofemoral instability. *Knee Surg Sports Traumatol Arthrosc*. 2021;29(2):546-552.
- Hiemstra LA, Kerslake S, Loewen M, Lafave M. Effect of trochlear dysplasia on outcomes after isolated soft tissue stabilization for patellar instability. *Am J Sports Med*. 2016;44(6):1515-1523.
- Huber C, Zhang Q, Taylor WR, et al. Properties and function of the medial patellofemoral ligament: a systematic review. *Am J Sports Med*. 2019;48(3):754-766.
- Jibri Z, Jamieson P, Rakhra KS, Sampaio ML, Dervin G. Patellar maltracking: an update on the diagnosis and treatment strategies. *Insights Imaging*. 2019;10(1):65.
- Li J, Li Z, Wang K, et al. Medial patellofemoral ligament reconstruction: a comparison of single-bundle transpatellar tunnel and double-anchor anatomic techniques for the treatment of recurrent lateral patellar dislocation in adults. *Arthroscopy*. 2019;35(3):845-854, e841.
- Liu JN, Brady JM, Kalbian IL, et al. Clinical outcomes after isolated medial patellofemoral ligament reconstruction for patellar instability among patients with trochlear dysplasia. *Am J Sports Med*. 2018;46(4):883-889.
- Liu JN, Steinhaus ME, Kalbian IL, et al. Patellar instability management: a survey of the International Patellofemoral Study Group. *Am J Sports Med*. 2018;46(13):3299-3306.
- Longo UG, Berton A, Salvatore G, et al. Medial patellofemoral ligament reconstruction combined with bony procedures for patellar instability: current indications, outcomes, and complications. *Arthroscopy*. 2016;32(7):1421-1427.
- Luceri F, Roger J, Randelli PS, Lustig S, Servien E. How does isolated medial patellofemoral ligament reconstruction influence patellar height? *Am J Sports Med*. 2020;48(4):895-900.
- Matzkin E. Medial patellofemoral ligament reconstruction: indications, technique, and outcomes. *Arthroscopy*. 2019;35(11):2970-2972.
- Neri T, Parker DA, Beach A, et al. Medial patellofemoral ligament reconstruction with or without tibial tubercle transfer is an effective treatment for patellofemoral instability. *Knee Surg Sports Traumatol Arthrosc*. 2019;27(3):805-813.
- Neri T, Parker DA, Putnis S, et al. Clinical and radiological predictors of functional outcome after isolated medial patellofemoral ligament reconstruction at midterm follow-up. *Am J Sports Med*. 2019;47(6):1338-1345.
- Post WR, Fithian DC. Patellofemoral instability: a consensus statement from the AOSSM/PFF Patellofemoral Instability Workshop. *Orthop J Sports Med*. 2018;6(1):2325967117750352.
- Previtali D, Milev SR, Pagliuzzi G, et al. Recurrent patellar dislocations without untreated predisposing factors: medial patellofemoral ligament reconstruction versus other medial soft-tissue surgical techniques—a meta-analysis. *Arthroscopy*. 2020;36(6):1725-1734.
- Ren B, Zhang X, Zhang L, et al. Isolated trochleoplasty for recurrent patellar dislocation has lower outcome and higher residual instability compared with combined MPFL and trochleoplasty: a systematic review. *Arch Orthop Trauma Surg*. 2019;139(11):1617-1624.
- Rosa SB, Ewen PM, Doma K, Ferrer JFL, Grant A. Dynamic evaluation of patellofemoral instability: a clinical reality or just a research field? A literature review. *Orthop Surg*. 2019;11(6):932-942.
- Sappey-Marinié E, Sonnery-Cottet B, O'Loughlin P, et al. Clinical outcomes and predictive factors for failure with isolated MPFL reconstruction for recurrent patellar instability: a series of 211 reconstructions with a minimum follow-up of 3 years. *Am J Sports Med*. 2019;47(6):1323-1330.
- Schneider DK, Grawe B, Magnussen RA, et al. Outcomes after isolated medial patellofemoral ligament reconstruction for the treatment of recurrent lateral patellar dislocations: a systematic review and meta-analysis. *Am J Sports Med*. 2016;44(11):2993-3005.
- Schöttle PB, Schmeling A, Rosenstiel N, Weiler A. Radiographic landmarks for femoral tunnel placement in medial patellofemoral ligament reconstruction. *Am J Sports Med*. 2007;35(5):801-804.
- Sheehan FT, Derasari A, Fine KM, Brindle TJ, Alter KE. Q-angle and J-sign: indicative of maltracking subgroups in patellofemoral pain. *Clin Orthop Relat Res*. 2010;468(1):266-275.
- Steensen RN, Bentley JC, Trinh TQ, Backes JR, Wiltfong RE. The prevalence and combined prevalences of anatomic factors



- associated with recurrent patellar dislocation: a magnetic resonance imaging study. *Am J Sports Med.* 2015;43(4):921-927.
34. Stephen JM, Dodds AL, Lumpaopong P, et al. The ability of medial patellofemoral ligament reconstruction to correct patellar kinematics and contact mechanics in the presence of a lateralized tibial tubercle. *Am J Sports Med.* 2015;43(9):2198-2207.
  35. Straume-Naesheim TM, Randsborg PH, Mikaelsen JR, et al. Recurrent lateral patella dislocation affects knee function as much as ACL deficiency—however patients wait five times longer for treatment. *BMC Musculoskelet Disord.* 2019;20(1):318.
  36. Tanaka MJ. Editorial commentary: medial patellofemoral ligament reconstruction for knee patellar instability. When are soft tissue procedures not enough? *Arthroscopy.* 2018;34(2):511-512.
  37. Tensho K, Akaoka Y, Shimodaira H, et al. What components comprise the measurement of the tibial tuberosity–trochlear groove distance in a patellar dislocation population? *J Bone Joint Surg Am.* 2015;97(17):1441-1448.
  38. Thompson P, Metcalfe AJ. Current concepts in the surgical management of patellar instability. *Knee.* 2019;26(6):1171-1181.
  39. Tscholl PM, Wanivenhaus F, Centmaier-Molnar V, Camenzind RS, Fucentese SF. Clinical and radiological results after one hundred fifteen MPFL reconstructions with or without tibial tubercle transfer in patients with recurrent patellar dislocation—a mean follow-up of 5.4 years. *Int Orthop.* 2020;44(2):301-308.
  40. Ward SR, Terk MR, Powers CM. Patella alta: association with patellofemoral alignment and changes in contact area during weight-bearing. *J Bone Joint Surg Am.* 2007;89(8):1749-1755.
  41. Weber AE, Nathani A, Dines JS, et al. An algorithmic approach to the management of recurrent lateral patellar dislocation. *J Bone Joint Surg Am.* 2016;98(5):417-427.
  42. Xu Z, Zhang H, Chen J, Mohamed SI, Zhou A. Femoral anteversion is related to tibial tubercle–trochlear groove distance in patients with patellar dislocation. *Arthroscopy.* 2020;36(4):1114-1120.
  43. Zaffagnini S, Previtalli D, Tamborini S, et al. Recurrent patellar dislocations: trochleoplasty improves the results of medial patellofemoral ligament surgery only in severe trochlear dysplasia. *Knee Surg Sports Traumatol Arthrosc.* 2019;27(11):3599-3613.
  44. Zhang Z, Zhang H, Song G, et al. A high-grade J sign is more likely to yield higher postoperative patellar laxity and residual maltracking in patients with recurrent patellar dislocation treated with derotational distal femoral osteotomy. *Am J Sports Med.* 2019;48(1):117-127.
  45. Zhang Z, Zhang H, Song G, Zheng T, Feng H. A pre-operative grade 3 J-sign adversely affects short-term clinical outcome and is more likely to yield MPFL residual graft laxity in recurrent patellar dislocation. *Knee Surg Sports Traumatol Arthrosc.* 2020;28(7):2147-2156.